



Intestinal perforation involving the Dacron cuff of nephrostomy tubes following subcutaneous ureteral bypass system implantation for ureteral obstructions in two cats

Authors: Johnston, Sigrid K, Bennett, Tristram, and Miller, Amanda J

Source: Journal of Feline Medicine and Surgery Open Reports, 7(1)

Published By: SAGE Publishing

URL: <https://doi.org/10.1177/20551169211013295>

BioOne Complete (complete.BioOne.org) is a full-text database of 200 subscribed and open-access titles in the biological, ecological, and environmental sciences published by nonprofit societies, associations, museums, institutions, and presses.

Your use of this PDF, the BioOne Complete website, and all posted and associated content indicates your acceptance of BioOne's Terms of Use, available at www.bioone.org/terms-of-use.

Usage of BioOne Complete content is strictly limited to personal, educational, and non - commercial use. Commercial inquiries or rights and permissions requests should be directed to the individual publisher as copyright holder.

BioOne sees sustainable scholarly publishing as an inherently collaborative enterprise connecting authors, nonprofit publishers, academic institutions, research libraries, and research funders in the common goal of maximizing access to critical research.



Intestinal perforation involving the Dacron cuff of nephrostomy tubes following subcutaneous ureteral bypass system implantation for ureteral obstructions in two cats

Journal of Feline Medicine and Surgery Open Reports
1–7

© The Author(s) 2021

Article reuse guidelines:

sagepub.com/journals-permissions

DOI: 10.1177/20551169211013295

journals.sagepub.com/home/jfmsopenreports

This paper was handled and processed by the European Editorial Office (ISFM) for publication in *JFMS Open Reports*



Sigrid K Johnston, Tristram Bennett and Amanda J Miller

Abstract

Case summary This case report describes two cats that had subcutaneous ureteral bypass (SUB) systems implanted and subsequently developed duodenal perforations and septic peritonitis associated with the Dacron cuff of the nephrostomy tube. One cat recovered following surgical explantation of the SUB system with intestinal resection and anastomosis of the perforated small intestine, and – at the time of writing – is still alive. The other cat was humanely euthanased intraoperatively at the owner's request owing to its perceived prognosis.

Relevance and novel information To our knowledge this is the first time this complication has been reported following SUB device placement.

Keywords: Subcutaneous ureteral bypass (SUB); gastrointestinal perforation; dacron cuff; septic peritonitis

Accepted: 5 April 2021

Introduction

The subcutaneous (SC) ureteral bypass (SUB) implant system is the latest device used to surgically address feline ureterolithiasis, ureteral strictures and neoplasia, which result in partial or complete urinary outflow obstruction.^{1–6} The SUB device allows urinary diversion from the obstructed ureter via a locking-loop pigtail nephrostomy catheter that enters a readily accessible SC injection shunting port and subsequently a cystostomy catheter.^{2,3,5,6} The reported short-term postoperative complications associated with SUB implantation include implant occlusion from blood clots and urolith material, device leakage, tube kinking, haemorrhage, dysuria and urinary tract infections (UTIs).^{2,7} The most significant long-term complication is mineralisation of the SUB device, most commonly the cystostomy tube.^{3,7} Other reported long-term complications include migration of the cystostomy catheter and extrusion of the SC access port.^{8,9}

To our knowledge, at the time of publication, there have been no reported long-term gastrointestinal complications

with SUB system implantation in cats. The purpose of this case report is to describe two cases seen with similar post-operative complications involving the nephrostomy tube Dacron cuff perforating the duodenum and the clinical outcomes of this.

Case descriptions

In both cases described, the cats initially presented to a specialist referral practice for feline urolithiasis resulting in either unilateral (case 1) or bilateral (case 2) ureteral obstruction. Following appropriate diagnostic investigations, both cats subsequently underwent a modified

Small Animal Specialist Hospital, North Ryde, NSW, Australia

Corresponding author:

Sigrid K Johnston BVSc, MANZCVS (Surgery), Small Animal Specialist Hospital, 1 Riverside Corporate Park, 1 Richardson Pl, North Ryde, NSW 2113, Australia
Email: sigridjohnston@gmail.com



Creative Commons Non Commercial CC BY-NC: This article is distributed under the terms of the Creative Commons

Attribution-NonCommercial 4.0 License (<https://creativecommons.org/licenses/by-nc/4.0/>) which permits non-commercial use, reproduction and distribution of the work without further permission provided the original work is attributed as specified on the SAGE and Open Access pages (<https://us.sagepub.com/en-us/nam/open-access-at-sage>).

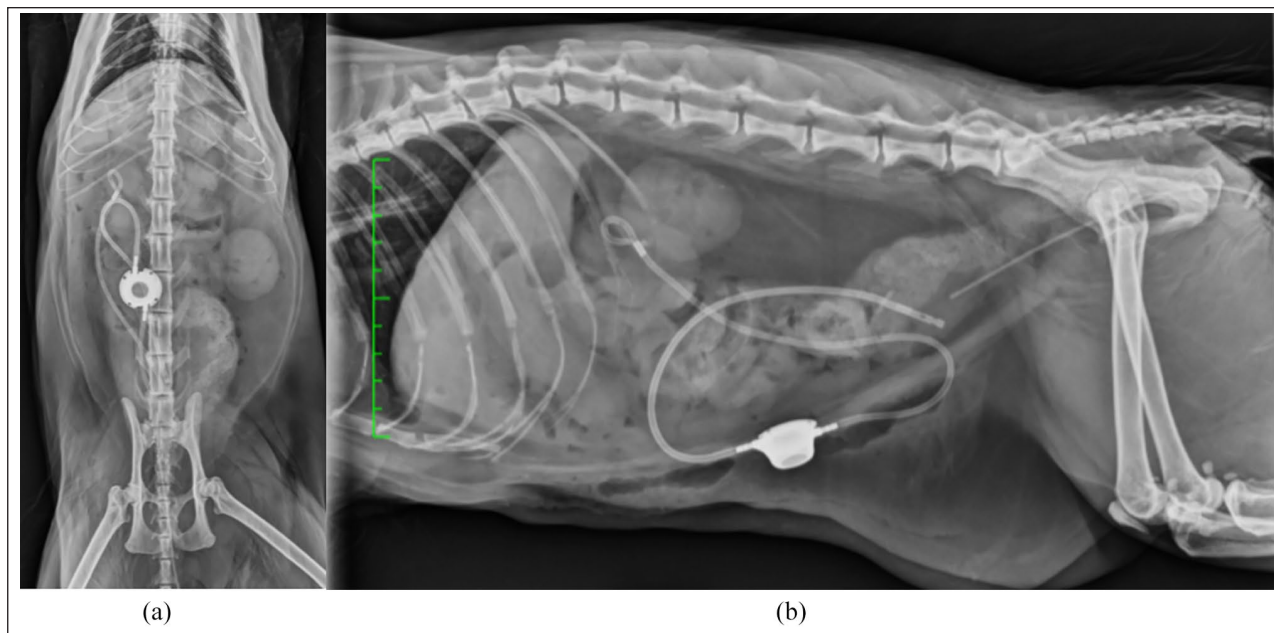


Figure 1 Immediate postoperative radiographs following initial unilateral subcutaneous ureteral bypass placement for case 1: (a) ventrodorsal abdominal radiograph; and (b) right lateral abdominal radiograph

Seldinger fluoroscopic-guided implantation of the SUB systems as per the surgical guidelines published by Berent and Weisse.² There were no intraoperative complications in either cat reported following SUB implantation. Once the system was surgically secured, saline solution (0.9% NaCl Solution; Baxter) iohexol (50:50 [Omnipaque; GE Healthcare]) was injected under fluoroscopic guidance until the entire SUB system contained contrast and no leakage was documented.

Three-view abdominal radiographs were performed immediately postoperatively in both cases, which revealed appropriate positioning of the SUB devices without any kinking in the tubing. Dacron cuff implants were positioned appropriately on the renal capsule and bladder wall, aided by visualisation of the radio-opaque markers on these implants (Figures 1 and 2). In case 2, it is likely that the pigtail catheter was not appropriately locked into the right kidney as this nephrostomy catheter later migrated (Figure 2).

In case 1, a small SC septic abscess developed over the right caudal abdomen 6 days postoperatively, where the bypass tubing was positioned. Ultrasound-guided fine-needle aspiration was performed and fluid culture and sensitivity (C+S) tests revealed a heavy growth of *Mycoplasma* species. Amoxicillin clavulanate (25 mg/kg PO q12h [Amoxyclav; Apex Laboratories]) and marbofloxacin (5 mg/kg PO q24h [Zeniquin; Zoetis]) were commenced for 8 weeks, after which the abscess completely resolved.

Approximately 1 month postoperatively, repeat abdominal ultrasound was performed for both cases,

which confirmed the resolution of hydronephrosis and pyelectasia, and SUB implant positioning was static. The right renal pelvis width was 1.7 mm in case 1, and the left and right measurements in case 2 were 2 mm and 2.6 mm, respectively.

Regular routine prophylactic flushing (every 3 months) through the SUB cutaneous port was performed inconsistently using tetra-EDTA. Time periods between flushes varied from 3 to 12 months in both cases, which was a result of demeanour issues requiring heavy sedation for basic handling and procedures, as well as financial constraints.

Approximately 6 months after surgery, case 1 underwent routine SUB flushing and repeat ultrasound. This identified a 7.5 mm × 9.8 mm hypoechoic rounded structure at the caudal pole of the right kidney centred over the nephrostomy tube. A loop of small intestine was passing over the nephrostomy site and the structure was suspected to be fibrosis or a granuloma. There were no other abnormalities detected at this time and this continued to be a static finding at subsequent ultrasounds performed approximately every 6 months. No other ultrasonographic abnormalities were detected in either case throughout the follow-up period.

Case 1

A 12-year-old spayed female domestic longhair cat presented to the emergency Department (ED) of a specialist hospital 36 months following right SUB system placement with a history of 3 days of lethargy, hyporexia and vomiting. The cat was pyrexic (temperature 40°C) and abdominal

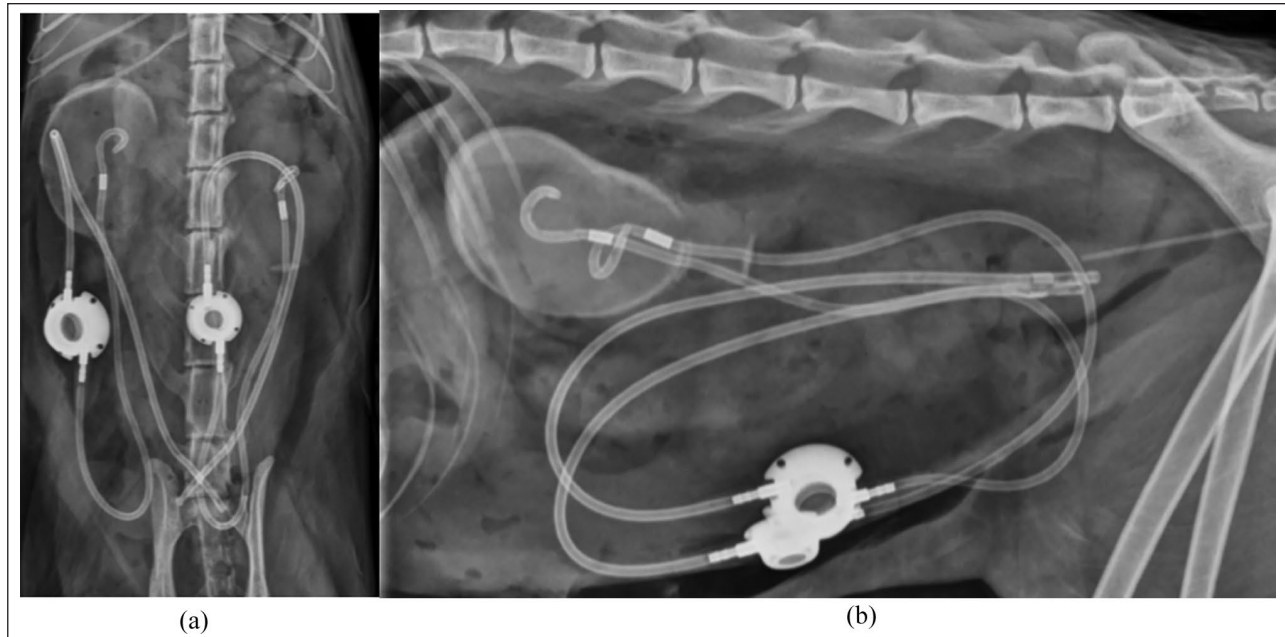


Figure 2 Immediate postoperative radiographs following initial bilateral subcutaneous ureteral bypass placement for case 2: (a) ventrodorsal abdominal radiograph; and (b) right lateral abdominal radiograph

palpation revealed no pain response associated with the right SC bypass port and implant. Abdominal ultrasonography performed by a board-certified radiologist revealed that the proximal nephrostomy tube of the SUB system, including the Dacron cuff, was located in the duodenal lumen (seen as an approximately 8 mm, hyperechoic, linear intraluminal structure). The caudal pole of the right kidney, nephrostomy tube and adjacent duodenum were surrounded by hypoechoic material.

Surgical management Preoperative bloodwork revealed a chronic non-regenerative, microcytic anaemia (haematocrit 0.251/l; packed cell volume [PCV]/total plasma protein [TPP] 20/60), moderate left shift banded neutrophilia ($27.8 \times 10^9/l$), elevated symmetric dimethylarginine (SDMA; 18 $\mu\text{g}/\text{dl}$), hypocalcaemia (1.74 mmol/l; no ionised calcium was performed) and mild hypoalbuminaemia (20 g/l). Creatinine and urea were within the normal reference intervals. Perioperative therapeutics included ampicillin (22 mg/kg IV [Austrapen; Mylan]), enrofloxacin (5 mg/kg IV [Baytril; Bayer]) and fentanyl (2–8 $\mu\text{g}/\text{kg}/\text{h}$ constant rate infusion [Fentanyl; Hospira]). Following these clinical and ultrasonographic findings the cat subsequently underwent a ventral midline exploratory coeliotomy. A small volume of sero-sanguinous free abdominal fluid was present and no fluid C + S was performed. The peritoneal cavity was lavaged with 500 ml of warmed sterile saline and suctioned.

The right renal capsule was grossly thickened and friable. The distal descending duodenum at the level of the duodenocolic ligament and the tip of the right pancreatic

limb was firmly adhered to the right kidney (Figure 3a). A moderate volume of haemorrhaging occurred during dissection of the adhesions from the right kidney, during which the cat received a total of 40 ml, type A whole blood transfused over 2 h intraoperatively without complications. The Dacron cuff of the nephrostomy tube was incorporated into the duodenum, resulting in perforation of the bowel at its mesenteric border with leakage of intestinal contents (see Figure 3b). The duodenocolic ligament was freed to allow resection of approximately 80 mm of affected small intestine (see Figure 4). An end-to-end anastomosis was performed using 4-0 polydioxanone suture (Monoplus; B-Braun) in a simple interrupted appositional suture pattern. The resultant mesenteric rent was closed with 4-0 polydioxanone suture (Monoplus; B-Braun) in a simple continuous pattern.

The decision was made to explant the right SUB system owing to the high risk of septic peritonitis and concerns for the SUB system being infected and resulting in ongoing pyelonephritis. Once explanted, the abdominal cavity was lavaged with 1 l warmed sterile saline (0.9% NaCl Solution; Baxter). A routine three-layer abdominal closure was performed. Immediate postoperative PCV/TPP was 38/60.

Follow-up Eight days after surgery, the cat was seen in the ED for a surgical site swelling and hyporexia of 24 h duration. An abdominal-focused assessment with ultrasonography for trauma scan revealed echogenicity consistent with soft tissue and occasional SC fluid pockets along the abdominal incision. The presumptive diagnosis was SC

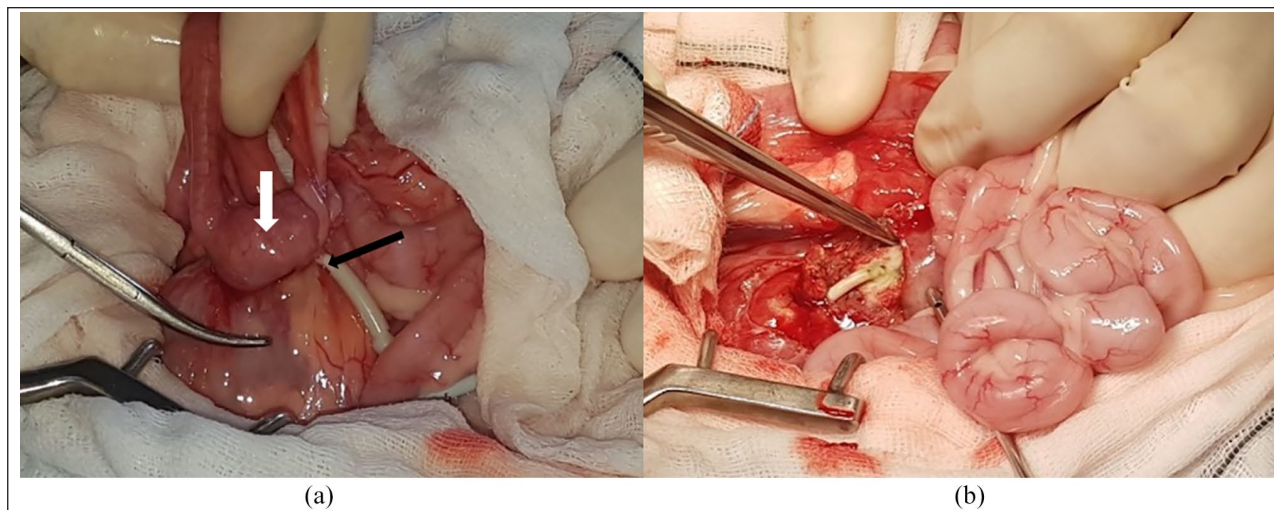


Figure 3 (a) Thickened capsule of the right kidney (curved haemostat), with the distal duodenum firmly adhered (white arrow) and nephrostomy tubing passing intraluminally (black arrow). (b) Dacron cuff (forceps) perforating the duodenum with leakage of intestinal contents

inflammation or aseptic cellulitis and ongoing monitoring at home was recommended. The cat was continued on a previously prescribed amoxicillin-clavulanate course (22 mg/kg PO q12h [Amoxyclav; Apex Laboratories]) for a concurrent UTI. Repeat renal bloodwork revealed a normal urea and creatinine, SDMA had marginally improved (17 µg/dl) and no urine specific gravity was recorded.

The cat re-presented 2 days later for ongoing hypoxia and progressive surgical site swelling, and subsequently surgical exploration was performed. A large pocket containing purulent material lined by grossly abnormal SC tissue was noted around the resected suture line. There was communication with the abdominal cavity. A sample of fluid was submitted for culture and sensitivity. The suture line, including the SC and dermal tissue, with associated suture material from the previous surgery was excised en bloc. The area was flushed copiously with sterile saline. The SC layer was apposed using 2-0 polydioxanone (Monoplus; B-Braun) in a simple continuous pattern, and the cutaneous layer was apposed using 3-0 polyamide (Dafilon; B-Braun) in a cruciate pattern. Tissue culture results revealed a light growth of multidrug-resistant *Enterococcus faecium* and mixed anaerobes. No antimicrobials were continued in the longer term owing to the resistance pattern; however, the wound was bandaged to prevent nosocomial infections and went on to heal without further complications. Follow-up urine C+S was performed 1 month following surgery, which revealed negative growth.

Case 2

A 3-year-old neutered male Siamese cat presented to a specialist hospital 14 months following bilateral SUB

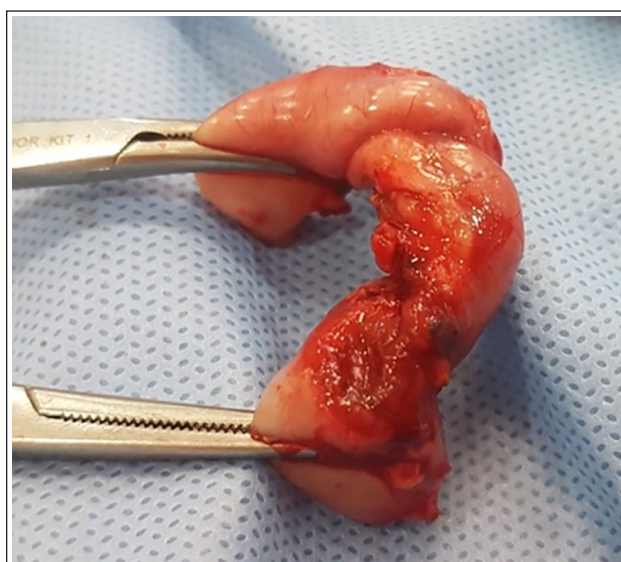


Figure 4 Resultant duodenectomy with full-thickness perforation at the mesenteric border

system placement for progressive diarrhoea, vomiting and poor appetite of 2 weeks' duration. Abdominal ultrasonography was performed by a board-certified radiologist, which revealed diffuse dilation of the jejunum with visible peristalsis and no source of obstruction. The appropriate location of the cystostomy tube within the urinary bladder was also confirmed. The cat was treated symptomatically, and re-examination was recommended if there was no clinical improvement.

Four days later the cat re-presented for clinical deterioration with progressive vomiting, lethargy and inappetence. Repeat abdominal ultrasonography revealed a

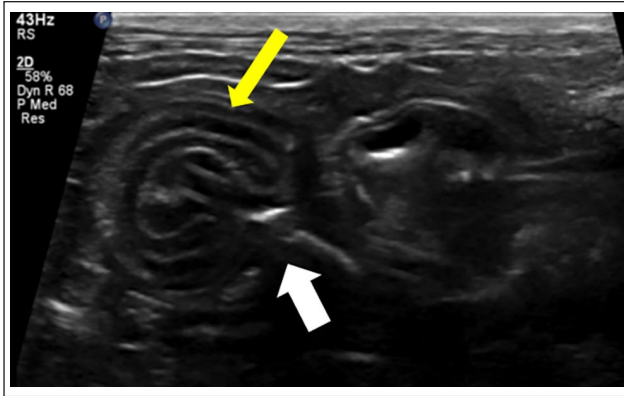


Figure 5 Ultrasound image of the plicating jejunum (yellow arrow) with the right nephrostomy tubing entering the descending duodenum (white arrow)

hyperechoic tube-like object perforating the small intestine with regional free abdominal fluid and partial intussusception (see Figure 5). Distally, the tube-like object was seen to pass through the duodenal wall into the peritoneum, where it was traced towards the urinary bladder (see Figure 6). The fluid was suspected to represent regional peritonitis and the foreign object likely represented the nephrostomy tube of the right SUB implant.

Surgical management Preoperative bloodwork revealed only a mildly elevated blood urea nitrogen (20.4 mmol/l), performed 5 days prior to surgery. No repeat biochemistry was performed following this. Preoperative PCV/TPP was 28/58. Perioperative therapeutics included ampicillin (22 mg/kg IV [Austrapen; Mylan]) and fentanyl (2–8 µg/kg/h CRI [Fentanyl; Hospira]).

Following these clinical and ultrasonographic findings the cat underwent a ventral midline exploratory coeliotomy. Multiple adhesions of the greater omentum were identified and a firm disc-like foreign body was palpated in the descending duodenum within the perinephric adhesions (see Figure 7a). The left SUB implant system was grossly normal. There was a scant volume of blood-tinged peritoneal fluid (see Figure 7b). Dissection of the perinephric adhesions revealed the right nephrostomy tube entering the antimesenteric wall of the descending duodenum, travelling approximately 20 mm distally within the lumen then exiting the descending duodenum before resuming its normal course to the right caudal abdominal wall incision and joining the SC port. The radiopaque nephrostomy tube marker was located external to the renal capsular surface and the previously palpated intraluminal disc was confirmed to be the Dacron cuff of the right nephrostomy tube (see Figure 7b). Dissection of the adhesions of the distal aspect of the right urinary catheter to the mid-jejunum revealed an additional partial thickness

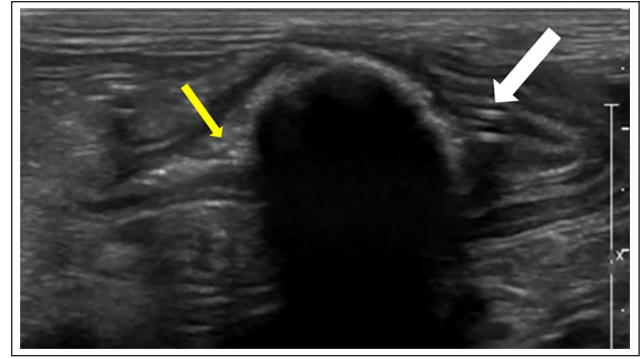


Figure 6 Ultrasound image of the hyperechoic structure within the distal duodenum (white arrow); proximally it is slightly filled with ingesta (yellow arrow)

jejunal perforation through the seromuscular layer (see Figure 7c). The right kidney appeared to have a viable blood supply and the decision to remove the right SUB system was made owing to similar concerns as in case 1. The owner elected for intraoperative euthanasia prior to completion of this procedure, based on the perceived prognosis.

Discussion

As mentioned previously, published short-term postoperative complications include implant occlusion from blood clots and urolith material, device leakage, tube kinking, haemorrhage, dysuria and UTIs.^{2,7} Mineralisation of the cystostomy tube is the most commonly reported long-term complication with known risk factors including the use of a small port, silicone-based catheters and postoperative ionised hypercalcaemia.^{3,7} To our knowledge, at the time of publication, there have been no reported gastrointestinal complications relating to SUB implant systems or other ureteral decompressive surgeries.

The SUB system was developed over 10 years ago, based on the SC nephrovesical bypass systems used in humans with ureteral obstructions unsuitable for stenting.^{2,10,11} The Seldinger technique used in humans is a minimally invasive procedure that uses either ultrasonographic or fluoroscopic guidance and relies on the placement of a polyurethane, non-cuffed, J-tube into the target renal calyx, securing the nephrostomy catheter to the renal capsule by the J-loop and tube fixation to the SC tissue with a non-absorbable monofilament suture to prevent implant dislocation. There is no reported use of sterile tissue glue with the placement of these systems.^{10–12} The only gastrointestinal complications seen in humans is related to the puncture of organs during percutaneous nephrostomy tube placement, as their application is not through an open approach.^{13,14}

Case 1 successfully underwent right explantation of the entire SUB system. The use of fluoroscopy through

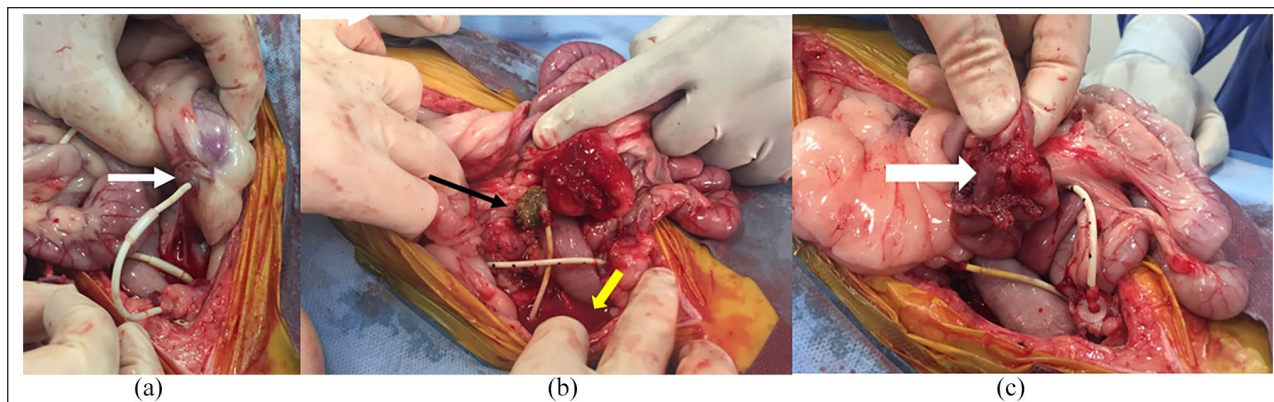


Figure 7 (a) Right Dacron cuff (white arrow) perforating the descending duodenum with perinephric adhesions. (b) Scant volume of blood-tinged peritoneal fluid (yellow arrow) and explantation of the Dacron cuff (black arrow). (c) Additional partial jejunal perforation (white arrow)

the injection of contrast medium into the SUB pre- and perioperatively with initial implantation highlights the importance of determining ureteral patency. A successful SUB system will provide urinary diversion and normalise the cats bloodwork and ultrasound findings; however, if explantation is performed without having ureteral patency re-established this can have devastating effects, especially if contralateral renal function is diminished. Given the ongoing concerns around SUB systems being infected in both cases with risks of septic peritonitis and pyelonephritis, explantation was deemed necessary. Alternative surgical options could have included exchanging the nephrostomy catheter or ureteronephrectomy if there was an ongoing absence of ureteral patency.

As these cases include the first reported gastrointestinal complications arising from SUB implants, the possible aetiologies can only be of a theoretical nature. The application of sterile cyanoacrylate glue (Histoacryl; B-Braun) between the Dacron cuff of the nephrostomy catheter and the renal capsule has been reported to provide implant security and prevent leakage from the renal capsule.² Excessive glue during application may act as an abrasive irregular surface on the renal capsule, and friction may result between tissue surfaces with intestinal peristalsis. Careful tissue glue application and subsequently covering the Dacron cuff with omentum or perinephric adipose tissue may aid in providing longer-term implant security. Anatomically, the close proximity of the duodenum to the right renal capsule as a result of its fixed position by a shorter mesentery, and the increased mobility of feline kidneys comparatively to canine kidneys could be of significance as both cases had complications associated with the right-sided nephrostomy tubes. Transmural migration of surgical sponges into intestines has been studied experimentally in rats with four stages of pathogenesis: foreign body reaction, secondary infection, mass formation and remodelling.¹⁵ Additionally, late Dacron patch inflammatory complications in humans

has been reported up to 7 years post-implantation.¹⁶ Therefore, secondarily, a foreign body reaction could have developed from the Dacron cuff within the abdominal cavity, contributing to the transmural migration into the small intestine.

Conclusions

While delayed intestinal perforation presumptively caused by multifactorial aetiology is a rare occurrence in the placement of SUB systems in feline patients, it should be considered a possible postoperative complication that may arise as a result of performing this ureteral decompressive surgery. It highlights the need for further investigation into the use cyanoacrylate tissue glue and its application on the renal capsule in relation to securing the Dacron cuff. Meticulous tissue glue application to the renal capsule when securing the Dacron cuff, followed by covering the cuff with omentum or perinephric adipose tissue, should also be further investigated.

Conflict of interest The authors declared no potential conflicts of interest with respect to the research, authorship, and/or publication of this article.

Funding The authors received no financial support for the research, authorship, and/or publication of this article.

Ethical approval The work described in this manuscript involved the use of non-experimental (owned or unowned) animals. Established internationally recognised high standards ('best practice') of veterinary clinical care for the individual patient were always followed and/or this work involved the use of cadavers. Ethical approval from a committee was therefore not specifically required for publication in JFMS Open Reports. Although not required, where ethical approval was still obtained, it is stated in the manuscript.

Informed consent Informed consent (either verbal or written) was obtained from the owner or legal custodian of all animal(s)

described in this work (either experimental or non-experimental animals) for the procedure(s) undertaken (either prospective or retrospective studies). No animals or humans are identifiable within this publication, and therefore additional informed consent for publication was not required.

References

- 1 Berent AC. **Ureteral obstructions in dogs and cats: a review of traditional and new interventional diagnostic and therapeutic options.** *J Vet Emerg Crit Care* 2011; 21: 86–103.
- 2 Berent AC and Weisse CW. **The SUB, a subcutaneous ureteral bypass device. A surgical guide.** https://norfolkvetprod-ucts.com/PDF/SUB/SUB2_Surgical_Guide_2018-03-email.pdf (2018, accessed 31 July, 2019).
- 3 Berent AC, Weisse CW, Bagley D, et al. **The use of a subcutaneous ureteral bypass (SUB) device for the treatment of benign ureteral obstructions in cats: 137 cats; 174 ureters (2009–2015).** *J Am Vet Med Assoc* 2018; 253: 1309–1327.
- 4 Deroy C, Rossetti D, Ragetly G, et al. **Comparison between double-pigtail ureteral stents and ureteral bypass devices for treatment of ureterolithiasis in cats.** *J Am Vet Med Assoc* 2017; 251: 429–437.
- 5 Horowitz C, Berent AC, Weisse CW, et al. **Predictors of outcome for cats with ureteral obstructions after interventional management using ureteral stents or a subcutaneous ureteral bypass device.** *J Feline Med Surg* 2013; 15: 1052–1062.
- 6 Livet V, Pillard P, Goy-Thollot I, et al. **Placement of subcutaneous ureteral bypasses without fluoroscopic guidance in cats with ureteral obstruction: 19 cases (2014–2016).** *J Feline Med Surg* 2016; 19: 1030–1039.
- 7 Chik C, Berent AC, Weisse CW, et al. **Therapeutic use of tetrasodium ethylenediaminetetraacetic acid solution for treatment of subcutaneous ureteral bypass device mineralization in cats.** *J Vet Inter Med* 2019; 33: 2124–2132.
- 8 Fouhety A and Boursier JF. **Infection and extrusion of a subcutaneous access port in a cat: a long-term postoperative complication of a subcutaneous ureteral bypass device.** *JFMS Open Rep* 2020; 6. DOI: 10.1177/2055116920911765.
- 9 Pilot M, Broome C, Hammond G, et al. **Bladder catheter dislodgement as a complication following placement of a subcutaneous ureteral bypass device.** *Vet Rec Case Rep* 2017; 5: e000479. DOI: 10.1136/vetreccr-2017-000479.
- 10 Schmidbauer J, Kratzik C, Klinger HC, et al. **Nephrovesical subcutaneous ureteric bypass: long-term results in patients with advanced metastatic disease – improvement of renal function and quality of life.** *Eur Urol* 2006; 50: 1073–1078.
- 11 Wang Y, Wang G, et al. **Subcutaneous nephrovesical bypass: Treatment for ureteral obstruction in advanced metastatic disease.** *Oncol Lett* 2015; 9: 387–390.
- 12 Jurczok A, Loertzer H, Wagner S, et al. **Subcutaneous nephrovesical and nephrocutaneous bypass.** *Gynecol Obstet Invest* 2005; 59: 144–148.
- 13 Dyer RB, Regan JD, Kavanagh PV, et al. **Percutaneous nephrostomy with extension of the techniques: step by step.** *Radiographics* 2002; 22: 503–525.
- 14 Wah TM, Weston MJ and Irving HC. **Percutaneous nephrostomy insertion.** *Clin Radiol* 2004; 59: 255–261.
- 15 Wattanasirichaigoon S. **Transmural migration of a retained surgical sponge into the intestinal lumen: an experimental study.** *J Med Assoc Thai* 1996; 79: 415–422.
- 16 Alawy M, Tawfick W, Elkassaby M, et al. **Late Dacron patch inflammatory reaction after carotid endarterectomy.** *Eur J Vasc Endovasc Surg* 2017; 54: 423–429.