



Olivopontocerebellar degeneration associated with 3-hydroxy-3-methylglutaric aciduria in a domestic shorthair cat

Authors: West, Natalie, Matiasek, Kaspar, and Rusbridge, Clare

Source: Journal of Feline Medicine and Surgery Open Reports, 7(2)

Published By: SAGE Publishing

URL: <https://doi.org/10.1177/20551169211037899>

BioOne Complete (complete.BioOne.org) is a full-text database of 200 subscribed and open-access titles in the biological, ecological, and environmental sciences published by nonprofit societies, associations, museums, institutions, and presses.

Your use of this PDF, the BioOne Complete website, and all posted and associated content indicates your acceptance of BioOne's Terms of Use, available at www.bioone.org/terms-of-use.

Usage of BioOne Complete content is strictly limited to personal, educational, and non - commercial use. Commercial inquiries or rights and permissions requests should be directed to the individual publisher as copyright holder.

BioOne sees sustainable scholarly publishing as an inherently collaborative enterprise connecting authors, nonprofit publishers, academic institutions, research libraries, and research funders in the common goal of maximizing access to critical research.



Olivopontocerebellar degeneration associated with 3-hydroxy-3-methylglutaric aciduria in a domestic shorthair cat

Journal of Feline Medicine and Surgery Open Reports
1–10

© The Author(s) 2021

Article reuse guidelines:

sagepub.com/journals-permissions

DOI: 10.1177/20551169211037899

journals.sagepub.com/home/jfmsopenreports

This paper was handled and processed by the European Editorial Office (ISFM) for publication in *JFMS Open Reports*



Natalie West¹ , Kaspar Matiasek²
and Clare Rusbridge³

Abstract

Case summary A rescue charity-owned 6-month-old neutered female domestic shorthair cat was presented with progressive tetraparesis, increased extensor muscle tone and signs of spinocerebellar ataxia, including hypermetria. The cat's male sibling, with similar progressive neurological signs, had been euthanased 2 months previously. An inherited metabolic disorder was suspected. Urine for determination of organic acid concentration was obtained and the cat was prescribed carnitine and taurine supplementation. The cat was euthanased 3 months later following progressive neurological signs, including ataxia, tetraparesis, tendency to fall, bilateral absent menace response and intention tremor. A selective post-mortem examination was obtained, taking samples from the brain, cervical spinal cord, tibial branch of the sciatic nerve, muscle, liver and kidneys. Organic acid analysis results received after euthanasia revealed a marked elevation of 3-hydroxy-3-methylglutaric acid (45 mmol/mol creatine [normal range 0–2]) and isovalerylglycine (27 mmol/mol creatinine [normal range 0–2]). 3-Hydroxy-3-methylglutaric acid was deemed clinically relevant as it is a metabolite of 3-hydroxy-3-methylglutaryl-CoA lyase, the enzyme involved in the final step of leucine degradation. Post-mortem examination revealed diffuse, chronic-active, severe olivoponto-(spino)-cerebellar degeneration.

Relevance and novel information This is the first report of 3-hydroxy-3-methylglutaric aciduria in the veterinary literature and the first description of the neuropathology of this disorder in any species. 3-Hydroxy-3-methylglutaric aciduria in humans occurs rarely and is due to a deficiency in 3-hydroxy-3-methylglutaryl-coenzyme A lyase.

Keywords: Neuropathology; neurology; organic aciduria; metabolic disorder

Accepted: 19 July 2021

Introduction

3-Hydroxy-3-methylglutaric aciduria is characterised by excessive 3-hydroxy-3-methylglutaric acid due to deficiency in enzymes metabolising leucine into acetyl coenzyme A (acetyl-CoA) and acetoacetate. It is a rare metabolic disease with an incidence of <1/100,000 among live human newborns and only 211 cases documented worldwide since the first description in 1976.^{1–3} 3-Hydroxy-3-methylglutaric aciduria has not been previously reported in any other species.

In humans, it is an autosomal recessive condition due to deficiency in the enzyme 3-hydroxy-3-methylglutaryl-coenzyme A lyase (HL). HL is an enzyme

involved in ketogenesis, and is specifically involved in the final step of leucine degradation into acetyl CoA and the ketone body acetoacetate.⁴ A deficiency in HL

¹Fitzpatrick Referrals, Guildford, UK

²Section of Clinical and Comparative Neuropathology, Centre for Clinical Veterinary Medicine, LMU Munich, Munich, Germany

³School of Veterinary Medicine, Faculty of Health and Medical Science, Guildford, UK

Corresponding author:

Natalie West BVMS, MRCVS, Fitzpatrick Referrals, Halfway Lane, Eashing, Surrey GU7 2QQ, UK
Email: nataliewest.vet@gmail.com



Creative Commons Non Commercial CC BY-NC: This article is distributed under the terms of the Creative Commons

Attribution-NonCommercial 4.0 License (<https://creativecommons.org/licenses/by-nc/4.0/>) which permits non-commercial use, reproduction and distribution of the work without further permission provided the original work is attributed as specified on the SAGE and Open Access pages (<https://us.sagepub.com/en-us/nam/open-access-at-sage>).




Figure 1 Images taken from video footage of a male 3-month-old cat demonstrating (a) hypermetric thoracic limb gait and (b) spasticity/hypertonicity with a tendency to fall and hyperextension of limbs

therefore results in an impairment in ketone body synthesis from fatty acids, as well as impaired leucine catabolism.⁵ The latter results in accumulation of 3-hydroxy-3-methylglutaric acid, 3-methylglutaric acid, 3-methylglutaconic acids, 3-hydroxyisovaleric acid and 3-methylcrotonylglycin – all of which can be detected in urine.^{5,6} Human patients predominantly present in the neonatal period; clinical signs reflect energy deficiency, hypoglycaemia and metabolic acidosis, in the absence of ketones. Ketone bodies are an important source of energy for a multiple organ systems, especially the developing brain in human neonates.^{2,6} Approximately 30% of patients have been reported with distinct neurological abnormalities.² There have been no neuropathology reports for 3-hydroxy-3-methylglutaric aciduria in the human literature.

Case description

Three domestic shorthair kittens became under the care of a feline charity at approximately 3 weeks of age and were vaccinated and neutered. All kittens were neurologically normal at the time of acquisition. The cats were deemed neurologically normal based on their clinical examination findings, performed at the primary care veterinarian at first vaccination. Two of three kittens developed neurological signs: the first was a male; the second to develop abnormalities was female.

The affected male kitten was presented to the primary care veterinarian at 3 months of age with a 1-month history of progressive pelvic limb paresis and ataxia. Although a neurologist did not examine the cat, brief video footage of the cat walking was reviewed by a neurologist; the gait appeared hypermetric, which was more pronounced on the thoracic limbs (Figure 1a). There was generalised hypertonicity with spasticity. The cat would

fall after a few steps into lateral recumbency with all limb joints and tail in rigid hyperextension (Figure 1b). Despite the hypermetria, intention tremor of the head or limbs was not present and menace response was normal (tested by the primary care veterinarian). Mentation appeared normal in that the cat was interactive and tried to play. The cat was feline leukaemia virus (FeLV) and feline immunodeficiency virus (FIV) negative (performed by an ELISA test kit [SNAP FIV/FeLV Combo; IDEXX]). Haematology revealed a leukocytosis (white blood cell count $18.62 \times 10^9/l$; reference interval [RI] 2.87–17.02) with a monocytosis ($1.15 \times 10^9/l$; RI 0.05–0.67) and lymphocytosis ($7.67 \times 10^9/l$; RI 0.92–6.88). A therapeutic trial was initiated with clindamycin (15 mg/kg q12h) and prednisolone (0.5 mg/kg). The cat showed no clinical response and 4 weeks later was euthanased owing to worsening neurological status. No post-mortem examination was performed.

Two months later, the neutered female sibling was presented to the referral centre at 6 months of age with a 3-month history of progressive gait abnormalities. The cat had been previously tested for FeLV/FIV (ELISA SNAP FIV/FeLV; IDEXX) and was negative. On examination performed by a neurologist, the cat had appropriate mentation and no cranial nerve deficits, including menace response. The gait had some similarities to the sibling, especially the hypermetric action (Figure 2) with increased tone/spasticity of the limb and tail extensor muscles resulting in a pronounced goose-stepping action, especially of the thoracic limbs. The cat fell frequently. There was a delay in postural reactions, as demonstrated by reduced pelvic limb ‘hopping ability’ on postural testing. Spinal reflexes were normal (Figure 2).

Funds for diagnostic investigation were limited. Based on the fact that two of three siblings were affected



Figure 2 Image taken from video footage obtained during the second consultation, at which time the female cat was 6 months old. The footage demonstrates hypermetria

by progressive neurological signs, an inherited neurological disease was suspected. To investigate the possible metabolic causes, an organic acid urinalysis was obtained and non-specific supplementation was started: L-carnitine at ~100 mg/kg/day, in addition to taurine at (500 mg/day), and a nutraceutical containing omega-3 fatty acids, phosphatidylserine, vitamin E, ginkgo biloba extract and B vitamins (Nutramind [Nutravet], at the recommended dose for a cat). The cat continued to deteriorate, and 3 months later the gait had deteriorated to the extent that the cat could only take a few steps before falling. There were more obvious cerebellar signs; the 'goose-stepping' hypermetric gait had become more exaggerated (Figure 2), muscle tone had increased and the cat had developed an intention tremor with deficit of menace response. The cat's signs suggested a cerebellar neuroanatomical localisation with spinocerebellar tract involvement. It was also considered that not all the signs were related to cerebellar disease and it was suspected that brainstem nuclei were also be affected, resulting in extrapyramidal signs of poor limb control and body movement, posture and tone (pelvic limb postural reaction deficits on examination).

The cat was euthanased and a limited post-mortem examination was obtained, taking samples from the brain, cervical spinal cord, the tibial branch of the sciatic nerve, muscle, liver and kidneys.

Urinary organic acid concentration revealed elevations in 3-hydroxy-3-methylglutaric acid (45 mmol/mol creatinine [normal range 0–2]), isovalerylglycine (27 mmol/mol creatinine [normal range 0–2]) and octanoic acid (8 mmol/mol creatinine [normal range 0–2]).

Gross examination of the cerebrum and brainstem was considered to be within normal anatomical limits. The cerebellum appeared small but had tight sulci and fissures. On trimming, subjectively, the base of cerebellar sulci only seemed slightly widened. Grossly, all other sampled tissues appeared normal.

While brain regions rostral to the mesencephalon were histologically unremarkable, significant changes were identified in the cerebellum, brainstem and spinal cord. Principal layering of the cerebellar cortex was within normal limits and the external cerebellar germinative layer had vanished, in accordance with the expected stage of maturity. Throughout the cerebellar vermis, paravermis and outer hemispheres, there was an oligofocal loss of Purkinje cells (PCs) alongside glial fibrillary acidic protein-positive Bergmann's gliosis and mild activation of microglial cells (Figure 3).

Calbindin, ITPR1 and KCNIP4 immunostains were performed to visualise the PC population (calbindin and ITPR1) and the synaptic glomeruli of granule cell layer (KCNIP4) (Figure 4). In agreement with histological findings, the number of PCs was significantly reduced in the affected cat. Distal to the PC layer and apparently preceding degeneration of PC somata, axonal torpedoes were identified extending from the granule layer downstream to cerebellar roof nuclei. Within the cerebellar white matter there was extensive diffuse astrogliosis, axonal torpedoes, multiple empty dilated myelin tubes, digestion chambers and occasional degenerate neurons of cerebellar (roof) nuclei (Figure 5). The affected axons mostly stained weakly positive for the Purkinje markers mentioned above. Further axonal spheroids of other neuronal origin, empty tubes and digestion chambers were scattered across long spinal tracts but predominantly affected the spinocerebellar and spinocuneocerebellar tracts and the ventral funiculus (Figure 4e). Within the spinal tracts, fibre dropout was extensive, leaving only post-resorptive macrophage clusters and microglial stars. Apart from cerebellar (roof) nuclei, single degenerating neurons were seen in multiple brainstem nuclei followed by scant gliosis. Notably, vestibular nuclei were spared, while multifocal loss of neurons and extensive fibrillary gliosis were evident in pre-cerebellar pontine and olivary nuclei (Figure 4b,c). No changes were seen in spinal grey matter columns.

Summarising these findings, a chronic progressive olivopontocerebellar degeneration with spinal white matter involvement was diagnosed.

Discussion

We have described the neurological deterioration of two feline litter siblings. The onset of signs was similar for both cats at age 3 and 4 months. Both cats showed a hypermetric gait with increased tone/spasticity of the limb and tail extensor muscles, which was more pronounced for the thoracic limbs. Both cats progressively deteriorated and were euthanased. Only one of the cats was presented to the referral hospital, whereby organic urinalysis revealed elevations in 3-hydroxy-3-methylglutaric acid, isovalerylglycine and octanoic acid, and

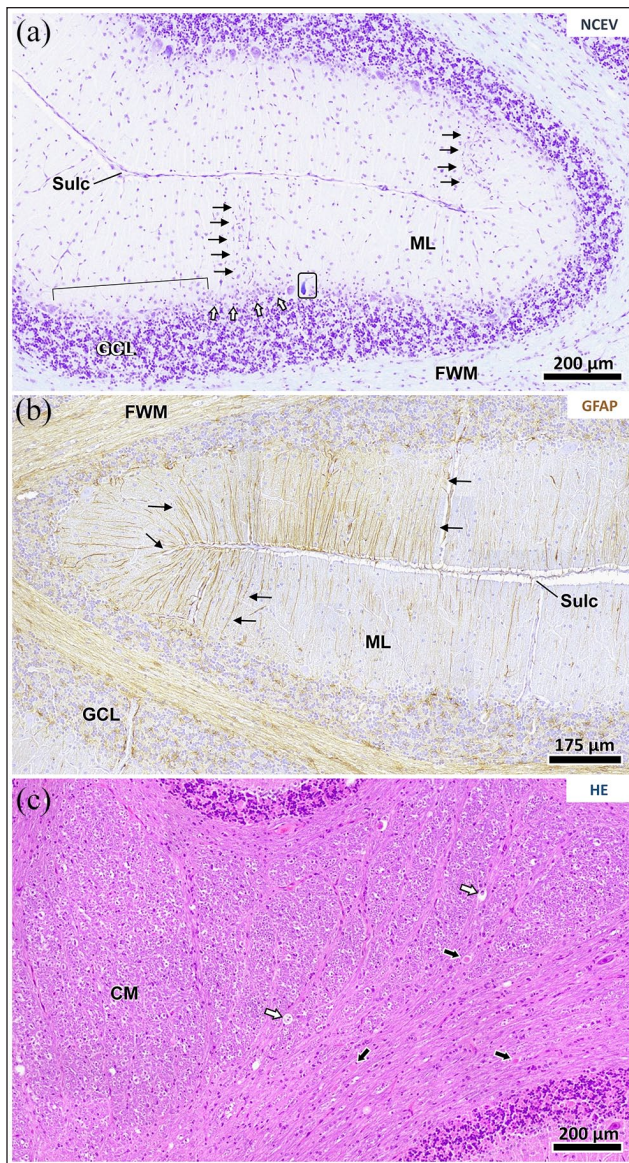


Figure 3 Spatial pattern of cerebellar changes in 3-hydroxy-3-methylglutaric aciduria. (a) Cerebellar cortical changes encompass widespread loss of Purkinje cells (PCs) indicated by wide spacing (bracket) and multifocal Bergmann's gliosis (white arrows). The molecular layer (ML) of affected areas was characterised by microgliosis (black arrows). Degenerative changes are occasionally seen in residual PCs (frame). Nissl cresyl echt violet staining. (b) The true extent of cerebellar cortical involvement becomes evident after glial fibrillary acidic protein (GFAP) staining with chromogen 3,3'-diaminobenzidine, which highlights the astroglial changes (brown signal). Neuronal degeneration is accompanied by extensive accentuation of apical Bergmann glia processes (black arrows) spanning the PC layer and pial surface. (c) Cerebellar white matter throughout the corpus medullare (CM) and foliary white matter shows the anterograde degeneration of PC axons as axonal spheroids (black arrows) and digestion chambers (white arrows). Haematoxylin and eosin staining. GCL = granule cell layer; Sulc = sulcus

the pathology revealed a diffuse, chronic-active, severe olivoponto-(spino)-cerebellar degeneration.

Explanation of clinical signs from pathology findings

Both the olivary and the pre-cerebellar pontine nuclei were found to have diffuse astrogliosis, astrocytosis and mild microgliosis (Figure 4c,d). The olivary nucleus integrates cerebellar efferents with extrapyramidal motor signals and proprioception, and is then excitatory to the climbing fibres of the inhibitory PCs (Figure 6).^{7,8} The olivary nucleus also exhibits an indirect inhibitory effect on the PCs through excitation of inhibitory interneurons,^{9,10} and is involved in a complex feedback circuit between the cerebellum and higher motor centres. Therefore, a loss of olivary neurons would result in a loss of cerebellar nuclei inhibitory control, manifesting as progressive ataxia and a high stepping gait (hyperflexion).¹¹ The pontine nucleus also functions as a relay nucleus receiving afferent fibres (pyramidal motor signals) from the cerebral cortex, projecting to the cerebellum via mossy fibres inserting on granule cell dendrites in synaptic glomeruli.^{12,13} The granule cell axons are excitatory and (parallel fibres) synapse with the PC dendritic tree exerting an excitatory input.¹⁴ The pontocerebellum regulates skilled movement.⁹ A lesion in either nuclei results in an ineffective feedback pathway, therefore causing an asynergia and a severe loss of motor coordination.^{8,13} The result of this is impaired balance, abnormal postural tone, dysmetria and the intention tremor seen in the cat diagnosed with 3-hydroxy-3-methylglutaric aciduria.⁸ The cerebellum relies on anticipatory postural adjustments together with somatosensory feedback loops to maintain balance during locomotion; ataxia develops when there is a breakdown of these mechanisms.¹⁵⁻¹⁷

On initial presentation the cat demonstrated spinocerebellar signs and weakness, lacking convincing signs that localised to the cerebellar cortex. However, there was a progressive neurological deterioration and after 3 months it had developed an intention tremor and menace response was absent. An intention tremor suggests a lesion of the cerebrocerebellum, the more lateral cerebellar hemispheres or the dentate nucleus,¹⁸ correlating with the pathology findings of chronic, severe, cerebellar white matter degeneration (Figure 3).

The neuropathological findings for this cat are similar to those suffering from an essential tremor, with PC loss, Bergmann cell gliosis and cerebellar torpedoes.¹⁹ An essential tremor is a postural and action tremor that develops secondary to pathological changes in the circuit involving the red nucleus, inferior olivary nucleus and the dentate nucleus.²⁰ We are the first to observe these neuropathological changes in a cat.

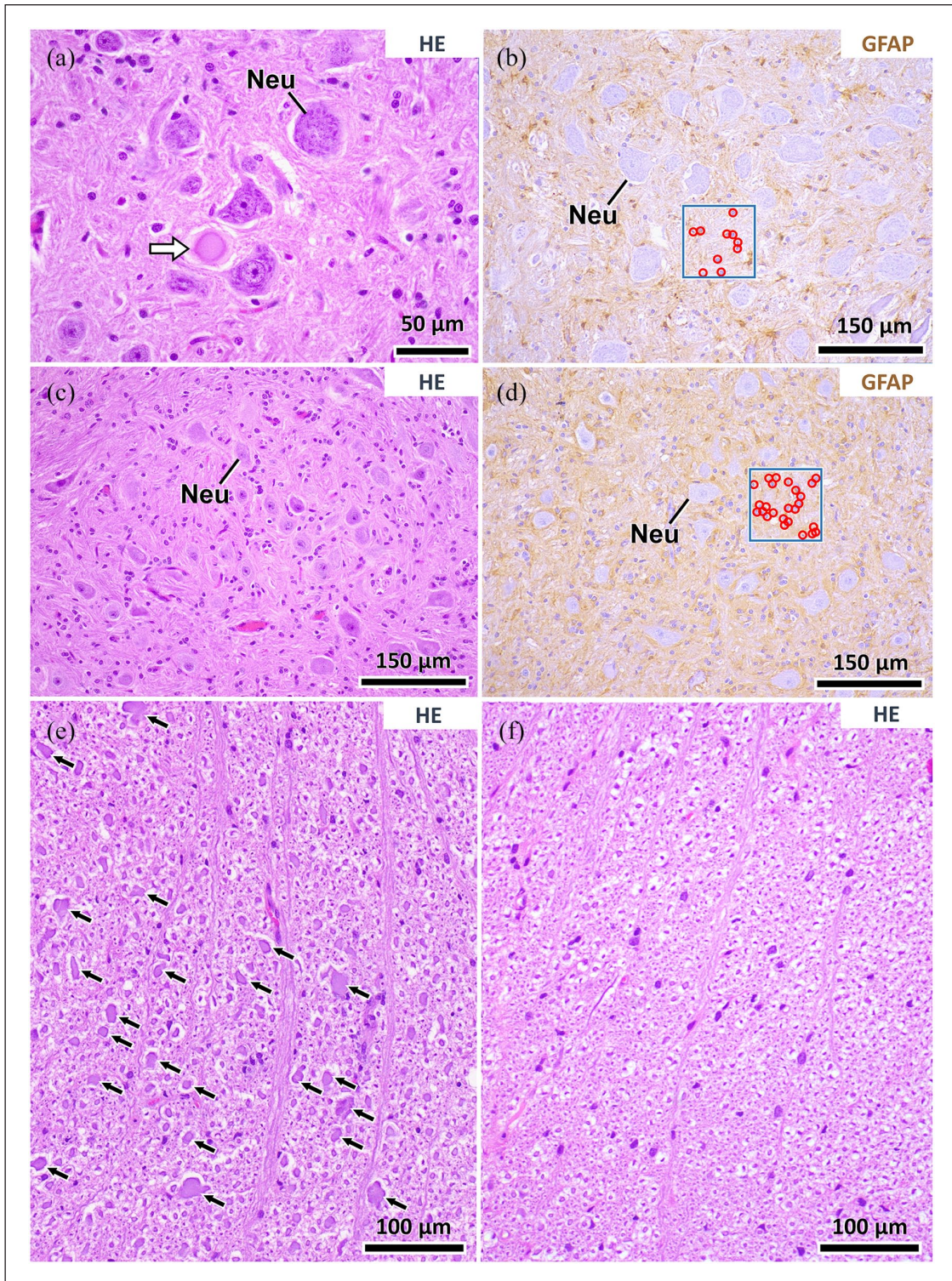


Figure 4 Histopathological changes in brainstem nuclei and spinal cord. (a,b) There are occasional degenerative neuronal changes (a, white arrow) encountered in cranial nerve nuclei as the facial motor nucleus, without a concurrent astroglial reaction (b, brown signal). (c,d) The pre-cerebellar olivary nuclei show wide spacing of neurons (Neu) and present with a comparatively high neuroglial nuclear density (glial cells are implicated in neurodegeneration, see frame in [d] as compared with relatively spared in [b]) and diffuse immunopositivity for glial fibrillary acidic protein (GFAP; d, brown signal). (e) Numerous axonal spheroids (black arrows) are seen in certain spinal tracts as, in particular, the spinocerebellar tract shown here. Compare the axonal diameters to that of a control (f). Stains: (a,c,e,f) haematoxylin and eosin; (b,d) GFAP immunohistochemistry with chromogen: 3,3'-diaminobenzidine (brown)

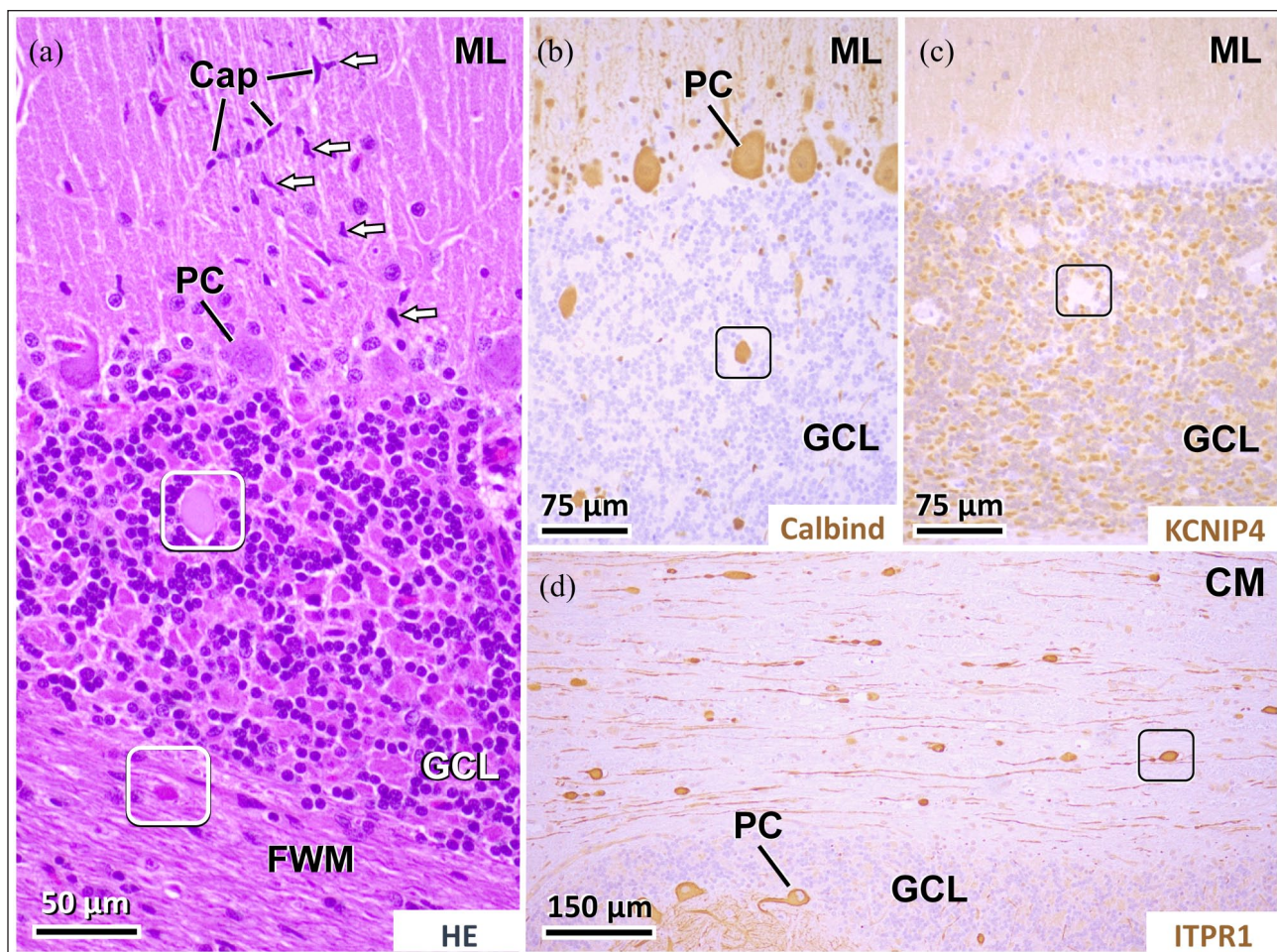


Figure 5 Details on molecular layer changes and axonal pathology. (a) Microgliosis (white arrows) of the molecular layer (ML) extends radially along degenerating Purkinje cell (PC) dendrites and regional capillaries (Cap). (a–d) The granule cell layer (GCL) and underlying white matter contains numerous axonal spheroids (white [a] and black [b–d] frames) that stain immunopositive for PC markers (b) calbindin and (d) ITPR-1, and negative for the synaptic (c) glomerula marker KCNIP4. Stains: (a) haematoxylin-eosin; (b) calbindin immunohistochemistry (Calbind) with chromogen: 3,3'-diaminobenzidine (DAB; brown); (c) KCNIP4 immunohistochemistry with chromogen DAB (brown); (d) ITPR1 immunohistochemistry with chromogen DAB (brown). CM = corpus medullare; FWM = foliary white matter; ML = molecular layer

This cat's neurological presentation reflected both a dysregulation with the olivopontocerebellar feedback circuit, as well as PC dysfunction. This presentation is in contrast to disorders exclusively affecting the granule cell layer with minimal involvement of other structures, namely parvovirus-induced cerebellar hypoplasia.²¹ Typically, affected kittens present with a non-progressive, symmetric cerebellar ataxia that is usually noticed when the kitten attempts to stand or walk.¹⁸

Although there was degeneration found in the facial nuclei (Figure 4a,b), there was no deficit to the palpebral reflex on examination. Should the cat have survived longer, this may have become apparent. The involvement of the facial nucleus could be explained by retrograde degeneration.¹² Anatomically, the olivary nucleus extends rostrally to the caudal aspect of the facial nucleus.

Both cats were observed to fall frequently, with increased limb and tail extensor tone. Hypertonus is a

classic feature of spinocerebellar ataxia, consistent with the Wallerian-like degeneration within the spinocerebellar tracts.⁸ The spinocerebellar tracts convey general proprioceptive information from the trunk and pelvic limbs to the cerebellum.¹² This may suggest why there were postural reaction deficits observed in the pelvic limbs and not the thoracic limbs.

Biochemistry

The accumulation of organic acids within cells exhibit toxic effect by a numerous mechanisms: inhibition of specific enzymes involved in energy metabolism within the brain; impaired coupling between astrocytes and neurons; stimulation of excitotoxic pathways; stimulation of reactive oxygen species; and interference in autoregulation and cerebral blood flow.²² The nervous system is particularly sensitive to the effects of toxic metabolite accumulation. The blood–brain barrier is

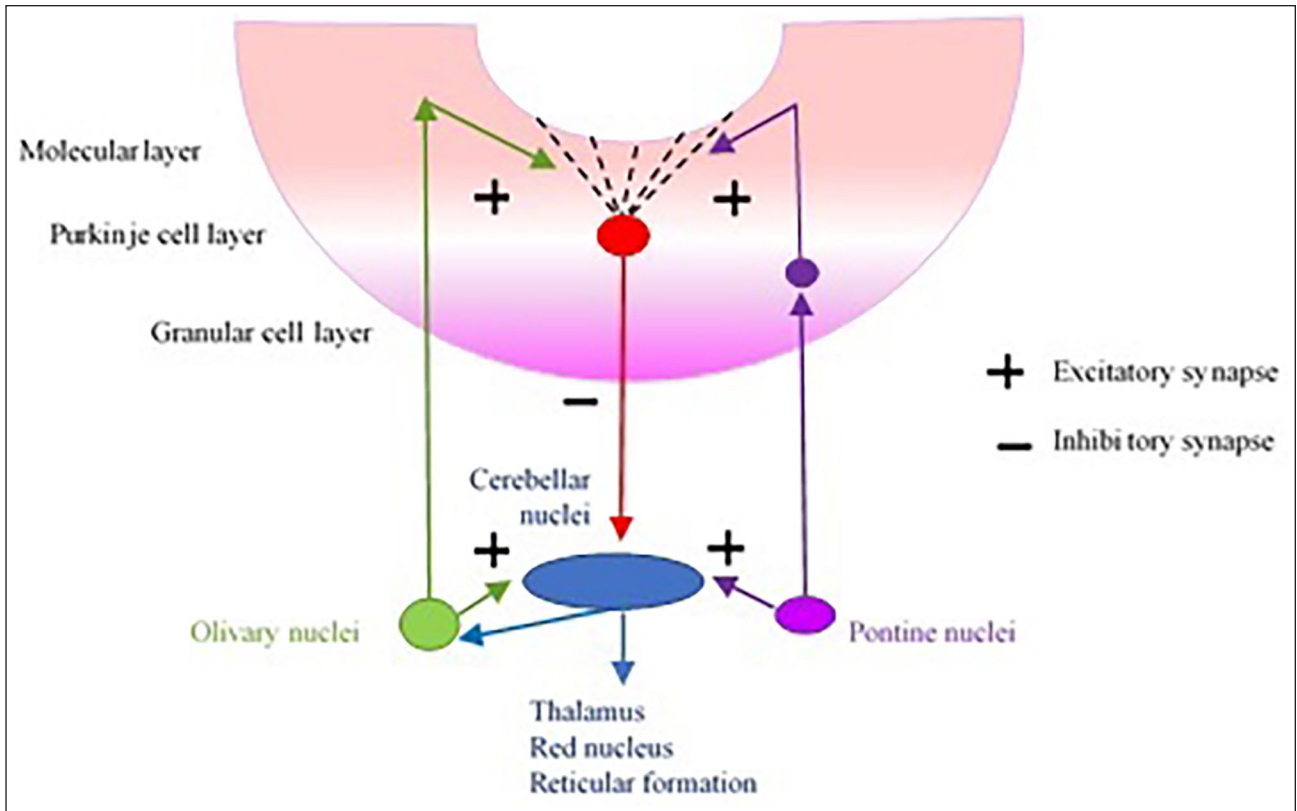


Figure 6 Neuronal pathway of the cerebellar cortex with regards to the olivary and pontine nuclei

ineffective at facilitating with metabolite efflux transport and therefore has been hypothesised to contribute to the accumulation of toxic metabolites in the central nervous system.²² Neurons are incapable of undergoing mitosis and therefore have difficulty eliminating unwanted or undamaged organelles.²³ Histological stain and specific immunolabelling revealed a reduction in PC-specific proteins, including calbindin and ITPR1. When taken together this is reflective of PC loss (Figure 5). ITPR1 is a ligand-gated calcium channel that has a role in intracellular calcium signalling and coincidence detection; it is particularly expressed on cerebellar PCs.²⁴ Interestingly, heterogenous deletions or missense mutations in *ITPR1* have previously been implicated in spinocerebellar ataxia in humans and dogs.^{21,25} It was suggested that the accumulation of toxic metabolites (3-hydroxy-3-methylglutarate) can activate energy-demanding glutamatergic signalling pathways, resulting in an over-excitation of impaired postsynaptic neurons.²² This specifically disrupts ITPR1 signalling and it is thought that this leads to a marked selectivity for the cerebellum and spinocerebellar tract.²⁵ This represents an interesting avenue for future research into the mechanisms described in these findings.

The neurodegenerative phenotype in the cat described, predominantly involving the cerebellum and its feedback nuclei, bears the most pathological resemblance to the fatal neonatal condition L-2-hydroxyglutaric

aciduria described by Chen et al.²⁶ Similarities included neuronal dropout with gliosis in the pontine and inferior olivary nuclei, as well as focal PC dropout in the cerebellum.²⁶ In contrast to L-2-hydroxyglutaric aciduria, no forebrain lesions were found in this cat.

Organic acid urinalysis for the female cats found elevations in 3-hydroxy-3-methylglutaric acid, isovalerylglycine and octanoic acid. Octanoic was very slightly elevated, and therefore likely irrelevant. The former is a result of the catabolism of the amino acid leucine (Figure 7). To confirm the reliability of the results found, analysis of a second urine sample would be preferred. Unfortunately, this was not possible owing to the cat's clinical deterioration and subsequent euthanasia before the results of organic acid urinalysis were determined.

Isovaleryl-CoA dehydrogenase catalyses the third step in leucine catabolism, the oxidation of isovaleryl-CoA to 3-methylcrotonyl-CoA.²⁷ Moreover, isovalerylglycine is an intermediate precursor of 3-hydroxy-3-methylglutaric acid and elevations of isovalerylglycine are secondary to the final step in the pathway (Figure 7). The elevations in 3-hydroxy-3-methylglutaric aciduria are therefore clinically significant.

Leucine is a branched-chain amino acid and ultimately it renders acetyl-CoA and acetoacetate, having undergone catabolism. These primary metabolic endpoints are produced by the final step of leucine degradation whereby HL catalyses the irreversible conversion of

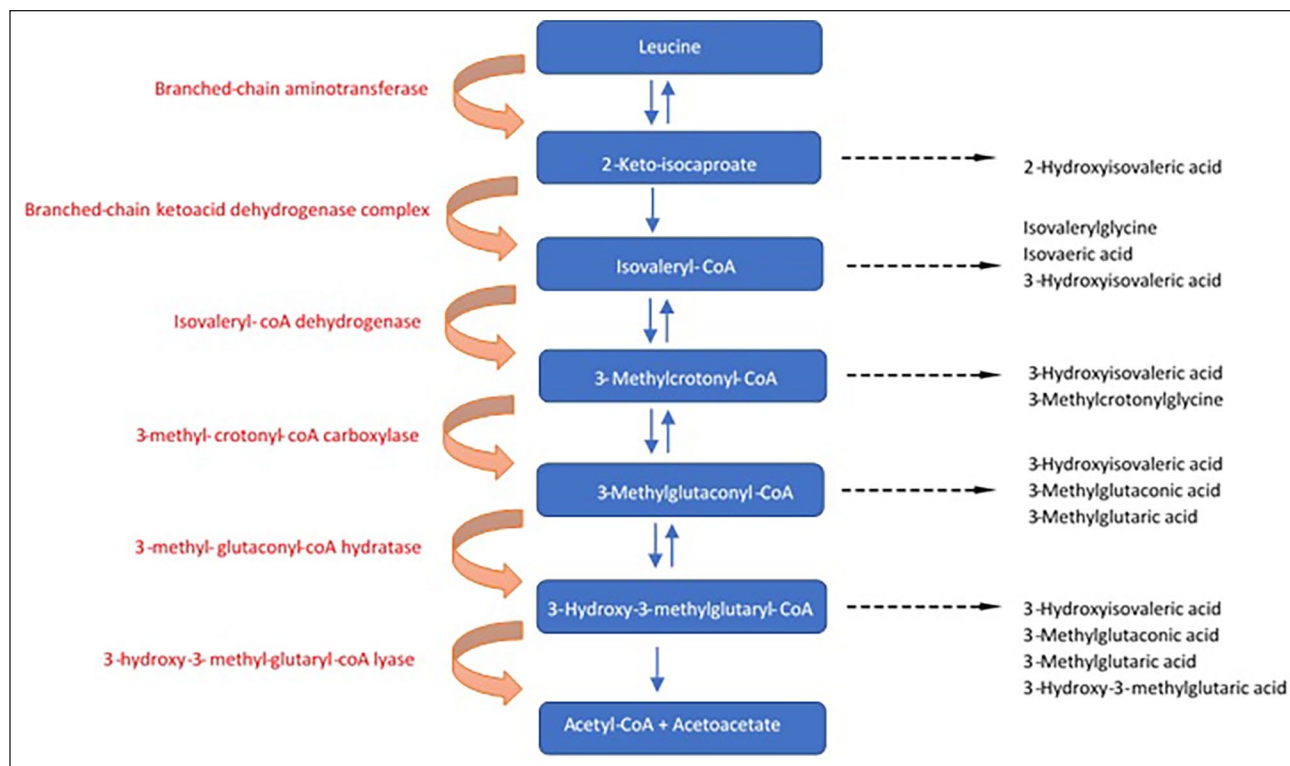


Figure 7 Leucine degradation pathway. Adapted from: Adeva-Andany MM, Lopez-Maside L, Donapetry-Garcia C, et al. Enzymes involved in branched-chain amino acid metabolism in humans. *Amino Acids* 2017; 49; 1005–1028 (with permission of Springer)²⁷

3-hydroxy-3-methylglutaryl-CoA to acetyl and acetoacetate (Figure 5).^{1,4,27} Acetyl and acetoacetate are the precursors for ketone body synthesis; in humans there are only two amino acids degradation to these final metabolites, namely leucine and lysine.²⁸

Human studies of 3-hydroxy-3-methylglutaric aciduria

Human studies have reported that the liver and the pancreas are the organs with the highest HL activity, thus rendering these organs most susceptible to the effects of an HL deficiency, which is evident by the most common clinical presentation (vomiting, dehydration and lethargy with an associated metabolic acidosis and hypoketotic hypoglycaemia).²⁹ Studies investigating HL activity in the rat brain found that HL activity was high in the postnatal period, correlating with cholesterol synthesis. Thereafter, the enzymatic activity continued to decline to minimal levels in the adult brain.^{30,31} This provides an explanation as to why most patients typically present in the neonatal period.²

In contrast to humans, these cats did not show signs consistent with a metabolic acidosis. As cats are carnivores with a much higher protein content to their diet than omnivorous species such as the human and dog,

their metabolism has adapted so that the hepatic transaminases and amino acid degenerative enzymes do not change with the levels of dietary protein. The high-protein diet results in a high rate of nitrogen metabolism providing the mechanism by which kittens are less sensitive to branched chained amino acids; dietary changes to leucine do not significantly influence leucine plasma concentrations.^{32,33} This is in contrast to humans, whereby dietary leucine was reduced by 20g/kg to 5g/kg, resulting in an over three-fold increase in branched-chain amino acid concentrations.^{33,34}

Conclusions

This is the first report of 3-hydroxy-3-methylglutaric aciduria in the veterinary literature. The two cats from the same litter presented at 3–6 months of age with progressive spinocerebellar signs and weakness. The female cat developed cerebellar signs in the late stage of the disease and urinalysis revealed significant elevations in 3-hydroxy-3-methylglutaric acid. The cat was euthanased owing to deterioration. Histopathological examination of this cat revealed marked olivopontocerebellar degeneration. This case report highlights an organic aciduria as an important differential in a young cat presenting with progressive neurological signs. A diagnosis can

be made at relatively low cost from urinalysis alone; however, the lengthy wait for results can be frustrating, especially if a patient is deteriorating. There is no specific treatment for 3-hydroxy-3-methylglutaric aciduria and the prognosis is grave.

Conflict of interest The authors declared no potential conflicts of interest with respect to the research, authorship, and/or publication of this article.

Funding The authors received no financial support for the research, authorship, and/or publication of this article.

Ethical approval This work involved the use of non-experimental animals only (including owned or unowned animals and data from prospective or retrospective studies). Established internationally recognised high standards ('best practice') of individual veterinary clinical patient care were followed. Ethical approval from a committee was therefore not necessarily required.

Informed consent Informed consent (either verbal or written) was obtained from the owner or legal custodian of all animal(s) described in this work for the procedure(s) undertaken. No animals or humans are identifiable within this publication, and therefore additional informed consent for publication was not required.

ORCID ID Natalie West  <https://orcid.org/0000-0003-4215-4094>
Clare Rusbridge  <https://orcid.org/0000-0002-3366-2110>

References

- Faull KF, Bolton PD, Halpern B, et al. **The urinary organic acid profile associated with 3-hydroxy-3-methylglutaric aciduria.** *Clin Chim Acta* 1976; 73: 553–559.
- Grünert SC and Sass JO. **3-Hydroxy-3-methylglutaryl-coenzyme A lyase deficiency: one disease – many faces.** *Orphanet J Rare Dis* 2020; 15: 48.
- Ozand PT, Devol EB and Gascon GG. **Neurometabolic diseases at a national referral center: five years experience at the King Faisal Specialist Hospital and Research Centre.** *J Child Neurol* 1992; 7: S4–S11.
- Reimão S, Morgado C, Almeida IT, et al. **3-Hydroxy-3-methylglutaryl-coenzyme A lyase deficiency: initial presentation in a young adult.** *J Inherit Metab Dis* 2009; 32
- Sass JO, Fukao T and Mitchell GA. **Inborn errors of ketone body metabolism and transport.** *J Inborn Errors Metab Screen* 2018; 6. DOI: 10.1036/ommbid.130.
- Grünert SC, Schlatter SM, Schmitt RN, et al. **3-Hydroxy-3-methylglutaryl-coenzyme A lyase deficiency: clinical presentation and outcome in a series of 37 patients.** *Mol Genet Metab* 2017; 121: 206–215.
- Armstrong DM and Harvey RJ. **Responses in the inferior olive to stimulation of the cerebellar and cerebral cortices in the cat.** *J Physiol* 1966; 187: 553–574.
- King SA. **King's applied anatomy of the central nervous system of domestic mammals.** Vol 1. 3rd ed. St Louis, MO: Elsevier, 1987.
- Thomson C and Hahn C. **Veterinary neuroanatomy: a clinical approach.** St Louis, MO: Elsevier, 2012.
- Montarolo PG, Palestini M and Strata P. **The inhibitory effect of the olivocerebellar input on the cerebellar Purkinje cells in the rat.** *J Physiol* 1982; 332: 187–202.
- Horn KM, Deep A and Gibson AR. **Progressive limb ataxia following inferior olive lesions.** *J Physiol* 2013; 591: 5475–5489.
- De Lahunta A and Glass E. **Veterinary neuroanatomy and clinical neurology.** 3rd ed. St Louis, MO: Saunders Elsevier, 2009.
- Uemura EE. **Fundamentals of canine neuroanatomy and neurophysiology.** Chichester: John Wiley & Sons, 2015.
- Tanaka M. **The dendritic differentiation of Purkinje neurons: unsolved mystery in formation of unique dendrites.** *Cerebellum* 2015; 14: 227–230.
- Morton SM and Bastian AJ. **Mechanisms of cerebellar gait ataxia.** *Cerebellum* 2007; 6: 79–86.
- Horak FB and Diener HC. **Cerebellar control of postural scaling and central set in stance.** *J Neurophysiol* 1994; 72: 479–493.
- Timmann D and Horak FB. **Perturbed step initiation in cerebellar subjects: 2 Modification of anticipatory postural adjustments.** *Exp Brain Res* 2001; 141: 110–120.
- Dewey CW and da Costa RC. **Practical guide to canine and feline neurology.** 3rd ed. Chichester: John Wiley & Sons, 2015.
- Shilla HA, Adler CH and Beach TG. **Pathology in essential tremor.** *Park Relat Disord* 2012; 18 Supp 1: S135–S137.
- Puschmann A and Wszolek ZK. **Diagnosis and treatment of common forms of tremor.** *Semin Neurol* 2011; 31: 65–77.
- Oster-Granite ML and Herndon RM. **The pathogenesis of parvovirus-induced cerebellar hypoplasia in the syrian hamster, *Mesocricetus auratus*.** Fluorescent antibody, foliation, cytoarchitectonic, golgi and electron microscopic studies. *J Comp Neurol* 1976; 169: 481–521.
- Kölker S, Burgard P, Sauer SW, et al. **Current concepts in organic acidurias: understanding intra- and extracerebral disease manifestation.** *J Inherit Metab Dis* 2013; 36: 635–644.
- Yang Y, Coleman M, Zhang L, et al. **Autophagy in axonal and dendritic degeneration.** *Trends Neurosci* 2013; 36: 418–428.
- Jarius S, Scharf M, Begemann N, et al. **Antibodies to the inositol 1,4,5-trisphosphate receptor type 1 (ITPR1) in cerebellar ataxia.** *J Neuroinflammation* 2014; 11: 206. DOI: 10.1186/s12974-014-0206-3.
- Schorge S, van de Leemput J, Singleton A, et al. **Human ataxias: a genetic dissection of inositol triphosphate receptor (ITPR1)-dependent signaling.** *Trends Neurosci* 2010; 33: 211–219.
- Chen E, Nyhan WL, Jakobs C, et al. **L-2-Hydroxyglutaric aciduria: neuropathological correlations and first report**

- of severe neurodegenerative disease and neonatal death.** *J Inherit Metab Dis* 1996; 19: 335–343.
- 27 Adeva-Andany MM, López-Maside L, Donapetry-García C, et al. **Enzymes involved in branched-chain amino acid metabolism in humans.** *Amino Acids* 2017; 49: 1005–1028.
- 28 Newsholme P, Stenson L, Sulvucci M, et al. **Amino acid metabolism.** *Compr Biotechnol* 2011; 1: 3–14.
- 29 Puisac B, Arnedo M, Casale CH, et al. **Differential HMG-CoA lyase expression in human tissues provides clues about 3-hydroxy-3-methylglutaric aciduria.** *J Inherit Metab Dis* 2010; 33: 405–410.
- 30 Shah SN. **Cytosolic 3-hydroxy-3-methyl glutaryl coenzyme a synthase in rat brain: properties and developmental change.** *Neurochem Res* 1982; 7: 1359–1366.
- 31 McGarry JD and Foster DW. **Ketogenesis and cholesterol synthesis in normal and neoplastic tissues of the rat.** *J Biol Chem* 1969; 244: 4251–4256.
- 32 Hargrove DM, Rogers QR and Morris JG. **Leucine and isoleucine requirements of the kitten.** *Br J Nutr* 1984; 52: 595–605.
- 33 Hargrove DM, Rogers QR, Calvert CC, et al. **Effects of dietary excesses of the branched-chain amino acids on growth, food intake and plasma amino acid concentrations of kittens.** *J Nutr* 1988; 118: 311–320.
- 34 Syndermann S, Holt L, Norton PM, et al. **Effect of high and low intakes of individual amino acids on the plasma aminogram.** In: Syndermann S, Holt L, Norton PM, et al. (eds). Protein nutrition and free amino acid patterns. New Brunswick, NJ: Rutgers University Press, 1968, pp 19–31.