



## **Skeletal radiographic manifestations of GM2 gangliosidosis variant 0 (Sandhoff disease) in two Japanese domestic cats**

Authors: Yu, Yoshihiko, Hasegawa, Daisuke, Hamamoto, Yuji, Mizoguchi, Shunta, Fujimori, Toshiki, et al.

Source: Journal of Feline Medicine and Surgery Open Reports, 8(1)

Published By: SAGE Publishing

URL: <https://doi.org/10.1177/20551169221074964>

---


BioOne Complete ([complete.BioOne.org](https://complete.BioOne.org)) is a full-text database of 200 subscribed and open-access titles in the biological, ecological, and environmental sciences published by nonprofit societies, associations, museums, institutions, and presses.

Your use of this PDF, the BioOne Complete website, and all posted and associated content indicates your acceptance of BioOne's Terms of Use, available at [www.bioone.org/terms-of-use](https://www.bioone.org/terms-of-use).

Usage of BioOne Complete content is strictly limited to personal, educational, and non - commercial use. Commercial inquiries or rights and permissions requests should be directed to the individual publisher as copyright holder.

---

BioOne sees sustainable scholarly publishing as an inherently collaborative enterprise connecting authors, nonprofit publishers, academic institutions, research libraries, and research funders in the common goal of maximizing access to critical research.



# Skeletal radiographic manifestations of GM2 gangliosidosis variant 0 (Sandhoff disease) in two Japanese domestic cats

*Journal of Feline Medicine and Surgery Open Reports*  
1–7

© The Author(s) 2022

Article reuse guidelines:

sagepub.com/journals-permissions

DOI: 10.1177/20551169221074964

journals.sagepub.com/home/jfmsopenreports

This paper was handled and processed by the European Editorial Office (ISFM) for publication in *JFMS Open Reports*



Yoshihiko Yu<sup>1</sup>, Daisuke Hasegawa<sup>1,2</sup> ,  
Yuji Hamamoto<sup>1,3</sup>, Shunta Mizoguchi<sup>1,4</sup>,  
Toshiki Fujimori<sup>5</sup>, Yoshiaki Kubo<sup>3</sup>,  
Md Shafiqul Islam<sup>6</sup> and Osamu Yamato<sup>6</sup>

## Abstract

**Case series summary** Two Japanese domestic cats with GM2 gangliosidosis variant 0, diagnosed at different times, are included in this case series. Both cats were diagnosed by genetic analysis and had the *HEXB:c.667C>T* pathogenic genetic variant, which have been previously reported in Japanese domestic cats with GM2 gangliosidosis variant 0. Clinical signs and the identification of vacuolation in circulating lymphocytes were consistent with those in previous reports of feline GM2 gangliosidosis variant 0. Radiography showed that both cases had similar skeletal radiographic manifestations, which has not been previously reported in Japanese domestic cats with GM2 gangliosidosis variant 0. Radiographic findings included abnormally shaped vertebral bodies, obscure or irregular endplates (both of which were seen especially in the cervical and thoracic vertebrae), generalised osteopenia and new bone proliferation around articular facets.

**Relevance and novel information** To the best of our knowledge, this is the first report to present the skeletal radiographic abnormalities of Japanese domestic cats with GM2 gangliosidosis variant 0 caused by the *HEXB:c.667C>T* pathogenic genetic variant. Furthermore, together with a report published in 2015 on the radiographic findings of feline GM2 gangliosidosis variant 0 caused by another pathogenic genetic variant, this report suggests that these findings may be indicators of feline GM2 gangliosidosis variant 0. The easily obtained radiographic findings described in this report may be useful as a finding suggestive of feline GM2 gangliosidosis variant 0, in addition to the cytological finding of the vacuolated cells. The report emphasises the utility of radiography for diagnosis of cases with suspected progressive neurodegenerative diseases.

**Keywords:** Lysosomal storage disease; *HEXB*;  $\beta$ -hexosaminidase; rare disease; veterinary radiology

**Accepted:** 4 January 2022

<sup>1</sup>Laboratory of Veterinary Radiology, Nippon Veterinary and Life Science University, Musashino, Tokyo, Japan

<sup>2</sup>The Research Center for Animal Life Science, Nippon Veterinary and Life Science University, Musashino, Tokyo, Japan

<sup>3</sup>Veterinary Medical Teaching Hospital, Nippon Veterinary and Life Science University, Musashino, Tokyo, Japan

<sup>4</sup>Warabee Animal Hospital, Warabi, Saitama, Japan

<sup>5</sup>Ishikawa Animal Hospital, Matsumoto, Nagano, Japan

<sup>6</sup>Laboratory of Clinical Pathology, Joint Faculty of Veterinary Medicine, Kagoshima University, Korimoto, Kagoshima, Japan

### Corresponding author:

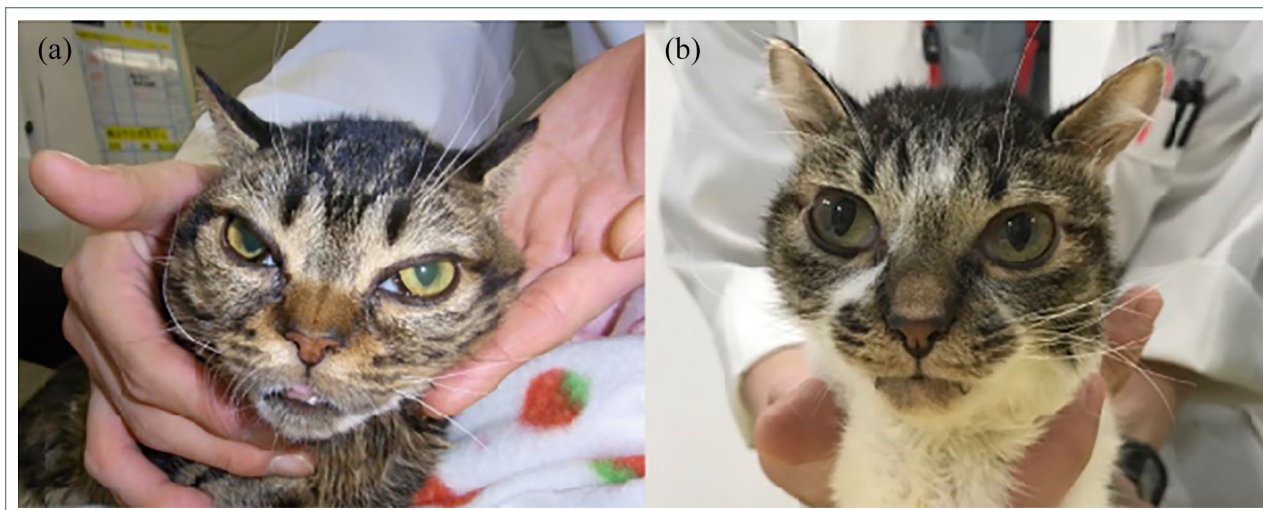
Daisuke Hasegawa DVM, PhD, DAiCVIM (Neurology), Laboratory of Veterinary Radiology, Nippon Veterinary and Life Science University, 1-7-1 Kyounan-cho, Musashino, Tokyo 180-8602, Japan

Email: disk-hsgw@nvlu.ac.jp



Creative Commons Non Commercial CC BY-NC: This article is distributed under the terms of the Creative Commons

Attribution-NonCommercial 4.0 License (<https://creativecommons.org/licenses/by-nc/4.0/>) which permits non-commercial use, reproduction and distribution of the work without further permission provided the original work is attributed as specified on the SAGE and Open Access pages (<https://us.sagepub.com/en-us/nam/open-access-at-sage>).



**Figure 1** Appearance of (a) case 1 and (b) case 2. Abnormal facial appearance can be seen. Both cases showed third eyelid protrusion in both eyes. The cornea of case 1 appears to be opaque (a)

### Case series description

Two consecutive cases were presented to the Veterinary Medical Teaching Hospital (VMTH) of Nippon Veterinary and Life Science University (NVLU; Tokyo, Japan); both were diagnosed with GM2 gangliosidosis variant 0 (Sandhoff disease), with genetic confirmation in 2013 and 2017, respectively.

In both cases, after the diagnostic work-up, progressive neurodegenerative disease such as lysosomal storage disease (LSD) was suspected. After the suspected diagnosis, blood samples were collected for genetic analysis. Genotyping of *HEXB:c.667C>T* variant, which was reported as the causal variant of GM2 gangliosidosis variant 0 in Japanese domestic cats,<sup>1</sup> was performed as previously described.<sup>2</sup> Both cases were lost to follow-up, so further information was unavailable.

#### Case 1

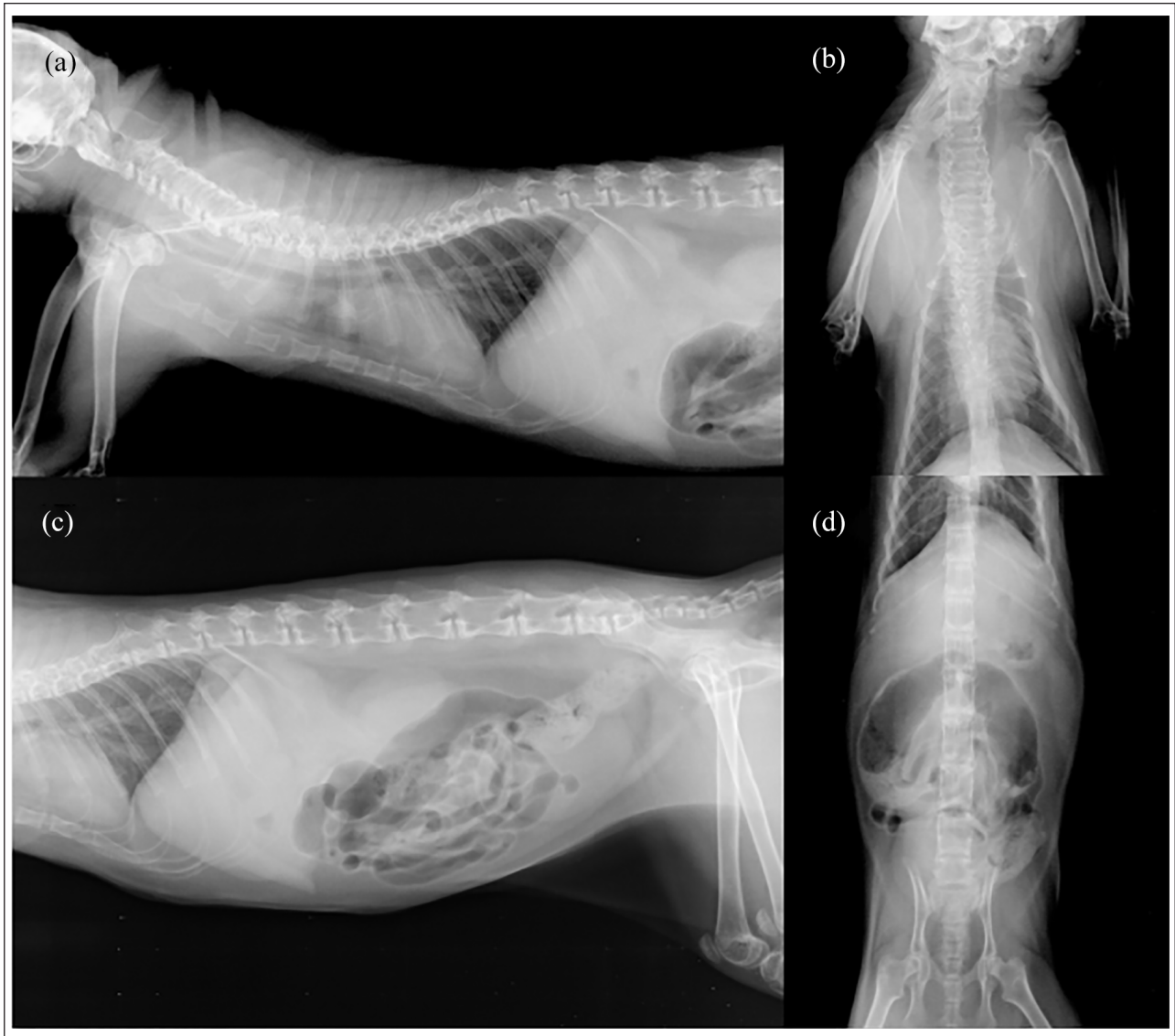
Case 1 was a stray intact female Japanese domestic kitten that was rescued (along with its five littermates) by its owner at an estimated age of 2 weeks. After about 2 months, the kitten was noted to have ataxia and intention tremor by the primary veterinarian, although other kittens in the same litter did not show any abnormalities. One hundred and fifty-five days after the owner had taken the cat to the primary veterinarian, the cat was presented to the General Practice Service at the VMTH of NVLU due to the progression of the clinical signs. It weighed 2.1 kg. Complete blood count (CBC) was unremarkable; however, examination of a blood smear revealed cytoplasmic vacuoles in lymphocytes (see Figure S1 in the supplementary material). Serum chemistry revealed non-specific findings; details of the serum chemistry data are provided in Table S1

in the supplementary material. Because the cat was suspected of having a neurological disease, consultation at the Neurology and Neurosurgery Service in the VMTH of NVLU was requested.

Neurological examination revealed abnormal mental status and non-ambulatory paraparesis. Postural reactions were absent in all four limbs. Spinal reflexes were increased or exaggerated in all four limbs. Crossed extensor reflexes were observed in both hindlimbs. Babinski reflex was present in all limbs except for the left forelimb. Palpebral reflex at lateral canthus of both eyes was absent. The patient showed slow horizontal pendular nystagmus when it was in a normal position, and vertical pendular nystagmus when its position changed. Third eyelid protrusion occurred in both eyes (Figure 1a).

Skeletal survey radiography revealed abnormalities (more obviously in the cervical and upper thoracic vertebrae) (Figure 2). Vertebral bodies were abnormally shaped, and there was generalised osteopenia in the entire spine. On the lateral view of the cervical vertebrae, the craniocaudal dimensions of the vertebrae were shortened, while the dorsoventral dimensions were widened. Furthermore, in the dorsoventral view of the cervical vertebral column, their lateral dimensions were widened. The dorsal spinous processes of the thoracic vertebrae were abnormally shaped and their craniocaudal dimensions were wider. In the dorsoventral view, the lateral dimensions of lumbar vertebral bodies were mildly widened. In the cervical and thoracic vertebrae, especially, endplates were obscure or irregular. Bone proliferation was also seen around articular facets, especially in the lumbar vertebrae.

MRI was performed without general anaesthesia/sedation using a 3.0 Tesla unit (Signa HDxt 3.0 T; GE



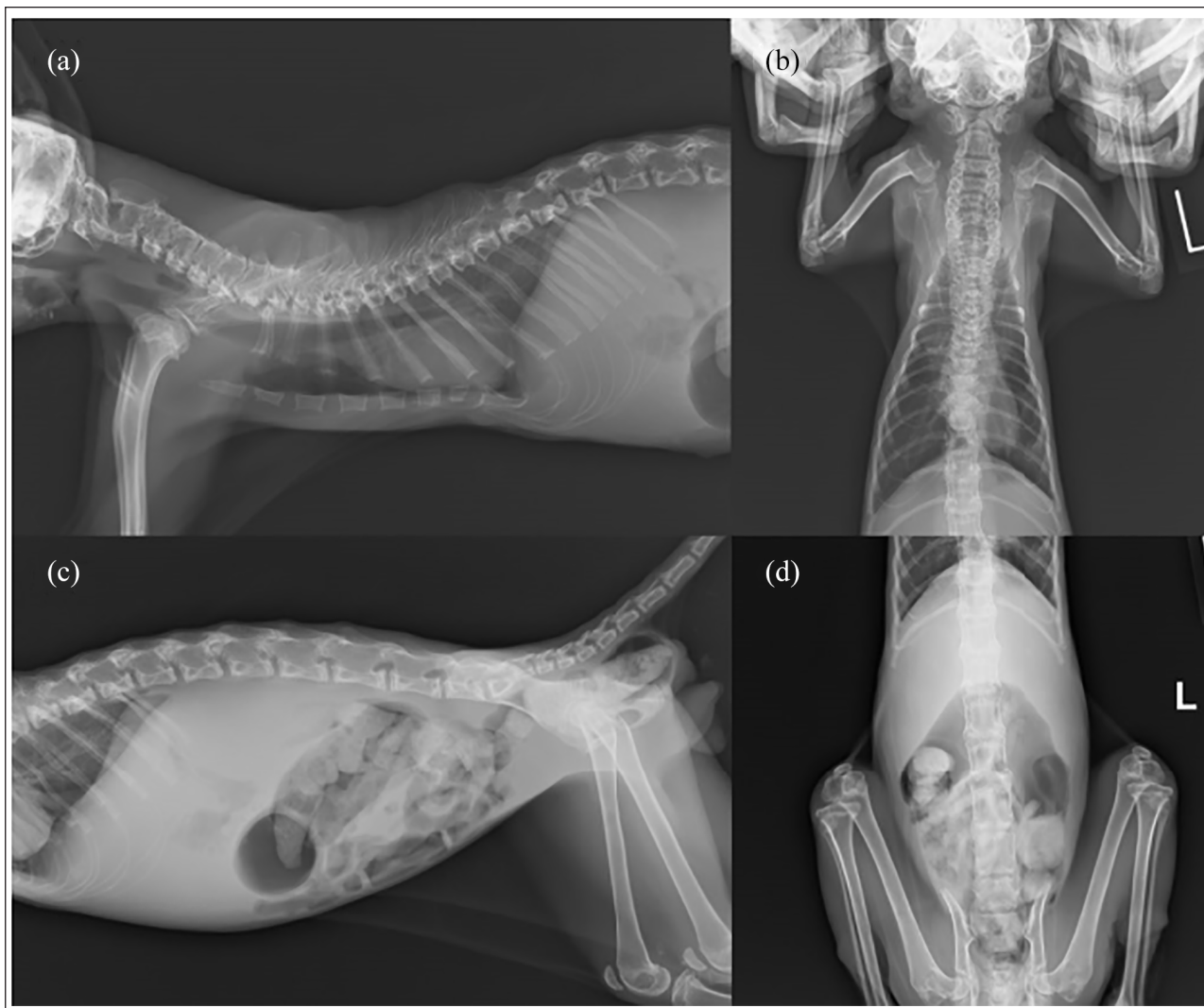
**Figure 2** Radiographs of case 1: (a) right lateral cervicothoracic radiograph; (b) dorsoventral cervicothoracic radiograph; (c) right lateral abdominal radiograph; and (d) dorsoventral abdominal radiograph

Healthcare), and sagittal and transverse T2-weighted (T2W) images and transverse periodically rotated overlapping parallel lines with enhanced reconstruction (PROPELLER) T2W images of the brain were obtained. General anesthesia or sedation were avoided because of the potentially increased risk of complications in this cat with deteriorating condition. Instead, a veterinarian accompanied the cat on the MRI bed and held the cat in place to minimise its body movements. In the sagittal plane of T2W imaging, the corpus callosum was hardly recognisable, which has previously been reported to be an imaging indicator for suspicion of LSD,<sup>3</sup> even though MRI was obtained without general anesthesia/sedation and motion artefact was present (see Figure S2 in the supplementary material). Furthermore, ventral vertebral

bodies of C2–C6 seen in the sagittal T2W MRI showed T2 hyperintensity, and T2 signal intensity was higher than its adjacent intervertebral discs. In the transverse plane, brain T2W imaging showed white matter signal hyperintensity and ventricular enlargement, which was consistent with the MRI findings previously reported in Korat<sup>4</sup> and Japanese domestic cats.<sup>5</sup> Furthermore, the muzzle of this cat appeared to be shorter than that of a normal cat.

### Case 2

Case 2 was a stray intact male Japanese domestic kitten that had been rescued by its owner. The day after the owner started taking care of the kitten, it was presented at the primary veterinary hospital. The age of this kitten was unknown; however, it was estimated to be about



**Figure 3** Radiographs of case 2: (a) right lateral cervicothoracic radiograph; (b) dorsoventral cervicothoracic radiograph; (c) right lateral abdominal radiograph; and (d) dorsoventral abdominal radiograph

2 months old. At this time, the primary veterinarian found that the kitten had a head tremor and visual weakness, and was ambulatory. A month and a half later, the patient gradually became non-ambulatory; radiography was therefore performed at the primary veterinary hospital, which revealed abnormalities in the vertebral column. Two hundred and forty-three days after its first visit to the primary veterinary hospital, the cat was presented to the General Practice Service in the VMTH of NVLU owing to head and generalised tremor, recumbency, lethargy, anorexia, haematuria and difficulty with defaecation. It was able to urinate on its own when supported. It had mild dehydration and weighed 1.2 kg, and its body temperature was 36.1°C. Feline immunodeficiency virus antibody and feline leukaemia virus antigen were not detected by screening tests. At the initial presentation, CBC showed neutrophilia and very mild lymphocytopenia. Serum chemistry findings included

increased liver enzymes and decreased albumin (see Table S1 in the supplementary material).

Skeletal survey radiography revealed skeletal abnormalities (Figure 3). Radiographic findings were similar to those seen in case 1; however, pectus excavatum was found in case 2. In the lateral view, the craniocaudal dimensions of dorsal spinous processes of the upper thoracic vertebrae in case 2 were a little wider than in case 1, while those of the lower thoracic vertebrae in case 1 were wider than in case 2. Furthermore, the dorsoventral dimensions of dorsal spinous processes of the upper thoracic vertebrae in case 2 were shorter than in case 1 in the lateral view.

Two weeks later, the cat was re-evaluated at the Neurology and Neurosurgery Service of the VMTH of NVLU. Its weight had decreased to 1.15 kg. CBC and serum chemistry were performed again. At this time, although the CBC results were now within the reference

intervals (RIs), cytoplasmic vacuoles in lymphocytes were seen on a blood smear (see Figure S1 in the supplementary material). Most serum chemistry levels had not drastically changed from the previous test; however, serum amyloid A was remarkably elevated (107.9 µg/ml; RI 0–6.5 µg/ml). The concentration of ammonia in the blood was measured and was unremarkable. Serum chemistry data of case 2 are shown in Table S1 in the supplementary material. Neurological examination revealed abnormal mental status, recumbency, poor-to-absent postural reactions in all limbs, exaggerated spinal reflexes in all four limbs, the presence of crossed extensor reflexes in all limbs, horizontal pendular nystagmus and a bilateral menace response deficit. Pupillary light reflex was present, although the pupil size was slow to return to normal. Palpebral reflex at the lateral canthus of both eyes appeared weak. The third eyelid appeared in both eyes (Figure 1b). Withdrawal reflexes were normal in all four limbs. Muscle atrophy of the extremities was observed. Although MRI was scheduled to be performed, it was cancelled because the cat's body temperature was, at that time, 35.1°C.

## Discussion

GM2 gangliosidosis is a subset of LSD and causes the accumulation of GM2 ganglioside and other glycolipids in lysosomes, which leads to progressive diffuse neurological deterioration. GM2 gangliosidosis is known to be caused by a genetic deficiency of beta (β)-hexosaminidase or GM2 activator protein. GM2 gangliosidosis is further divided into three subtypes, including variant B (Tay-Sachs disease), variant 0 (Sandhoff disease) and variant AB (GM2 activator protein deficiency). Four genetic causal variants in the *HEXB* gene for feline GM2 gangliosidosis variant 0 have been identified so far: an inversion in domestic shorthair cats;<sup>6</sup> a splice site deletion in European Burmese;<sup>7</sup> a single base pair deletion in Korat;<sup>8</sup> and a nonsense mutation in Japanese domestic cats.<sup>1</sup>

Although feline GM2 gangliosidosis variant 0 has been well studied and utilised as a large-animal model of human Sandhoff disease,<sup>9,10</sup> bone abnormalities had not been reported before 2015.<sup>11</sup> Bony abnormalities, referred to as mucopolysaccharidosis (MPS)-like phenotype,<sup>11</sup> have been found in a continuously maintained research colony of feline GM2 gangliosidosis variant 0 model,<sup>12,13</sup> which has a 25 base pair inversion near the end of the *HEXB* coding sequence, *HEXB*:c.1467\_1491inv25 (p.F488Lfs\*4).<sup>6</sup> Prior to the report by Gray-Edwards et al in 2015,<sup>11</sup> a review article on feline and canine LSD stated that bony and connective tissue abnormalities could also be observed in some forms of gangliosidosis or glycoproteinosis,<sup>14</sup> although the subtype of those diseases has not been specified. Both the present and previous reports suggest that these radiographic findings may be indicators in feline GM2 gangliosidosis variant 0.

In this report, two Japanese domestic cats with skeletal radiographic abnormalities presented separately; both cats had the homozygous *HEXB*:c.667C>T pathogenic genetic variant, which was different to that reported by Gray-Edwards et al.<sup>11</sup> Diffuse osteopenia most severely affected the spine in the current cases, as well as in the cats previously reported.<sup>11</sup> Furthermore, previously reported abnormally shaped vertebral bodies (especially in cervical vertebrae) were also commonly seen in the current cases.<sup>11</sup> In the previous research,<sup>11</sup> multiple punctate radiolucent defects in the epiphyses of the humerus, distal radius, femur and tibia were reported. Although radiographs of the appendicular skeleton such as forelimbs and hindlimbs were not obtained independently in both of the current cases, and detailed evaluation was difficult, an increase in radiolucency was seen in the epiphyses of the humerus and femur, especially in case 2. It should also be noted that the ages of the cats in the previous report (around 4.5 months old) and the two cases in the present report (around 1 year old) were different.<sup>11</sup>

Several reports of GM2 gangliosidosis variant 0 in Japanese domestic cats have been published,<sup>5,15,16</sup> however, none has given descriptions of abnormal radiographic skeletal findings, and one case report stated that their cat showed no abnormalities in radiographic examinations of the cranial and cervical regions,<sup>16</sup> and was identified as carrying the *HEXB*:c.667C>T pathogenic genetic variant in a subsequent genetic study.<sup>1</sup> The discrepancy between that report<sup>16</sup> and ours seems to suggest that variable phenotypic expression occurs, even among cases with the same pathogenic genetic variant. Intrafamilial variability has been recognised in LSD in humans.<sup>17,18</sup> Therefore, it may be considered that phenotypic variability exists in Japanese domestic cats with the same pathogenic genetic variant.

The radiological skeletal manifestation seen in two cats reported here may be similar to those of several diseases, including MPS,<sup>19–22</sup> hypervitaminosis A,<sup>23</sup> congenital hypothyroidism<sup>24</sup> and hyperparathyroidism.<sup>25</sup> Multiple epiphyseal dysplasia,<sup>26</sup> which has been reported in dogs but not in cats, may also be considered. Nevertheless, genetic confirmation of the *HEXB*:c.667C>T variant proved that these two cats were affected by GM2 gangliosidosis variant 0.

The presence of cytoplasmic vacuoles within leukocytes is a well-known reliable indicator of some LSDs, which may be identified by evaluation of blood smears.<sup>14,16,27</sup> In addition to the cytological finding of the vacuolated cells, the abnormal findings on skeletal radiographs reported here may help to assist in the diagnosis of neurodegenerative diseases, some of which show abnormal skeletal radiographic phenotypes, such as GM2 gangliosidosis variant 0 and a few types of MPS, in cats.

## Conclusions


This report provides evidence of skeletal radiographic abnormality in two consecutive cases of feline GM2 gangliosidosis variant 0 (Sandhoff disease) with the homozygous *HEXB:c.667C>T* pathogenic genetic variant. This report highlights the utility of survey radiography when proceeding with diagnoses of feline cases with suspected progressive neurodegenerative diseases.

**Conflict of interest** The authors declared no potential conflicts of interest with respect to the research, authorship, and/or publication of this article.

**Funding** The authors received no financial support for the research, authorship, and/or publication of this article.

**Ethical approval** The work described in this manuscript involved the use of non-experimental (owned or unowned) animals. Established internationally recognised high standards ('best practice') of veterinary clinical care for the individual patient were always followed and/or this work involved the use of cadavers. Ethical approval from a committee was therefore not specifically required for publication in *JFMS Open Reports*. Although not required, where ethical approval was still obtained, it is stated in the manuscript.

**Informed consent** Informed consent (verbal or written) was obtained from the owner or legal custodian of all animal(s) described in this work (experimental or non-experimental animals, including cadavers) for all procedure(s) undertaken (prospective or retrospective studies). For any animals or people individually identifiable within this publication, informed consent (verbal or written) for their use in the publication was obtained from the people involved.

**ORCID iDs** Daisuke Hasegawa  <https://orcid.org/0000-0002-7554-9108>

Osamu Yamato  <https://orcid.org/0000-0002-4430-5645>

**Supplementary material** The following files are available online:

Figure S1: Blood smear of case 1 and case 2. Lymphocytic vacuolation was seen in both cases. No obvious abnormalities were found in neutrophils in both cases.

Figure S2: Brain MRI of case 1.

Table S1: Results of serum chemistry analyses of case 1 and case 2.

## References

- Kanae Y, Endoh D, Yamato O, et al. **Nonsense mutation of feline  $\beta$ -hexosaminidase  $\beta$ -subunit (*HEXB*) gene causing Sandhoff disease in a family of Japanese domestic cats.** *Res Vet Sci* 2007; 82: 54–60.
- Rahman MM, Shoubudani T, Mizukami K, et al. **Rapid and simple polymerase chain reaction-based diagnostic assays for GM2 gangliosidosis variant 0 (Sandhoff-like disease) in Japanese domestic cats.** *J Vet Diagn Invest* 2011; 23: 338–342.
- Hasegawa D, Tamura S, Nakamoto Y, et al. **Magnetic resonance findings of the corpus callosum in canine and feline lysosomal storage diseases.** *PLoS ONE* 2013; 8: e83455. DOI: 10.1371/journal.pone.0083455.
- Kroll RA, Pagel MA, Roman-Goldstein S, et al. **White matter changes associated with feline GM2 gangliosidosis (Sandhoff disease): correlation of MR findings with pathologic and ultrastructural abnormalities.** *AJNR Am J Neuroradiol* 1995; 16: 1219–1226.
- Hasegawa D, Yamato O, Kobayashi M, et al. **Clinical and molecular analysis of GM2 gangliosidosis in two apparent littermate kittens of the Japanese domestic cat.** *J Feline Med Surg* 2007; 9: 232–237.
- Martin DR, Krum BK, Varadarajan GS, et al. **An inversion of 25 base pairs causes feline GM2 gangliosidosis variant 0.** *Exp Neurol* 2004; 187: 30–37.
- Bradbury AM, Morrison NE, Hwang M, et al. **Neurodegenerative lysosomal storage disease in European Burmese cats with hexosaminidase  $\beta$ -subunit deficiency.** *Mol Genet Metab* 2009; 97: 53–59.
- Muldoon LL, Neuwelt EA, Pagel MA, et al. **Characterization of the molecular defect in a feline model for type II GM2-gangliosidosis (Sandhoff disease).** *Am J Pathol* 1994; 144: 1109–1118.
- Bradbury AM, Gurda BL, Casal ML, et al. **A review of gene therapy in canine and feline models of lysosomal storage disorders.** *Hum Gene Ther Clin Dev* 2015; 26: 27–37.
- Lawson CA and Martin DR. **Animal models of GM2 gangliosidosis: utility and limitations.** *Appl Clin Genet* 2016; 9: 111–120.
- Gray-Edwards HL, Brunson BL, Holland M, et al. **Mucopolysaccharidosis-like phenotype in feline Sandhoff disease and partial correction after AAV gene therapy.** *Mol Genet Metab* 2015; 116: 80–87.
- Cork LC, Munnell JF, Lorenz MD, et al. **GM2 ganglioside lysosomal storage disease in cats with beta-hexosaminidase deficiency.** *Science* 1977; 196: 1014–1017.
- Cork LC, Munnell JF and Lorenz MD. **The pathology of feline GM2 gangliosidosis.** *Am J Pathol* 1978; 90: 723–734.
- Skelly BJ and Franklin RJM. **Recognition and diagnosis of lysosomal storage diseases in the cat and dog.** *J Vet Intern Med* 2002; 16: 133–141.
- Yamato O, Hayashi D, Satoh H, et al. **Retrospective diagnosis of feline GM2 gangliosidosis variant 0 (Sandhoff-like disease) in Japan: possible spread of the mutant allele in the Japanese domestic cat population.** *J Vet Med Sci* 2008; 70: 813–818.
- Yamato O, Matsunaga S, Takata K, et al. **GM2-gangliosidosis variant 0 (Sandhoff-like disease) in a family of Japanese domestic cats.** *Vet Rec* 2004; 155: 739–744.
- McDowell GA, Cowan TM, Blitzer MG, et al. **Intrafamilial variability in Hurler syndrome and Sanfilippo syndrome type A: implications for evaluation of new therapies.** *Am J Med Genet* 1993; 47: 1092–1095.
- Amaral O, Fortuna AM, Lacerda L, et al. **Molecular characterisation of type 1 Gaucher disease families and patients: intrafamilial heterogeneity at the clinical level.** *J Med Genet* 1994; 31: 401–404.
- Cowell KR, Jezyk PF, Haskins ME, et al. **Mucopolysaccharidosis in a cat.** *J Am Vet Med Assoc* 1976; 169: 334–339.

- 20 Konde LJ, Thrall MA, Gasper P, et al. **Radiographically visualized skeletal changes associated with mucopolysaccharidosis VI in cats.** *Vet Radiol* 1987; 28: 223–228.
- 21 Gitzelmann R, Bosshard NU, Superti-Furga A, et al. **Feline mucopolysaccharidosis VII due to  $\beta$ -glucuronidase deficiency.** *Vet Pathol* 1994; 31: 435–443.
- 22 Schultheiss PC, Gardner SA, Owens JM, et al. **Mucopolysaccharidosis VII in a cat.** *Vet Pathol* 2000; 37: 502–505.
- 23 English PB. **Clinical communication: a case of hyperostosis due to hypervitaminosis A in a cat.** *J Small Anim Pract* 1969; 10: 207–212.
- 24 Crowe A. **Congenital hypothyroidism in a cat.** *Can Vet J* 2004; 45: 168–170.
- 25 Dimopoulou M, Kirpensteijn J, Nielsen DH, et al. **Nutritional secondary hyperparathyroidism in two cats: evaluation of bone mineral density with dual-energy X-ray absorptiometry and computed tomography.** *Vet Comp Orthop Traumatol* 2010; 23: 56–61.
- 26 Rørvik AM, Teige J, Ottesen N, et al. **Clinical, radiographic, and pathologic abnormalities in dogs with multiple epiphyseal dysplasia: 19 cases (1991–2005).** *J Am Vet Med Assoc* 2008; 233: 600–606.
- 27 Alroy J, Freden GO, Goyal V, et al. **Morphology of leukocytes from cats affected with  $\alpha$ -mannosidosis and mucopolysaccharidosis VI (MPS VI).** *Vet Pathol* 1989; 26: 294–302.