



Caval chemodectoma in a cat

Authors: Martinez, Irene, Brockman, Daniel, and Purzycka, Katarzyna

Source: Journal of Feline Medicine and Surgery Open Reports, 8(1)

Published By: SAGE Publishing

URL: <https://doi.org/10.1177/20551169221106990>

BioOne Complete (complete.BioOne.org) is a full-text database of 200 subscribed and open-access titles in the biological, ecological, and environmental sciences published by nonprofit societies, associations, museums, institutions, and presses.

Your use of this PDF, the BioOne Complete website, and all posted and associated content indicates your acceptance of BioOne's Terms of Use, available at www.bioone.org/terms-of-use.

Usage of BioOne Complete content is strictly limited to personal, educational, and non - commercial use. Commercial inquiries or rights and permissions requests should be directed to the individual publisher as copyright holder.

BioOne sees sustainable scholarly publishing as an inherently collaborative enterprise connecting authors, nonprofit publishers, academic institutions, research libraries, and research funders in the common goal of maximizing access to critical research.



Caval chemodectoma in a cat

Irene Martinez¹ , Daniel Brockman²
and Katarzyna Purzycka³

Journal of Feline Medicine and Surgery Open Reports
1–5

© The Author(s) 2022

Article reuse guidelines:

sagepub.com/journals-permissions

DOI: 10.1177/20551169221106990

journals.sagepub.com/home/jfmsopenreports

This paper was handled and processed
by the European Editorial Office (ISFM)
for publication in *JFMS Open Reports*



Abstract

Case summary An 11-year-old male neutered domestic shorthair cat was presented with a 4-week history of an intermittent cough and dyspnoea. A pleural effusion was identified, which was confirmed as chyle. Echocardiography and CT revealed a 16 mm mass cranial to the heart, which was invading the cranial vena cava. Because of the location of the mass, it was assumed that chylothorax had developed as a result of direct disruption of the thoracic duct by the tumour or secondarily to central venous hypertension. An exploratory thoracotomy was performed, and the mass, which originated within the wall of the cranial vena cava, was excised with narrow gross margins. Histopathology and immunohistochemistry were consistent with a chemodectoma with residual tumour cells at the surgical margin. Given the residual microscopic disease, adjuvant treatment with toceranib phosphate was initiated. The cat remained well for the duration of treatment and was euthanased 31 months after diagnosis when CT identified recurrent pleural effusion, a heart base mass with cranial vena cava and azygos vein invasion.

Relevance and novel information Chemodectomas are rare in cats, with only 13 cases reported in the literature to date, and all were located in either the aortic or carotid body. The reported survival with partial resection and/or subtotal pericardiectomy was 13–19 months. Treatment of feline chemodectomas with toceranib phosphate has not been previously reported. To our knowledge, this is the first description of the surgical management of a feline vena cava chemodectoma, combined with adjuvant toceranib phosphate, resulting in a prolonged survival.

Keywords: Chemodectoma; oncology; surgery; vena cava; toceranib phosphate

Accepted: 26 May 2022

Case description

An 11-year-old neutered male domestic shorthair cat presented to the referral emergency service with a 4-week history of an intermittent and progressive cough and dyspnoea. The cat presented to its primary care practice with pleural effusion, which was drained, but 48 h later, the cat redeveloped respiratory signs.

On presentation, apart from tachypnoea (respiratory rate 40 breaths/min, without respiratory effort), other vital parameters were within normal limits. On auscultation, cardiopulmonary sounds were muffled throughout the chest. The cat weighed 5.42 kg with a body condition score of 5/9. The rest of the physical examination was unremarkable.

Emergency thoracocentesis was performed and the examination of the fluid was consistent with modified transudate effusion. The results showed fluid cholesterol (Chol) 2.5 mmol/l, fluid triglycerides (Tg) 0.30 mmol/l,

fluid Chol:Tg rate 8.33 and fluid protein 34.2 g/l. Cytology of the fluid revealed exudate with mixed inflammation (predominantly neutrophilic). Bacterial culture was negative. Haematological and serum biochemistry revealed no significant findings.

Echocardiography was performed, which showed normal cardiac structure. CT of the thorax was performed under general anaesthetic and demonstrated an

¹Hamilton Specialist Referrals, High Wycombe, UK

²Queen Mother Hospital for Animals, The Royal Veterinary College, Hatfield, UK

³Lumbry Park Veterinary Specialists, Alton, UK

Corresponding author:

Irene Martinez MRCVS, Hamilton Specialist Referrals, Cressex Business Park Unit 1& Unit 5, Halifax Road, High Wycombe, Buckinghamshire HP12 3SD, UK
Email: irenegaldames@gmail.com



Creative Commons Non Commercial CC BY-NC: This article is distributed under the terms of the Creative Commons

Attribution-NonCommercial 4.0 License (<https://creativecommons.org/licenses/by-nc/4.0/>) which permits non-commercial use, reproduction and distribution of the work without further permission provided the original work is attributed as specified on the SAGE and Open Access pages (<https://us.sagepub.com/en-us/nam/open-access-at-sage>).

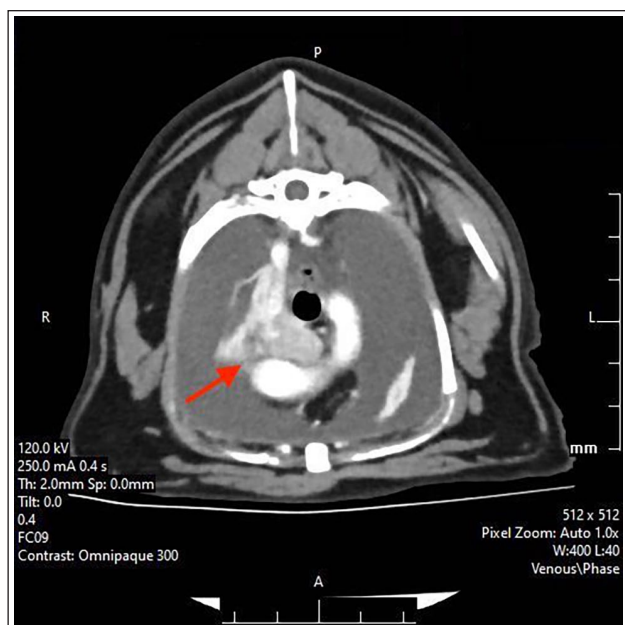


Figure 1 Tranversal thoracic CT showing a heart base mass with vena cava and azygos invasion. The red arrow indicates the mass with contrast

irregular, large ($0.8 \times 1.7 \times 2-7$ cm) contrast-enhancing heart base mass located cranial to the heart, indenting and invading the cranial vena cava (Figure 1). Therefore, an exploratory thoracotomy was pursued as the next diagnostic and therapeutic step.

The cat was premedicated with methadone 0.2 mg/kg intravenously (IV) and had an intercostal block with ropivacaine 1 mg/kg and lidocaine 2 mg/kg. Cefuroxime 20 mg/kg IV was also administered before and during surgery. Anaesthesia was maintained with isoflurane in oxygen, with no intraoperative complications were recorded. A right fourth intercostal thoracotomy was performed. Following a temporary occlusion of the cranial vena cava, a rounded and well-defined mass with irregular margins was identified and excised from the cranial vena cava at the level of the azygous vein (Figure 2). The caval incision was reconstructed with a continuous suture of 7-0 prolene. A pleural port was placed and secured to the caudodorsal thoracic fascia through a separate more caudal incision. Postoperatively, the cat was managed overnight in the intensive care unit, with close monitoring. The cat made a good recovery, with no major or minor complications, and was discharged 5 days postoperatively. The pleural port was removed 14 days postoperatively, with no evidence of residual pleural effusion.

Histopathology of the mass was consistent with an incompletely excised chemodectoma. Subsequently, immunohistochemistry was performed using thyroglobulin antibodies; neoplastic cells did not exhibit thyroglobulin labelling, ruling out an ectopic thyroid

carcinoma. To our knowledge, chemodectoma in the vena cava has not been reported previously.

The cat was re-examined 2 weeks later. Clinical examination was unremarkable, and there was no evidence of pleural effusion. Given residual microscopic disease, adjuvant treatment with toceranib phosphate (Palladia; Zoetis) was initiated (10 mg [1.8 mg/kg] on a Monday–Wednesday–Friday schedule). Complete blood count, serum biochemistry, urinalysis and oscillometric blood pressure monitoring at the referring practice were advised every 4 weeks after starting the treatment. The cat's respiratory rate and effort were monitored at home. Treatment with toceranib phosphate was well tolerated, with no adverse effects reported.

Three months later, a repeat CT showed no evidence of local recurrence and no other lesions were identified. Treatment with toceranib phosphate was discontinued after 1 year as the cat remained well at that time. The cat re-presented with dyspnoea 31 months later and a repeated CT scan identified a recurrent heart base mass with cranial vena cava and azygos vein invasion, and pleural effusion. A humane euthanasia was elected by the client.

Discussion

Based on a literature search, this appears to be the first reported chemodectoma in the cranial vena cava of a cat.¹⁻¹⁰ Surgical excision followed by adjuvant treatment with toceranib phosphate resulted in a prolonged survival of 2.5 years before the tumour recurred. Chemodectomas are tumours of the chemoreceptor tissue, with the largest accumulation of these cells located in the aortic and carotid bodies found in the adventitia of the aortic arch and at the carotid bifurcation, respectively.¹⁻³ Chemoreceptor cells have different functions in the body: they sense changes in the arterial partial pressures of oxygen and carbon dioxide, blood pH and temperature. Stimulation of chemoreceptor cells results in compensatory changes in respiratory rate, blood pressure or both.^{1-3,11} In humans, living at high altitude seems to be a predisposing factor for the development of chemodectoma.^{1,2} Brachycephalic breeds, especially Boxers and Boston Terriers are over-represented in the canine population, with no clear breed predisposition in cats.^{1,2,11} Chemodectoma appears to be rare in cats, with only 13 cases reported in the literature to date.⁶ Affected cats are adults (aged 7–16 years), with females reported slightly more commonly than males.¹⁻³ Previously reported feline chemodectomas were localised at the heart base,^{1,2,12} in a portion of the aorta,³⁻⁵ at the base of the left pulmonary artery^{5,13} and the right pulmonary artery,¹³ or at the entrance of the vena cava.² The anatomical location of the mass in the cranial vena cava at the level of the azygos vein has not been reported previously in the veterinary literature.

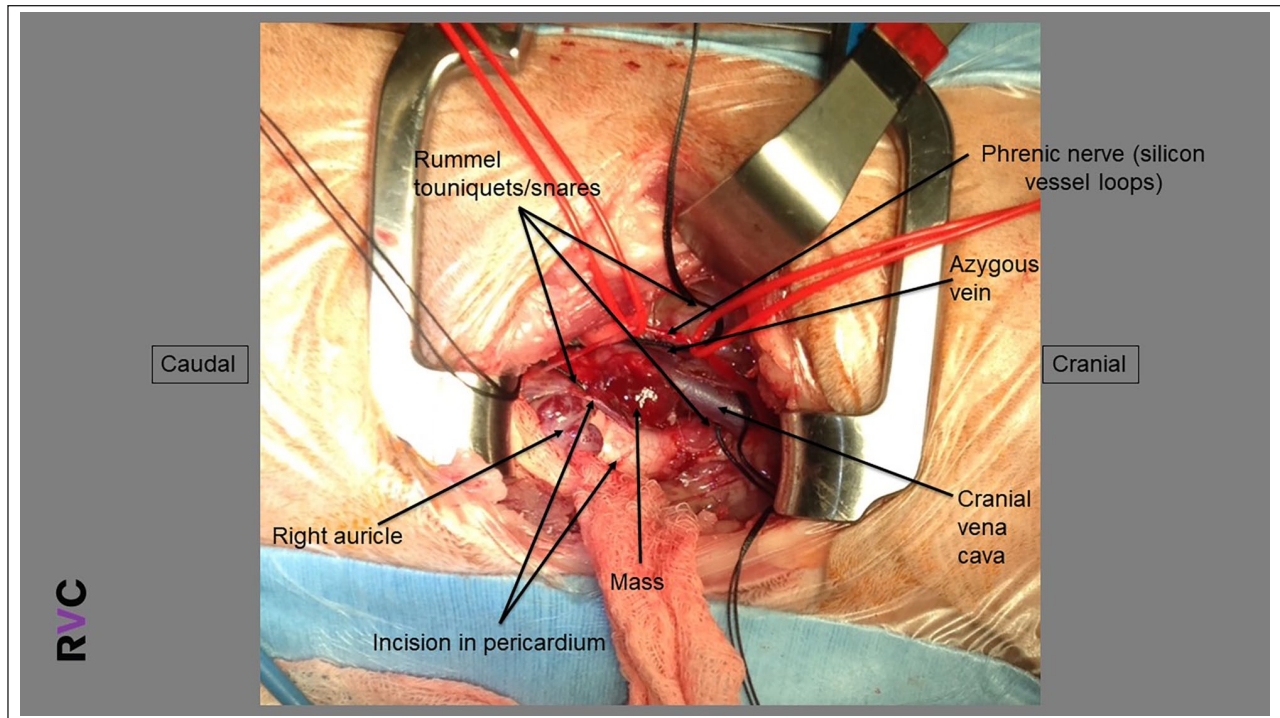


Figure 2 Intraoperative image: right fourth intercostal thoracotomy. The arrow labelled 'mass' points to the caval chemodectoma before being excised

Although chemodectomas are typically slow growing, most are associated with local invasion of surrounding tissue and vascular structures at the time of diagnosis. Given the slow growth of the tumour, clinical signs caused by chemodectoma of the aortic and carotid bodies are often subtle until the tumour stage is advanced.¹⁻³ The most commonly reported clinical signs in cats include dyspnoea, coughing, pericardial effusion, pleural effusion and, less commonly, pulmonary oedema.^{1-4,6,14} In the reported case, a pleural effusion had presumptively developed as a result of direct disruption of the thoracic duct by the tumour or secondarily to central venous hypertension.

Metastasis is seen in 22% of dogs with chemodectoma and the lung is the most commonly reported site.¹⁻³ Metastases were seen in 5/13 cats reported with sites including the intrathoracic lymph nodes, pericardium, epicardium, myocardium, diaphragm, surface of intercostal muscles and pulmonary parenchyma.^{1,3,5,7,8} In this case, no evidence of metastasis was reported at the time of diagnosis, follow-up imaging during treatment or at the time of euthanasia. In previous reports of feline chemodectoma, radiographs,^{1,4} thoracic ultrasound,^{2,4} echocardiography^{1,6} and CT were used for imaging.^{3,6} Thoracic radiographs showed a soft tissue opacity in the region of the heart base,¹⁻³⁻⁸ while CT allowed for identification of the precise location of the mass assessment for invasion into the surrounding tissues, and measurement of the precise size of the mass. It also

allowed for a more thorough assessment of metastases.^{3,6} This was also previously illustrated by Yoon et al,¹⁵ where CT provided accurate information for presurgical staging and patient management in animals with mediastinal masses. In humans, CT is the imaging modality of choice for both mediastinal tumour detection and evaluation of the extent of disease.¹⁶ Both, echocardiography and CT can be useful in documenting the compression of specific vessels and in determining the extension of the tumour.¹¹ However, in this case, the echocardiography did not document presence of the mass, which was only evident on the CT.

Histologically, chemodectomas are often partially encapsulated with tumour cells organised in lobules, similar to this case. The predominant cell types are epithelioid in appearance, with slightly eosinophilic cytoplasm.^{4,12} In the cat reported here, cells were partially encapsulated and arranged in dense packets in a fine fibrovascular stroma that had moderate amounts of pale eosinophilic granular cytoplasm. Given that neoplastic cells did not exhibit thyroglobulin labelling, a diagnosis of ectopic thyroid carcinoma was ruled out. In reported cases, the diagnosis was confirmed with a necropsy and histopathology examination in at least six cases,^{1,4-6,9,10} histopathology of the mass following the surgery in one case² and confirmed by cytology in two cases.^{3,5}

Chemodectomas in humans, also known as paragangliomas, are mainly located in the head and neck, originating from parasympathetic tissue. The most

common locations for these tumours are the carotid body, vagal body and jugulotympanic region.¹⁷ In the human literature, only two cases of neuroendocrine tumours of the inferior vena cava have been reported.¹⁸ Paragangliomas are uncommon, with population studies noting an incidence of 1–8 cases per 1 million people.¹⁹ Rates of malignant tumours in humans range between 2% and 19%. Surgical excision is the preferred therapeutic option for carotid body tumours and is most often recommended in young and otherwise healthy patients with small-to-medium sized and functional tumours where there is evidence of malignancy or fast growth.²⁰ Radiotherapy is an alternative if a patient cannot undergo a surgical procedure, as it either decreases in size or temporarily stops its growth. One study describing patients undergoing radiotherapy as a sole treatment revealed that 70% remained stable over years or with minimal growth, and only 30% needed further treatment due to rapid growth or clinical symptoms.^{20,21}

Treatment options for chemodectomas in animals are not well defined. Surgical excision of the aortic body tumour has been described,¹³ although it is not commonly pursued, given that its location in the aorta would preclude complete surgical excision. Surgical excision has been reported in a dog with a left atrial paraganglioma, with a survival time of 21 months following surgery.²² Pericardiectomy in dogs with aortic body tumours was shown to improve survival, even in cases with no pericardial effusion at the time of diagnosis.^{11,23} Pericardiectomy has also been previously reported as palliative treatment in dogs with heart base masses that are not resectable and pericardial effusion and tamponade are causing clinical signs. Dogs that underwent pericardiectomy demonstrated a significantly longer survival time (mean 661 days) compared with those that were treated medically without surgery (mean 129 days).²³ There have also been a few cases in dogs with cardiac tumours without neoplastic pericardial disease reporting successful surgery (pericardiectomy) with survival times of up to 729 days, although morbidity and mortality were high.¹⁴ There are no feline case series supporting the benefits of pericardiectomy in chemodectomas; however, there is a case report describing subtotal pericardiectomy, following which the cat survived for 19 months.¹⁰ Two further case reports described resection of a heart base mass at the entrance of the vena cava² and the aortic body.⁹ The first cat died suddenly the following morning;² the other survived for 13 months without clinical signs.⁹ Further reported cases were euthanased either at the time of diagnosis or shortly after at the owners' request.^{1,4,6,8} In our case, surgery was attempted in order to achieve a definitive diagnosis; despite incomplete excision, it also provided long-term control of clinical signs and allowed tailoring of the adjunctive therapy.

Medical treatment of chemodectomas is not well described. Toceranib phosphate (Palladia; Zoetis) is a tyrosine kinase inhibitor initially licensed for treatment of mast cell tumours in dogs.^{22,24} It has shown biological activity against several types of tumours, including neuroendocrine neoplasia such as insulinoma, phaeochromocytoma, thyroid carcinoma and anal sac adenocarcinoma.^{25–27} The use of toceranib phosphate in heart base tumours in dogs has been recently reported. In this case series, dogs with heart base tumours showed 91% clinical improvement in macroscopic disease settings. In addition, 81% had complete resolution of signs after starting treatment with toceranib phosphate.²⁸ Palliative medical treatment with toceranib phosphate in the macroscopic setting in a cat has been reported; however, treatment was discontinued after 2 weeks as a result of difficulties in administration, and the cat survived 6 weeks post-diagnosis. Therefore, the response to treatment could not be evaluated.³

Conclusions

There have been no reported cases of cats receiving toceranib phosphate in adjuvant settings. In this case, although it is unknown whether treatment with toceranib phosphate actually modified the growth of the tumour and delayed local recurrence, the treatment was well tolerated. We speculate whether this contributed to the prolonged period before local recurrence occurred (31 months post-diagnosis). At the same time, given the slow growth of chemodectomas, it is possible that this tumour would take this long to regrow without adjuvant treatment. It is likely that surgical excision was beneficial as, by removing the tumour, the pleural effusion resolved, which had caused the clinical signs at the presentation.

To our knowledge, this is the first report of a chemodectoma arising from the wall of the cranial vena cava in a cat. This is also the first description of the surgical management of chemodectoma in this location, where marginal surgical excision required vascular reconstruction, but this, along with a 12-month course of toceranib, afforded this cat a long period (31 months from diagnosis) free from clinical signs.

Conflict of interest The authors declared no potential conflicts of interest with respect to the research, authorship, and/or publication of this article.


Funding The authors received no financial support for the research, authorship, and/or publication of this article.

Ethical approval The work described in this manuscript involved the use of non-experimental (owned or unowned) animals. Established internationally recognised high standards ('best practice') of veterinary clinical care for the individual patient were always followed and/or this work involved the

use of cadavers. Ethical approval from a committee was therefore not specifically required for publication in *JFMS Open Reports*. Although not required, where ethical approval was still obtained, it is stated in the manuscript.

Informed consent Informed consent (verbal or written) was obtained from the owner of all animal(s) described in this work (experimental or non-experimental animals, including cadavers) for all procedure(s) undertaken (prospective or retrospective studies). No animals or people are identifiable within this publication, and therefore additional informed consent for publication was not required.

ORCID iD Irene Martinez  <https://orcid.org/0000-0003-2301-3317>

Daniel Brockman  <https://orcid.org/0000-0002-2133-9500>

References

- Willis R, Williams AE, Schwarz T, et al. **Aortic body chemodectoma causing pulmonary edema in a cat.** *J Small Anim Pract* 2001; 42: 20–23.
- Caruso KJ, Cowell RL, Upton ML, et al. **Intrathoracic mass in a cat.** *Vet Clin Pathol* 2002; 31: 193–195.
- Hansen S, Smith A, Kuo K, et al. **Metastatic neuroendocrine carcinoma of aortic body origin in a cat.** *Vet Clin Pathol* 2016; 45: 490–494.
- Paltrinieri S, Riccaboni P, Rondena M, et al. **Pathologic and immunohistochemical findings in a feline aortic body tumor.** *Vet Pathol* 2004; 41: 195–198.
- Buergelt CD and Das KM. **Aortic body tumour in a cat: a case report.** *Vet Pathol* 1968; 5: 84–91.
- del Busto I, Stiborova K, Villiers E, et al. **Aortic chemodectoma causing a lymphocyte-rich effusion in a cat.** *Vet Rec Case Rep* 2018; 4: e000620. DOI: 10.1136/vetreccr-2018-000620.
- Tilley LP, Bond B, Patnaik AM, et al. **Cardiovascular tumors in the cat.** *J Am Anim Hosp Assoc* 1981; 17: 1009–1021.
- George C and Steinberg H. **An aortic body carcinoma with multifocal thoracic metastases in a cat.** *J Comp Pathol* 1989; 101: 467–469.
- Tillson DM, Fingland RB and Andrews GA. **Chemodectoma in a cat.** *J Am Anim Hosp Assoc* 1994; 30: 586–590.
- Fossum TW, Miller MW, Rogers KS, et al. **Chylothorax associated with right-sided heart failure in five cats.** *J Am Vet Med Assoc* 1994; 204: 84–89.
- Ehrhart N, Ehrhart EJ, Willis J, et al. **Analysis of factors affecting survival in dogs with aortic body tumors.** *Vet Surg* 2002; 32: 44–48.
- Yamamoto S, Fukushima R, Hirakawa A, et al. **Histopathological and immunohistochemical evaluation of malignant potential in canine aortic body tumours.** *J Comp Path* 2013; 149: 182–191.
- Orton EC. **Surgery of the cardiovascular system.** In: Fossum TW (ed). *Small animal surgery*. St Louis, MO: Mosby, 1997, pp 575–608.
- Treggiari E, Pedro B, Dukes-McEwan J, et al. **A descriptive review of cardiac tumours in dogs and cats.** *Vet Comp Oncol* 2015; 2: 273–288.
- Yoon J, Feeney DA, Cronk DE, et al. **Computed tomographic evaluation of canine and feline mediastinal masses in 14 patients.** *Vet Radiol Ultrasound* 2004; 45: 542–546.
- Rebner M, Gross BH, Robertson JM, et al. **CT evaluation of mediastinal masses.** *Comput Radiol* 1987; 11: 103–110.
- Galan SR and Kann PH. **Genetics and molecular pathogenesis of pheochromocytoma and paraganglioma.** *Clin Endocrinol (Oxf)* 2013; 78: 165–175.
- Ransford G, Ayyathurai R, Fernandez G, et al. **Surgical management of a neuroendocrine tumor of the inferior vena cava.** *J Vasc Surg* 2013; 58: 496–499.
- Fishbein L and Nathanson KL. **Pheochromocytoma and paraganglioma: understanding the complexities of the genetic background.** *Cancer Genet* 2012; 205. DOI: 10.1016/j.cancergen.2012.01.009.
- Valero C, Ganly I and Shah JP. **Head and neck paragangliomas: a 30 year experience.** *Head Neck* 2020; 42: 2486–2495.
- Hoang V, Trinh C, Lai T, et al. **Carotid body tumor: a case report and literature review.** *J Radiol Case Rep* 2019; 13: 19–30.
- London CA, Hannah AL, Zadovoskaya R, et al. **Phase I dose-escalating study of SU11654, a small molecule receptor tyrosine kinase inhibitor, in dogs with spontaneous malignancies.** *Clin Cancer Res* 2003; 9: 2755–2768.
- Vicari ED, Brown DC, Holt DE, et al. **Survival times of and prognostic indicators for dogs with heart base masses: 25 cases (1986–1999).** *J Am Vet Med Assoc* 2001; 219: 485–487.
- Polyzos A. **Activity of SU11248, a multitargeted inhibitor of vascular endothelial growth factor receptor and platelet-derived growth factor receptor, in patients with metastatic renal cell carcinoma and various other solid tumors.** *J Steroid Biochem Mol Biol* 2008; 108: 261–266.
- Flesner BK, Fletcher JM, Smithee T, et al. **Long-term survival and glycemic control with toceranib phosphate and prednisone for a metastatic canine insulinoma.** *J Am Anim Hosp Assoc* 2019; 55. DOI: 10.5326/JAAHA-MS-6751.
- Musser ML, Taikowski KL, Johannes CM, et al. **Retrospective evaluation of toceranib phosphate (Palladia®) use in the treatment of inoperable, metastatic, or recurrent canine pheochromocytomas: 5 dogs (2014–2017).** *BMC Vet Res* 2018; 14: 272. DOI: 10.1186/s12917-018-1597-7.
- London C, Mathie T, Stingle N, et al. **Preliminary evidence for biologic activity of toceranib phosphate (Palladia®) in solid tumors.** *Vet Comp Oncol* 2012; 10: 194–205.
- Lew F, McQuown B, Borrego J, et al. **Retrospective evaluation of canine heart base tumours treated with toceranib phosphate (Palladia): 2011–2018.** *Vet Comp Oncol* 2019; 17: 465–471.