



## **Pharyngeal dermoid cyst causing partial upper airway obstruction in a cat**

Authors: Koch, Lydia, Csebi, Peter, Lipnik, Karoline, and Gradner, Gabriele

Source: Journal of Feline Medicine and Surgery Open Reports, 8(2)

Published By: SAGE Publishing

URL: <https://doi.org/10.1177/20551169221122853>

---

BioOne Complete ([complete.BioOne.org](https://complete.BioOne.org)) is a full-text database of 200 subscribed and open-access titles in the biological, ecological, and environmental sciences published by nonprofit societies, associations, museums, institutions, and presses.

Your use of this PDF, the BioOne Complete website, and all posted and associated content indicates your acceptance of BioOne's Terms of Use, available at [www.bioone.org/terms-of-use](https://www.bioone.org/terms-of-use).

Usage of BioOne Complete content is strictly limited to personal, educational, and non - commercial use. Commercial inquiries or rights and permissions requests should be directed to the individual publisher as copyright holder.

---

BioOne sees sustainable scholarly publishing as an inherently collaborative enterprise connecting authors, nonprofit publishers, academic institutions, research libraries, and research funders in the common goal of maximizing access to critical research.



# Pharyngeal dermoid cyst causing partial upper airway obstruction in a cat

Lydia Koch<sup>1</sup> , Peter Csebi<sup>2</sup>, Karoline Lipnik<sup>3</sup> and Gabriele Gradner<sup>1</sup>

*Journal of Feline Medicine and Surgery Open Reports*  
1–6

© The Author(s) 2022

Article reuse guidelines:

sagepub.com/journals-permissions

DOI: 10.1177/20551169221122853

journals.sagepub.com/home/jfmsopenreports

This paper was handled and processed by the European Editorial Office (ISFM) for publication in *JFMS Open Reports*



## Abstract

**Case summary** A 2-year-old cat was presented with nasopharyngeal stridor and stertor. Radiographs of the upper neck region showed a mass lesion in the nasopharynx. A nasopharyngeal polyp was suspected, but an attempt at endoscopic removal failed, owing to fragmentation of the mass and excessive haemorrhage. A sample was taken and histology confirmed a dermoid cyst. CT was performed and the lesion was described as most likely to be a dermoid cyst, consistent with the histopathological findings. Surgical exploration and subsequent complete removal of the mass led to a full recovery.

**Relevance and novel information** The nasopharyngeal location represents a previously unreported location of a dermoid cyst. This report raises awareness of dermoid cysts as a potential differential diagnosis within the nasopharyngeal region and highlights the importance of pre-interventional diagnostic imaging.

**Keywords:** Dermoid cyst; airway obstruction; pharynx; stridor

**Accepted:** 11 August 2022

## Case description

A 2-year-old female neutered domestic shorthair cat weighing 4.1 kg was presented to the Small Animal Department of the University of Veterinary Medicine Vienna with progressive stridor and stertor exacerbated by exercise. Coughing was noticed occasionally. Other clinical parameters, including exploration of the oral cavity and blood work were unremarkable, and a tentative diagnosis of a nasopharyngeal polyp was made. A two-view radiographic examination of the upper neck was performed and revealed an oval mass lesion about 2.8 cm long and 1.4 cm high with heterogeneous fat and soft tissue opacity in the nasopharynx. The mass extended from the temporomandibular joint to the larynx, completely obliterating the nasopharynx. The lesion had a convex caudal margin and created a mass effect by depressing the soft palate (Figure 1). The tympanic bullae were air filled with a thin intact wall. A nasopharyngeal polyp was considered likely, but differential diagnoses included granuloma, abscess or foreign body reaction, cyst or neoplasia.<sup>1</sup>

The cat underwent endoscopic examination of the upper airway to remove the suspected polyp. Analgesia was provided with buprenorphine (20 µg/kg IV) and meloxicam (0.05 mg/kg IV). The mass was found to be hemispheric, broad-based, located on the right side of the nasopharynx and extending caudally to the soft palate (Figure 2).

Endoscopic removal failed as the mass could not be mobilised efficiently, and it fragmented when attempting

<sup>1</sup>Small Animal Surgery, Department for Small Animals and Horses, University of Veterinary Medicine Vienna, Vienna, Austria

<sup>2</sup>Clinical Unit of Diagnostic Imaging, Department for Small Animals and Horses, University of Veterinary Medicine Vienna, Vienna, Austria

<sup>3</sup>Institute of Pathology, Department for Pathobiology, University of Veterinary Medicine Vienna, Vienna, Austria

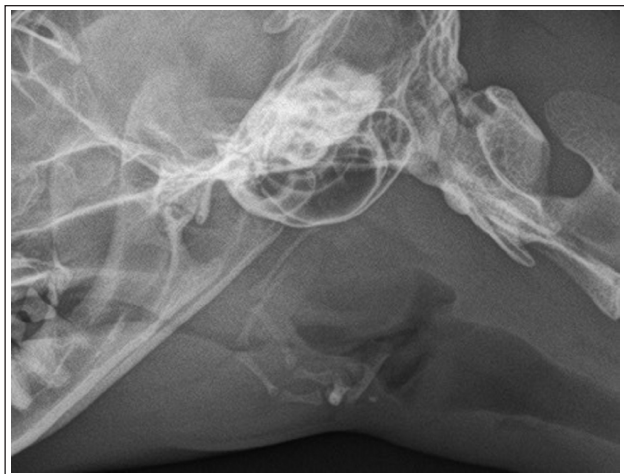### Corresponding author:

Lydia Koch DVM, Small Animal Surgery, Department for Small Animals and Horses, University of Veterinary Medicine Vienna, Veterinärplatz 1, Vienna 1210, Austria  
Email: lydia.koch@vetmeduni.ac.at

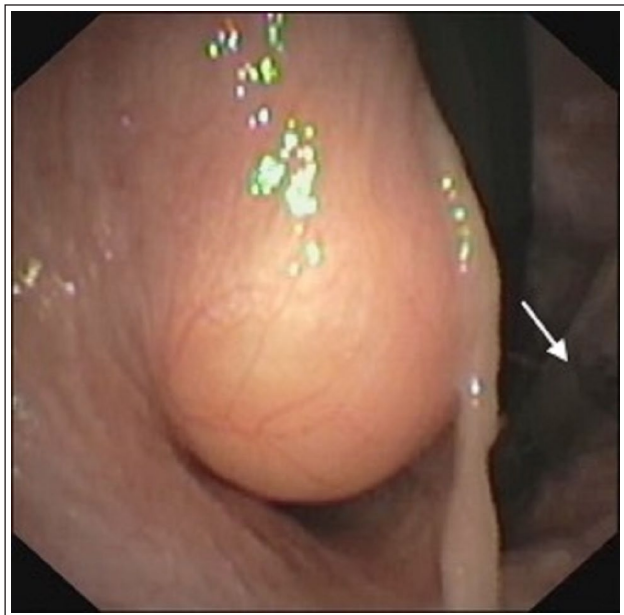

Creative Commons Non Commercial CC BY-NC: This article is distributed under the terms of the Creative Commons

Attribution-NonCommercial 4.0 License (<https://creativecommons.org/licenses/by-nc/4.0/>) which permits non-commercial use, reproduction and distribution of the work without further permission provided the original work is attributed as specified on the SAGE and Open Access pages (<https://us.sagepub.com/en-us/nam/open-access-at-sage>).



**Figure 1** Heterogeneous fat and partial soft tissue opacity nasopharyngeal mass lesion depressing the soft palate



**Figure 2** Appearance of the mass located in the right nasopharynx during endoscopic examination. Arrow points to the endotracheal tube

to remove it with torquing. Partial laser ablation of the mass was performed because of bleeding and swelling. After removing a small amount of soft tissue, a hair shaft was found within the cystic lumen. Ablation was performed as far as possible, and the extracted specimens were fixed in 4% neutral buffered formalin and sent to the Institute of Pathology at the Veterinary University of Vienna for histopathological examination. An oesophagostomy tube was placed to provide nutritional support.

Sections of 4 µm thickness were prepared from five 5 × 2 × 2 mm to 3 × 3 × 3 mm, white-to-greyish soft tissue pieces and stained with haematoxylin and eosin

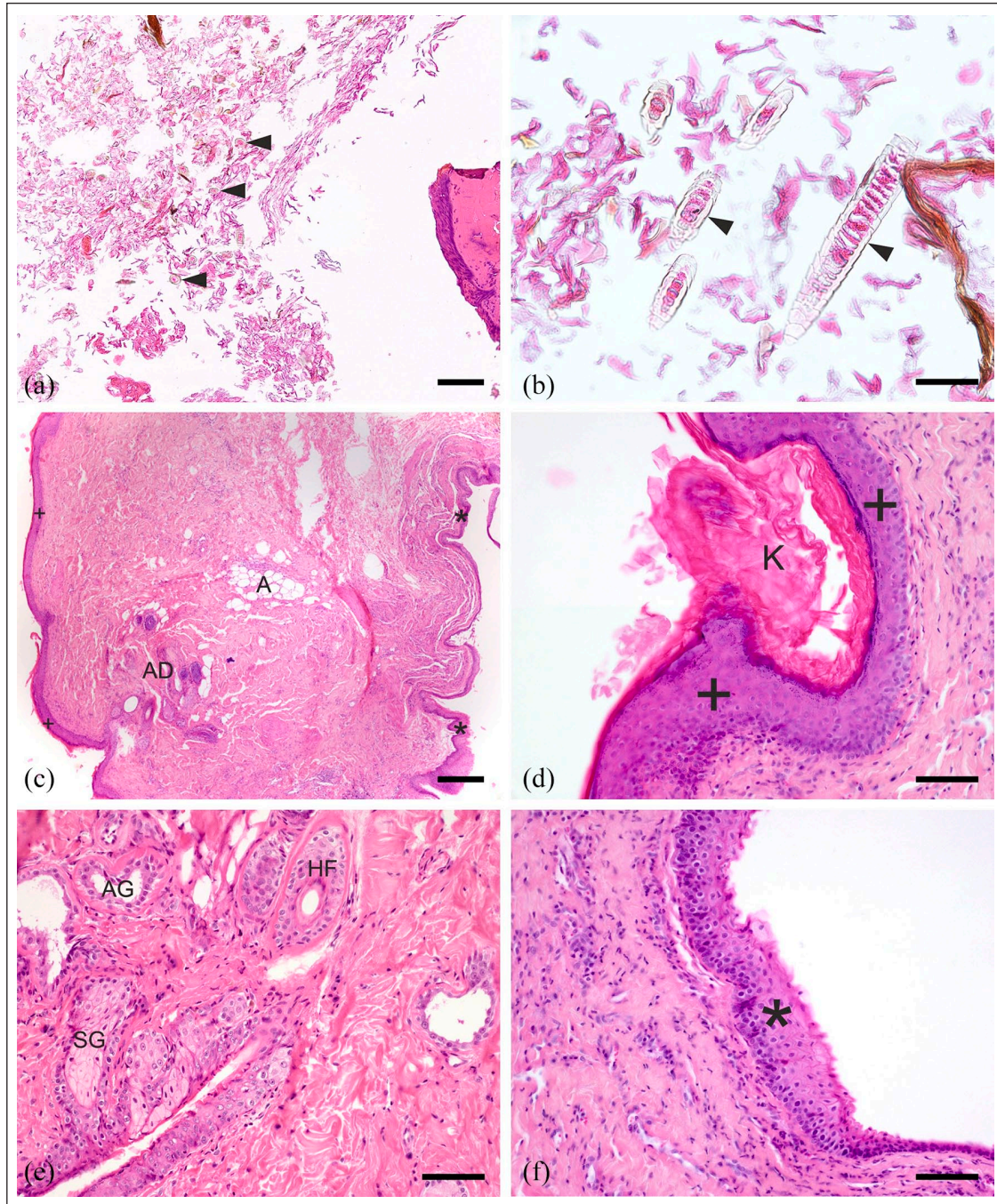
(Figure 3). The samples consisted of normal skeletal muscle, adipose and collagenous connective tissue with some degree of heat denaturation due to the surgical technique utilised. The specimens were partially covered by keratinising, flattened squamous epithelium accompanied by abundant luminal accumulation of lamellar, predominantly loosely packed orthokeratin and multiple hair shaft fragments (Figure 3a,b).

As complete surgical removal was not possible, further work-up was initiated. CT examination was performed the next day (Somatom Emotion 16 CT; Siemens) to evaluate the extent of the lesion. CT imaging showed a rounded, well-defined mass approximately 3.7 × 2 × 2 cm on the right side of the pharynx. The lesion showed a heterogeneous structure with mainly fat attenuation and more centrally located linear and rounded soft tissue attenuation areas. Contrast enhancement was not seen. The mass lesion extended from the pterygoid to the level of the craniocervical junction. It was bordered medially by the pharyngeal wall and laterally by the medial pterygoid muscle, the ceratohyoid and stylohyoid bone, the external carotid artery and the medial retropharyngeal lymph node. The mass bulged into the pharynx and caused marked luminal compression. Multiple gas bubbles were present in the surrounding soft tissues extending caudally along the fascial planes, consistent with the previous surgical procedure (Figure 4). Differential diagnoses from the CT included a primary dermoid cyst or, less likely, a lipoma with cystic content.

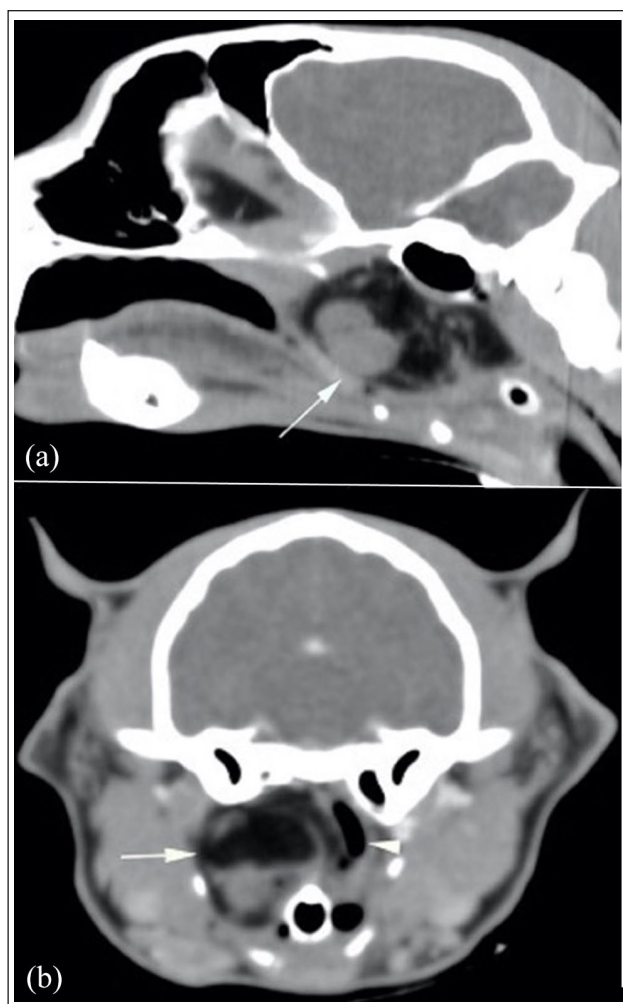
Surgical excision was performed via the right upper neck region with the tympanic bulla as a landmark. A ventral skin incision was made, and soft tissues were bluntly dissected until a mass with soft tissue strands became visible. Two cysts were found adherent to the lipomatous mass on the medial aspect; one was filled with hair shaft fragments and the other with a yellowish content. Furthermore, laceration of the caudal nasopharynx and approximately 10 cm of the cranial oesophagus became visible. After closing the laceration with a #3/0 absorbable multifilament suture material, resection of the mass was continued.

The tissue was fixed and prepared as described above. Four soft tissue samples were analysed histologically. Large areas consisted of regular adipose tissue interspersed by small parts of skeletal muscle, partially accompanied by fibrinoid necrosis, demarcated by cell-rich, juvenile granulation tissue. One sample was widely confined by a cyst wall covered by keratinising, stratified, well-differentiated epidermal-like epithelium (Figure 3c,d) associated with moderate-to-marked hyperkeratosis (Figure 3d). The subepithelial fibrovascular stroma abutting the cyst wall harboured foci of skin adnexa (Figure 3c), including small hair follicles, sebaceous glands and apocrine sweat glands (Figure 3e). In close proximity to the adnexal structures, there were





**Figure 3** Dermoid cyst with a stratified squamous epithelium, skin adnexal structures and keratin and hair shaft congested cavity located in the pharynx. (a,b) Cystic cavity filled with loosely packed orthokeratin and numerous hair shaft fragments (arrowheads). The right side of (a) shows the cystic wall, delimiting the cavity; bar represents 300 $\mu$ m in (a) and 40 $\mu$ m in (b). (c) The microscopic examination of the cross-section revealed fibrovascular stroma covered by an epithelial cell lining compatible with pharyngeal mucosa (asterisk) on the right-hand side, whereas on the left-hand side an epidermal-like well-differentiated, stratified, keratinising epithelium (cross) depicting the luminal cover of the cystic wall was seen. Adjacent to the epidermal-like epithelium, focal accumulation of skin adnexal structures (AD) resembling folliculo-sebaceous hair units, as well as oligofocal interspersed groups of adipocytes (A), are presented (bar represents 300 $\mu$ m). (d) Cystic wall consisting of fibrovascular stroma lined by cornified, stratified, squamous epithelium (cross) compatible to epidermal epithelium with marked hyperkeratosis (K; bar represents 80 $\mu$ m). (e) Focal area with skin adnexal structures displaying hair follicles (HF), sebaceous glands (SG) and as sweat glands (AG) embedded in a dermal-like stromal compartment (bar represents 80 $\mu$ m). (f) Pharyngeal cutaneous mucosa showing fibrovascular stroma lined by non-cornified, stratified, squamous epithelium (asterisks; bar represents 80 $\mu$ m)



**Figure 4** (a) Sagittal reformatted image showing marked rostrocaudal extension of the mass lesion ventral to the tympanic bulla and inherent rounded ventrally located soft tissue attenuating structure (arrow). There are multiple gas bubbles caudal to the lesion extending into the fascial planes of the neck consistent with emphysema. (b) Transverse image at the rostral level of the tympanic bulla showing a large mixed fat and soft tissue-attenuating mass lesion on the right side of the nasopharynx (arrow). The nasopharyngeal lumen is markedly displaced leftward and compressed (arrowhead)

focally grouped adipocytes in the stromal connective tissue (Figure 3c). In contrast, the sample was lined with stratified squamous epithelium compatible with pharyngeal cutaneous mucosa (Figure 3c,f). These findings were consistent with a dermoid cyst.

The oesophagostomy tube was replaced with a gastrostomy tube to maintain appropriate feeding during the healing process. The cat recovered from anaesthesia without any problems and was sent home 3 days postoperatively. Analgesia was continued with buprenorphine (15 µg/kg IV q6h daily until discharge) and meloxicam (0.05 mg/kg PO for a total of 10 days). Food and water

were administered via the tube for a period of 15 days, and weekly revisits were scheduled. Complications during this phase included loosening of the feeding tube plug and of the bandage. After 15 days, oral intake of water and liquid food was initiated. Twenty-two days postoperatively, a contrast media swallow using 10 ml amidotrizoate (Gastrografin; Bayer Vital) and fluoroscopy was performed. It showed no evidence of leakage and therefore the cat was fed orally with moist cat food. As the patient had no problems with the intake of conventional cat food, the gastrostomy tube was removed 29 days after placement.

## Discussion

Although dermoid cysts have been reported in cats,<sup>2-9</sup> with a predisposition for the neck and shoulder region,<sup>5</sup> to our knowledge, this is the first report of such a cyst located within the nasopharynx.

The most common disease of the nasopharynx in young cats is inflammatory polyps arising from the lining of the middle ear or the Eustachian tube, usually causing stertor of the upper airways.<sup>10-14</sup> Diagnosis is made based on patient history and physical examination and supported by endoscopic evaluation, diagnostic imaging and histopathology.<sup>13,15,16</sup>

Based on the signalment and history of this cat, a nasopharyngeal polyp was suspected; therefore, endoscopic evaluation was performed and removal by traction and avulsion was attempted. In this method, the polyp is grasped close to its base and gentle, steady traction is applied until it detaches.<sup>11,13-15</sup> If haemorrhage occurs, it is usually minimal and can be stopped by the application of pressure.<sup>11,14,17</sup> Because easy grasping of the mass was not possible in our case and persistent bleeding occurred, a different disease other than a nasopharyngeal polyp was suspected.

To determine this, a CT or MRI examination would have been helpful prior to any attempt to remove the mass. Although there are only a few reports regarding the appearance of dermoid cysts on CT and MRI, there are remarkable differences to nasopharyngeal polyps.<sup>9,18-22</sup> In one report of a dermoid cyst, including CT imaging findings, a cystic structure with mixed attenuation and a hypoattenuating centre was noted,<sup>20</sup> which is comparable to the findings in our patient. In a study of 13 cats with nasopharyngeal polyps that underwent a CT examination, all masses were hypoattenuating to the adjacent musculature and isoattenuating to soft tissue.<sup>21</sup> Furthermore, all had an ill-defined shape, and there was no possibility of delineating them from surrounding structures. Most had a homogenous appearance and ill-defined borders. After administration of contrast medium, all masses had an oval appearance, showed hypoattenuation compared with soft tissue and had well-defined borders and rim enhancement. In some patients, the latter could be followed into the auditory tube.



In a few MRI reports regarding the appearance of dermoid cysts not associated with the spinal cord, they are described as well demarcated and heterogeneously hyperintense in T1 consistent with fat and fluid.<sup>9,19</sup> One report additionally described a thin rim, which took up contrast medium.<sup>18</sup> In comparison, MRI examination of nasopharyngeal polyps showed a stalk-like structure hyperintense in T2 vs grey matter, hypo- to isointense on T1 and a heterogeneous rim enhancement after the administration of contrast medium in one study.<sup>22</sup>

The treatment of choice for dermoid cysts is surgical removal, which has been reported to have excellent outcomes.<sup>16,23,24</sup> Consistent with our findings, keratinised squamous epithelial lining with keratin fragments, hair shafts and follicles are described in the histopathological examinations of these cysts.

Although it is unclear when the laceration of the oesophagus occurred in our patient, this complication is possible either secondarily to a process compromising the integrity of the oesophageal wall or during placement of an oesophageal feeding tube when the wall is friable, too large instruments are used to penetrate the wall or if there are multiple attempts at proper placement.<sup>14,25</sup> After the second surgery, in which laceration of the oesophagus was detected and addressed, a gastrotomy tube was placed. These tubes are indicated after surgery of the oesophagus, as an oesophagostomy tube can interfere with healing.<sup>14</sup>

## Conclusions

Although nasopharyngeal polyps are a very common cause of stertor in young cats, other differentials should be considered. Ideally, CT or MRI should be performed before attempting removal. When addressing a mass located in that region, veterinarians must be aware of the possibility of haemorrhage and equipment for haemostasis, as well as the possibility of converting from an endoscopic to an open approach, must be available.


**Conflict of interest** The authors declared no potential conflicts of interest with respect to the research, authorship, and/or publication of this article.

**Funding** The authors received no financial support for the research, authorship, and/or publication of this article.

**Ethical approval** The work described in this manuscript involved the use of non-experimental (owned or unowned) animals. Established internationally recognised high standards ('best practice') of veterinary clinical care for the individual patient were always followed and/or this work involved the use of cadavers. Ethical approval from a committee was therefore not specifically required for publication in *JFMS Open Reports*. Although not required, where ethical approval was still obtained, it is stated in the manuscript.

**Informed consent** Informed consent (verbal or written) was obtained from the owner or legal custodian of the animal described in this study (experimental or non-experimental animals, including cadavers) for all procedures undertaken (prospective or retrospective studies). For any animals or people individually identifiable within this publication, informed consent (verbal or written) for their use in the publication was obtained from the people involved.

**ORCID iD** Lydia Koch  <https://orcid.org/0000-0001-7228-0097>

Karoline Lipnik  <https://orcid.org/0000-0002-7832-9012>

## References

- Dennis R, Kirberger RM and Wrigley RH. Handbook of small animal radiology and ultrasound: techniques and differential diagnoses. Edinburgh: Churchill Livingstone/Elsevier, 2010.
- Henderson JP, Pearson GR and Smerdon TN. **Dermoid cyst of the spinal cord associated with ataxia in a cat.** *J Small Anim Pract* 1993; 34: 402–404.
- Rochat MC, Campbell GA and Panciera RJ. **Dermoid cysts in cats: two cases and a review of the literature.** *J Vet Diagn Invest* 1996; 8: 505–507.
- Chenier S, Quesnel A and Girard C. **Intracranial teratoma and dermoid cyst in a kitten.** *J Vet Diagn Invest* 1998; 10: 381–384.
- Gross TL, Ihrke PJ, Walder EJ, et al. Skin diseases of the dog and cat: clinical and histopathologic diagnosis. Hoboken, NJ: Wiley, 2008.
- Tolbert K, Brown HM, Rakich PM, et al. **Dermoid cysts presenting as enlarged thyroid glands in a cat.** *J Feline Med Surg* 2009; 11: 717–719.
- Tong T and Simpson DJ. **Case report: spinal dermoid sinus in a Burmese cat with paraparesis.** *Aust Vet J* 2009; 87: 450–454.
- Fleming JM, Platt SR, Kent M, et al. **Cervical dermoid sinus in a cat: case presentation and review of the literature.** *J Feline Med Surg* 2011; 13: 992–996.
- Brady S, Bell E, Courtman N, et al. **Nasal dermoid cyst with intracranial extension in a cat.** *JFMS Open Rep* 2019; 5. DOI: 10.1177/2055116919827404.
- Allen H, Broussard J and Noone K. **Nasopharyngeal diseases in cats: a retrospective study of 53 cases (1991–1998).** *J Am Anim Hosp Assoc* 1999; 35: 457–461.
- Muilenburg RK and Fry TR. **Feline nasopharyngeal polyps.** *Vet Clin North Am Small Anim Pract* 2002; 32: 839–849.
- Veir JK, Lappin MR, Foley JE, et al. **Feline inflammatory polyps: historical, clinical, and PCR findings for feline calici virus and feline herpes virus-1 in 28 cases.** *J Feline Med Surg* 2002; 4: 195–199.
- Reed N and Gunn-Moore D. **Nasopharyngeal disease in cats: 1. Diagnostic investigation.** *J Feline Med Surg* 2012; 14: 306–315.
- Johnston SA and Tobias KM. Veterinary surgery: small animal. St Louis, MO: Elsevier, 2017.
- Esterline ML, Radlinsky MG and Schermerhorn T. **Endoscopic removal of nasal polyps in a cat using a novel surgical approach.** *J Feline Med Surg* 2005; 7: 121–124.

- 16 Stelmann U, Silva A, Souza B, et al. **Dermoid cyst in sheep – a case report.** *Rev Bras Med Vet* 2012; 34: 127–130.
- 17 Anderson DM, White RAS and Robinson RK. **Management of inflammatory polyps in 37 cats.** *Vet Rec* 2000; 147: 684–687.
- 18 Anderson DM and White RA. **Nasal dermoid sinus cysts in the dog.** *Vet Surg* 2002; 31: 303–308.
- 19 Targett MP, McInnes E and Dennis R. **Magnetic resonance imaging of a medullary dermoid cyst with secondary hydrocephalus in a dog.** *Vet Radiol Ultrasound* 1999; 40: 23–26.
- 20 Visser EMS, Caliskan N, Veraa S, et al. **A retrobulbar dermoid cyst with involvement of the sinus in an 18-year old pony.** *Equine Vet Educ* 2019; 31: e47–e52. DOI: 10.1111/eve.12994.
- 21 Oliveira CR, O'Brien RT, Matheson JS, et al. **Computed tomographic features of feline nasopharyngeal polyps.** *Vet Radiol Ultrasound* 2012; 53: 406–411.
- 22 Tanaka T, Akiyoshi H, Mie K, et al. **MRI findings, including diffusion-weighted imaging and apparent diffusion coefficient value, in two cats with nasopharyngeal polyps and one cat with lymphoma.** *JFMS Open Rep* 2018; 4. DOI: 10.1177/2055116918812254.
- 23 Muñoz E, Leiva M, Naranjo C, et al. **Retrobulbar dermoid cyst in a horse: a case report.** *Vet Ophthalmol* 2007; 10: 394–397.
- 24 Hillyer LL, Jackson AP, Quinn GC, et al. **Epidermal (infundibular) and dermoid cysts in the dorsal midline of a three-year-old thoroughbred-cross gelding.** *Vet Dermatol* 2003; 14: 205–209.
- 25 Sutton JS, Culp WTN, Scotti K, et al. **Perioperative morbidity and outcome of esophageal surgery in dogs and cats: 72 cases (1993–2013).** *J Am Vet Med Assoc* 2016; 249: 787–793.