



Osteomyelitis associated with *Bartonella henselae* infection in a young cat

Authors: Hui, Jamie, Ryan, Kirk A, Rademacher, Nathalie, Neupane, Pradeep, and Breitschwerdt, Edward B

Source: Journal of Feline Medicine and Surgery Open Reports, 8(2)

Published By: SAGE Publishing

URL: <https://doi.org/10.1177/20551169221124910>

BioOne Complete (complete.BioOne.org) is a full-text database of 200 subscribed and open-access titles in the biological, ecological, and environmental sciences published by nonprofit societies, associations, museums, institutions, and presses.

Your use of this PDF, the BioOne Complete website, and all posted and associated content indicates your acceptance of BioOne's Terms of Use, available at www.bioone.org/terms-of-use.

Usage of BioOne Complete content is strictly limited to personal, educational, and non - commercial use. Commercial inquiries or rights and permissions requests should be directed to the individual publisher as copyright holder.

BioOne sees sustainable scholarly publishing as an inherently collaborative enterprise connecting authors, nonprofit publishers, academic institutions, research libraries, and research funders in the common goal of maximizing access to critical research.



Osteomyelitis associated with *Bartonella henselae* infection in a young cat

Jamie Hui¹, Kirk A Ryan¹, Nathalie Rademacher¹, Pradeep Neupane² and Edward B Breitschwerdt³

Journal of Feline Medicine and Surgery Open Reports
1–5

© The Author(s) 2022

Article reuse guidelines:

sagepub.com/journals-permissions

DOI: 10.1177/20551169221124910

journals.sagepub.com/home/jfmsopenreports

This paper was handled and processed by the American Editorial Office (AAFP) for publication in *JFMS Open Reports*



Abstract

Case summary A 1-year-old male intact domestic shorthair cat was evaluated for acute onset non-weightbearing left forelimb lameness and generalized peripheral lymphadenopathy. CT identified a monostotic aggressive bone lesion with an incomplete fracture of the left radial metaphysis. Bone aspirates yielded osteoblasts with minimal nuclear atypia. Abdominal ultrasound revealed a nodular spleen and lymphadenopathy; cytologically, both contained lymphoid hyperplasia. A urine histoplasma antigen test was negative. *Bartonella henselae* and *Mycoplasma haemominutum* DNA was amplified by PCR from peripheral blood. Indirect immunofluorescence documented strong *B. henselae* immunoreactivity, with lower *Bartonella vinsonii* subspecies *berkhoffii* and *Bartonella koehlerae* antibody titers. After the administration of doxycycline and pradofloxacin for suspected *Bartonella*-induced osteomyelitis, lameness resolved rapidly. Six-week post-treatment radiographs identified healing of the affected bone, and *Bartonella* species enrichment blood culture was negative. *B. henselae* antibody titers decreased four-fold over a year, supporting seroreversion.

Relevance and novel information *B. henselae* is a flea-transmitted, host-adapted species, not previously implicated as a cause of osteomyelitis in cats. *B. henselae* subclinical bacteremia is highly prevalent among cats; however, bacteremia has been associated with lymphadenopathy and febrile illness in cats. This report describes a unique clinical presentation in association with *B. henselae* infection in a cat.

Keywords: *Bartonella henselae*; bartonellosis; osteomyelitis; bone

Accepted: 22 August 2022

Introduction

Bartonella species are Gram-negative, fastidious, facultative intracellular bacilli that have coevolved with various mammalian hosts, including cats, dogs and humans.¹ Cats are the principal reservoir host for *Bartonella henselae* (*Bh*), *Bartonella koehlerae* (*Bk*) and *Bartonella clarridgeiae* (*Bc*).^{1,2} *B. henselae* has a global bacteremic prevalence as high as 50–76%.^{1,3} *Ctenocephalides felis* is the principal arthropod vector for multiple *Bartonella* species (including *Bh*, *Bk* and *Bc*).^{1,4,5} Disease expression following *Bh* infection is largely dependent on host immunocompetence, the presence of comorbidities or coinfections, and strain virulence. After infection with a host-adapted *Bartonella* species, healthy cats commonly experience subclinical bacteremia that persists for months to years.^{1–3} Alternatively, mild or

transient fever and lymphadenopathy are sometimes observed.^{3,6} Serious disorders such as endocarditis, myocarditis, uveitis, encephalitis and musculoskeletal abnormalities are uncommonly reported.^{1,3,7,8}

¹Department of Veterinary Clinical Sciences, Louisiana State University, Baton Rouge, LA, USA

²Department of Microbiology and Immunology, School of Medicine, University of North Carolina, Chapel Hill, NC, USA

³Department of Clinical Sciences, College of Veterinary Medicine, North Carolina State University, Raleigh, NC, USA

Corresponding author:

Jamie Hui BVSc, Department of Veterinary Clinical Sciences, Louisiana State University, Skip Bertman Dr, Baton Rouge, LA 70803, USA

Email: jhui2@lsu.edu



Creative Commons Non Commercial CC BY-NC: This article is distributed under the terms of the Creative Commons

Attribution-NonCommercial 4.0 License (<https://creativecommons.org/licenses/by-nc/4.0/>) which permits non-commercial use, reproduction and distribution of the work without further permission provided the original work is attributed as specified on the SAGE and Open Access pages (<https://us.sagepub.com/en-us/nam/open-access-at-sage>).

Recognition of osteomyelitis as a manifestation of feline bartonellosis is hitherto limited to a case report detailing a domestic cat infected with non-host-adapted *Bartonella vinsonii* subspecies *berkhoffii* (*Bvb*).⁹ Documentation of seroreversion (quantitative decrease in antibody titers) and its clinical significance during and after antimicrobial treatment for feline bartonellosis is also sparse.⁶ We report the clinicopathologic findings in a cat with *Bh* bacteremia, osteomyelitis and serologic trends over a 1-year follow-up period.

Case description

A 1-year-old male intact domestic shorthair cat weighing 3 kg was referred for evaluation of an aggressive bone lesion of the left radius following a 4-week history of progressive left forelimb lameness. Left forelimb radiographs performed by the primary veterinarian revealed a small lucency in the left proximal radial metaphysis. There was minimal response to cage confinement and meloxicam (Metacam; Boehringer Ingelheim). The cat was infested with fleas. It had been introduced from a feral population into a multi-cat household 3 months before presentation.

Physical examination identified a non-weightbearing left forelimb lameness, a painful left elbow swelling and generalized peripheral lymphadenomegaly. Complete blood count demonstrated a mature neutrophilia (14,100/ μ l; reference interval [RI] 2500–12,500). Serum alkaline phosphatase was mildly elevated (54 U/l; RI 0–45). There was mild proteinuria (30 mg/dl) and poorly concentrated urine (cystocentesis performed after intravenous fluid therapy). Repeat radiographs confirmed the progression of an ill-defined lucency in the left proximal radial metaphysis, with thinning and discontinuity of the cranial aspect of the cortex with a short zone of transition (Figure 1). Circumferential irregular-to-smooth periosteal bone reaction and soft tissue swelling were evident. Abdominal ultrasound identified multifocal lymphadenopathy (up to 9.3 mm wide) and hypoechoic splenic nodules.

Fine-needle aspiration of the affected bone yielded rare reactive osteoblasts. Cytologically, abdominal and peripheral lymph node aspirates contained reactive lymphoid hyperplasia. CT confirmed cortical lysis of the medial aspect of the left proximal radial metaphysis with irregular thinning of the cortex caudally and adjacent to the lytic region (Figure 2a), accompanied by a moderate amount of circumferential, smooth-to-brush border periosteal reaction (Figure 2b).

Neoplasia was considered an unlikely differential diagnosis given the cat's young age; therefore, additional infectious disease testing was pursued. A needle core bone biopsy was not attempted due to cortical lysis, small patient size and increased risk of an iatrogenic fracture. The owner declined surgical bone biopsy.

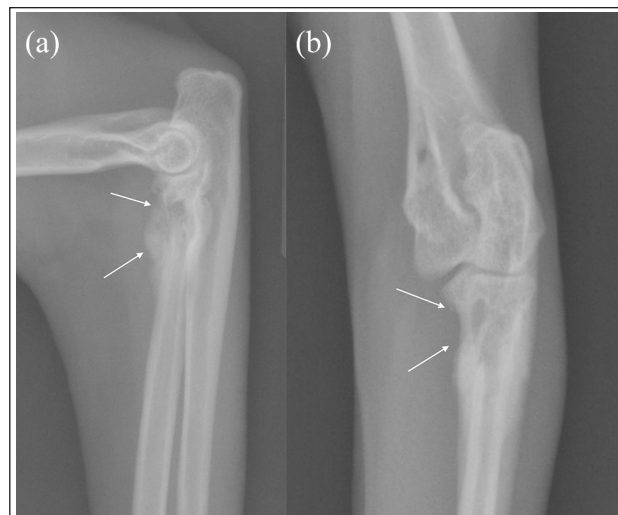


Figure 1 Orthogonal radiographs. (a) Mediolateral view and (b) craniocaudal view of the left elbow taken at the initial referral. Note the ill-defined, geographic lysis in the proximal metaphysis of the radius with focal cortical destruction and thinning (white arrows). These findings are consistent with an aggressive bone lesion from either osteomyelitis or neoplasia

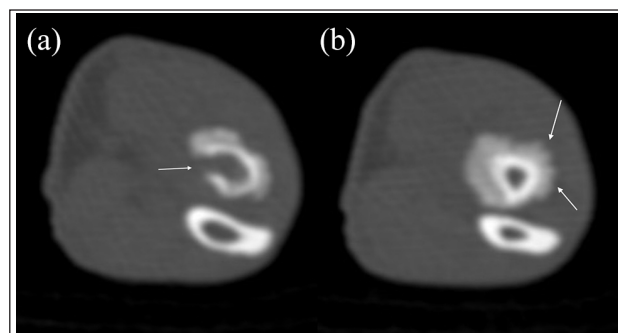


Figure 2 CT images (window length 550, window width 2700 in a bone algorithm with a 0.625 mm slice thickness) of the left proximal radius and ulna taken at the same time as the radiographs in Figure 1. (a) Transverse image of the left radius at the level of the proximal metaphyseal lytic area with cortical defect medially (white arrow). (b) Transverse image of the left radius distal to the lytic area seen in (a) showing the circumferential brush border new bone formation (white arrows)

Doxycycline (5 mg/kg PO q12h [Doxycycline monohydrate oral suspension USP; Cipla]) and clindamycin (16 mg/kg PO q12h [ClinDrops; Henry Shein Animal Health]) were initiated. Buprenorphine (0.02 mg/kg PO q8h [Buprenorphine hydrochloride; Par Sterile Products]) was weaned over 2 weeks.

Feline leukemia virus and feline immunodeficiency virus testing (SNAP FIV/FELV Combo; IDEXX Laboratories) was negative. Urine culture was negative for aerobic bacterial growth and urine was negative for

histoplasma antigen (MiraVista Veterinary Diagnostics). A feline vector-borne infectious disease serology and PCR panel was submitted to the Vector Borne Diseases Diagnostic Laboratory, North Carolina State University. The *Bh* immunofluorescence assay (IFA) antibody titer was markedly elevated (1:4096); *Bvb* and *Bk* titers were 1:256 and 1:64, respectively. *B henselae* DNA was amplified from the cat's blood (VB19-08571) specimen, using previously described *Bartonella* genus-specific *ssrA* real-time PCR (qPCR), 16S–23S intergenic transcribed spacer (ITS) region qPCR and 16S–23S ITS conventional PCR assays.^{10,11} Blast analysis of conventional ITS sequences (National Center for Biotechnology Information Basic Local Alignment Search Tool) were 100% identical to *Bh* isolate MT095053.1 (569/569 base pairs) and 99.82% similar to *Bh* CAL-1 (GenBank accession No AF369527.1). *B henselae* CAL-1 has one extra nucleotide, an 'A', that was missing from the amplicon sequences obtained from this cat's blood using both forward and reverse ITS primers. *Mycoplasma haemominutum* DNA was also amplified from the cat's blood.

Based upon clinicopathological findings and infectious disease test results, osteomyelitis secondary to bartonellosis was suspected. Pradofloxacin oral suspension (7.5 mg/kg PO q24h [Veraflox; Bayer]) was initiated and doxycycline was continued. Clindamycin was discontinued. Two weeks later, the owner reported rapid improvement in weightbearing of the affected limb.

At re-evaluation 6 weeks later, the left forelimb lameness and peripheral lymphadenopathy had resolved. An echocardiogram, performed as a screening for *Bartonella*-induced endocarditis, was normal. There was resolution of the left elbow periosteal reaction, and decreased lysis of the proximal radial metaphysis, with smooth cortical bone remodeling (Figure 3). The radiographic findings, clinical response to antibiotics and previously documented microbiological results supported resolving osteomyelitis, presumptively secondary to bartonellosis. *Bhenselae ssrA* PCR was negative, indicating that bacteremia had resolved or was below the level of PCR detection. Indirect fluorescence antibody titers remained similarly elevated (*Bh* 1:2048; *Bvb* 1:256; *Bk* 1:256). Although the *Bh* titer decreased from 1:4096 to 1:2048, an increase or decrease in IFA titer by one dilution is generally interpreted as clinically and microbiologically unchanged. Although coinfection with more than one *Bartonella* species was possible, the serology and PCR results supported *Bh* bacteremia with potential *Bvb* and *Bk* cross-reactivity. *M haemominutum* DNA was again PCR amplified from the cat's blood. Given the possibility of ongoing infection, particularly involving bone, antibiotic therapy with doxycycline and pradofloxacin was continued at the same dosages for another 6 weeks with the goals of complete elimination of *Bartonella* species bacteremia and documentation of seroreversion.

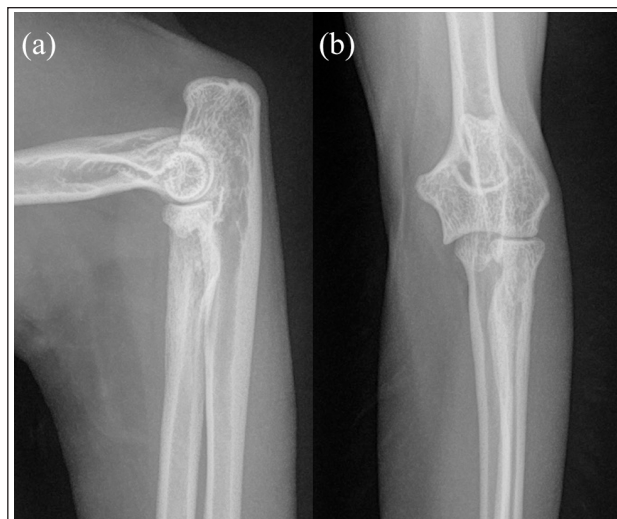


Figure 3 Orthogonal radiographs: (a) mediolateral view and (b) craniocaudal view taken 6 weeks after doxycycline and pradofloxacin administration. There was significant healing of the osteomyelitic lesion of the left radius. The lytic area in the proximal radial metaphysis and the cortical destruction were no longer noted with bone remodeling and resolution of the previously noted smooth-to-brush border new bone formation

During the subsequent 6 weeks, the cat remained clinically normal. Three months post-antibiotic therapy, radiographs illustrated complete resolution of the osteomyelitic lesion. Antibody titers (*Bh* 1:4096; *Bvb* 1:256; *Bk* 1:128) remained essentially unchanged. Persistent seroreactivity, in conjunction with negative *Bartonella* genus-specific *ssrA* qPCR, 16S–23S ITS region qPCR, PCR assays and resolution of clinical disease, was interpreted as a durable immune system memory response. Antibiotic therapy was discontinued. Ten months after diagnosis, the *Bh* IFA antibody titer was 1:1024 (four-fold decrease), *Bvb* was 1:16 and *Bk* was <1:16. *Bartonella* genus-specific *ssrA* qPCR, 16S–23S ITS region qPCR and PCR assays were again negative. *Bartonella* alpha proteobacteria growth medium (BAPGM) with qPCR testing¹² at 7, 14 and 21 days was also negative. Twelve months after the onset of illness, the cat was outwardly healthy with no residual lameness.

Discussion

Osteomyelitis secondary to systemic bartonellosis is a rare manifestation of a common infection in cats. To our knowledge, *Bh* bacteremia has not previously been associated with feline osteomyelitis. Primary differential diagnoses for a monostotic osteolytic and osteoproliferative lesion involving the metaphysis include infectious osteomyelitis and neoplasia. Based on PCR positivity and high IFA seroreactivity, *Bh* was presumably the pathogen that caused osteomyelitis in this young cat. Although contributing roles from *Bvb* and *Bk* were possible, the

late, negative convalescent serology results for these species supported *Bh* as the primary cause of osteomyelitis. While the cat remained bacteremic with *M haemominutum* despite antimicrobial treatment, this hemotropic *Mycoplasma* species is of relatively low pathogenicity and has not been implicated as a cause of osteomyelitis in cats.⁴

Owing to the frequency of subclinical bartonellosis, proof of disease causation in bacteremic cats remains challenging. Diagnosis can be supported by positive blood or tissue culture, seroconversion or seroreversion in association with compatible clinical findings and visualization of the organism in association with a pathological lesion.¹ While not widely documented in the literature, seroreversion in treated cats is noted in isolated reports, especially by use of Western blotting.⁶ In this case, the combination of positive PCR, high *Bh* seroreactivity and rapid clinical improvement after the initiation of appropriate antibiotics and seroreversion provided very strong, albeit indirect, evidence for diagnosis of bartonellosis in this cat. Very elevated *Bh* titers often correlate with positive PCR or blood culture results in sick cats.¹ In contrast, serology alone in chronically infected cats can be of low diagnostic yield as relapsing bacteremia has been documented in conjunction with low or non-detectable antibody titers, as also reported for dogs and humans.^{1,2} Seroconversion in acute bartonellosis in combination with seroreversion with directed antibiotic therapy provides microbiological support for the diagnosis, as documented by sero-reversion in this cat. Following an acute illness, *Bh* and *Bk* seroconversion over a 2-month period was documented in a dog, followed by seroreversion with combination antimicrobial therapy.¹³ In future feline cases, where osteomyelitis is suspected, obtaining aerobic, anaerobic and optimized *Bartonella* species enrichment cultures by aspiration or biopsy directly from the lesion would be recommended. Additionally, if biopsied, research laboratories can now visualize *Bartonella* species in diseased tissues using immunohistochemistry or in situ hybridization, which would provide more direct evidence of *Bartonella* species as a cause of osteomyelitis in cats.

Combination therapy with doxycycline and pradofloxacin should be considered in sick cats with systemic bartonellosis.¹ This approach achieves high intracellular and plasma concentrations, increasing the chance of suppressing active bacteremia and/or attaining therapeutic elimination of intracellular bacteria.¹ However, neither drug nor the combination of them guarantees infection cure.^{1,3} Prolonged therapy with a minimum duration of 6 weeks has been recommended for clinical remission, if not bacterial eradication. Given the broad antimicrobial

spectrum of doxycycline and pradofloxacin, a definitive diagnosis or a very high index of suspicion for bartonellosis is optimal before initiating treatment to avoid inducing antibiotic resistance. Treatment duration for bacterial osteomyelitis in dogs and cats is generally up to 8 weeks for oral antibiotic administration.¹⁴ In this cat, there was incomplete radiographic resolution of the osteomyelitic lesion 6 weeks post-antibiotic administration, so a further 6 weeks of treatment was recommended. Three months post-initiation of antibiotic therapy, despite persistently elevated antibody titers, treatment was discontinued due to clinical and radiographic resolution. While dogs can exhibit a significant decrease in antibody titers 3–6 months after successful elimination of the *Bh* and *Bvb*,⁵ the extent to which this holds true for cats is unclear. Therefore, sequential serology and BAPGM enrichment blood culture post-treatment were performed to assess completeness of pathogen elimination. Clinical remission and seroreversion, in conjunction with negative BAPGM enrichment blood culture results, provided support for therapeutic elimination of *Bh* in this cat.

Conclusions

Bartonellosis should be considered as a differential diagnosis in cats presenting with aggressive bone lesions and generalized lymphadenopathy.

Conflict of interest In conjunction with Dr Sushama Sontakke and North Carolina State University, Edward B Breitschwerdt, DVM holds US Patent No 7,115,385; Media and Methods for cultivation of microorganisms, which was issued October 3, 2006. He is a cofounder, shareholder and Chief Scientific Officer for Galaxy Diagnostics, a company that provides advanced diagnostic testing for the detection of *Bartonella* species infections. All other authors declare no potential conflicts of interest.

Funding The authors received no financial support for the research, authorship, and/or publication of this article.

Ethical approval The work described in this manuscript involved the use of non-experimental (owned or unowned) animals. Established internationally recognized high standards ('best practice') of veterinary clinical care for the individual patient were always followed and/or this work involved the use of cadavers. Ethical approval from a committee was therefore not specifically required for publication in *JFMS Open Reports*. Although not required, where ethical approval was still obtained it is stated in the manuscript.

Informed consent Informed consent (verbal or written) was obtained from the owner or legal custodian of all animal(s) described in this work (experimental or non-experimental animals, including cadavers) for all procedure(s) undertaken

(prospective or retrospective studies). No animals or people are identifiable within this publication, and therefore additional informed consent for publication was not required.

References

- 1 Alvarez-Fernandez A, Breitschwerdt EB and Solano-Gallego L. **Bartonella infections in cats and dogs including zoonotic aspects.** *Parasit Vectors* 2018; 11: 624. DOI: 10.1186/s13071-018-3152-6.
- 2 Sykes JE and Chomel BB. **Bartonellosis.** In: Sykes JE (ed). *Canine and feline infectious diseases.* St Louis, MO: Elsevier Saunders, 2014, pp 498–509.
- 3 Mazurek L, Winiarczyk S and Adaszek L. **Feline bartonellosis key issues and possible vectors.** *Ann Parasitol* 2018; 64: 309–315.
- 4 Barker EN. **Update on feline hemoplasmosis.** *Vet Clin North Am Small Anim Pract* 2019; 49: 733–743.
- 5 Breitschwerdt EB, Maggi RG, Chomel BB, et al. **Bartonellosis: an emerging infectious disease of zoonotic importance to animals and human beings.** *J Vet Emerg Crit Care (San Antonio)* 2010; 20: 8–30.
- 6 Breitschwerdt EB, Broadhurst JJ and Cherry NA. **Bartonella henselae as a cause of acute-onset febrile illness in cats.** *JFMS Open Rep* 2015; 1. DOI: 10.1177/2055116915600454.
- 7 Donovan TA, Balakrishnan N, Carvalho Barbosa I, et al. **Bartonella spp. as a possible cause or cofactor of feline endomyocarditis-left ventricular endocardial fibrosis complex.** *J Comp Pathol* 2018; 162: 29–42.
- 8 Lappin MRB and Black JC. **Bartonella spp infection as a possible cause of uveitis in a cat.** *J Am Vet Med Assoc* 1999; 214: 1205–1207.
- 9 Varanat M, Travis A, Lee W, et al. **Recurrent osteomyelitis in a cat due to infection with Bartonella vinsonii subsp. berkhoffi genotype II.** *J Vet Intern Med* 2009; 23: 1273–1277.
- 10 Ernst E, Quorollo B, Olech C, et al. **Bartonella rochalimae, a newly recognized pathogen in dogs.** *J Vet Intern Med* 2020; 34: 1447–1453.
- 11 Breitschwerdt EB, Maggi RG, Quach C, et al. **Bartonella spp. bloodstream infection in a Canadian family.** *Vector Borne Zoonotic Dis* 2019; 19: 234–241.
- 12 Duncan AW, Maggi RG and Breitschwerdt EB. **A combined approach for the enhanced detection and isolation of Bartonella species in dog blood samples: pre-enrichment liquid culture followed by PCR and subculture onto agar plates.** *J Microbiol Methods* 2007; 69: 273–281.
- 13 Golly E, Breitschwerdt EB, Balakrishnan N, et al. **Bartonella henselae, Bartonella koehlerae and Rickettsia rickettsii seroconversion and seroreversion in a dog with acute-onset fever, lameness, and lymphadenopathy followed by a protracted disease course.** *Vet Parasitol Reg Stud Reports* 2017; 7: 19–24.
- 14 Gieling F, Peters S, Erichsen C, et al. **Bacterial osteomyelitis in veterinary orthopaedics: pathophysiology, clinical presentation and advances in treatment across multiple species.** *Vet J* 2019; 250: 44–54.