



## **Resolution of megaesophagus after correction of a paraesophageal hernia**

Authors: Rolph, Kerry E, Ryan, John, Yool, Donald, and Liuti, Tiziana

Source: Journal of Feline Medicine and Surgery Open Reports, 9(2)

Published By: SAGE Publishing

URL: <https://doi.org/10.1177/20551169231199451>

---

BioOne Complete ([complete.BioOne.org](https://complete.BioOne.org)) is a full-text database of 200 subscribed and open-access titles in the biological, ecological, and environmental sciences published by nonprofit societies, associations, museums, institutions, and presses.

Your use of this PDF, the BioOne Complete website, and all posted and associated content indicates your acceptance of BioOne's Terms of Use, available at [www.bioone.org/terms-of-use](https://www.bioone.org/terms-of-use).

Usage of BioOne Complete content is strictly limited to personal, educational, and non - commercial use. Commercial inquiries or rights and permissions requests should be directed to the individual publisher as copyright holder.

---

BioOne sees sustainable scholarly publishing as an inherently collaborative enterprise connecting authors, nonprofit publishers, academic institutions, research libraries, and research funders in the common goal of maximizing access to critical research.



# Resolution of megaesophagus after correction of a paraesophageal hernia

Kerry E Rolph<sup>1</sup> , John Ryan<sup>2</sup>, Donald Yool<sup>3</sup> and Tiziana Liuti<sup>2</sup>

*Journal of Feline Medicine and Surgery Open Reports*  
1–5

© The Author(s) 2023

Article reuse guidelines:

sagepub.com/journals-permissions

DOI: 10.1177/20551169231199451

journals.sagepub.com/home/jfmsopenreports

This paper was handled and processed by the European Editorial Office (ISFM) for publication in *JFMS Open Reports*



## Abstract

**Case summary** A 6-year-old female Siamese cat presented with an 8-week history of vomiting and progressive hyporexia. On presentation, the cat was found to have a hypochloremic alkalosis. Imaging demonstrated hiatal hernia and megaesophagus. Exploratory laparotomy demonstrated a paraesophageal hiatal hernia. The hernia was reduced, phrenoplasty and esophagopexy were performed, and a gastrotomy tube was placed. Treatment of the hernia led to resolution of the megaesophagus.

**Relevance and novel information** Megaesophagus can occur secondarily to paraesophageal hernia in the cat. In this case, correction of the paraesophageal hernia led to complete resolution of the esophageal dilation and all associated clinical signs.

**Keywords:** Hiatal hernia; megaesophagus; paraesophageal; vomiting; hypochloremic alkalosis

**Accepted:** 19 August 2023

## Introduction

Abnormal esophageal function is reported in 1% of the referral cat population and can arise as a primary or secondary abnormality.<sup>1</sup> Clinical signs of esophageal disease occur when the esophageal motility is disturbed or when there is obstruction to the movement of ingesta. Cases typically present with regurgitation, although occasionally cats with esophagitis will present with ptyalism and lip smacking, dysphagia or aspiration pneumonia, either with or without overt signs of regurgitation.

Decreased or absent esophageal motility usually results in dilation (which is typically diffuse), known as megaesophagus. Megaesophagus can be congenital or acquired, with acquired disease being primary (idiopathic) or secondary to disease of the neuromuscular junction.

Congenital megaesophagus is rare in cats, with only sporadic cases having been reported.<sup>2,3</sup> Clinical signs are typically evident from a young age (3 months). Acquired megaesophagus of primary origin (idiopathic) has rarely been documented in cats. Two cases are reported in which concurrent gastroesophageal intussusception was present.<sup>4,5</sup> However, in neither case was there severe

esophagitis, and the megaesophagus did not resolve with successful treatment of the intussusception, leading to a diagnosis of idiopathic megaesophagus with secondary intussusception. In addition, one case has been reported in association with hypertrophic osteopathy.<sup>6</sup>

Secondary megaesophagus is the most common type of megaesophagus in the cat. Physical obstruction of the esophagus by aberrant vasculature is occasionally encountered.<sup>7–10</sup> Lesions of the central nervous system

<sup>1</sup>Center for Integrative Mammalian Research, Ross University School of Veterinary Medicine, Basseterre, St Kitts, West Indies

<sup>2</sup>Department of Clinical Sciences, Royal (Dick) School of Veterinary Studies, University of Edinburgh, Easter Bush, Roslin, Midlothian, UK

<sup>3</sup>Vets Now Emergency, Glasgow, UK

### Corresponding author:

Kerry E Rolph BVM&S, Cert VC, PhD, FANZCVS (Feline Chapter), DipECVIM-Ca, FRCVS, Center for Integrative Mammalian Research, Ross University School of Veterinary Medicine, Basseterre, St Kitts, West Indies  
Email: KRolph@rossvet.edu.kn



Creative Commons Non Commercial CC BY-NC: This article is distributed under the terms of the Creative Commons

Attribution-NonCommercial 4.0 License (<https://creativecommons.org/licenses/by-nc/4.0/>) which permits non-commercial use, reproduction and distribution of the work without further permission provided the original work is attributed as specified on the SAGE and Open Access pages (<https://us.sagepub.com/en-us/nam/open-access-at-sage>).

have not been reported to cause megaesophagus in cats. However, peripheral neuropathies are common causes of megaesophagus, with feline dysautonomia being reported frequently.<sup>11,12</sup> In feline dysautonomia, megaesophagus is typically one of a plethora of clinical signs (which may include mydriasis, dry eye, crusting of the nasal planum, aspiration pneumonia, lethargy, constipation or diarrhoea, urinary retention, collapse and bradycardia). Other causes of peripheral neuropathy, such as lead toxicosis, leading to megaesophagus have rarely been reported in cats.<sup>13</sup> Neuromuscular junctionopathies can also result in megaesophagus. Myasthenia gravis is occasionally seen in cats, with the Abyssinian (and Somali) being at increased risk,<sup>14,15</sup> although the disease is seen sporadically in other breeds of cat and has been reported to occur with cranial mediastinal mass.<sup>15,16</sup> Occasionally, megaesophagus is associated with severe esophagitis. This was considered to be the likely cause of megaesophagus in one report of a cat that presented with severe esophagitis after diaphragmatic hernia repair.<sup>17</sup> In addition, megaesophagus has been reported in association with upper respiratory obstruction/stenosis, with two cases documenting large nasopharyngeal polyps and associated megaesophagus,<sup>18,19</sup> one documenting nasopharyngeal stenosis with concurrent hiatal hernia and megaesophagus<sup>20</sup> and one case of megaesophagus with laryngeal paralysis and gastroesophageal intussusception.<sup>21</sup> All of these cases demonstrated resolution of the megaesophagus after the respiratory obstruction was treated.

This case report describes the first case of diffuse megaesophagus secondary to paraesophageal hiatal hernia, with complete resolution of esophageal dilation and clinical signs after surgical correction of the hernia.

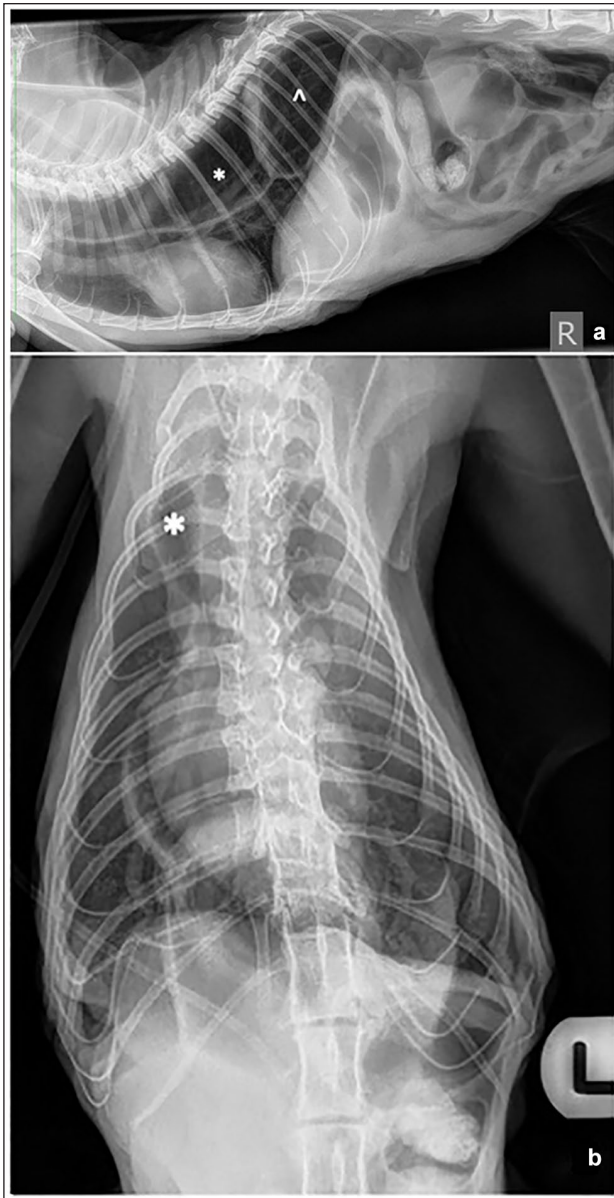
## Case description

A 6-year-old female intact, indoor only, Siamese cat presented with an 8-week history of vomiting, which was described as having progressively worsened over the duration of clinical signs. The vomitus was initially described as partly digested food. No dysphagia or regurgitation was noted by the owner. During the initial period, the cat continued to eat, but at presentation it was reported to have demonstrated hyporexia/anorexia for 2 weeks. During this time, the cat was reported to have 'vomited' clear fluid only. The cat was reported to demonstrate frequent episodic gagging. On examination, the cat was found to be markedly underweight (body condition score 2/9). She was dull and estimated to be approximately 8% dehydrated. Physical examination revealed mild bilateral enlargement of the mandibular lymph nodes and halitosis with stertorous pharyngeal sounds. Thoracic auscultation was unremarkable, heart rate was 160 bpm and respiratory rate was 36 bpm.

Abdominal palpation revealed cranial abdominal discomfort and gas-filled loops of intestine. The systolic blood pressure was 130 mmHg (Doppler). Blood samples were taken for acid-base, coagulation, complete blood count and serum biochemistry; these demonstrated mild alkalosis, pH 7.48 (reference interval [RI] 7.25–7.45), prolonged activated partial thromboplastin time (42.5 s, RI 10–20) and an elevated white blood cell count (WBC) ( $21.8 \times 10^9/l$ , RI  $7.0\text{--}20.0 \times 10^9/l$ ) due to neutrophilia ( $18 \times 10^9/l$ , RI  $2.5\text{--}12.8 \times 10^9/l$ ). The chloride was decreased (109 mmol/l, RI 117–140), as was the phosphate (0.85 mmol/l, RI 1.4–2.5) and albumin (22.4 g/l, RI 28–39), while the fibrinogen was increased (7.6 g/l, RI 2–4) and glucose (10.8 mmol/l, RI 3.3–5.0). Abdominal ultrasonography revealed a large volume of gas throughout the gastrointestinal tract, limiting the examination. The gastric wall and intestine demonstrated normal layering and thickness (0.21–0.27 mm). There was a small amount of non-shadowing, echogenic, gravity-dependent material within the gallbladder. The hepatic parenchyma and gallbladder wall were unremarkable. Both adrenal glands were mildly enlarged (width of 0.5 cm on the left and 0.54 cm on the right). In addition, there was a 2.25 cm-diameter anechoic, fluid-filled mass noted in the caudal abdominal cavity; this was thought to be an ovarian cyst. No other abnormalities were identified; however, full assessment was hindered by the presence of luminal gas.

Conscious radiographs of the thorax and cranial abdomen demonstrated an ovoid shape ( $5 \times 3$  cm in size) with gas-filled opacity surrounded by a thin, soft tissue wall, located in the caudodorsal thorax, between the aorta and the caudal vena cava; distension by gas of the esophagus was seen cranial to the previously described structure (Figure 1). There was marked and generalized gas distension of the small intestine; part of the stomach was still seen within the abdominal cavity. Based on the radiographic findings, a diagnosis of hiatal hernia was made with a potential differential of a gastro-esophageal intussusception.

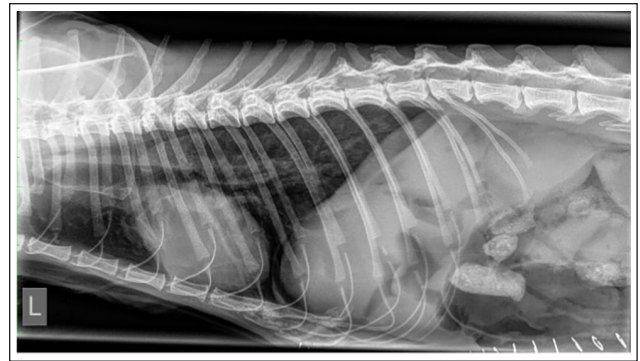In the light of the clinical progression, acid-base imbalances and static radiographic findings, emergency surgical exploration was advised. Before surgery the cat was placed on 0.9% normal saline, and both the pH and electrolytes were monitored closely. Surgical exploration identified a hiatal hernia, with the body of the stomach having entered the mediastinum via the esophageal hiatus, consistent with a type II hiatal hernia. The hernia was reduced, and phrenoplasty and esophagopexy was performed. In addition, a left-sided gastrostomy tube was placed. The cystic ovary was identified, and an ovariohysterectomy was performed. On recovery from anesthesia, thoracic radiography was repeated (Figure 2). There was no esophageal distension appreciable on the



**Figure 1** Right (a) lateral and (b) dorsoventral projection of the thorax and cranial abdomen. Note the gas distension of the thoracic esophagus (\*) and the ovoid shape with gas-filled opacity surrounded by a thin, soft tissue wall in the caudodorsal thoracic cavity (^). Note the marked and generalised gas distension of the small intestine

follow-up radiograph, and the gas-filled structure in the caudodorsal thorax was no longer visible. Free gas in the peritoneal space was seen secondarily to surgery.

Postoperatively, the cat was hospitalized for 10 days with the gastrotomy tube in place. However, during this time the tube was not used, as the cat started eating well, with no further vomiting.



**Figure 2** Postoperative left lateral thoracic radiograph. No esophageal distension is visible; the gas-filled structure in the caudodorsal thorax is no longer visible. Note free gas in the peritoneal space secondary to surgery

## Discussion

This is the first case report of megaesophagus arising secondary to primary type II hiatal hernia that resolved postoperatively. Previously, a case of megaesophagus secondary to nasopharyngeal stenosis with concurrent hiatal hernia was documented.<sup>20</sup> In that case, treatment of the nasopharyngeal stenosis resulted in resolution of the megaesophagus and hiatal hernia. In addition, one case of marked esophageal dilation with laryngeal paralysis and gastroesophageal intussusception<sup>21</sup> has been reported. However, in that case, treatment of the laryngeal paralysis resulted in resolution of the esophageal dilation and gastroesophageal intussusception. The case presented here demonstrated stertorous breathing and mild inflammation of the pharynx, but this was consistent with inflammation caused by chronic vomiting. There were no respiratory abnormalities observed after treatment of the hiatal hernia.

In this case, the presentation was for vomiting without regurgitation. However, it was noted that in the 2 weeks before presentation the nature of vomiting had altered, and during this time only clear liquid was expelled. Throughout this period, the cat was noted to have gagging episodes. It was suspected that the episodic regurgitation with the pharyngeal inflammation had led to some gagging, leading the owner to interpret these signs as vomiting rather than regurgitation.

In a series of 31 cases of feline hiatal hernia, mild esophageal dilatation with gas or fluid consistent with reflux and esophagitis was noted in 6 (19.4%) cats and none of the cats was reported to demonstrate marked esophageal dilation.<sup>22</sup> However, in that series, type II hiatal hernia was uncommon, being present in only 1/31 cases. Traditionally, all paraesophageal (type II–IV) hiatal hernias have been considered surgical emergencies, and despite recently changes

to the recommendations within the human literature, symptomatic cases of suspected paraesophageal hiatal hernia, which are deemed unstable, remain a surgical emergency due to the risk of incarceration or volvulus.<sup>23,24</sup>

It is uncertain why this case developed paraesophageal hiatal hernia. Ultrasonography demonstrated an ovarian cyst, which was thought to be an incidental finding, and bilateral adrenal enlargement (with the mean adrenal width in cats weighing less than 4 kg having been reported to be  $3.2 \pm 0.4$  mm<sup>25</sup>). However, the adrenomegaly was considered likely secondary to the cats' chronic illness, an assumption that is supported by a recent report of adrenomegaly (>4.8 mm) in critically ill cats.<sup>26</sup> Unfortunately, gastric biopsy results were not available, so underlying disease cannot be ruled out. However, the complete resolution of all clinical signs postoperatively is supportive of the hernia being causative, at least at the time of presentation.

There are no other reported cases of paraesophageal hernia associated with megaesophagus. However, other causes of obstructive gastrointestinal disease have been reported to cause megaesophagus in cats. Muscular hypertrophy leading to thickening of the pharyngeal and diaphragmatic musculature and a secondary megaesophagus has been seen in some advanced cases of hypertrophic myopathy in cats.<sup>27</sup> In addition, a case has been reported after a Billroth I gastroduodenostomy to remove a large mass later identified as lymphoma,<sup>28</sup> and two cases of megaesophagus have been reported in cats with pseudo-obstruction.<sup>29,30</sup> In the case reported here, it was suspected that the megaesophagus arose secondary to obstruction at the lower esophageal sphincter, resulting in dilation, and abnormal motility within the esophagus. Other potential causes, such as esophagitis, were considered less likely due to the rapid resolution that occurred after correction of the hiatal hernia. The rapid resolution also called into question whether this was a true megaesophagus or severe esophageal dilation (without abnormal motility); however, the generalized nature of the dilation and the persistent nature of the dilation (evidenced on multiple preoperative radiographs) led the authors to the conclusion that there was likely abnormal motility alongside dilation, suggestive of true megaesophagus.

## Conclusions

Megaesophagus secondary to hiatal hernia can occur in cats, and in some cases, management of the obstruction can result in resolution of the megaesophagus.

**Conflict of interest** The authors declared no potential conflicts of interest with respect to the research, authorship, and/or publication of this article.

**Funding** The authors disclosed receipt of the following financial support for the research, authorship, and/or publication of

this article: The authors received financial support for the publication of this article from Center for Integrative Mammalian Research, Ross University School of Veterinary Medicine.

**Ethical approval** The work described in this manuscript involved the use of non-experimental (owned or unowned) animals. Established internationally recognised high standards ('best practice') of veterinary clinical care for the individual patient were always followed and/or this work involved the use of cadavers. Ethical approval from a committee was therefore not specifically required for publication in *JFMS Open Reports*. Although not required, where ethical approval was still obtained, it is stated in the manuscript.

**Informed consent** Informed consent (verbal or written) was obtained from the owner or legal custodian of all animal(s) described in this work (experimental or non-experimental animals, including cadavers) for all procedure(s) undertaken (prospective or retrospective studies). For any animals or people individually identifiable within this publication, informed consent (either verbal or written) for their use in the publication was obtained from the people involved.

**ORCID ID** Kerry E Rolph  <https://orcid.org/0000-0002-4660-5676>

## References

- 1 Frowde PE, Battersby IA, Whittle NT, et al. **Oesophageal disease in 33 cats.** *J Feline Med Surg* 2011; 13: 564–569.
- 2 Clifford DH, Soifer FK, Wilson CF, et al. **Congenital achalasia of the esophagus in four cats of common ancestry.** *J Am Vet Med Assoc* 1971; 158: 1554–1560.
- 3 Hoenig M, Mahaffey MB, Parnell PG, et al. **Megaesophagus in two cats.** *J Am Vet Med Assoc* 1990; 196: 763–765.
- 4 van Geffen C, Saunders JH, Vandeveld B, et al. **Idiopathic megaesophagus and intermittent gastro-oesophageal intussusception in a cat.** *J Small Anim Pract* 2006; 47: 471–475.
- 5 Martinez NI, Cook W, Troy GC, et al. **Intermittent gastro-oesophageal intussusception in a cat with idiopathic megaesophagus.** *J Am Anim Hosp Assoc* 2001; 37: 234–237.
- 6 Mills J. **Hypertrophic istheopathy and megaesophagus in a cat.** *Vet Comp Orthop Traumatol* 2010; 23: 218–222.
- 7 Shannon D, Husnik R, Fletcher JM, et al. **Persistent right aortic arch with an aberrant left subclavian artery, Kommerell's diverticulum and bicarotid trunk in a 3-year-old cat.** *JFMS Open Rep* 2015; 1. DOI: 10.1177/2055116915614590.
- 8 Rossanese M, Cinti F, Chanoit GPA, et al. **Clinical findings, surgical treatment and long-term outcome of dogs and cats with double aortic arch: four cases (2005–2022).** *J Small Anim Pract* 2022; 63: 834–842.
- 9 Yarim M, Gültiken ME, Öztürk S, et al. **Double aortic arch in a Siamese cat.** *Vet Pathol* 1999; 36: 340–341.
- 10 Suzuki R, Mochizuki Y, Yoshimatsu H, et al. **Severe oesophageal constriction due to an aberrant right subclavian artery with Kommerell's diverticulum in a cat.** *JFMS Open Rep* 2018; 4. DOI: 10.1177/2055116918764589.
- 11 Novellas R, Simpson KE, Gunn-Moore DA, et al. **Imaging findings in 11 cats with feline dysautonomia.** *J Feline Med Surg* 2010; 12: 584–591.

- 12 Symonds HW, McWilliams P, Thompson H, et al. **A cluster of feline dysautonomia (Key-Gaskell Syndrome) in a closed colony of cats.** *Vet Rec* 1995; 136: 353–355.
- 13 Maddison JE and Allan GS. **Megaesophagus attributable to lead toxicosis in a cat.** *J Am Vet Med Assoc* 1990; 197: 1357–1358.
- 14 Shelton GD, Ho M and Kass PH. **Risk factors for acquired myasthenia gravis in cats: 105 cases (1986-1998).** *J Am Vet Med Assoc* 2000; 216: 55–57.
- 15 Hague DW, Humphries HD, Mitchell MA, et al. **Risk factors and outcomes in cats with acquired myasthenia gravis (2001-2012).** *J Vet Intern Med* 2015; 29: 1307–1312.
- 16 Day MJ. **Review of thymic pathology in 30 cats and 36 dogs.** *J Small Anim Pract* 1997; 38: 393–403.
- 17 Joseph R, Shadwick SR and Bennett AR. **Transient megaesophagus and oesophagitis following diaphragmatic rupture repair.** *J Feline Med Surg* 2008; 10: 284–290.
- 18 Byro JK, Shadwick SR and Bennett AR. **Megaesophagus in a 6-month old cat secondary to a nasopharyngeal polyp.** *J Feline Med Surg* 2010; 12: 322–324.
- 19 Itoh T, Nishi A, Uchida K, et al. **Resolution of megaesophagus after excision of a nasopharyngeal polyp in an 8-month-old cat.** *Jpn J Vet Anesth Surg* 2015; 46: 77–79.
- 20 DeSandre-Robinson DM, Madden SN and Walker JT. **Nasopharyngeal stenosis with concurrent hiatal hernia and megaesophagus in an 8-year-old cat.** *J Feline Med Surg* 2011; 13: 454–459.
- 21 Tayler S, Mullowney D, Lataretu A, et al. **Gastroesophageal intussusception and extreme esophageal dilatation secondary to bilateral laryngeal paralysis in a cat.** *J Vet Intern Med* 2021; 35: 1088–1092.
- 22 Duffy EC, Griffin S, O’Connell EM, et al. **Clinical, computed tomographic and histopathological findings in two cats with pulmonary fibrosis of unknown aetiology.** *JFMS Open Rep* 2020; 6. DOI: 10.1177/2055116920968723.
- 23 Mazer L and Telem DA. **Paraesophageal hernia: current management.** *Adv Surg* 2021; 55: 109–122.
- 24 Sivacolundhu RK, Read RA and Marchevsky AM. **Hiatal hernia controversies—a review of pathophysiology and treatment options.** *Aust Vet J* 2002; 80: 48–53.
- 25 Pérez-López L, Wägner AM, Saavedra P, et al. **Ultrasonographic evaluation of adrenal gland size in two body weight categories of healthy adult cats.** *J Feline Med Surg* 2021; 23: 804–808.
- 26 Oliveira J, Dias MJ, Fontes AP, et al. **Ultrasonographic detected adrenomegaly in clinically ill cats: a retrospective study.** *Vet Sci* 2022; 9: 420. DOI: 10.3390/vetsci9080420.
- 27 Gashen FP, Hoffman EP, Gorospe JR, et al. **Dystrophin deficiency causes lethal muscle hypertrophy in cats.** *J Neurol Sci* 1992; 110: 149–159.
- 28 Shimamura S, Shimizu M, Kobayashi M, et al. **Megaesophagus was complicated with Billroth I gastroduodenostomy in a cat.** *J Vet Med Sci* 2005; 67: 935–937.
- 29 Mortier J, Elissalt E, Palierne S, et al. **Chronic intestinal pseudo-obstruction associated with enteric ganglionitis in a Persian cat.** *JFMS Open Rep* 2016; 2. DOI: 10.1177/2055116916655173.
- 30 Imai DM, Miller JL, Leonard BC, et al. **Visceral smooth muscle  $\alpha$ -actin deficiency associated with chronic intestinal pseudo-obstruction in a Bengal cat (*Felis catus x Prionailurus bengalensis*).** *Vet Pathol* 2014; 51: 612–618.