



## Effect of diazoxide on a cat with insulinoma

Authors: Sato, Shiori, Hori, Koji, Tanabe, Gaku, Maeda, Shingo, Momoi, Yasuyuki, et al.

Source: Journal of Feline Medicine and Surgery Open Reports, 10(1)

Published By: SAGE Publishing

URL: <https://doi.org/10.1177/20551169231220290>

---

BioOne Complete ([complete.BioOne.org](https://complete.BioOne.org)) is a full-text database of 200 subscribed and open-access titles in the biological, ecological, and environmental sciences published by nonprofit societies, associations, museums, institutions, and presses.

Your use of this PDF, the BioOne Complete website, and all posted and associated content indicates your acceptance of BioOne's Terms of Use, available at [www.bioone.org/terms-of-use](https://www.bioone.org/terms-of-use).

Usage of BioOne Complete content is strictly limited to personal, educational, and non - commercial use. Commercial inquiries or rights and permissions requests should be directed to the individual publisher as copyright holder.

---

BioOne sees sustainable scholarly publishing as an inherently collaborative enterprise connecting authors, nonprofit publishers, academic institutions, research libraries, and research funders in the common goal of maximizing access to critical research.



# Effect of diazoxide on a cat with insulinoma

Shiori Sato<sup>1</sup>, Koji Hori<sup>2</sup>, Gaku Tanabe<sup>3</sup>,  
Shingo Maeda<sup>1,2</sup> , Yasuyuki Momoi<sup>1,2</sup>   
and Tomohiro Yonezawa<sup>1,2</sup>

*Journal of Feline Medicine and Surgery Open Reports*  
1–5

© The Author(s) 2024

Article reuse guidelines:

sagepub.com/journals-permissions

DOI: 10.1177/20551169231220290

journals.sagepub.com/home/jfmsopenreports

This paper was handled and processed by the European Editorial Office (ISFM) for publication in *JFMS Open Reports*



## Abstract

**Case summary** The patient was a castrated male American Shorthair cat, approximately 14 years old, weighing 3.4 kg. The patient had chronic kidney disease (CKD) (International Renal Interest Society stages 3–4) as an underlying disease. The cat was examined at a hospital for intermittent lethargy and seizures. Hypoglycaemia was repeatedly observed, and the insulin level was 1.78 ng/ml (reference interval 0.27–0.69) when the blood glucose was 49 mg/dl. Although the cat was tentatively diagnosed with insulinoma, surgery was not recommended because of the severe CKD. Although frequent feeding and prednisolone treatment were initially attempted, blood glucose decreased to 24–42 mg/dl. Diazoxide was additionally prescribed at a dose of 5.2 mg/kg q12h. The cat's clinical signs improved, and the blood glucose was in the range of 75–103 mg/dl during the first 2 months. It was maintained at >50 mg/dl until the patient died of renal failure 161 days after the start of diazoxide treatment. With regard to adverse events, vomiting once every 2–3 days without weight loss and non-regenerative anaemia were observed, which might have been at least partially caused by diazoxide treatment. An insulinoma was definitively diagnosed via pathological autopsy.

**Relevance and novel information** This is the first reported case of long-term treatment with diazoxide in a cat with insulinoma. Since it was effective in situations where conventional therapies were unsuccessful, diazoxide could be useful as a new therapeutic option for cats with insulinoma. Since adverse events, such as progression of vomiting frequency and non-regenerative anaemia, were observed, careful monitoring was required during administration.

**Keywords:** Adverse effect; diazoxide; fructosamine; hypoglycaemia; insulinoma

**Accepted:** 27 November 2023

## Case description

The patient was a castrated male American Shorthair cat, approximately 14 years old, weighing 3.4 kg. The cat had chronic kidney disease (CKD) for at least 2 years and was classified as International Renal Interest Society stage 3 approximately 1 month prior. The cat was treated with the prostacyclin analogue beraprost sodium (Rapros; Toray Industries) at a dose of 55 µg q12h PO and fluid replacement therapy (60 ml of lactated Ringer's solution) every other day. The patient was prescribed oral diazepam (diazepam tablets TOWA; Towa Pharma International Holdings) at a dose of 0.147 mg/kg as needed to stimulate its appetite. On day 1, the patient was admitted to the hospital for intermittent lethargy, wobbling for a month and a generalised seizure 3 days

before admission. Physical examination revealed a body condition score of 2/5, with mild dehydration. Blood examinations were conducted using a Dimension EXL

<sup>1</sup>Veterinary Medical Center, Graduate School of Agricultural and Life Sciences, University of Tokyo, Tokyo, Japan

<sup>2</sup>Department of Veterinary Clinical Pathobiology, Graduate School of Agricultural and Life Sciences, University of Tokyo, Tokyo, Japan

<sup>3</sup>Gleen Animal Clinic, Tokyo, Japan

### Corresponding author:

Tomohiro Yonezawa DVM, PhD, Department of Veterinary Pathobiology, Graduate School of Agricultural and Life Sciences, University of Tokyo, 1-1-1 Yayoi, Bunkyo-ku, Tokyo 113-8657, Japan  
Email: tomohiro.yonezawa@gmail.com



Creative Commons Non Commercial CC BY-NC: This article is distributed under the terms of the Creative Commons

Attribution-NonCommercial 4.0 License (<https://creativecommons.org/licenses/by-nc/4.0/>) which permits non-commercial use, reproduction and distribution of the work without further permission provided the original work is attributed as specified on the SAGE and Open Access pages (<https://us.sagepub.com/en-us/nam/open-access-at-sage>).

200 (Siemens) and a ProCyt Dx analyser (IDEXX Laboratories). The results are presented in Table 1 and Figure 1. The cat was hypoglycaemic, with findings consistent with renal failure (blood urea nitrogen [BUN] >140mg/dl; creatinine [CRE] 6.17mg/dl). Non-regenerative anaemia (haematocrit [HCT] 24%; haemoglobin [HGB] 7.4g/dl) was also detected. The patient's blood glucose level was 64mg/dl. Thoracic radiography and abdominal ultrasonography revealed no significant abnormalities except for bilateral renal atrophy. Based on the results of these clinical tests, daily fluid therapy and an injection of darbepoetin alpha (5.0µg IM, Nesp Injection Plastic Syringe; Kyowa Kirin Frontier) were administered to improve the clinical signs of CKD.

The patient revisited the hospital on days 6 and 8. Although the levels of HGB, HCT, BUN and CRE improved, clinical signs, such as lethargy and wobbling, did not improve. The blood glucose level was 49mg/dl on day 8, and the insulin level was 1.78ng/ml (reference interval [RI] 0.27–0.69ng/ml; Fuji Film Vet Systems). The amended insulin:glucose ratio (AIGR) was 24.5. The RI for AIGR has not been established for cats, but a cut-off level for dogs (<30.0) has been applied to prior cat cases, albeit without documentation.<sup>1</sup> Furthermore, the actual value ideally would be established by each reference laboratory. Taken together, insulinoma was suspected in this case. Frequent feeding for over five times/day and prednisolone at a dose of 0.67mg/kg were started on day 8. Although the blood glucose level initially increased (81mg/dl on day 10), the hypoglycaemia progressively became more severe several weeks later. Although prednisolone was increased to a dose of 1.34mg/kg/day, the blood glucose level was 24mg/dl, and the fructosamine level was approximately the lower limit of normal at 177µmol/l (RI 172–349; Fuji Film Vet Systems). On day 33, an isoechoic nodular mass measuring 6.2×6.6mm was observed in the pancreatic body (Figure 2).

After informed consent was obtained from the owner, diazoxide (diazoxide capsule 'OP'; OrphanPacific) was additionally prescribed at a dose of 5.2mg/kg q12h, which is known as a starting dose for dogs and ferrets.<sup>2</sup> After starting diazoxide medication, the cat's activity improved, and neurological abnormalities, such as wobbling and seizures, completely disappeared. Hypoglycaemia also improved. On day 45, 13 days after the start of diazoxide treatment, the blood glucose level was 103mg/dl. On days 51–93, which were 19–61 days later, the blood glucose level was in the range of 73–105mg/dl. The fructosamine level increased to 230µmol/l on day 65. Subsequently, the blood glucose and fructosamine levels gradually decreased but were still maintained at over 50mg/dl and 200µmol/l, respectively, until day 170.

Several adverse events were observed during diazoxide treatment. The patient continued to experience intermittent vomiting once every 2–3 days. Non-regenerative anaemia (HCT 18% and HGB 7.0g/dl) was apparent 19 days after starting diazoxide treatment, whereas the respective values had been 32.3% and 11.6g/dl before treatment. Anaemia was controlled by a subcutaneous injection of darbepoetin alpha. Loss of appetite and anorexia related to diazoxide administration were not observed.

Weight loss persisted, and dehydration occurred intermittently throughout the observation period. Blood CRE concentrations gradually increased, and oliguria/anuria developed on day 190. The cat died on day 193, which was 161 days after the start of diazoxide administration. A pathological autopsy revealed one visible nodule and several small nodules in the pancreatic body. Immunohistochemistry of the pancreatic nodules showed staining for chromogranin A and insulin, indicating insulinoma as the definitive diagnosis. Renal atrophy, sclerosis of the glomeruli, severe fibrosis of the medulla and cortex, and infiltration of inflammatory cells were observed in both kidneys.

## Discussion

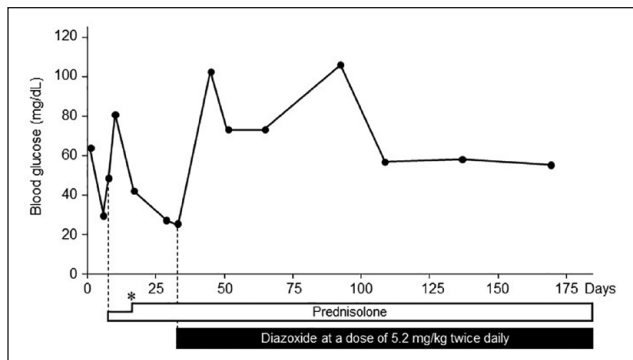
Feline insulinoma is a rare disease, with only a few cases reported.<sup>1,3–5</sup> A definitive diagnosis of insulinoma was established by histological confirmation.<sup>6,7</sup> Although clinically specific indicators for a definitive diagnosis have not been established in veterinary medicine,<sup>8</sup> a physiologically inappropriate normal-to-high insulin concentration in the presence of hypoglycaemia is considered the most accurate criterion for a preliminary diagnosis in dogs.<sup>7</sup> Standard diagnostic criteria for cats are yet to be established. In the present case, a definitive diagnosis was made via autopsy. Although AIGR, fructosamine and glycoalbumin (RI 8.5–16.5%; Fuji Film Vet Systems) in this case were approximately the lower limit of the RI, a high level of insulin with hypoglycaemia was observed. These results suggest that it is difficult to establish clear diagnostic criteria for feline insulinoma and that it is necessary to make a comprehensive assessment for the ante-mortem diagnosis of feline insulinoma.

Although diazoxide has been used in dogs with insulinomas that do not respond to dietary management and prednisone,<sup>9,10</sup> its use has not been reported in cats, except for one case report of administration to a single cat. In the report, diazoxide was administered to a cat at a dose of 5mg/kg q12h.<sup>1</sup> Hypoglycaemia improved rapidly 8h after treatment. However, the medication was discontinued because of severe loss of appetite immediately after administration. In the present case, continuous administration was tolerated for more than 5

**Table 1** The history of blood examination results in the present case

Clinical days	Days after tentative diagnosis of insulinoma	Days after the start of diazoxide administration	Body weight (kg)	HCT (%)	RBC (M/ $\mu$ l)	HGB (g/dl)	MCV (fl)	MCH (pg)	HCHC (g/dl)	WBC (K/ $\mu$ l)	PLT (K/ $\mu$ l)	GLU (mg/dl)	FRT ( $\mu$ mol/l)	GA (%)	BUN (mg/dl)	CRE (mg/dl)	Urinalysis (USG)	Notes
(-27)	-	-	3.7	31.7	7.6	10.4	41.5	13.6	32.8	16.0	82.0	-	-	-	52	2.96	-	The cat was diagnosed with CKD IRIS stage 3
1	-	-	3.6	23.3	4.8	7.4	48.5	15.4	31.8	17.9	369.0	64	-	-	140	6.17	-	The cat was diagnosed with CKD IRIS stage 4. Dalbepoetin alpha was injected
6	-	-	3.6	40.1	7.7	12.4	52.4	16.2	30.9	10.0	260.0	29	-	-	104	5.35	-	The insulin level was 1.79 ng/ml. The cat was tentatively diagnosed with an insulinoma. Frequent feeding and prednisolone were started
8	1	-	3.5	42.9	8.3	12.8	51.9	15.5	29.8	14.2	194.0	49	-	-	-	-	-	
10	3	-	3.5	43.4	8.5	13.2	51.2	15.6	30.4	12.1	159.0	81	-	-	96	4.41	-	
17	10	-	3.5	42.8	9.0	13.9	47.7	15.5	32.5	15.1	575.0	42	-	-	109	4.86	-	
29	22	-	3.4	37.1	8.4	12.1	44.4	14.5	32.6	23.5	233.0	27	-	-	84	3.69	-	
33	26	1	3.5	32.3	7.3	11.6	44.3	15.9	35.9	12.6	225.0	24	177	7.8	103	3.94	1.010	Diazoxide was started
45	38	13	3.3	26.8	6.4	8.9	42.1	14.0	33.2	16.2	358.0	103	-	-	90	3.68	-	
51	44	19	3.3	18.8	4.6	7.0	41.1	15.3	37.2	11.1	207.0	73	194	11.4	82	3.78	-	Dalbepoetin alpha was injected
65	58	33	3.4	23.1	5.4	8.4	42.7	15.5	36.4	11.6	252.0	73	269	11.8	107	4.01	-	
93	86	61	3.4	17.5	4.1	6.3	42.4	15.3	36.0	12.6	188.0	105	230	11.1	111	4.36	-	Dalbepoetin alpha was injected
109	102	77	3.2	27.1	6.4	9.7	42.5	15.2	35.8	12.2	323.0	56	235	10.0	69	3.26	-	
138	131	106	3.1	23.8	5.3	8.1	45.1	15.3	34.0	14.0	277.0	58	200	9.3	100	4.67	-	
170	163	138	3.0	17.6	4.0	6.1	43.6	15.1	34.7	15.4	246.0	55	208	9.7	129	5.19	-	Dalbepoetin alpha was injected
193	186	161	2.3	-	-	-	-	-	-	-	-	-	-	-	-	-	-	The cat died

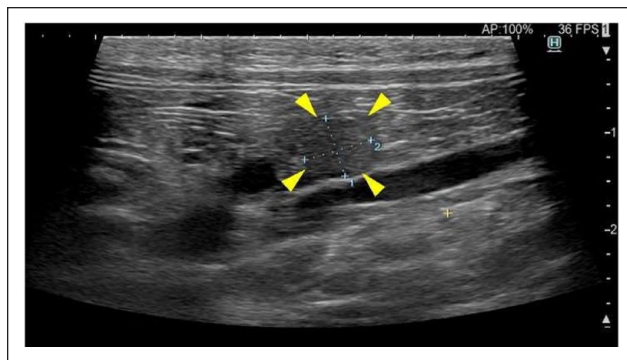
BUN = blood urea nitrogen; CKD = chronic kidney disease; CRE = creatinine; FRT = fructosamine; GA = glycoalbumin; GLU = blood glucose; HCT = haematocrit; HGB = haemoglobin; K = x 1000; IRIS = International Renal Interest Society; M = x 1,000,000; MCH = mean corpuscular haemoglobin; MCHC = mean corpuscular haemoglobin concentration; MCV = mean corpuscular volume; PLT = platelet count; RBC = red blood cell count; USG = urine specific gravity; WBC = white blood cell count



**Figure 1** Blood glucose levels of the patient throughout the observation periods. The white and black bars under the graph show the prednisolone and diazoxide treatment period. An asterisk indicates the date of dose increase of prednisolone from 0.67 to 1.5 mg/kg/day

months. To the best of our knowledge, this is the first case report of long-term treatment with diazoxide in a cat with hypoglycaemia. Blood glucose, fructosamine and glycoalbumin levels, as well as clinical signs associated with hypoglycaemia, improved throughout the observation period. Moreover, diazoxide was effective in situations where conventional therapies, such as frequent feeding and prednisolone, were ineffective. These results suggest that diazoxide could be considered a new therapeutic option for insulinoma in cats. In this patient, it was used at the starting dose for dogs and ferrets,<sup>2</sup> and dose increase or reduction was not attempted. Therefore, an appropriate dose for cats should be established in future studies.

Several reviews have documented the adverse effects of diazoxide. According to the client information sheet provided by the British Small Animal Veterinary Association, diazoxide can cause loss of appetite, vomiting and diarrhoea.<sup>11</sup> In a previous case report involving cats, treatment was discontinued because of severe appetite loss immediately after the first administration.<sup>1</sup> In any case, attention should be paid to the side effects related to the upper gastrointestinal tract, such as nausea, vomiting and anorexia. Although vomiting once every 2–3 days was observed immediately after starting the medication in the present patient, the clinical signs were not severe enough to impair the cat's quality of life. Since mild vomiting 2–3 times weekly is expected in a cat with kidney failure, there is no reliable indication that this coincided with the start of diazoxide treatment. In addition, loss of appetite related to the diazoxide treatment was not observed in this case. The patient had been prescribed an appetite stimulant, such



**Figure 2** Ultrasound image of the present case. An isoechoic nodular mass measuring 6.2 × 6.6 mm was observed in the pancreatic body (arrowheads)

as diazepam, for loss of appetite caused by CKD for at least 6 months. Considering this background, it could not be precisely evaluated whether diazoxide caused a reduction in appetite in this case; therefore, it is suggested that appetite stimulants could be useful for the loss of appetite caused by diazoxide. In another review, liver, kidney and/or heart failure were considered contraindications for the use of diazoxide in dogs.<sup>7</sup>

Association with aplastic anaemia is also described in a textbook.<sup>12</sup> These backgrounds support that the significant drop in haematocrit and haemoglobin after initiating diazoxide treatment in the cat could be adverse effects of diazoxide. They also could have been due to a simultaneous rapid diminution in renal function. The medical literature suggests that the diazoxide dose should be reduced in patients with renal failure.<sup>13</sup> In this case, a low dosage was initiated and not increased, and the CKD was carefully monitored. Unfortunately, the precise assessment of CKD progression using blood pressure measurement or urinalysis was not performed. While there is a high possibility that diazoxide could have driven the progression of renal failure, it is hard to draw conclusions because this case had already severe CKD before treatment.

## Conclusions

The long-term administration of diazoxide has been shown to be useful for improving blood glucose levels in cats with insulinoma and CKD.

Non-regenerative anaemia and vomiting frequency progressed after diazoxide treatment and could have been partially a side effect of the medication. It is necessary to prescribe diazoxide very cautiously, while monitoring the haemogram and renal function.


**Conflict of interest** The authors declared no potential conflicts of interest with respect to the research, authorship, and/or publication of this article.

**Funding** This work was supported by JSPS KAKENHI (grant number 21H02355).

**Ethical approval** The work described in this manuscript involved the use of non-experimental (owned or unowned) animals. Established internationally recognised high standards ('best practice') of veterinary clinical care for the individual patient were always followed and/or this work involved the use of cadavers. Ethical approval from a committee was therefore not specifically required for publication in *JFMS Open Reports*. Although not required, where ethical approval was still obtained, it is stated in the manuscript.

**Informed consent** Informed consent (verbal or written) was obtained from the owner or legal custodian of all animal(s) described in this work (experimental or non-experimental animals, including cadavers) for all procedure(s) undertaken (prospective or retrospective studies). For any animals or people individually identifiable within this publication, informed consent (verbal or written) for their use in the publication was obtained from the people involved.

**ORCID iD** Shingo Maeda  <https://orcid.org/0000-0003-1413-1258>

Yasuyuki Momoi  <https://orcid.org/0000-0002-6211-8704>

Tomohiro Yonezawa  <https://orcid.org/0000-0003-3457-9295>

## References

- Kornya M, Abrams-Ogg A, Comeau D, et al. **Juvenile hyperinsulinism in a Maine Coon kitten.** *JFMS Open Rep* 2022; 23: DOI: 10.1177/20551169221136473.
- Idowu O and Heading K. **Hypoglycemia in dogs: causes, management, and diagnosis.** *Can Vet J* 2018; 59: 642–649.
- Hawks D, Peterson ME, Hawkins KL, et al. **Insulin-secreting pancreatic (islet cell) carcinoma in a cat.** *J Vet Intern Med* 1992; 6: 193–196.
- Kraje AC. **Hypoglycemia and irreversible neurologic complications in a cat with insulinoma.** *J Am Vet Med Assoc* 2003; 223: 812–814, 810.
- Greene SN and Bright RM. **Insulinoma in a cat.** *J Small Anim Pract* 2008; 49: 38–40.
- Schaub S and Wigger A. **Ultrasound-aided diagnosis of an insulinoma in a cat.** *Tierarztl Prax Ausg K Kleintiere Heimtiere* 2013; 41: 338–342.
- Buishand FO. **Current trends in diagnosis, treatment and prognosis of canine insulinoma.** *Vet Sci* 2022; 9. DOI: 10.3390/vetsci9100540.
- Thompson JC. **Differential diagnosis of tumour-associated hypoglycaemia in small animals.** *N Z Vet J* 1994;42: 77. DOI: 10.1080/00480169.1994.36539.
- Leifer C, Peterson M and Matus R. **Insulin-secreting tumor: diagnosis and medical and surgical management in 55 dogs.** *J Am Vet Med Assoc* 1986; 188: 60–64.
- Tobin R, Nelson R, Lucroy M, et al. **Outcome of surgical versus medical treatment of dogs with beta cell neoplasia: 39 cases (1990–1997).** *J Am Vet Med Assoc* 1999; 215: 226–230.
- BSAVA. **Diazoxide.** Client information leaflet. <https://www.bsavalibrary.com/content/dataitem/canine-and-feline/diazoxide> (2014, accessed 6 June 2023).
- Nelson RW. **Beta-cell neoplasia: insulinoma.** In: Feldman EC, Nelson RW, Reusch CE., et al. (eds). *Canine and feline endocrinology* 4th ed. St. Louis, MO: Elsevier Saunders, 2015, pp 348–375.
- Neonatal Medicines Formulary Consensus Group, Australia. **Diazoxide.** [https://www.slhd.nsw.gov.au/RPA/neonatal%5Ccontent/pdf/Medications\\_Neomed/Diazoxide\\_Neomed.pdf](https://www.slhd.nsw.gov.au/RPA/neonatal%5Ccontent/pdf/Medications_Neomed/Diazoxide_Neomed.pdf) (2016, accessed 6 June 2023).