



Total hip replacement in a cat with contralateral pelvic limb amputation

Authors: Bourbos, Alexandros, Piana, Francesco, and Langley-Hobbs, Sorrel Judith

Source: Journal of Feline Medicine and Surgery Open Reports, 10(1)

Published By: SAGE Publishing

URL: <https://doi.org/10.1177/20551169241232297>

BioOne Complete (complete.BioOne.org) is a full-text database of 200 subscribed and open-access titles in the biological, ecological, and environmental sciences published by nonprofit societies, associations, museums, institutions, and presses.

Your use of this PDF, the BioOne Complete website, and all posted and associated content indicates your acceptance of BioOne's Terms of Use, available at www.bioone.org/terms-of-use.

Usage of BioOne Complete content is strictly limited to personal, educational, and non - commercial use. Commercial inquiries or rights and permissions requests should be directed to the individual publisher as copyright holder.

BioOne sees sustainable scholarly publishing as an inherently collaborative enterprise connecting authors, nonprofit publishers, academic institutions, research libraries, and research funders in the common goal of maximizing access to critical research.



Total hip replacement in a cat with contralateral pelvic limb amputation

Alexandros Bourbos, Francesco Piana 
 and Sorrel Judith Langley-Hobbs 

Journal of Feline Medicine and Surgery Open Reports
 1–6

© The Author(s) 2024

Article reuse guidelines:

sagepub.com/journals-permissions

DOI: 10.1177/20551169241232297

journals.sagepub.com/home/jfmsopenreports

This paper was handled and processed by the European Editorial Office (ISFM) for publication in *JFMS Open Reports*



Abstract

Case summary A 10-year-old male neutered domestic shorthair cat, which had previously had its contralateral pelvic limb amputated, was treated for coxofemoral degenerative joint disease (DJD) with a total hip replacement. The long-term outcome was favourable and no complications were recorded. Interestingly, the contralateral coxofemoral joint left at the time of the previous amputation developed DJD and became a source of pain for the cat and was subsequently excised.

Relevance and novel information This case report shows that total hip replacement is a viable option in cats with coxofemoral DJD and a contralateral limb amputation. Retained joints in amputated limbs may develop osteoarthritis and be a source of pain for a cat.

Keywords: Total hip replacement; amputee; degenerative joint disease; orthopaedic surgery

Accepted: 26 January 2024

Introduction

Diseases and injuries of the hip joint are common in cats.^{1–3} Total hip replacement (THR) is the gold standard treatment for debilitating conditions affecting the coxofemoral joint in both humans and small animals.^{4–7} In a retrospective case series of nine pelvic limb amputee dogs undergoing THR, amputation of the contralateral pelvic limb was reported to be a relative contraindication for THR as the reported complications were higher in that study than normally reported after THR.⁸ The present report aimed to describe an amputee cat that underwent THR at our institution. To the best of the authors' knowledge, there are no peer-reviewed reports on THR in cats with an amputated contralateral pelvic limb.

Case description

A 10-year-old, 3.92 kg, male neutered, domestic shorthair cat was referred for evaluation of a left pelvic limb lameness. There was a history of comminuted phalangeal fractures and talocrural luxation of the right pelvic limb when the cat was aged 5 months. Amputation was performed at that time, at the level of the proximal

third of the femur, with preservation of the right coxofemoral joint.

On presentation at our institution, the cat was in good general health, with a body condition score of (5/9). Its overall mobility was severely restricted, with the cat walking for only two or three steps before sitting down. Marked pain and a reduced range of motion was elicited on manipulation, particularly extension, of the left coxofemoral joint. There was also resentment of any palpation and manipulation of the right coxofemoral joint. There was moderate swelling affecting the caudomedial aspect of the right elbow. No other significant abnormalities were detected. The cat was sedated with dexmetomidine hydrochloride (Dexdomitor; Vetoquinol; 5 µg/kg IV and butorphanol (Dolorex; MSD Animal Health; 0.3 mg/kg IV) and radiographic evaluation was

Langford Veterinary Hospital – University of Bristol, Langford, Bristol, UK

Corresponding author:

Alexandros Bourbos DVM, DipECVS, MRCVS, Langford Veterinary Hospital – University of Bristol, Langford, Bristol, UK
 Email: alxbourbos@yahoo.gr



Creative Commons Non Commercial CC BY-NC: This article is distributed under the terms of the Creative Commons

Attribution-NonCommercial 4.0 License (<https://creativecommons.org/licenses/by-nc/4.0/>) which permits non-commercial use, reproduction and distribution of the work without further permission provided the original work is attributed as specified on the SAGE and Open Access pages (<https://us.sagepub.com/en-us/nam/open-access-at-sage>).

performed (Figure 1). The radiographs showed marked left and right coxofemoral osteoarthritis with periarticular osteophytosis. Elbow radiographs showed moderate new bone formation medial to the right elbow, suggestive of flexor tendon enthesopathy, and periarticular bony changes affecting both elbows consistent with osteoarthritic change. Based on these clinical and radiographic findings, and after discussion with the owners, a decision was made to perform a left total hip replacement. The cat was discharged home and returned 7 weeks later for surgery.

On re-presentation, the cat was premedicated with dexmetomidine hydrochloride (5 µg/kg IV) and methadone (Methadyne; Jurox; 0.2 mg/kg IV) and anaesthesia was induced with propofol (PropoFlo; Zoetis, 1 mg/kg IV). Anaesthesia was maintained with 2% isoflurane (Isoflurane; Piramal Critical Care) in oxygen. Cefuroxime (Zinacef; Glaxo Smith Kline) 20 mg/kg was administered 30 mins before skin incision and repeated thereafter every 90 mins. Epidural analgesia was provided with bupivacaine (Marcain Polyamp Steripack; Aspen Pharma; 1 mg/kg). A standard craniolateral approach was performed to the left hip as previously described.⁹ The THR was performed routinely and a 12 mm cemented fixation (CFX) acetabular cup was placed. The intention was to insert the cup in a more closed position than normal to reduce the chance of luxation due to the contralateral hindlimb amputation and therefore an expected higher hip joint load. During the reaming of the femoral canal, a very small fissure was noted on the proximal medial aspect of the femur. To avoid propagation of the fissure, three cerclage wires using 1 mm diameter (20 G) orthopaedic wire were applied to the proximal femur. A 3 mm CFX stem was applied after the femoral canal was filled with low-viscosity polymethylmethacrylate (PMMA) bone cement. A +2 femoral head was selected to minimise laxity at the head-cup interface. Wound closure was routinely performed. Radiographs of the coxofemoral joint were obtained postoperatively (Figure 2).

The cat was hospitalised for the next 48 h, and analgesia was provided with methadone 0.2 mg/kg q4h. Cefuroxime (20 mg/kg) was continued intravenously every 8 h for the next 24 h postoperatively. Robenacoxib (Onsior; Elanco) was administered subcutaneously during the hospitalisation period at 1 mg/kg q24h for 3 days, and then it was continued orally at home. Cephalexin (Rilexine; Virbac; 20 mg/kg) was administered orally for 5 days postoperatively. Follow-up radiographs 6 weeks after surgery were performed at the referring veterinary clinic (Figure 3); these showed stable implants and progression of bony healing. No complications were recorded in the postoperative period (follow-up 30 months). The Feline Musculoskeletal Pain Index was used to keep track of the cat's mobility in the postoperative period; this has shown an increase in the

overall index, which is associated with improved mobility (from 45 at 6 weeks to 58 at 15 months postoperatively) (see supplementary material).

Discussion

This case report documents an acceptable long-term outcome (follow-up of over 12 months)¹⁰ without complications of a cemented hip replacement in a cat that had previously undergone contralateral pelvic limb amputation. Total hip replacement in dogs with previous contralateral amputated pelvic limb has been described in three studies;^{8,11,12} one reported that 4/9 dogs required surgical revision after luxation of the THR.⁸ Another, which included 16 amputee pelvic limb dogs that underwent various surgical procedures of the contralateral limb, documented that only one dog had an acceptable outcome after THR without any complication.¹¹ In the more recent study, a satisfactory outcome was reported for all 13 dogs at the 3-month follow-up appointment after THR.¹²

Outcome after femoral head osteotomy

Femoral head and neck excision or osteotomy (FHO) was the other surgical option discussed with the owners for managing this cat's painful arthritic coxofemoral joint. A recent study investigating function in cats 1 year after FHO reported that residual gait abnormalities were identified through ground reaction forces analysis but not through orthopaedic examination.¹³

A previous study of 81 dogs and cats at a mean of 4 years after FHO reported good limb function in only 38% of cases, satisfactory function in 20% of cases and unsatisfactory function in 42% of cases.¹⁴ A small study involving only three cats reported better functional outcomes in cats that underwent THR compared with cats that had FHO.¹⁵ Owing to the results available in the current literature, FHO was not felt to be the best option for this three-legged cat.

Osteoarthritis in the hip joint in humans and tripedal animals

In humans, the prevalence of osteoarthritis in the contralateral hip joint in the amputee population is two- to 10-fold higher and occurs sooner compared with individuals without limb loss.^{16,17} Changes in the gait pattern have been well documented, with alterations in ground reaction forces of the intact limb; this could increase the load of the hip joint, and over time, this may lead to joint pain and degeneration.¹⁸ The effect of pelvic limb amputation on the kinetics of the pelvis has been investigated in client-owned amputee dogs.¹⁹ During propulsion, an increase in lumbo-sacral-iliac extension and in lateral bending in the horizontal plane towards the pelvic limb has been described. Furthermore, while a quadruped dog bears approximately 40% of its body weight on the pelvic limbs combined, researchers have demonstrated that the amputee bears 26–33% of its body weight in the

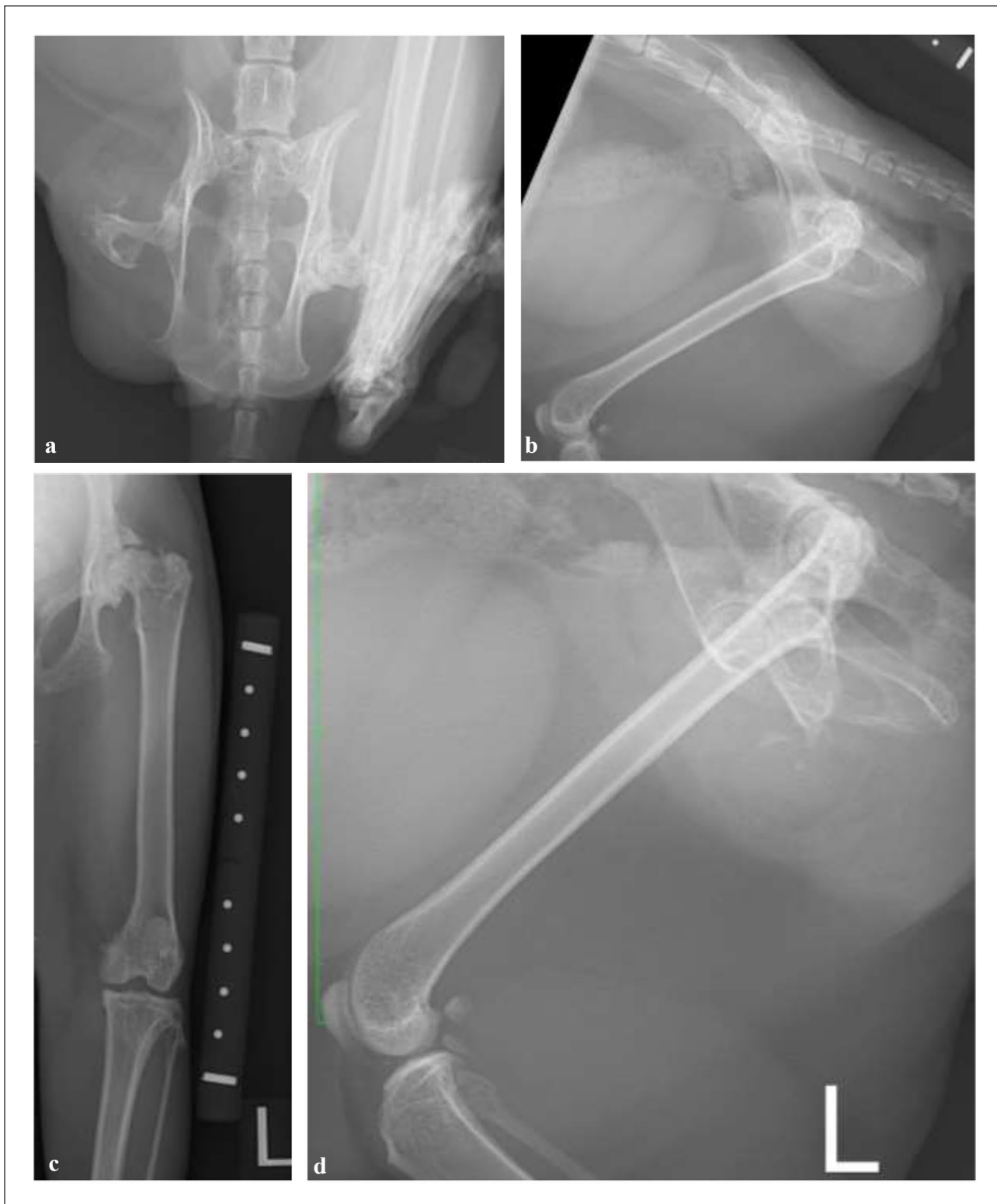

Figure 1 (a) Ventrodorsal and (b) lateral radiographs of the pelvis and femur, (c) craniocaudal horizontal beam, and (d) mediolateral radiographs of the left femur demonstrate marked periarticular osteophytosis of the coxofemoral joints compatible with a diagnosis of osteoarthritis

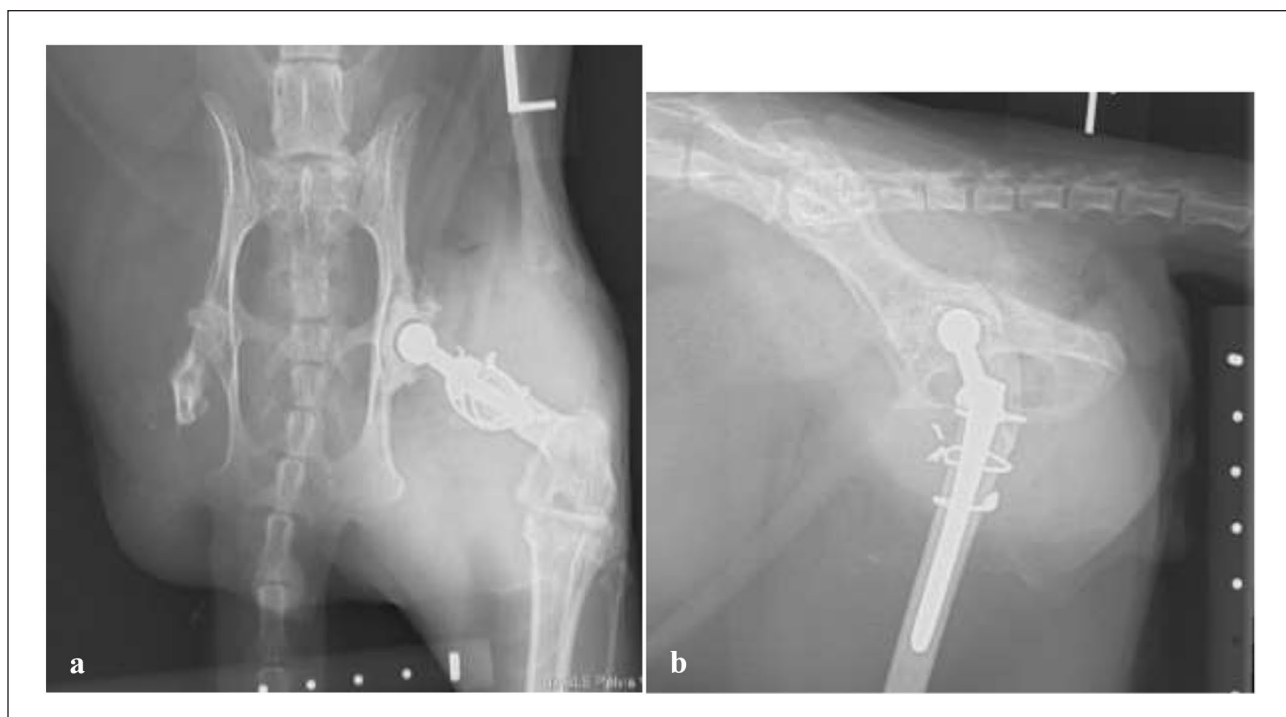

Figure 2 (a) Ventrodorsal and (b) lateral postoperative radiographs of the pelvis and femur demonstrate satisfactory postoperative implant positioning after left total hip replacement. Three cerclage wires are positioned around the proximal third of the femoral diaphysis to minimise the chance of fissure propagation

sole pelvic limb.^{20,21} Similar studies are not available for cats. The altered mechanics of the contralateral hip in an amputee may influence clinical and radiological results after THR; however, there is limited literature concerning the outcomes and role of THR as a surgical option for amputee humans.²²

Osteoarthritis in the coxofemoral joint of the amputated limb

An interesting observation in the cat reported herein was the degree of osteoarthritis in the coxofemoral joint of the amputated limb and the pain associated with this joint. Hip osteoarthritis secondary to dysplasia is well recognised in cats and has been reported in 60–95.6% of cats that were identified as having hip dysplasia on a ventro-dorsal hip radiograph.^{23,24} It remains unclear if the osteoarthritis in the amputated hip joint could represent an evolution of degenerative joint disease (DJD) due to hip dysplasia or is attributable to the effect of joint biomechanics and limited movement because of amputation. It does raise the question of whether the joints preserved in amputated limbs, even if non-weight bearing, may become a source of pain in domestic animals. In this case, the cat had the painful left hip joint removed during a separate surgical procedure 6 months after THR surgery on the right hip.

Implant positioning and adjustments in tripods

The complications of THR include hip luxation, infection, femoral fracture, aseptic loosening of the acetabular

cup and/or femoral stem, and sciatic neurapraxia. Luxation is considered the most common complication reported in 1.1–8.5% of cases,^{25,26} with improper orientation of the acetabular and femoral components being major contributing factors.²⁷

Acetabular cup positioning, particularly the angle of lateral opening (ALO), has been shown to be important in canine THR to reduce the likelihood of luxation, with the recommended range between 35° and 55°.²⁸ Intraoperatively, the cup was intended to be inserted in a more closed position compared with routine cases, based on the operating surgeon's speculation that this would help prevent luxation (the postoperative angle of the lateral opening was 16°). This hypothesis is because, with the contralateral limb amputation, a higher load on the THR implant would be expected because the patient's weight bears on only one pelvic limb. Moreover, the limb is more adducted under the pelvis during the stance phase and often a 'jump' is performed in the swing phase. More studies investigating the average ALO in cats undergoing THR and whether a more closed angle is associated with a reduction in postoperative luxation rate are needed to fully explore this speculation.

Conclusions

This case demonstrates that THR is a viable option in cats with coxofemoral DJD and a contralateral limb amputation. Retained joints in amputated limbs may develop osteoarthritis and be a source of pain for a cat.

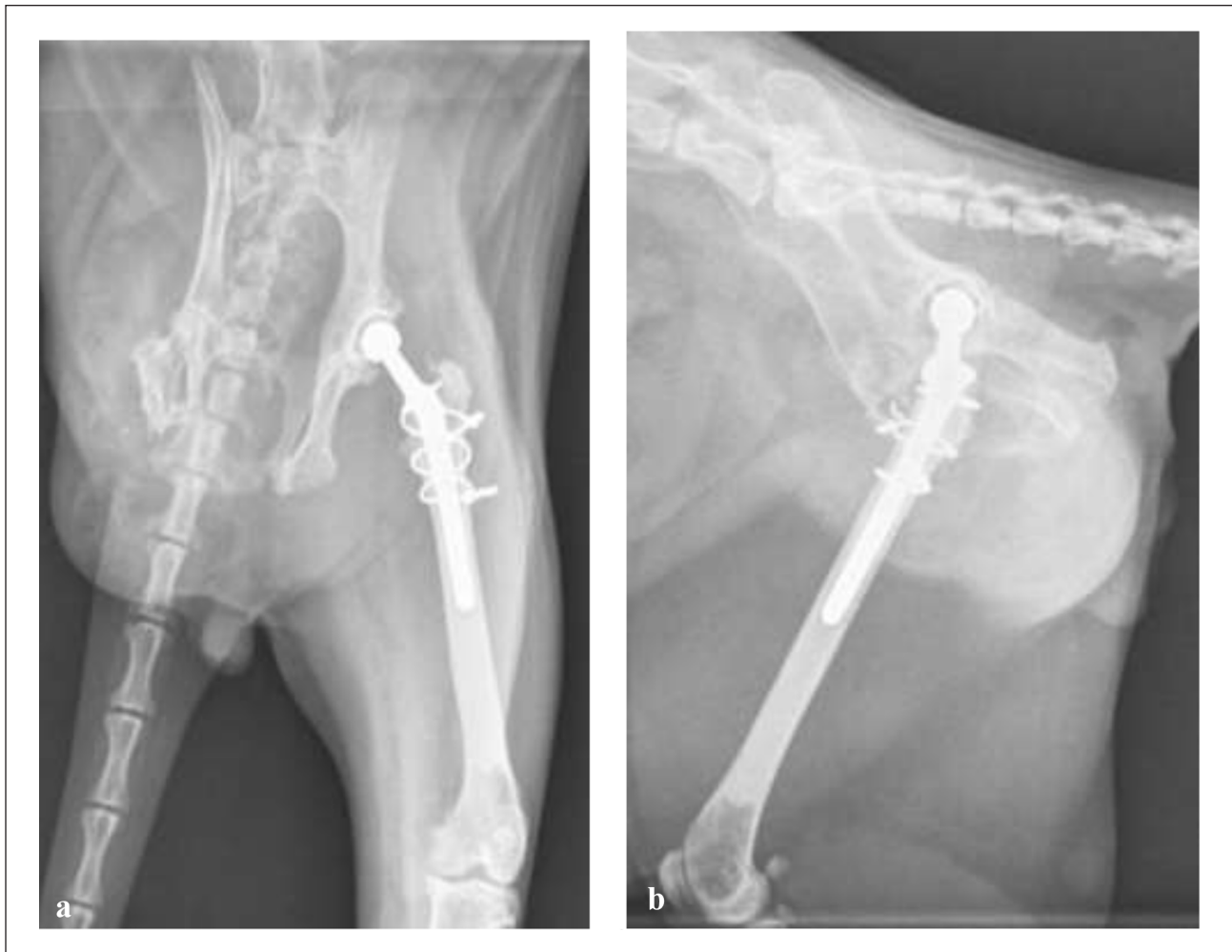


Figure 3 Ventro-dorsal (a) and lateral (b) 6 weeks follow-up radiographs of the pelvis and femur showing stable implants and absence of complications

Acknowledgements The authors thank the cat's owners for requesting referral and completing the questionnaires, and for providing updates, as well as the referring veterinary surgeon for their referral and assistance with the follow-up radiographs and updates on this case.

Supplementary material The following files are available as supplementary material:

- Feline musculoskeletal pain index 1
- Feline musculoskeletal pain index 2
- Feline musculoskeletal pain index 3

Conflict of interest The authors declared no potential conflicts of interest with respect to the research, authorship, and/or publication of this article.

Funding The article processing charge for this article has been funded by Langford Veterinary Services (Clinical Research Fund).

Ethical approval The work described in this manuscript involved the use of non-experimental (owned or unowned)

animals. Established internationally recognised high standards ('best practice') of veterinary clinical care for the individual patient were always followed and/or this work involved the use of cadavers. Ethical approval from a committee was therefore not specifically required for publication in *JFMS Open Reports*. Although not required, where ethical approval was still obtained, it is stated in the manuscript.

Informed consent Informed consent (verbal or written) was obtained from the owner or legal custodian of all animal(s) described in this work (experimental or non-experimental animals, including cadavers) for all procedure(s) undertaken (prospective or retrospective studies). For any animals or people individually identifiable within this publication, informed consent (verbal or written) for their use in the publication was obtained from the people involved.

ORCID iD Francesco Piana  <https://orcid.org/0000-0002-2753-4497>

Sorrel Judith Langley-Hobbs  <https://orcid.org/0000-0003-4397-5150>

References

- 1 Hardie EM, Roe SC and Martin FR. **Radiographic evidence of degenerative joint disease in geriatric cats: 100 cases (1994–1997).** *J Am Vet Med Assoc* 2002; 220: 628–632.
- 2 Fischer HR, Norton J, Kobluk CN, et al. **Surgical reduction and stabilization for repair of femoral capital physeal fractures in cats: 13 cases (1998–2002).** *J Am Vet Med Assoc* 2004; 224: 1478–1482.
- 3 Kawamata T, Niiyama M and Taniyama H. **Open reduction and stabilization of coxofemoral joint luxation in dogs and cats, using a stainless steel rope inserted via a ventral approach to the hip joint.** *Aust Vet J* 1996; 74: 460–464.
- 4 Charnley J. **The long-term results of low-friction arthroplasty of the hip performed as a primary intervention.** *J Bone Joint Surg Br* 1972; 54: 61–76.
- 5 Bardet JF. **Cemented total hip replacement: experience in France with the Porte prosthesis.** In: Vezzoni A (ed). *ESVOT 2004 Pre-Congress – total hip replacement seminar, 2004*, p 14.
- 6 Hach V and Delfs G. **Initial experience with a newly developed cementless hip endoprosthesis.** *Vet Comp Orthop Traumatol* 2009; 22: 153–158.
- 7 Kalis RH, Liska WD and Jankovits DA. **Total hip replacement as a treatment option for capital physeal fractures in dogs and cats.** *Vet Surg* 2012; 41: 148–155.
- 8 Preston CA, Schulz KS and Vasseur PB. **Total hip arthroplasty in nine canine hind limb amputees: a retrospective study.** *Vet Surg* 1999; 28: 341–347.
- 9 Johnson KA. *Piermattei's atlas of surgical approaches to the bones and joints of the dog and cat.* 5th ed. St Louis, MO: Elsevier, 2014, Plate 67, pp 329–335.
- 10 Cook JL, Evans R, Conzemius MG, et al. **Proposed definitions and criteria for reporting time frame, outcome, and complications for clinical orthopedic studies in veterinary medicine.** *Vet Surg* 2010; 39: 905–908.
- 11 Contreras ET, Worley DR, Palmer RH, et al. **Postamputation orthopedic surgery in canine amputees: owner satisfaction and outcome.** *Top Companion Anim Med* 2018; 33: 89–96.
- 12 Gifford AB, Lotsikas PJ, Liska WD, et al. **Total hip replacement in dogs with contralateral pelvic limb amputation: a retrospective evaluation of 13 cases.** *Vet Surg* 2020; 49: 1487–1496.
- 13 Schnabl-Feichter E, Schnabl S, Tichy A, et al. **Measurement of ground reaction forces in cats 1 year after femoral head and neck ostectomy.** *J Feline Med Surg* 2021; 23: 302–309.
- 14 Off W and Matis U. **Excision arthroplasty of the hip joint in dogs and cats. Clinical, radiographic and gait analysis findings at the surgical veterinary clinic of the Ludwig Maximilians University of Munich.** *Tierarztl Prax* 1997; 25: 379–387.
- 15 Liska WD, Doyle N, Marcellin-Little DJ, et al. **Total hip replacement in three cats: surgical technique, short-term outcome and comparison to femoral head ostectomy.** *Vet Comp Orthop Traumatol* 2009; 22: 505–510.
- 16 Kulkarni J, Adams J, Thomas E, et al. **Association between amputation, arthritis and osteopenia in British male war veterans with major lower limb amputations.** *Clin Rehabil* 1998; 12: 274–279.
- 17 Struyf PA, van Heugten CM, Hitters MW, et al. **The prevalence of osteoarthritis of the intact hip and knee among traumatic leg amputees.** *Arch Phys Med Rehabil* 2009; 90: 440–446.
- 18 Norvell DC, Czerniecki JM, Reiber GE, et al. **The prevalence of knee pain and symptomatic knee osteoarthritis among veteran traumatic amputees and nonamputees.** *Arch Phys Med Rehabil* 2005; 86: 487–493.
- 19 Hogy SM, Worley DR, Jarvis SL, et al. **Kinematic and kinetic analysis of dogs during trotting after amputation of a pelvic limb.** *Am J Vet Res* 2013; 74: 1164–1171.
- 20 Kirpensteijn J, Van Den Bos R, Van Den Brom WE, et al. **Ground reaction force analysis of large breed dogs when walking after the amputation of a limb.** *Vet Rec* 2000; 146: 155–159.
- 21 Fuchs A, Goldner B, Nolte I, et al. **Ground reaction force adaptations to tripedal locomotion in dogs.** *Vet J* 2014; 201: 307–315.
- 22 Amanatullah DF, Trousdale RT and Sierra RJ. **Total hip arthroplasty after lower extremity amputation.** *Orthopedics* 2015; 38: 394–400.
- 23 Langenbach A, Green P, Giger U, et al. **Relationship between degenerative joint disease and hip joint laxity by use of distraction index and Norberg angle measurement in a group of cats.** *J Am Vet Med Assoc* 1998; 213: 1439–1443.
- 24 Keller GG, Reed AL, Lattimer JC, et al. **Hip dysplasia: a feline population study.** *Vet Radiol Ultrasound* 1999; 40: 460–464.
- 25 Paul HA and Bargar WL. **A modified technique for canine total hip replacement.** *J Am Anim Hosp Assoc* 1987; 23: 13–18.
- 26 Olmstead ML, Hohn RB and Turner TM. **A five-year study of 221 total hip replacements in the dog.** *J Am Vet Med Assoc* 1983; 183: 191–194.
- 27 Massat BJ and Vasseur PB. **Clinical and radiographic results of total hip arthroplasty in dogs: 96 cases (1986–1992).** *J Am Vet Med Assoc* 1994; 205: 448–454.
- 28 Dyce J, Wisner ER, Wang Q, et al. **Evaluation of risk factors for luxation after total hip replacement in dogs.** *Vet Surg* 2000; 6: 524–532.