



## **Choledochoduodenostomy combined with Billroth II procedure for extrahepatic biliary obstruction and duodenal perforation in a cat**

Authors: Tomura, Shintaro, Iwata, Taisuke, Sugimoto, Taichi, Nakashima, Ko, Kojima, Kazuhiro, et al.

Source: Journal of Feline Medicine and Surgery Open Reports, 10(1)

Published By: SAGE Publishing

URL: <https://doi.org/10.1177/20551169241246415>

---

BioOne Complete ([complete.BioOne.org](https://complete.BioOne.org)) is a full-text database of 200 subscribed and open-access titles in the biological, ecological, and environmental sciences published by nonprofit societies, associations, museums, institutions, and presses.

Your use of this PDF, the BioOne Complete website, and all posted and associated content indicates your acceptance of BioOne's Terms of Use, available at [www.bioone.org/terms-of-use](https://www.bioone.org/terms-of-use).

Usage of BioOne Complete content is strictly limited to personal, educational, and non - commercial use. Commercial inquiries or rights and permissions requests should be directed to the individual publisher as copyright holder.

---

BioOne sees sustainable scholarly publishing as an inherently collaborative enterprise connecting authors, nonprofit publishers, academic institutions, research libraries, and research funders in the common goal of maximizing access to critical research.



# Choledochoduodenostomy combined with Billroth II procedure for extrahepatic biliary obstruction and duodenal perforation in a cat

*Journal of Feline Medicine and Surgery Open Reports*  
1–6

© The Author(s) 2024

Article reuse guidelines:

sagepub.com/journals-permissions

DOI: 10.1177/20551169241246415

journals.sagepub.com/home/jfmsopenreports

This paper was handled and processed by the European Editorial Office (ISFM) for publication in *JFMS Open Reports*.



Shintaro Tomura<sup>1</sup> , Taisuke Iwata<sup>1</sup>, Taichi Sugimoto<sup>1</sup>, Ko Nakashima<sup>1</sup>, Kazuhiro Kojima<sup>2</sup>, Kazuyuki Uchida<sup>2</sup> and Atsushi Fujita<sup>1</sup>

## Abstract

**Case summary** A 5-year-old neutered Somali cat presented with a 2-week history of icterus. Diagnostic imaging revealed extrahepatic biliary obstruction (EHBO) due to a common bile duct (CBD) mass. During exploratory laparotomy, a duodenal perforation was discovered incidentally. Choledochoduodenostomy combined with the Billroth II procedure was performed after resection of the CBD mass and the proximal duodenum to treat the EHBO and duodenal perforation. Based on histological and immunohistochemical findings, the CBD mass was diagnosed as a neuroendocrine carcinoma with gastrin-producing cell differentiation. The cat recovered almost uneventfully and was discharged 11 days after surgery. The cat survived for nearly 100 days without recurrence of EHBO or duodenal perforation; however, intermittent vomiting and weight loss persisted despite supportive medications.

**Relevance and novel information** To the best of our knowledge, there is no detailed report on the application of choledochoduodenostomy combined with the Billroth II procedure in cats, as we used to treat the EHBO and duodenal perforation in the present case. As serum gastrin concentrations were elevated on the first day of hospitalisation, the CBD mass was diagnosed as a neuroendocrine carcinoma with gastrin-producing cell differentiation, which seemed to have caused not only EHBO but also duodenal perforation (Zollinger–Ellison syndrome). The cat survived for almost 100 days without any perioperative complications. However, this combined procedure might be considered as only a salvage option and not as a definitive treatment option in cats requiring simultaneous biliary and gastrointestinal reconstruction because postoperative supportive care could not improve the cat's condition or maintain its quality of life.

**Keywords:** Billroth II; choledochoduodenostomy; duodenal perforation; extrahepatic biliary obstruction; gastrin-secreting tumour; neuroendocrine carcinoma

**Accepted:** 25 March 2024

## Introduction

The surgical prognosis of extrahepatic biliary obstruction (EHBO) due to neoplastic diseases is considered poor in cats.<sup>1,2</sup> Postoperative complications include ascending cholangiohepatitis, dehiscence or stricture of the anastomosis site, and physiological changes in the gastrointestinal tract.<sup>3,4</sup> Cholecystoduodenostomy and cholecystojejunostomy are common biliary diversion techniques in veterinary medicine,<sup>4</sup> and only one study

<sup>1</sup>Japan Small Animal Medical Center, Tokorozawa, Saitama, Japan

<sup>2</sup>Department of Veterinary Pathology, Graduate School of Agricultural and Life Sciences, The University of Tokyo, Bunkyo-ku, Tokyo, Japan

### Corresponding author:

Atsushi Fujita DVM, Japan Small Animal Medical Center, 1-10-4, Higashitokorozawawada, Tokorozawa, Saitama 359-0023, Japan  
Email: a.fujita@jsamc.jp



Creative Commons Non Commercial CC BY-NC: This article is distributed under the terms of the Creative Commons

Attribution-NonCommercial 4.0 License (<https://creativecommons.org/licenses/by-nc/4.0/>) which permits non-commercial use, reproduction and distribution of the work without further permission provided the original work is attributed as specified on the SAGE and Open Access pages (<https://us.sagepub.com/en-us/nam/open-access-at-sage>).

has reported on common bile duct (CBD) re-implantation as choledochoduodenostomy in detail in a cat.<sup>5</sup> Moreover, choledochal stenting is a less invasive procedure to make the CBD patent and might be performed for palliation in neoplastic disease.<sup>6</sup>

The prognosis of the Billroth II procedure in veterinary medicine has been guarded.<sup>7</sup> However, Barandun et al<sup>8</sup> achieved tension-free anastomosis without biliary diversion using the Billroth II procedure in two cats, and suggested that as a digestive reconstruction method, the Billroth II procedure might contribute to a good medium- or long-term quality of life if the biliary system could be preserved.

Here, we report a case in which choledochoduodenostomy was combined with the Billroth II procedure adding Braun anastomosis to resolve not only EHBO but also duodenal perforation in a cat with a gastrin-secreting neuroendocrine carcinoma in the CBD, elaborating on the surgical strategy and postoperative course.

## Case description

A 5-year-old neutered Somali cat weighing 4.3 kg presented with a 2-week history of icterus with severe anorexia, lethargy and vomiting. On presentation, severe icterus, fever (39.8°C) and weight loss (11%) were observed.

The complete blood count (Procyte DX; IDEXX) result was within the reference interval (RI). A blood chemistry panel (FUJI DRI-CHEM 7000V; Fujifilm) revealed elevated liver enzymes and hyperbilirubinemia. The serum amyloid A (SAA) concentration (FUJI DRI-CHEM IMMUNO AU10V; Fujifilm) was also increased (Table 1).

Thoracic and abdominal radiographs were unremarkable. Abdominal ultrasonography (ARIETTA 70; Hitachi) revealed an 11 mm long oval hyperechoic mass within the distal aspect of the dilated CBD. Intrahepatic bile ducts were also dilated. No ascites or gastrointestinal

perforation was identified. EHBO appeared to be caused by intraluminal obstruction by the mass (Figure 1).

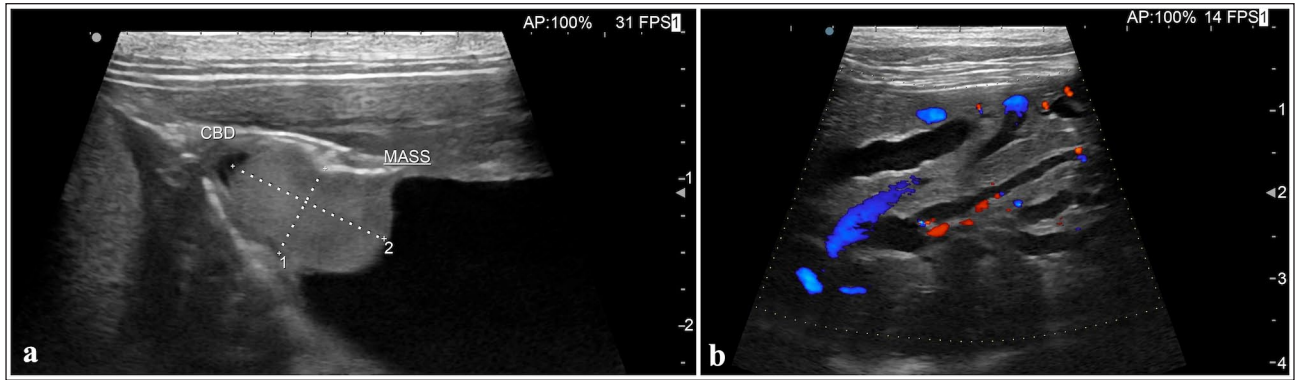
After intravenous therapy with maropitant citrate and metoclopramide in the hospital, exploratory laparotomy was performed under general anaesthesia on day 4. Epidural anaesthesia was delivered using ropivacaine hydrochloride and medetomidine hydrochloride (2 mg/kg and 2 µg/kg, respectively). Fentanyl and ketamine (1 µg/kg/h and 0.2 mg/kg/h, respectively, as a continuous infusion) were continued until the day after surgery.

With the cat in dorsal recumbency, a ventral midline incision was made from the xiphoid process to the umbilicus. Highly viscous ascitic fluid was noted on abdominal entry, which was collected for cytological analysis and bacterial culture. The mass was palpable within the distal portion of the CBD. The proximal CBD was approximately 20 mm dilated and adherent to the duodenum (Figure 2a). When the adhesion was dissected using bipolar forceps, a 15 mm long duodenal perforation was found at the adhesion site, and multiple ulcerative lesions were recognised in the mucosa around the site. The mass and perforation site were resected, followed by a choledochoduodenostomy with the Billroth II procedure (Figure 2b,c). First, the distal CBD was dissected from the portal vein and pancreas using bipolar forceps or sterilised cotton swabs, ligated twice with hemoclips and cut with Metzenbaum scissors proximal to the confluence point of the pancreatic duct. Then, it was decided that the gastrointestinal tract from the pyloric antrum to the duodenum rostral to the major duodenal papilla would be resected. Branches of the right gastric and gastroepiploic arteries and veins in this area were ligated using bipolar forceps. The pyloric antrum was cut with a stapling device (Endo GIA Tri-Staple 2.0 mm × 60 mm; Medtronic) and the duodenum was occluded with Doyen forceps and cut with

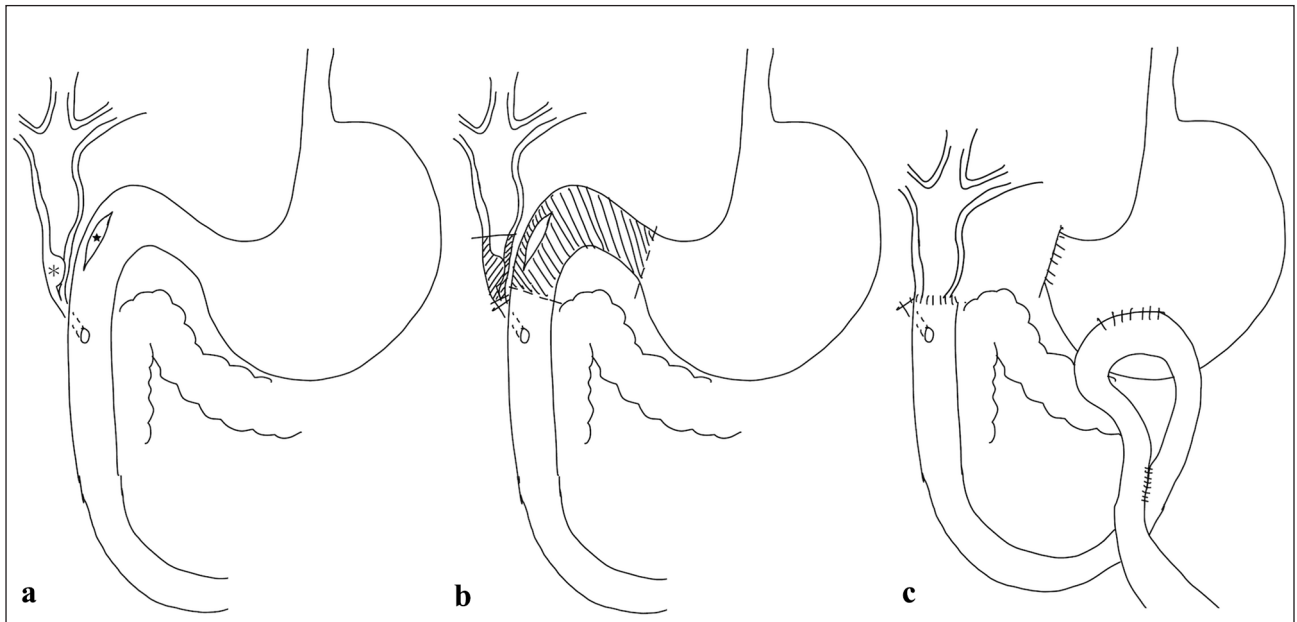
**Table 1** Results of blood examination in the present case

Variable	Day 1	Day 15	Day 19	Day 27	Day 55	Day 72	Day 86	RI
HCT (%)	36	NE	32	33	35	30	26	30.3–52.3
RBC (×10 <sup>6</sup> /µl)	8.73	NE	7.22	6.82	7.55	6.75	5.61	6.54–12.2
HGB (g/dl)	12.3	NE	11.0	10.4	11.6	10.0	8.3	9.8–16.2
WBC (×10 <sup>3</sup> /µl)	6.23	NE	5.23	3.22	6.36	5.46	6.05	2.87–17.02
PLT (×10 <sup>3</sup> /µl)	408	NE	434	446	497	344	301	151–600
T-BIL (mg/dl)	13.4	0.7	0.4	0.1	0.1	0.1	0.3	0.1–0.4
ALT (U/l)	112	51	67	68	401	461	659	22–84
AST (U/l)	154	NE	28	25	282	94	159	18–51
ALP (U/l)	387	29	31	29	71	112	219	<58
GGT (U/l)	39	NE	3	2	7	43	55	1–10
SAA (µg/ml)	28.56	3.82	>225	<3.75	7.61	61.79	60.78	<5.49

ALP = alkaline phosphatase; ALT = alanine aminotransferase; AST = aspartate aminotransferase; GGT = gamma-glutamyl transferase; HCT = haematocrit; HGB = haemoglobin; NE = not evaluated; PLT = platelet count; RBC = red blood cell count; SAA = serum amyloid A; T-BIL = total bilirubin; WBC = white blood cell count



**Figure 1** Abdominal ultrasonography: (a) an oval hyperechoic mass distal to the dilated common bile duct (CBD) and (b) dilated intrahepatic bile ducts throughout the liver

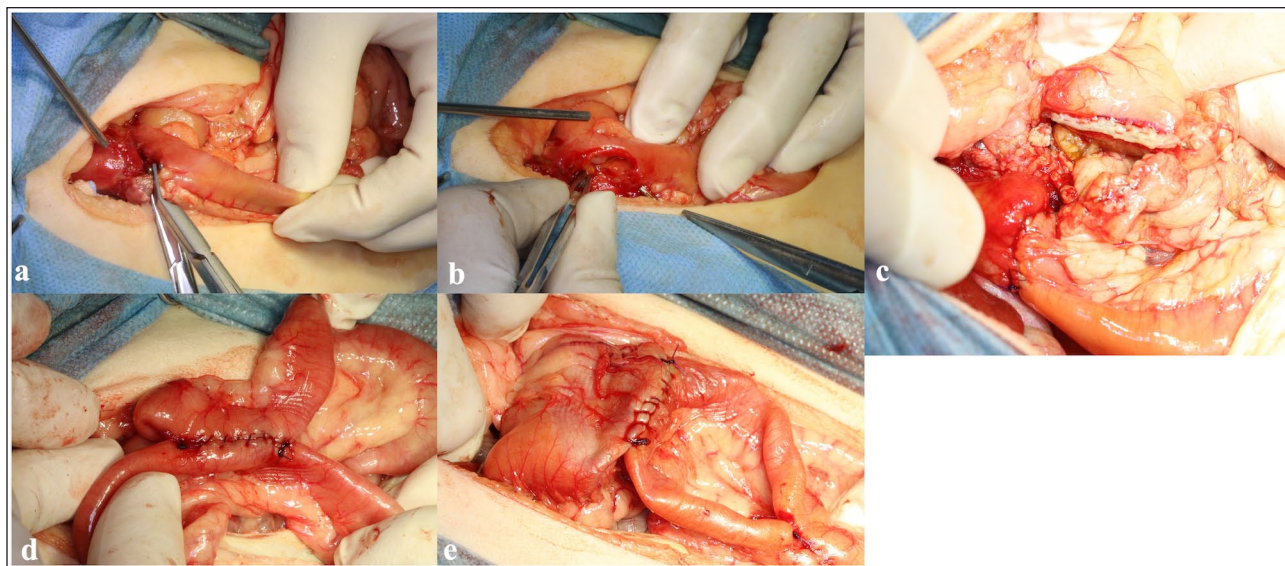


**Figure 2** Schematic representation of the surgical procedure: (a) the mass in the common bile duct (asterisk) and the site of duodenal perforation (star); (b) diagonal lines indicating the resected areas; and (c) Billroth II gastrojejunostomy combined with Braun anastomosis and choledochoduodenostomy

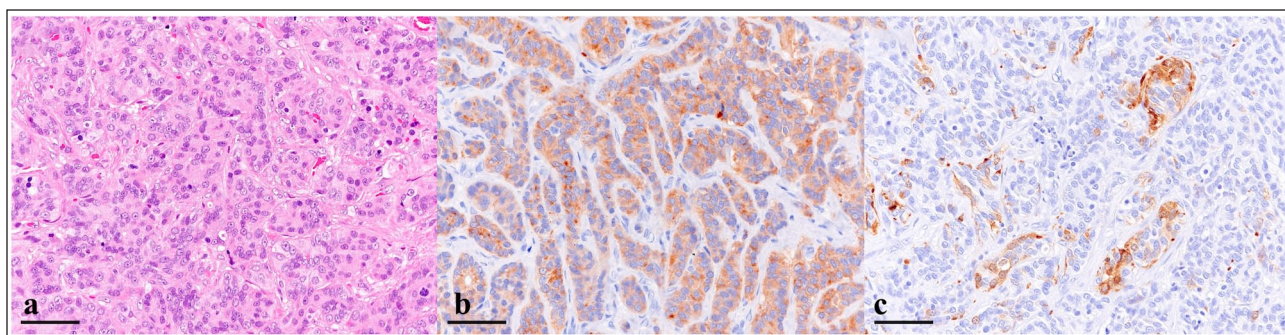
Metzenbaum scissors. The CBD proximal to the mass was cut using Metzenbaum scissors, and all resected tissues were examined histopathologically. A bile sample was also collected for bacterial examination.

Biliary and intestinal tract reconstruction started with end-to-end choledochoduodenostomy, which was closed with 5-0 polydioxanone monofilament suture material in a Gambee's continuous pattern. Subsequently, a side-to-side jejunal anastomosis (Braun anastomosis) was performed as follows: the jejunum 10 cm distal to the caudal duodenal flexure was juxtaposed 20 cm distal to the site. Occluding with a Doyen forceps, 4 cm long full-thickness incisions were made in the antimesenteric

border of the sites using a scalpel and Metzenbaum scissors. The anastomosis was completed using a simple continuous pattern of 4-0 polydioxanone monofilament suture material. Finally, the middle of the loop was anastomosed to the ventral aspect of the stomach (side-to-side gastrojejunostomy) in an isoperistaltic fashion, using the same material (Figures 2 and 3). There was no tension at either of the anastomosis sites. Liver biopsy, peritoneal lavage and abdominal drainage tube placement were also performed. The abdomen was closed routinely, and a feeding tube was placed through the oesophagus into the stomach. The tube was not removed until the cat died.



**Figure 3** Surgical procedure: (a) ligation of the common bile duct distal to the mass; (b) duodenal perforation; (c) partial gastrectomy and choledochoduodenostomy; (d) Braun anastomosis; and (e) gastrojejunostomy



**Figure 4** Histopathological and immunohistochemical findings: (a) the tumour is highly cellular with a small lobular pattern surrounded by a thin fibrovascular stroma (haematoxylin and eosin, bar = 50µm); (b) tumour cells are diffusely immunopositive for synaptophysin (immunohistochemistry, bar = 50µm); and (c) tumour cells are partially immunopositive for gastrin (immunohistochemistry, bar = 50µm)

The cat recovered uneventfully from the surgery and received intravenous nutrition for 2 days after surgery. Enteral nutrition was started on day 7. A small amount of gastric juice (<10ml) was occasionally withdrawn through the feeding tube. Icterus and anorexia improved almost completely during hospitalisation without nausea and vomiting. The abdominal drainage tube was removed on day 9. Bacterial cultures of both the ascitic fluid and bile samples were negative. Cefmetazole sodium and clindamycin phosphate were continued for 1 week postoperatively. Supportive medications including maropitant citrate, lansoprazole, metoclopramide, mosapride citrate, prednisolone, albumin tannate and probiotics were administered at the usual doses and continued until death. The cat was discharged on day 15.

Based on histological and immunohistochemical findings, the mass was diagnosed as a neuroendocrine carcinoma with gastrin-producing cell differentiation (Figure 4), and the liver sample was diagnosed as chronic cholangiohepatitis. No tumour cells were observed in the stomach, duodenum or liver.

Serum gastrin concentrations were measured retrospectively and were elevated on days 1 and 15 (970 and 740 pg/ml, respectively; RI  $\leq$ 200 pg/ml in humans; Hoken Kagaku).

Four days after discharge (day 19), the cat revisited with severe anorexia, lethargy and pyrexia. Only the SAA concentration was markedly increased. As the gallbladder wall appeared to be thickened on abdominal ultrasonography, bacterial cholecystitis was suspected.

The cat was treated with enrofloxacin and supportive care. Eight days later, anorexia and lethargy improved almost completely and the body temperature was normal. The SAA concentration was decreased to the RI. Enrofloxacin was continued until the patient's death.

On day 55 (40 days after discharge), the cat returned with occasional vomiting. No anorexia or lethargy was observed. Liver enzymes and SAA concentration were increased without hyperbilirubinaemia. Abdominal ultrasonography showed multiple mixed-pattern hepatic nodules (up to 10mm) and swelling of the left hepatic lymph node. Exacerbation of cholangiohepatitis or tumour metastases was suspected. The owner declined further examination. There was no subsequent anorexia or lethargy, but occasional vomiting and weight loss persisted. The increase in liver enzymes and SAA concentration worsened gradually, with mild anaemia, and the cat died on day 103. A postmortem examination was not performed.

## Discussion

We performed a choledochoduodenostomy and Billroth II procedure with Braun anastomosis for EHBO and duodenal perforation caused by a primary gastrin-secreting CBD neuroendocrine carcinoma in a cat, which seemed to be Zollinger–Ellison syndrome. The cat tolerated surgery well and survived nearly 100 days without EHBO recurrence or duodenal perforation, although intermittent postoperative vomiting and weight loss persisted despite supportive medications. To the best of our knowledge, there is no published, detailed report on the application of choledochoduodenostomy combined with the Billroth II procedure in cats.

The ideal site of enteric–biliary anastomosis is considered to be between the duodenum and proximal jejunum, allowing bile to enter the intestine near its original site,<sup>6</sup> and tension-free anastomosis is recommended. In this case, the CBD was dilated 2cm in diameter, and the oval-shaped edge was adequate to perform an end-to-end choledochoduodenostomy without any tension. There was no perioperative complication at the site and no evidence of EHBO recurrence until the patient's death. In human medicine, choledchoenterostomy is considered superior to cholecystoenterotomy as surgical management for EHBO due to neoplastic disease owing to the biliary bypass failure risk.<sup>9</sup> A cat with EHBO and acute cholecystitis was recently reported to be successfully treated with end-to-side choledochoduodenostomy and cholecystectomy without EHBO recurrence, even after tumour recurrence.<sup>5</sup> These reports suggest that choledochoduodenostomy is a feasible option for neoplastic EHBO in cats, as in humans.

Chronic inflammatory hepatobiliary diseases were histopathologically accompanied by neoplastic

diseases in cats with EHBO,<sup>1</sup> as seen in our case. As cachexia due to concurrent cholangiohepatitis or latent residual tumour progression might have contributed to the cat's death, careful medical management might be required. Furthermore, the gallbladder was preserved for future use as biliary rerouting in the event that EHBO recurred. However, as bacterial cholecystitis was suspected 4 days after discharge (day 19), additional cholecystectomy might have prolonged survival time in this cat, as reported recently.<sup>10</sup> Moreover, cholecystocentesis for bacterial culture was not performed due to concerns about potential complications in the diverted bile tract. The prolonged use of antibiotics is not recommended, particularly in this situation, as it may contribute to antibiotic resistance. Enrofloxacin should have been stopped when the cat's condition improved.

Tension at the gastrointestinal suture site is a common cause of dehiscence.<sup>6</sup> We thus resected and reconstructed the gastrointestinal tract because of the difficulty of repairing the perforation site. In this case, where the Billroth II procedure combined with Braun anastomosis was chosen, the separated reconstruction resulted in no tension at either anastomotic site and no perioperative problems were observed. Although Braun anastomosis is intended to reduce gastric bile reflux, as is the case in humans,<sup>11</sup> its positive effect is still controversial in veterinary medicine. Postoperative contrast-enhanced radiography might be required to assess the flow of contents in the alimentary tract.

The survival time of the cat was also short, as previously reported.<sup>12</sup> Surgical factors contributing to this poor outcome included the need for biliary diversion in the Billroth II procedure or EHBO due to the neoplastic disease. Therefore, biopsy of the mass plus substantially less invasive procedures, such as choledochal stenting with serosal patch or Y-U pyloroplasty, might have been another option.

## Conclusions

Choledochoduodenostomy and the Billroth II procedure combined with Braun anastomosis was performed for EHBO and concurrent duodenal perforation in a cat with a primary gastrin-secreting CBD neuroendocrine carcinoma. This combined biliary diversion procedure might be considered as a salvage option for this condition but cannot be recommended as a treatment approach based on the outcome of this cat. Less invasive procedures (eg, stenting with serosal patching) could be considered as alternative palliative care options with potentially reduced morbidity.

**Conflict of interest** The authors declared no potential conflicts of interest with respect to the research, authorship, and/or publication of this article.

**Funding** The authors received no financial support for the research, authorship, and/or publication of this article.

**Ethical approval** The work described in this manuscript involved the use of non-experimental (owned or unowned) animals. Established internationally recognised high standards ('best practice') of veterinary clinical care for the individual patient were always followed and/or this work involved the use of cadavers. Ethical approval from a committee was therefore not specifically required for publication in *JFMS Open Reports*. Although not required, where ethical approval was still obtained, it is stated in the manuscript.

**Informed consent** Informed consent (verbal or written) was obtained from the owner or legal custodian of all animal(s) described in this work (experimental or non-experimental animals, including cadavers) for all procedure(s) undertaken (prospective or retrospective studies). For any animals or people individually identifiable within this publication, informed consent (either verbal or written) for their use in the publication was obtained from the people involved.

**ORCID iD** Shintaro Tomura  <https://orcid.org/0000-0002-0748-244X>

## References

- 1 Buote NJ, Mitchell SL, Penninck D, et al. **Cholecystoenterostomy for treatment of extrahepatic biliary tract obstruction in cats: 22 cases (1994–2003).** *J Am Vet Med Assoc* 2006; 228: 1376–1382.
- 2 Mayhew PD, Holt DE, McLear RC, et al. **Pathogenesis and outcome of extrahepatic biliary obstruction in cats.** *J Small Anim Pract* 2002; 43: 247–253.
- 3 Mehler SJ, Mayhew PD, Drobatz KJ, et al. **Variables associated with outcome in dogs undergoing extrahepatic biliary surgery: 60 cases (1988–2002).** *Vet Surg* 2004; 33: 644–649.
- 4 Morrison S, Prostredny J and Roa D. **Retrospective study of 28 cases of cholecystoduodenostomy performed using endoscopic gastrointestinal anastomosis stapling equipment.** *J Am Anim Hosp Assoc* 2008; 44: 10–18.
- 5 Hayes G, Devereux S, Loftus JP, et al. **Common bile duct obstruction palliated with common bile duct re-implantation (choledochoduodenostomy) in a cat.** *Can Vet J* 2019; 60: 1089–1093.
- 6 Mehler SJ. **Complications of the extrahepatic biliary surgery in companion animals.** *Vet Clin North Am Small Anim Pract* 2011; 41: 949–967.
- 7 Fossum TW and Hedlund CS. **Gastric and intestinal surgery.** *Vet Clin North Am Small Anim Pract* 2003; 33: 1117–1145.
- 8 Barandun MA, Mullins RA and Rytz U. **Billroth II procedure for the treatment of spontaneous gastrointestinal perforation in two cats.** *J Am Vet Med Assoc* 2021; 259: 1325–1331.
- 9 Sarfeh IJ, Rypins EB, Jakowatz JG, et al. **A prospective, randomized clinical investigation of cholecystoenterostomy and choledochenterostomy.** *Am J Surg* 1988; 155: 411–414.
- 10 Center SA, Randolph JF, Warner KL, et al. **Clinical features, concurrent disorders, and survival time in cats with suppurative cholangitis-cholangiohepatitis syndrome.** *J Am Vet Med Assoc* 2022; 260: 212–227.
- 11 Hölscher AH, Bollschweiler E and Mönig SP. **Ulcer surgery - what remains? [article in German]** *Der Internist* 2006; 47: 602–610.