



Fatal Toxoplasmosis in Sand Cats (*Felis margarita*)

Authors: Pas, An, and Dubey, J. P.

Source: Journal of Zoo and Wildlife Medicine, 39(3) : 362-369

Published By: American Association of Zoo Veterinarians

URL: <https://doi.org/10.1638/2007-0149.1>

BioOne Complete (complete.BioOne.org) is a full-text database of 200 subscribed and open-access titles in the biological, ecological, and environmental sciences published by nonprofit societies, associations, museums, institutions, and presses.

Your use of this PDF, the BioOne Complete website, and all posted and associated content indicates your acceptance of BioOne's Terms of Use, available at www.bioone.org/terms-of-use.

Usage of BioOne Complete content is strictly limited to personal, educational, and non - commercial use. Commercial inquiries or rights and permissions requests should be directed to the individual publisher as copyright holder.

BioOne sees sustainable scholarly publishing as an inherently collaborative enterprise connecting authors, nonprofit publishers, academic institutions, research libraries, and research funders in the common goal of maximizing access to critical research.

FATAL TOXOPLASMOSIS IN SAND CATS (*FELIS MARGARITA*)

An Pas, D.V.M., and J. P. Dubey, M.V.Sc., Ph.D.

Abstract: The sand cat (*Felis margarita*) is a small-sized felid occurring in the United Arab Emirates (UAE). The sand cat captive-breeding program at the Breeding Centre for Endangered Arabian Wildlife in Sharjah, UAE, has until recently been severely compromised by very high newborn mortality rates. Two different pairs of sand cats gave birth, respectively, to one and two litters (with a total of eight kittens) between 1999 and 2006. Seven out of eight kittens died between the third and 21st wk of life. Toxoplasmosis was confirmed as the cause of death in these two litters. Adult cats had high antibody titers to *Toxoplasma gondii* before pregnancy, suggesting that maternal immunity did not protect the kittens against infection with *T. gondii* and that maternal immunity might not have prevented transplacental transmission of the parasite. This observation contrasts with what is seen in domestic cats. To date, this is the first report on confirmed fatal toxoplasmosis and prevalence of *T. gondii* in sand cats.

Key words: *Felis margarita*, sand cat, *Toxoplasma gondii*, toxoplasmosis.

INTRODUCTION

The sand cat (*Felis margarita*) is a small-sized desert felid weighing 2–3 kg. It is found in sand and stone deserts ranging from the north of Africa to Asia, with the Arabian Peninsula as its center of distribution. It is well adapted to living in arid areas and in areas where temperature changes are extreme with temperatures ranging from 0°C to 58°C.²⁰ The sand cat is mainly nocturnal, spending the days in a shallow burrow or under vegetation. Its prey consists of small rodents and occasional birds and reptiles. These sand cats may be able to exist without drinking free water.²⁷

The sand cat is listed under the 2008 Convention of International Trade in Endangered Species of Wild Fauna and Flora (CITES) Appendix II, which regulates the import and export of animals to avoid trade that would become a threat to the survival of the species. The subspecies *Felis margarita harrisoni* that is found in the United Arab Emirates (UAE) is not listed as endangered, but due to rapid urbanization, declining numbers can be expected.^{3,19}

Sand cats are held and bred in captivity at institutes worldwide. An international studbook has been in existence since the 1980s, and after 2000 they became part of an Europäischen Erhaltungszuchtprogramm and Species Survival Plan program.

In captivity, sand cats are fed a variety of diets from small whole chicks and rodents to commer-

cially prepared feline diets. Some vegetables are added to the diets and water is available.²⁷

At the Breeding Centre for Endangered Arabian Wildlife (BCEAW), the sand cats are kept in large outside enclosures with an inner den. The enclosures are accessed only by the keepers and the breeding animals are not on display to the public. The cats are kept individually and are paired for only part of the year to avoid having offspring during the extremely hot summer months. If the female shows interest in the male, the pair is kept together for about 2 wk. If no interest is noticed, the animals are separated again for about 2–3 wk. If a pregnancy is suspected, access to the cage is restricted to one keeper and as soon as the kittens are born, the inner den is left untouched.

The animals are fed a diet similar to that of other small carnivores kept at the BCEAW. Over the years different raw meats, such as chicken, camel, donkey, and buffalo, and whole prey, such as mice, rats, and day-old chicks, have been fed. No commercial cat food is used.

CASE REPORT

First litter

On 4 March 1999, a litter of four kittens was born at the BCEAW (Table 1). Both parents were captive bred in the U.S. On the 13th day after birth, one kitten (FM009) disappeared. The other three kittens showed no abnormal behavior or signs of illness at that time. However, the growth rate of two of the kittens was slower than would be expected at 3 mo of age. Protocols used at that time included deworming with fenbendazole; and vaccination with a killed rabies vaccine (Annumune, Fort Dodge, Iowa 50501, USA) and a killed vaccine against feline rhinotracheitis, calicivirus, and panleucopenia (Fel-O-Vax PCT, Fort Dodge, Iowa

From the Breeding Centre for Endangered Arabian Wildlife, P.O. Box 29922, Sharjah, United Arab Emirates (Pas); and the U.S. Department of Agriculture, Animal Natural Resources Institute, Animal Parasitic Disease Laboratory, BARC-East, Building 1001, Beltsville, Maryland 20705-2350, USA (Dubey). Correspondence should be directed to Dr. Pas (breeding@epaa-shj.gov.ae).

Table 1. Summary of lesions and immunohistochemical (IHC) examination.

ID	Sex	Birth	Death	Symptoms	Necropsy	Histology
First litter						
FM 009	F	04-Mar-99	17-Mar-99	disappeared, probably died and eaten	not done	not done
FM 008	F	04-Mar-99	19-Jul-99	found dead, underweight	no gross lesions, autolysis, no fluid	no obvious changes, no conclusion, IHC <i>Toxoplasma gondii</i> negative
FM 007	M	04-Mar-99	23-Jul-99	found dead, weight loss	no gross lesions, no fluid	no obvious changes, no conclusion, IHC structures suggestive of <i>T. gondii</i>
FM 006	M	04-Mar-99	01-Aug-99	found dead, lost condition over last few days	lung edema, liver congested, no fluid	IHC-positive lung <i>T. gondii</i>
Mother						
FM 004	F	02-Apr-97	04-Jan-00	found dead, severe weight loss	necrotic foci in lung, sero-hemorrhagic fluid in abdomen, perforated pylorus	IHC-negative <i>T. gondii</i>
Second litter						
FM 014	M	01-Apr-05	23-Jun-05	anorexia, acute death	liver pale, fluid in thorax, lungs mottled, no gross abnormalities in heart, jelly in pericardium	inflammation and necrosis in liver, spleen, heart, lymph nodes; 1 <i>T. gondii</i> tachyzoite in heart
FM 015	F	01-Apr-05	07-Jul-05	anorexia, dyspnea, watery eyes, pyrexia, depressed, death on day 4	necrotic foci in liver, jelly-like fluid in pericardium	multi-organ inflammation and necrosis, IHC <i>T. gondii</i> positive
Third litter						
FM 016	M	02-Mar-06	28-Mar-06	found dead, no previous symptoms	sero-hemorrhagic fluid in abdomen and thorax, white foci all over liver, pneumonia, white stripes of necrosis on heart	severe necrosis and inflammation in lung, liver, spleen, heart. <i>T. gondii</i> present in all organs
FM 017	F	02-Mar-06	alive	retina degeneration, serology (see text)		IHC-positive multi-organ (see text)

50501, USA). The kittens remained thin even though their appetites were good.

On day 135 postpartum, a female kitten (FM008) was found dead. Aside from being underweight, no previous symptoms had been noticed. Gross necropsy and histology were unremarkable; however, most organs were severely autolyzed and prevented further evaluation. Immunohistochemistry (IHC) for *T. gondii* performed at the Animal Parasitic Diseases Laboratory (APDL) in Beltsville, Maryland (USA), using *T. gondii*-specific rabbit polyclonal sera as described^{12,24} on formalin-preserved samples was negative.

The remaining two kittens were placed in isolation and received extra food and intensive monitoring. Four days later, a male kitten (FM007) also died (day 139). Gross necropsy and histology were again unremarkable; however, structures suggestive of *T. gondii* were observed in lung and liver on IHC examination performed by Abbey Veterinary Services, Devon, United Kingdom.

The fourth kitten (FM006) was found dead on day 148. Grossly, lung edema and a pale congested liver were the only postmortem abnormalities seen. No histology was performed on this last kitten, but samples were preserved in 10% formalin. In 2006, these samples were retrieved and were processed at the APDL by IHC. *T. gondii* was found in its pulmonary lesions.

A few months later, the mother (FM004) died unexpectedly. This female had no previous clinical signs of infection. Postmortem evaluation revealed that she was underweight. Small necrotic foci were seen in the lungs, and the abdomen contained a small volume of fluid. No further analysis was conducted at that time; however, retrospective IHC was performed at APDL on formalin-preserved samples and these were negative for *T. gondii*.

Second litter

A second breeding female (FM011) was acquired on breeding loan from Al Wabra Wildlife Preservation, Qatar, in 2003. She was captive born at Twycross Zoo, United Kingdom, in 1998. She was paired with a wild-caught male (FM005) for breeding and a litter of two kittens, one male and one female, was born in April 2005. At 6 wk of age, the kittens were dewormed and 2 wk later they were vaccinated against rabies and against feline rhinotracheitis, calicivirus, and panleucopenia infection using the same protocol as in the previous litter.

On day 84, the male kitten (FM014) was found dead. The only indicator that he was ill occurred the night before when he left half his food uneaten.

Necropsy examination revealed a pale liver and pneumonia with serohemorrhagic fluid in the thorax. Histological examination showed numerous small foci of necrosis in the liver, pneumonia with focal necrosis, and myocarditis. Numerous *T. gondii* tachyzoites were identified in liver, heart, and lungs by IHC performed at the APDL.

Two weeks later, the female kitten (FM015) became ill and was the first case to present with clinical illness. The animal was anorexic, depressed, dyspnoeic, and pyrexic. Treatment was initiated with the antibiotics marbofloxacin (s.c. 2 mg/kg, Marbocyl 1%, Vetoquinol, Lure Cedex, France) and amoxicillin (s.c. 15 mg/kg Betamox LA inj., Norbrook, Carlisle, United Kingdom), and NSAIDs (carprofen s.c., 3 mg/kg, Rimadyl, Pfizer, Vericore Ltd., Dundee, United Kingdom). Fluids (sodium lactate, Gulf Inject LLC, Dubai, UAE) and aminoacids (Duphalyte®, Fort Dodge, Vall de Bianya, Spain) were given subcutaneously.

Hematological evaluation revealed a slight anemia and a leukocytosis. Despite treatment, the animal died 4 days later. On necropsy, foci of necrosis were seen in the liver. Histopathology revealed multi-organ necrosis and inflammation, and on IHC, liver, lung, and heart were positive for *T. gondii*.

Third litter

One year later, the same pair of sand cats had a second litter, again one male and one female. The kittens were weighed twice a week in an attempt to detect disease in the early stages. They were developing normally until day 26, when the male (FM016) was found dead. No abnormalities in behavior had been noticed during physical examination the previous day; however, severe and widespread lesions were seen at necropsy (Fig. 1). There was serohemorrhagic fluid in the thorax and abdomen; diffuse small white foci of necrosis on the liver; severe pneumonia; and the heart had prominent linear areas of necrosis in the myocardium.

Bacterial culture of the hemorrhagic fluid was negative, as was viral screening for feline leukemia virus (FeLV) antigens and feline immunodeficiency virus (FIV) and feline coronavirus (FCoV) antibodies. Histopathology revealed severe inflammation and necrosis in the lung, liver, spleen, and heart. Protozoal tachyzoites were identified in all organs. An IHC evaluation (performed at APDL) confirmed the diagnosis of severe acute generalized toxoplasmosis. Parenchymal necrosis was most pronounced in the liver (Fig. 2). Within the spleen and the myocardium, a profuse growth of *T. gondii* tachyzoites was observed (Fig. 3).

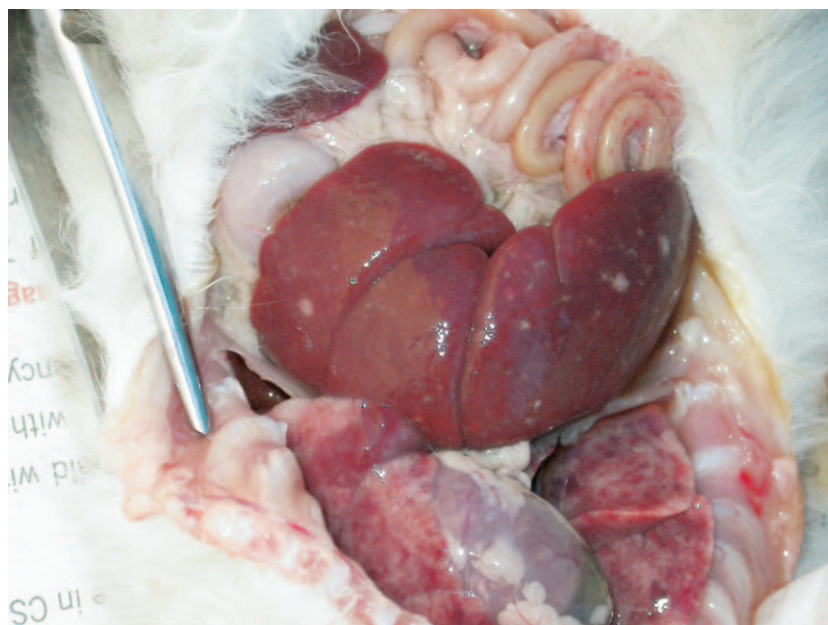


Figure 1. Sandcat FM016 liver and lungs at post-mortem examination. Grossly, the liver had multifocal areas of discoloration that were suggestive of necrosis. The lungs were edematous and focally congested.

Numerous tachyzoites were seen in hepatocytes; Kupfer cells; pulmonary macrophages and interstitium; renal glomeruli; myocardiocytes; large intestinal lamina propria and muscularis; and spleno-

cytes. A notable finding was the absence of lesions and protozoa in the brain and the absence of schizonts and gamonts in the intestine.

Based on protocols used for the prevention of

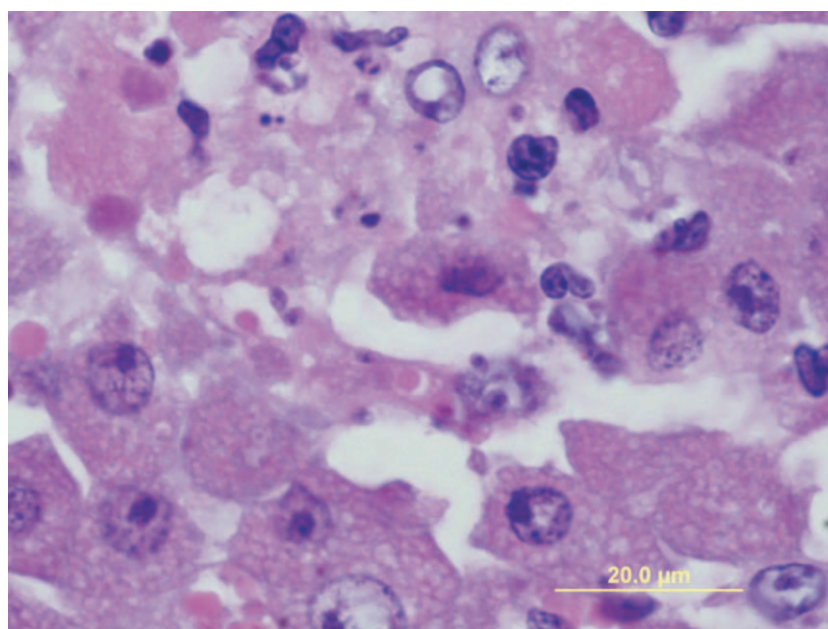


Figure 2. Histology of Sandcat FM016 liver. Necrotic hepatocytes with many individual protozoal tachyzoites scattered in the lesion, H&E.

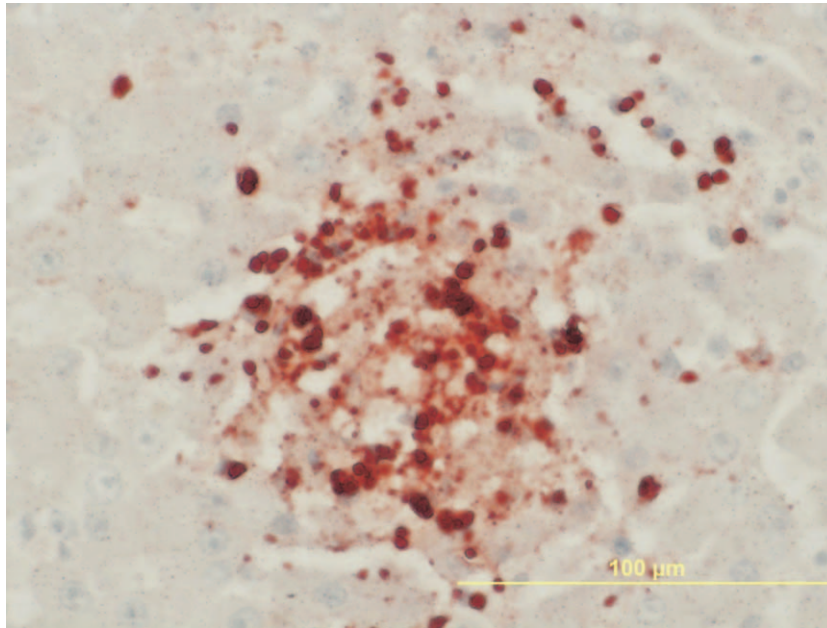


Figure 3. Sandcat FM016 liver section with tachyzoites immunohistochemically stained with polyclonal *T. gondii* antibodies.

toxoplasmosis-related deaths in Pallas kittens, it was decided to start the surviving kitten (FM017), which was then 27 days old, on a prophylactic course of clindamycin (Dalacin CTM, Pharmacia, Puurs, Belgium) at a dose of 20 mg/kg given orally with a syringe.^{1,28} Once the kitten started eating solid food, the clindamycin powder was disguised in liquid fat on the food.

The feeding regimen of the sand cats was assessed and altered to exclude any raw fresh meat, except for white rats and mice bred at the BCEAW. All other meat would be bought frozen or kept frozen at -20°C for at least 1 wk prior to feeding.

Blood was collected at the age of 51 days; antibodies to *T. gondii*, FeLV, FIV, and FCoV were not found. Hematological values were within the normal range. A general physical examination did not reveal any abnormalities or signs of illness.

A repeat blood sample at 4 mo of age was also negative for *T. gondii*. Given that there were no adverse reactions to the high dose of clindamycin, prophylactic treatment was continued for 15 wk. At 8 mo of age, another blood sample was collected. The kitten now had a modified agglutination test (MAT) titer of $>3,200$ although it was not ill.

At the age of 1 yr, however, it was observed to walk into objects and a severe bilateral mydriasis was seen. Direct and indirect pupil reflexes were negative and ophthalmological examination re-

vealed a partial degeneration of the retina. Blood samples excluded infections with FIV, FeLV, or *Bartonella* sp. Further differentials for retinal degeneration included taurine deficiency and feline infectious peritonitis, but no further indications could support these etiologies, leaving a retinitis caused by toxoplasmosis a very likely diagnosis.

Adults

During the same period (1999–2006), four adult sand cats (FM004, FM001, FM013, and FM010) also died. In three of these cases (FM004, FM013, and FM001), the clinical signs and/or the findings on necropsy could have been related to a *T. gondii* infection.

As mentioned above, recently recovered samples on formalin of FM004 were IHC negative for *T. gondii*. Samples of FM010, however, revealed an inert *T. gondii*-like tissue cyst in the lungs and lung worms, but IHC was negative for *T. gondii*. No samples from FM001 and FM013 were available for further analysis.

Serological examination for *T. gondii*

Serum from all the sand cats present at the BCEAW was collected and analyzed (Table 2). Serum that was collected and banked frozen at -20°C in previous years also was analyzed. Immunoglobulin G antibodies to *T. gondii* were determined for

Table 2. Antibodies to *Toxoplasma gondii* in sera of sand cats from the Breeding Centre for Endangered Arabian Wildlife.

Number	Gender	Age	Date sampled	Titer
				MAT ^a
FM 001	Female	>6 yr	Apr 2003	>3,200
		>7 yr	Mar 2004	>3,200
FM 005	Male	10 yr	Apr 2006	>3,200
FM 011	Female	5 yr	Jul 2003	>3,200
		8 yr	Jan 2006	>3,200
FM 012	Female	5 yr	Jul 2003	>3,200
FM 015	Female	3 mo	Jul 2005	200
FM 017	Female	4 mo	Jul 2006	<25
		8 mo	Nov 2006	3,200
				LAT
FM 002	Male	11 yr	Apr 2006	512
FM 005	Male	10 yr	Apr 2006	512
FM 011	Female	8 yr	Apr 2006	512
FM 017	Female	1 mo	Apr 2006	0

^a MAT, modified agglutination test; LAT, latex agglutination test.

a total of 12 samples collected from four adult females, two female kittens, and two adult males. Two of these animals were wild caught but had spent several years in captivity before samples were taken. All the other animals were captive born at the BCEAW or other centers.

Antibodies to *T. gondii* were determined using the MAT and the latex agglutination test (LAT). The MAT was performed at the APDL as described.¹¹ Based on extensive studies in experimentally infected cats, a cutoff titer of 1:25 is considered indicative of *T. gondii* infection.^{15–17} The LAT was performed at the University of Glasgow, Scotland, using a commercial kit (Eiken, Tokyo, Japan); a titer of 1:64 was used as a cutoff titer. These results revealed that all adult sand cats had been infected with *T. gondii* but that infections were subclinical (Table 2).

The youngest animal, FM017, whose sibling (FM016) died of generalized toxoplasmosis, did not have an antibody titer at 1.5 mo of age or at 4 mo of age. At 8 mo though, it had seroconverted. This finding indicates that either it did not receive maternal immunity or maternal immunity had already waned. When the first sibling died in this litter, the diet was changed to exclude fresh unfrozen meat. Because seroconversion can take place in as short as 1 wk after exposure in domestic cats, this kitten was thought to have been exposed to *T. gondii* between the ages of 4 and 8 mo, despite the prophylactic measures taken.¹⁶

Feeding protocol

The diet of all small carnivores at the BCEAW consisted of imported frozen buffalo and chicken meat; locally purchased fresh camel and donkey meat; frozen day-old chicks; and white mice and rats, pigeons, guinea fowl, and quail that had been bred at the BCEAW.

After the neonatal deaths were confirmed as being caused by toxoplasmosis, the sand cat diet was adapted to include only meat that had been frozen at -20°C for at least 1 wk or fresh mice and rats bred at the BCEAW.

Although a serious effort is made to keep the enclosures pest free, wild rodents, birds, and reptiles still can gain access and feral cats are sometimes found roaming within the grounds of the BCEAW. On one occasion, a partially eaten wild rodent was found in the enclosure of the female (FM011) with the surviving kitten (FM017).

Samples taken from feral pigeons and black rats trapped on the premises of the BCEAW were analyzed at the APDL. It was determined that 18.7% of rats ($n = 16$) and 3.8% of pigeons ($n = 26$) had antibodies to *T. gondii*.

The annual report of the Central Veterinary Research Lab in Dubai, UAE, for 2003, 2004, and 2005 stated that camels in the UAE have a seroprevalence for toxoplasma of 67%, 55%, and 53%, respectively. Two studies in feral cats performed by the same laboratory showed a seroprevalence ranging from 35–52% (Schuster, pers. comm., 2006, Central Veterinary Research Lab in Dubai, UAE, Annual report of 2003, 2004, and 2005).

DISCUSSION

Toxoplasmosis is a widespread infection that can affect a large range of species. However, most infections in domestic cats are subclinical and fatal toxoplasmosis is rare. Felids are the only definitive hosts in which *T. gondii* can complete its full life cycle; all other vertebrates only serve as intermediate hosts.⁸

Cats are thought to become infected with *T. gondii* mainly by ingesting tissues of infected intermediate hosts. When a cat becomes infected through this route, it will start shedding oocysts 3–10 days after ingestion of tissue cysts and can shed millions of oocysts for a period of 1–2 wk, thereby contaminating the surrounding environment. Oocysts are extremely resistant and can survive for long periods in the environment.⁵

Cats also can acquire a *T. gondii* infection by ingesting sporulated oocysts from the environment (food or water that has been contaminated with cat

feces). However, this is a less efficient route of infection because the infecting dose is high (1,000 oocysts or more) and only a few cats that are fed oocysts do shed oocysts. This is in marked contrast to the high infectivity of oocysts for herbivores, where it has been reported that pigs and mice can become infected with exposure to only one oocyst.⁷

Cats, like other hosts of *T. gondii*, also can become infected transplacentally and transplacentally infected kittens can shed oocysts.^{9,10,15} Congenital infection can cause severe mortality in kittens.^{9,25} Subclinical cases have been described in several wild feline species.^{4,26} Unlike the domestic cat, the Pallas cat (*Otocolobus manul*) is highly susceptible to generalized toxoplasmosis causing a high newborn mortality.^{13,21,22,28} In addition, unlike other hosts, *T. gondii* infection before pregnancy does not prevent congenital toxoplasmosis in Pallas cats.²⁸ In this respect, the sand cat appears similar to the Pallas cat.

In 2003, 2 yr before she had her first litter, the breeding female sand cat at the BCEAW (FM011) had a high antibody titer against *T. gondii*. Two months before her second litter she still had a high titer. However, this maternal immunity proved not to be protective for the kittens, because three out of four died with generalized toxoplasmosis, one of which was only 26 days old. Considering the prepatent period (3–10 days after ingesting tissue cysts or 18 days or longer after ingesting oocysts) and the fact that this kitten was still suckling and not yet eating solid food, this kitten was most likely infected via the transplacental or lactogenic route.⁶ The kittens that died at a later stage most likely became infected by ingestion of infected meat.

At the age of 6 wk, it was suspected that maternal antibodies would still be detected in the kitten of a dam with positive antibody titers. However, the titer was negative at this age for the surviving kitten (FM017), demonstrating that despite normal suckling, this kitten did not receive any maternal protection through the colostrum or milk, or, more unlikely at this age, that maternal immunity had already waned.

The most likely source of infection at the BCEAW was fresh camel or donkey meat. Although no method can be regarded as 100% effective, most *T. gondii* tissue cysts will be destroyed when meat is frozen and thawed, heated up to 67°C, or otherwise processed.^{14,23} Heating or processing the meat is not considered as an option at the BCEAW for nutritional and behavioral enrichment reasons. Therefore, meat for the sand cats is now frozen prior to feeding to reduce the incidence of

infection. Whole prey bred at the BCEAW, such as rats and mice, are still fed fresh.

The possibility of acquiring an infection by eating pest animals entering the enclosures must still be taken into consideration.

Brown et al. explored the ecological base for the extreme susceptibility of Pallas cats to fatal toxoplasmosis.² It was suggested that the conditions in which Pallas cats live, the extremely cold winters and the very high altitude, reduce the viability of *T. gondii* oocysts that may be shed into the environment. Hence, Pallas cats may not have co-evolved with this specific parasite. This theory also might be applicable to sand cats, which live in environments where temperatures are extreme. Because they are a secretive species that lives away from urbanization, they have very little contact with humans or feral cats.

Prophylaxis

Until an efficient vaccine is developed, environmental control should be the focus of prophylaxis. Tissue cysts are killed by soap and water; heating to 67°C; and freezing in a household freezer, although no method can be considered 100% effective.^{8,14,23} Environmental control should consist of meticulous management of susceptible species; feeding of cooked or frozen meat; thorough disinfection; and exclusion of stray and pest animals for the protection of collection animals, staff, and visitors.³⁰

Highly susceptible species might benefit from prophylactic treatments. In the Pallas cats, prophylaxis with clindamycin, toltrazuril, and diclazuril has been used to try to reduce the incidence of *T. gondii*-related neonatal deaths.²⁸

These protocols are still under discussion and more research is needed to evaluate their effectiveness. The therapeutic agents used may arrest tachyzoite multiplication and alleviate symptoms in an acute infection but do not prevent the animal from becoming infected.¹⁸ It is crucial that the medication be administered at high doses for a very long period or until the animal has seroconverted. Providing such high doses for a prolonged period might be detrimental to the young animal; however, the prophylactic treatment with diclazuril seems to be safe and promising in the Pallas cat.²⁹

CONCLUSION

The sample size here is too small to make general conclusions about a higher susceptibility for generalized toxoplasmosis in newborn sand cats. The surprising fact that maternal immunity was not protective to the kittens and that consecutive litters

of the same female died with generalized toxoplasmosis, however, are intriguing and simulates the clinical outcome of toxoplasmosis in Pallas cats.

Acknowledgments: We would like to acknowledge His Highness Dr. Sheikh Sultan bin Mohammed al Qassimi, Ruler of Sharjah, for his support of the project and Jane Edmonds as Section Head of Department Felids at the Breeding Centre for Endangered Arabian Wildlife.

LITERATURE CITED

1. Basso, W., R. Edelhofer, W. Zenker, K. Möstl, A. Kübber-Heiss, and H. Prosl. 2005. Toxoplasmosis in Pallas's cats (*Otocolobus manul*) raised in captivity. *Parasitology* 130: 293–299.
2. Brown, M., M. R. Lappin, J. L. Brown, B. Munkhtsog, and W. F. Swanson. 2005. Exploring the ecologic basis for extreme susceptibility of Pallas cats (*Otocolobus manul*) to fatal toxoplasmosis. *J. Wildl. Dis.* 41: 691–700.
3. Conservation Breeding Specialist Group (SSC/IUCN). 2000. Conservation Assessment and Management Plan for Arabian Carnivores and Population and Habitat Viability Assessment for the Arabian Leopard and Tahr: Final Report. Conservation Breeding Specialist Group, Apple Valley, Minnesota.
4. Dorny, P., and J. Fransen. 1989. Toxoplasmosis in a Siberian tiger (*Panthera tigris altaica*). *Vet. Rec.* 125: 647.
5. Dubey, J. P. 2004. Toxoplasmosis—a waterborne zoonosis. *Vet. Parasitol.* 126: 57–72.
6. Dubey, J. P. 2005. Unexpected oocyst shedding by cats fed *Toxoplasma gondii* tachyzoites: in vivo stage conversion and strain variation. *Vet. Parasitol.* 133: 289–298.
7. Dubey, J. P. 2006. Comparative infectivity of oocysts and bradyzoites of *Toxoplasma gondii* for intermediate (mice) and definitive (cats) hosts. *Vet. Parasitol.* 140: 69–75.
8. Dubey, J. P., and C. P. Beattie. 1988. Toxoplasmosis of Animals and Man. CRC Press, Boca Raton, Florida. Pp. 1–220.
9. Dubey, J. P., and J. L. Carpenter. 1993. Neonatal toxoplasmosis in littermate cats. *J. Am. Vet. Med. Assoc.* 203: 1546–1549.
10. Dubey, J. P., and J. L. Carpenter. 1993. Histologically confirmed clinical toxoplasmosis in cats—100 cases (1952–1990). *J. Am. Vet. Med. Assoc.* 203: 1556–1566.
11. Dubey, J. P., and G. Desmots. 1987. Serological responses of equids fed *Toxoplasma gondii* oocysts. *Equine Vet. J.* 19: 337–339.
12. Dubey, J. P., M. M. Garner, M. M. Willette, K. L. Batey, and C. H. Gardiner. 2001. Disseminated toxoplasmosis in magpie geese (*Anseranas semipalmata*) with large numbers of tissue cysts in livers. *J. Parasitol.* 87: 219–223.
13. Dubey, J. P., A. P. Gendron-Fitzpatrick, A. L. Lenhard, and D. Bowman. 1988. Fatal toxoplasmosis and enteroepithelial stages of *Toxoplasma gondii* in a Pallas cat (*Felis manul*). *J. Protozool.* 35: 528–530.
14. Dubey, J. P., A. W. Kotula, A. Sharar, C. D. Andrews, D. S. Lindsay. 1990. Effect of high temperature on infectivity of *Toxoplasma gondii* tissue cysts in pork. *J. Parasitol.* 76: 201–204.
15. Dubey, J. P., M. R. Lappin, and P. Thulliez. 1995. Diagnosis of induced toxoplasmosis in neonatal cats. *J. Am. Vet. Med. Assoc.* 207: 179–185.
16. Dubey, J. P., M. R. Lappin, and P. Thulliez. 1995. Long-term antibody responses of cats fed *Toxoplasma gondii* tissue cysts. *J. Parasitol.* 81: 887–893.
17. Dubey, J. P., and P. Thulliez. 1989. Serologic diagnosis of toxoplasmosis in cats fed *Toxoplasma gondii* tissue cysts. *J. Am. Vet. Med. Assoc.* 194: 1297–1299.
18. Dubey, J. P., and R. A. Yeary. 1977. Anticoccidial activity of 2-sulfamoyl-4,4-diaminodiphenylsulfone, sulfadiazine, pyrimethamine, and clindamycin in cats infected with *Toxoplasma gondii*. *Can. Vet. J.* 18: 51–57.
19. Environment and Protected Areas Authority. 2004. Conservation Workshop for the Fauna of Arabia. Breeding Centre for Endangered Arabian Wildlife, Sharjah, United Arab Emirates.
20. Hammer, C., and S. Hammer. 2005. Sandkatzenhaltung (*Felis margarita harrisoni*) in Al Wabra Wildlife Preservation (AWWP). *Zool. Garten N. F.* 75: 145–161.
21. Kenny, D. E., M. R. Lappin, F. Knightly, J. Baier, M. Brewer, and D. M. Getzy. 2002. Toxoplasmosis in Pallas' cats (*Otocolobus felis manul*) at the Denver Zoological Gardens. *J. Zoo Wildl. Med.* 33: 131–138.
22. Ketz-Riley, C. J., J. W. Ritchey, J. P. Hoover, C. M. Johnson, and M. T. Barrie. 2003. Immunodeficiency associated with multiple concurrent infections in captive Pallas' cats (*Otocolobus manul*). *J. Zoo Wildl. Med.* 34: 239–245.
23. Kotula, A. W., J. P. Dubey, A. K. Sharar, C. D. Andrew, S. K. Shen, and D. S. Lindsay. 1991. Effect of freezing on infectivity of *Toxoplasma gondii* tissue cysts in pork. *J. Food Prot.* 54: 687–690.
24. Lindsay, D. S., and J. P. Dubey. 1989. Immunohistochemical diagnosis of *Neospora caninum* in tissue sections. *Am. J. Vet. Res.* 50: 1981–1983.
25. Nelson, R. W., and C. G. Couto. 2003. Polysystemic protozoal infections. *In: Small Animal Internal Medicine*, 3rd ed. Mosby, St. Louis, Missouri. Pp. 1296–1298.
26. Ocholi, R. A., J. O. Kalejaiye, and P. A. Okewole. 1989. Acute disseminated toxoplasmosis in two captive lions (*Panthera leo*) in Nigeria. *Vet. Rec.* 124: 515–516.
27. Sausman, K. 1997. Sand Cat *Felis margarita* International Studbook 31 December 1997. Pp. 1–4.
28. Swanson, W. F. 1999. Toxoplasmosis and neonatal mortality in Pallas' cats: a survey of North American zoological institutions. *Proc. AAZV.* 1999: 347–350.
29. Swanson, W. F., J. Bond, and M. Bush. 2001. Assessment of diclazuril toxicity in neonatal domestic cats and initial application for prevention and treatment of toxoplasmosis in neonatal Pallas' cats. *Proc. AAZV, AAWV, ARAV, NAZVW Joint Conf.* 2001: 390–391.
30. Wolfe, B. A. 2003. Toxoplasmosis. *In: Fowler, M. E., and R. E. Miller (eds.). Zoo & Wild Animal Medicine*, 5th ed. W. B. Saunders Co., Philadelphia, Pennsylvania. Pp. 745–749.

Received for publication 27 November 2007