

Paleontological Contributions

June 21, 2010

Number 2

SKULL OF THE EOCENE PRIMATE *OMOMYS CARTERI* FROM WESTERN NORTH AMERICA

Benjamin John Burger

University of Colorado Museum of Natural History, Boulder, Colorado 80309, USA;
present address: SWCA Environmental Consultants, 2028 W. 500 N. Vernal, Utah 84078, USA
e-mail: benjamin.burger@colorado.edu

ABSTRACT

The description of a skull of the omomyid primate *Omomys carteri* from the middle Eocene Bridger Formation of southwestern Wyoming provides important new information relevant to our understanding of Eocene primate systematics and evolution. More specifically, *Omomys carteri* exhibits a long and wide nasal region and lacks the forward orientation of the orbits found in other omomyid primates. Furthermore, other features such as an unreduced cranial arterial system, primitive auditory bulla, expanded internal choanae, and an unreduced canine indicate that the cranium of *Omomys carteri* is primitive. Phylogenetic analysis of 52 cranial, 194 dental, and 56 postcranial characters, including the new characteristics of *Omomys carteri* discussed here, suggests that omomyiforms belong to a monophyletic tarsiiform clade exclusive of anthropoids. Anthropoids are still viewed as a sister group to tarsiiforms, forming a haplorhine clade, with an uncertain position for the problematic fossil primate *Rooneyia*. The reconstructed cranial anatomy of the haplorhine morphotype is more primitive than originally thought and likely exhibited many of the primitive traits featured in the skull of *Omomys carteri*.

Keywords: mammal, haplorhine, tarsiiform, omomyiform, anatomy, Bridger Formation

INTRODUCTION

While working with parties from the American Museum of Natural History under the direction of John Alexander in the summer of 1998, a fragmentary primate skull was found eroding from a light grey to green mudstone from the middle Eocene Bridger Formation, Blackfork Member (Bridger B) in southwestern Wyoming. The new skull features a large nasal region and large orbits, a combination not typically found in primates. Most living primates have reduced nasal regions to accommodate forward-facing orbits, with high levels of stereoscopic vision. The middle Eocene primate skull still retained a large nasal region. Other characteristics of the new fragmentary skull revealed that this primate exhibited many primitive characteristics, not typical of modern primates. Incorporating this new, fascinating skull into what we know about

the evolution of early primates, this paper seeks to provide a better picture of primate evolution during the Eocene.

Eocene primates are traditionally grouped into two infraorders: the smaller-bodied, mostly nocturnal Omomyiformes, and the larger, diurnal Adapiformes. In North America, adapiforms are well known from several nearly complete skeletons (*Notharctus* and *Smilodectes*) and skulls (*Cantius*, *Notharctus*, *Smilodectes*, and *Mahgarita*) (Gregory, 1920; Gazin, 1958; Gingerich, 1981a, 1981b; Gingerich & Martin, 1981; Rose and Walker, 1985; Alexander, 1992, 1994; Gunnell, 1995a; Hamrick and Alexander, 1996; Rose, MacPhee, & Alexander, 1999). In Europe, Adapiformes include the recently described *Darwinius* skeleton from Messel (Franzen & others, 2009), as well as larger, late Eocene primates known from complete skulls, such as *Adapis*, *Leptadapis*, and *Magnadapis* (Godinot & Couette, 2008). Skeletal material and skulls of

omomyiforms are considerably less common. Skulls of only two other species of North American omomyiforms (*Shoshonius cooperi* and *Tetonius homunculus*) have been described (Wortman, 1904; Beard, Krishtalka, & Stucky, 1991; Beard & MacPhee, 1994). Omomyiforms are subdivided into the European Microchoeridae, consisting of five genera, and the mostly North American Omomyidae, comprising 35 genera (Tornow, 2008). Only four genera of Omomyiformes are found in Asia, including *Teilhardina* and *Macrotarsius*, which are also known in North America (Beard & MacPhee, 1994; Rose, Godinet, & Bown, 1994). During the late Eocene, North American Adapiformes and Omomyiformes died off, with only the anomalous omomyiform *Ekgmowechashala* surviving into the early Oligocene.

Examination of the preserved teeth on the fragmentary skull reveal that the specimen belongs to *Omomys carteri*, an omomyiform primate known from fossilized teeth since its early discovery in 1869 (Leidy, 1869). Knowledge of this small primate from Wyoming has been increasing rapidly. In 1993, a field crew from the University of Colorado under the direction of Peter Robinson discovered an unusual accumulation of *Omomys carteri* teeth, jaws, and associated postcranial skeletons from rocks located in the stratigraphically higher Twin Buttes Member (Bridger C) of the Bridger Formation (Anemone & Covert, 2000; Murphey, 2001). Although no skulls were found from the so-called *Omomys* quarry, several isolated petrosal bones were found and described (Ross & Covert, 2000). The postcranial bones show osteological correlates to quadrupedal climbing and leaping among modern primates, like the Dwarf Lemur (*Cheirogaleus*) and Giant Mouse Lemur (*Mirza*) of Madagascar, and similarities to other fossil omomyid primates from the Eocene, such as *Hemiacodon* (Anemone & Covert, 2000). From isolated maxillary bones and preserved upper teeth, the lower margin of the orbit demonstrates a very large orbit for *Omomys carteri*, indicating a specialization for nocturnal activity (Heesy & Ross, 2001). Until now, there have been many missing pieces. The new fragmentary skull fills these missing pieces in showcasing what *Omomys carteri* actually looked like.

The fragmentary skull was recovered in three pieces that had eroded out of a light grey to green mudstone located 26.4 m below the Church Butte Tuff (dated 47.96 \pm 0.13 Ma; Murphey & others, 1999) in the Blackfork Member of the Bridger Formation, in the Br2 Biozone (Gunnell & others, 2009). The morphology of this new skull is strikingly dissimilar to other Omomyiformes for which skulls are known, particularly in its retention of primitive features, such as a robust snout. The purpose of this paper is to describe the cranial anatomy of *Omomys carteri* and draw comparisons with other fossil primate skulls from the Eocene epoch.

INSTITUTIONAL ABBREVIATIONS

AMNH FM: American Museum of Natural History (New York), Division of Paleontology Fossil Mammal Collection; AMNH CA: American Museum of Natural History (New York), Division of Paleontology Comparative Osteology Collection; AMNH MM: American Museum of Natural History (New York), Division of Zoology Mammal Collection; ANS: Academy of Natural Sciences (Philadelphia); USNM: United States National Museum (Smithso-

nian Institutions, Washington, D.C.); UCM: University of Colorado Museum Geology Section (Boulder); UTBEG: University of Texas at Austin Bureau of Economic Geology; MNHN-P: National Museum d'Histoire Naturelle Paleontologie (Paris); SDNHM: San Diego Natural History Museum Paleontology Collection; CM: Carnegie Museum of Natural History (Pittsburgh).

MATERIALS AND METHODS

AMNH FM 130000 *Omomys carteri*, with the following specimens referenced for comparison: AMNH FM 12041 *Omomys carteri*; AMNH FM 4204 *Tetonius homunculus*; AMNH MM 166856 *Tarsius* sp.; AMNH CA 269 *Nycticebus* sp.; MNHN-P Montauban 9 *Necrolemur antiquus* (cast); MNHN-P QU 11059 *Necrolemur antiquus* (cast); UTBEG 40688-7 *Rooneyia viejaensis* (cast); as well as published and figured specimens of *Shoshonius* and *Teilhardina*, among other Eocene primates.

SYSTEMATIC PALEONTOLOGY

Class MAMMALIA Linnaeus, 1758

Order PRIMATES Linnaeus, 1758

Suborder EUPRIMATES Hoffstetter, 1977

Infraorder HAPLORHINI Pocock, 1918

Pavorder TARSIFORMES Gregory, 1915

Family OMOMYIDAE Trouessart, 1879

Genus OMOMYS Leidy, 1869

OMOMYS CARTERI Leidy, 1869

Figure 1–10

Hemiacodon nanus Marsh, 1872, p. 213.

Hemiacodon pucillus Marsh, 1872, p. 213.

Omomys pucillus Wortman, 1904, p. 133.

Euryacodon lepidus Marsh, 1872, p. 223.

Palaeacodon vagus Marsh, 1872, p. 224.

Type species.—Holotype, ANS 10335 dentary with P₃, P₄, and M₂, Hypodigm AMNH FM 12041 maxilla with P³, P⁴, M¹, M² (Gazin, 1958, p. 109, pl. 7,5; pl. 6,4).

Occurrence.—Western United States, including Wyoming, Colorado, and Utah. First appearance at the Bridgerian Br1a zone and questionably extends into the Uintan Land Mammal Age (middle Eocene) (Robinson & others, 2004; Tornow, 2008).

Revised diagnosis.—*Omomys carteri* is distinguished by its size, unreduced upper third molar, lack of crenulated enamel on upper molars, with moderate to small paraconule and metaconule cusps, unreduced cusps on upper fourth premolar, and no deep separation between paraconid and metaconid cusps in lower molar. *Omomys carteri* is a slightly larger species than *Omomys lloydi*.

Description.—The focus of this study, AMNH FM 130000, preserves the nasal, frontal, and maxillary regions on both sides of the cranium (Fig. 1). The orbital region and upper dentition are preserved on the right side, and the squamosal and auditory region are preserved on the left side (Fig. 2). The cranium preserves the alveoli for i¹⁻², the alveolus for a large canine, and p²–m². The mesial

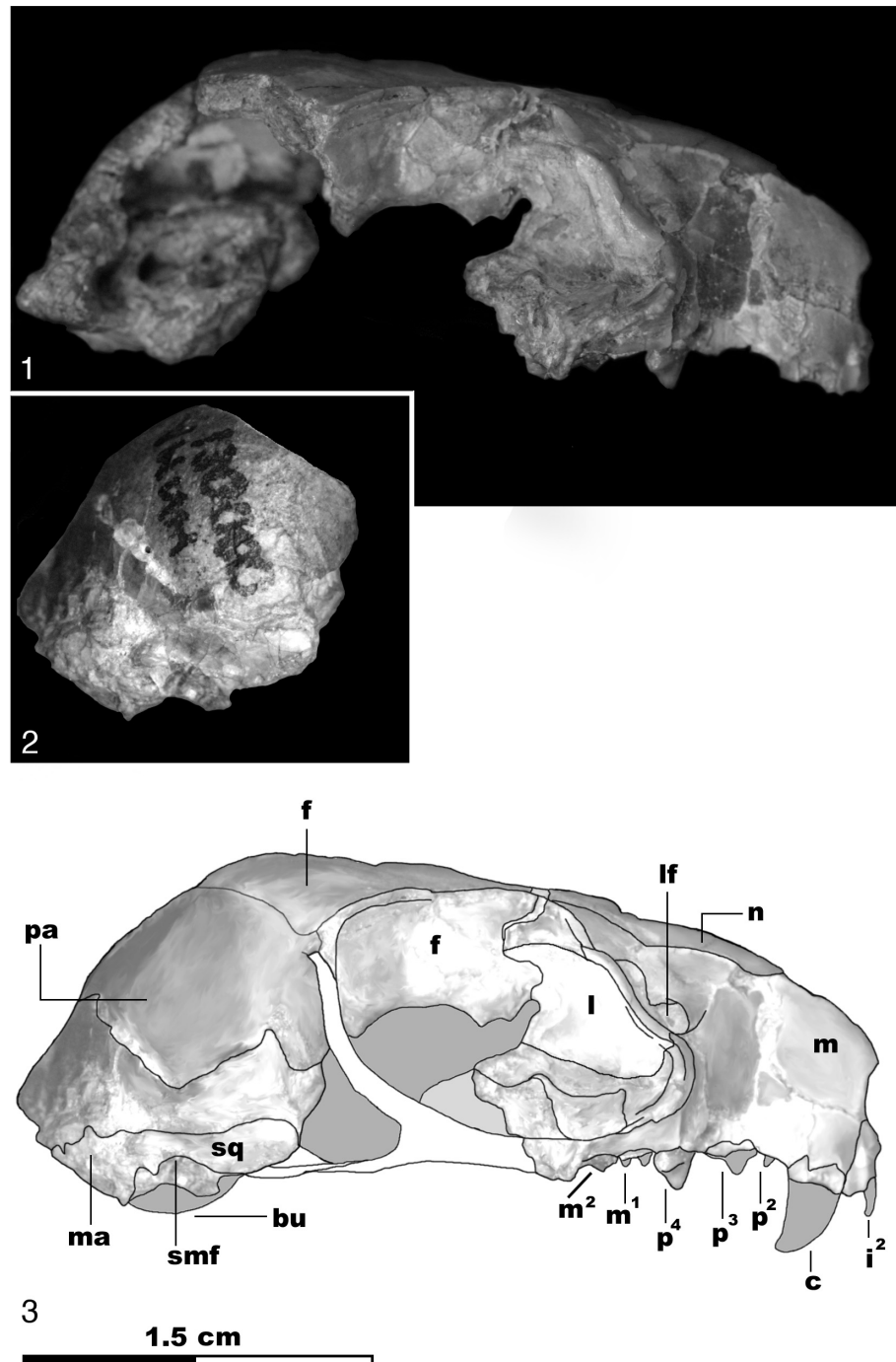


Figure 1. 1, Lateral view, right side of skull, *Omomys carteri* (AMNH FM 130000); 2, mirrored view, left side of parietal bone, *Omomys carteri* (AMNH FM 130000); 3, reconstruction of skull, *Omomys carteri*; *f*, frontal; *lf*, lacrimal foramen; *l*, lacrimal; *n*, nasal; *m*, maxilla; *pa*, parietal; *ma*, mastoid; *smf*, suprameatal foramen; *bu*, auditory bulla; *sq*, squamosal. Dental formula: i^2 , upper second incisor; *c*, canine; p^2 , second premolar; p^3 , third premolar; p^4 , fourth premolar; m^1 , first molar; m^2 , second molar (new).

half of the m^3 is also present (Fig. 3). A poorly preserved dentary, with a single lower first molar, was found occluded with the upper dentition. The orbitosphenoid and ethmoid (if present) are not preserved in the medial orbit, leaving only the frontal, lacrimal, and maxilla of the outer orbit preserved on the right side. The outline of the outer orbit is compressed, indicating that the skull is

slightly crushed dorsoventrally (Fig. 1). Overall, the orbital rim is preserved along the right frontal and maxillary bones, about 50% of the total orbit, with a small notch missing from the frontal and maxillary contact (Fig. 2.1–2.2). The pterygoids are not preserved, as much of the anterior basicranium is missing. A partial parietal and basioccipital, including the margin of the foramen magnum,

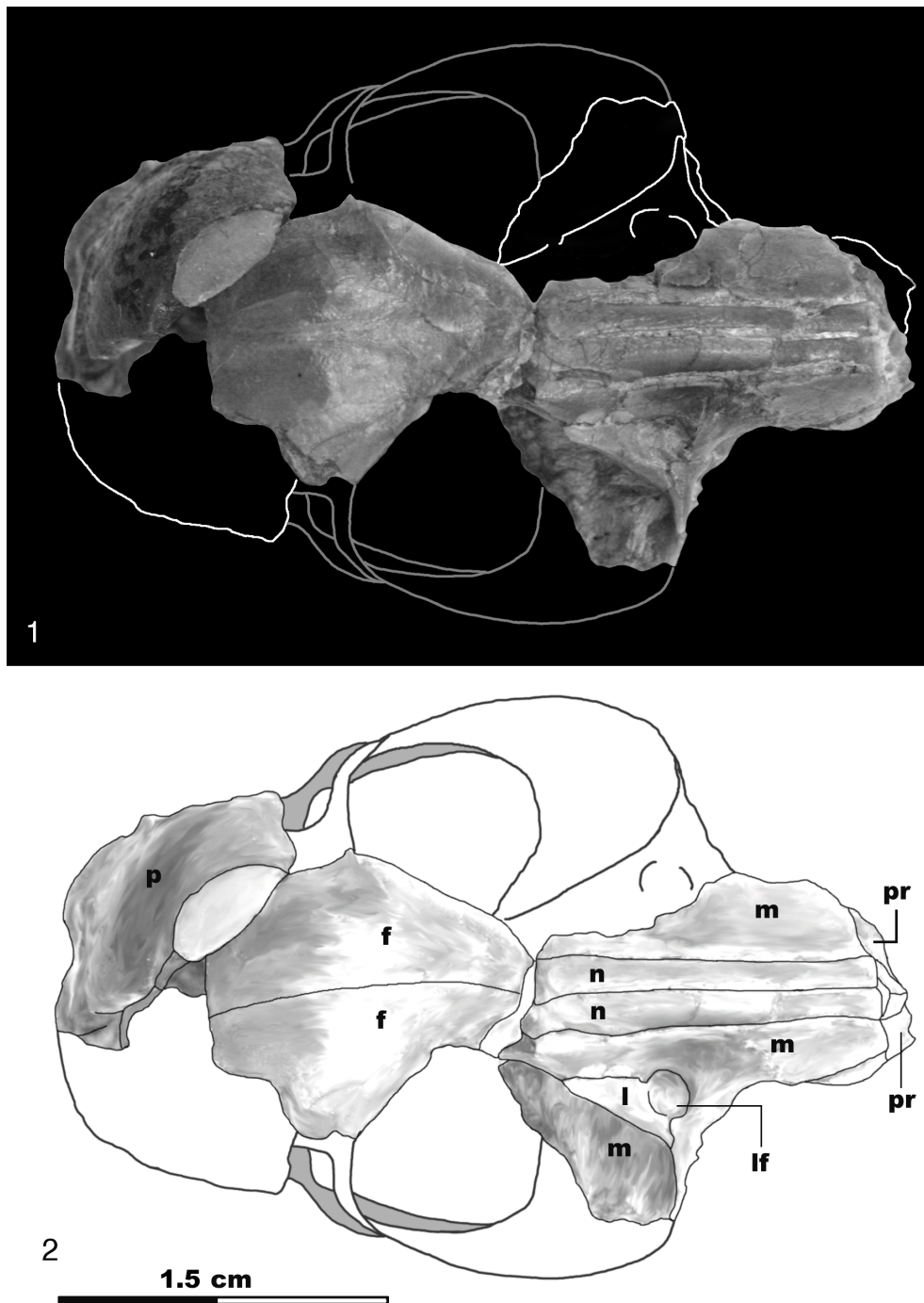


Figure 2. 1, Dorsal view of skull, *Omomys carteri* (AMNH FM 130000); 2, dorsal view; *p*, parietal; *f*, frontal; *n*, nasal; *m*, maxilla; *lf*, lacrimal foramen; *l*, lacrimal; *pr*, premaxilla (new).

are preserved on the left side (Fig. 4). See Table 1 for a listing of measurements for *Omomys carteri*.

Dentition.—The dental morphology of AMNH 130000 is virtually identical to that of a hypodigm of *Omomys carteri* (AMNH FM 12041, a maxilla consisting of p^3 – m^2) (see Szalay, 1976, p. 260, fig. 64). *Omomys* dental formula is interpreted as $i^2/l_2 c^1/l_1 p^3/l_3 m^3/l_3$. Measuring 2.21 mm in width, a large alveolus for the canine extends the maxilla laterally at the level of the incisive foramen. The basal enamel of i^2 is present and indicates a diminutive incisor.

The p^3 is long and medial. Between the p^3 and canine alveolus is a small alveolus for the p^2 , confirming that *Omomys carteri* retained three upper premolars. It preserves a narrow p^4 , however the cusps on the m^1 are not distinguishable. The m^2 features an extensive postcingulum. The paraconule and metaconule are centrally located, with a wide and deep protofossa basin.

Maxilla.—The broad maxillary bones project anteriorly, forming a long and wide muzzle (Fig. 1). The right side of the maxilla is complete from the midline of the third upper molar, while the

Table 1. Measurements of *Omomys carteri*, AMNH FM 130000 (new).

Area measured	Measurement	Area measured	Measurement
Canine length	2.41 mm	Length of right maxilla	23.8 mm
Canine width	2.21 mm	Maxillary depth	9.7 mm
p2 length	1.25 mm	Length of nasal bone	15.1 mm
p2 width	1.84 mm	Width of nasal bone	2.0 mm
p3 length	2.55 mm	Preorbital rostrum length	9.8 mm
p3 width	1.90 mm	Estimated skull length	42.5 mm
p4 length	2.25 mm	Width of orbit	13.0 mm
p4 width	3.12 mm	Intraorbital breadth	12.0 mm
m2 width	2.00 mm	Foramen magnum width	6.0 mm
m2 length	3.60 mm	Foramen magnum height	5.6 mm

left side preserves only the contact with the nasal and the rostrum anterior to the plane of the third upper molar (Fig. 1, Fig. 3). Paired, large, incisive foramina are present between the maxilla and the premaxilla (Fig. 3). The measured length of the right maxilla is 23.8 mm from the margin of the orbit to its anterior end. The maxillary depth is 9.7 mm, measured from the suture of the nasal to the fourth premolar.

Nasals.—The nasals of *Omomys carteri* are long and uniform in width throughout the length of the face, each measuring 15.1 mm in length and 2.0 mm in width (Fig. 2). The nasals exhibit little in the way of reduction and are convex in profile, which is atypical of primate skulls. Long, convex nasals are also found in primitive adapiforms such as *Pronycticebus*. Posteriorly the nasals end in a narrow contact directly with the frontal, forming a transverse suture that served as the original breakage point of the specimen.

Premaxilla.—The premaxillaries are poorly preserved and attached to the broad anterior suture of the maxilla. It is unclear how much of the anterior snout would have been composed of the premaxilla. However, it can be confirmed from the preserved alveoli on the right side that the upper incisors were vertically oriented (Fig. 1, Fig. 3). The bones comprising the margin of the external nares in living primates range from the broad premaxilla, as in lorises and galagos, to a highly reduced ventral and narrow premaxilla just containing incisor alveoli, as in tarsiers. Based on the poor preservation of the premaxilla on AMNH FM 130000, the upper interincisal gap cannot be accurately calculated. Given a total preserved preorbital rostrum length of 9.8 mm, it is likely that the maxilloturbinate was more extensive in *Omomys carteri* than in living haplorhines, such as tarsiers.

Lacrimal.—The lacrimal on the right side of the skull preserves both of its contacts with the frontal and maxilla (Fig. 1.3). It expands dorsally outside of the orbit, with the specimen's original breakage point occurring between the frontal and lacrimal (Fig. 1.3). The position of the lacrimal bone outside of the orbit is primitive, as is the wide intraorbital region. Contained within the maxilla and lacrimal contact, the large lacrimal foramen heavily indents the area just anterior to the margin of the right orbit (Fig. 1.3).

Orbit.—The maximum horizontal width of the orbit, taken from the preserved semicircle, is 13.0 mm, which is less than previous estimates of the orbital width of *Omomys* (Heesy & Ross, 2001). When the orbit size is scaled to the skull length of 42.5 mm, *Omomys* has an orbit width to skull length ratio of 0.30. The angle

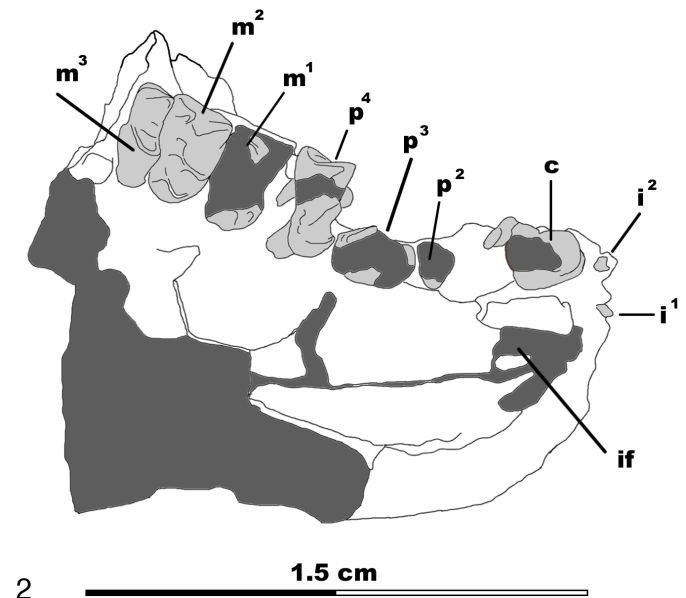



Figure 3. 1, Ventral view of palate of skull, *Omomys carteri* (AMNH FM 130000); 2, palate; *if*, incisive foramen. Dental formula: i^1 , first incisor; i^2 , second incisor; *c*, canine; p^2 , second premolar; p^3 , third premolar; p^4 , fourth premolar; m^1 , first molar; m^2 , second molar; m^3 , third molar (new).

between the plane formed by the frontal margin of the orbit and the midsagittal plane of the skull measures 30° . The angle formed by intersection of the axis of the maxillary tooth row and orbital plane is 25° at a minimum, which is less than the same angle in the skull of *Necrolemur* (33.5° ; MNHN-P QU 11059). The intraorbital breadth on AMNH FM 130000 is 12.0 mm, which is several mm wider than in other primates of similar size, such as tarsiers and nocturnal lemurs and lorises (Martin, 1990).

Frontal bones.—The frontal bones are well preserved on both sides of AMNH FM 130000 and are in contact across the fused metopic suture (Fig. 2). Both frontals preserve the margins of the orbit and lack the projecting rim of bone on the superior

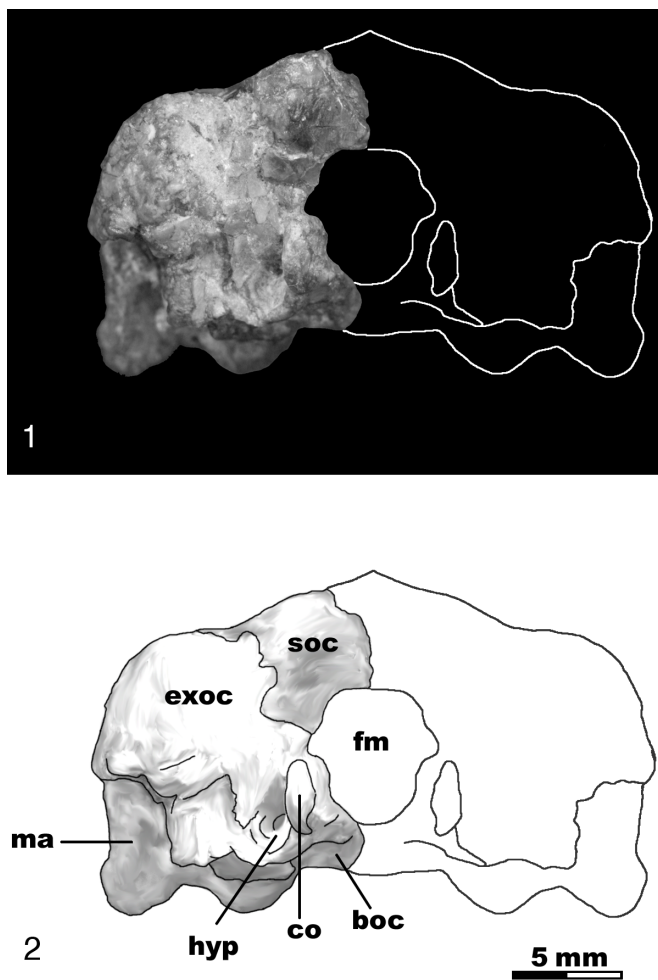


Figure 4. 1, Posterior view of back of brain case, *Omomys carteri* (AMNH FM 130000); 2, back of brain case; *soc*, supraoccipital; *exoc*, exoccipital; *ma*, mastoid; *co*, occipital condyle; *boc*, basioccipital; *hyp*, hypoglossal foramen; *fm*, foramen magnum (new).

margin of the orbit, a feature found in living tarsiers. The inner orbital region of both frontals is preserved, indicating that the frontal bone contributed to a large area of the superior region of the orbit. Given the unexpanded lateral intraorbital region of the frontal bone posteriorly, it can be concluded that *Omomys* lacked a frontal postorbital septum (Fig. 1).

Parietal.—The parietal bone is preserved on the left side of the skull, but does not articulate with the left frontal bone; a wedge of the cranium that would have provided this contact is missing (Fig. 2). The scars for the temporalis muscle are not preserved, as the outer layer of the bone has been lost. Although the parietal is fragmentary, it indicates that the brain of *Omomys* appears less expanded than in living primates of comparable size.

Basioccipital.—A complete left basioccipital is preserved. The foramen magnum measures 6.0 mm in height and 5.6 mm in width, measured by doubling the distance to the midline from the preserved left side. It is in proportion to that of other similar-sized primates. Unlike tarsiers, which have a narrow, collar-shaped occipital condyle, the skull of *Omomys* has a small, short, broad occipital condyle (Fig. 4, Fig. 5). The hypoglossal foramen is

large and sits in a deep fossa just lateral to the lowest point on the occipital condyle. Basally, the basioccipital extends ventrally and overlaps slightly with the moderately inflated tympanic bulla (Fig. 5).

Squamosal.—A small portion of the squamosal bone is present on the left side of the cranium. An enlarged mastoid process projects posteriorly, constituting a significant portion of the back of the cranium.

Tympanic bulla.—The entire ossified bulla was cast and removed during preparation in order to reveal the underlying structure of the middle ear cavity (Fig. 5). AMNH FM 130000 exhibits the derived primate condition of an ossified bulla composed of the petrosal, although a small flange of the basioccipital bone contributes to a small portion of the bulla posteriorly. The morphology and position of this bone is variable among major groups of primates and hence is an important indicator of phylogenetic relationships (MacPhee & Cartmill, 1986). The posterior carotid foramen, on the anterior end of the auditory bulla, courses medially into the middle ear cavity. Initially, the skull (AMNH FM 130000) was described as having a phaneric ectotympanic, indicating that the ectotympanic lay outside of the petrosal bulla (Alexander & MacPhee, 1999). Upon closer examination, the ectotympanic is interpreted as laying primarily outside of the bulla: phaneric, but with an overlap of the petrosal over its ventral surface. The lateral edge of the ectotympanic is unbroken, indicating that *Omomys* lacked an expanded tubular ectotympanic. Overall, the condition of the ectotympanic is primitive in that it is not completely enveloped by the petrosal bulla, nor is it expanded into a long, bony tube.

Middle ear cavity.—A conspicuous, bulbous promontorium is preserved on the ventral surface of the middle ear cavity (Fig. 5, Fig. 6). Arterial canals cross its surface longitudinally. The promontorium is auricular in shape around the fenestra cochlea (fenestra rotunda), which leads to the coiled cochlea of the inner ear cavity. A small, unnamed bony flange is present just medial to the promontory canal (Fig. 6.2, *stf*); this structure is also seen in the figured specimen (UCM 57460) described by Ross and Covert (2000). In tarsiers and anthropoids, a transverse septum arises with the carotid canal at the anterior end of the promontorium to divide the middle ear cavity and create the anterior accessory cavity from the middle ear cavity proper (MacPhee & Cartmill, 1986; Beard & MacPhee, 1994). Based on UCM 57460 and two other isolated petrosals of *Omomys*, Ross and Covert (2000) concluded that there was no such evidence for a transverse septum. Rather, the new skull exhibits a laterally oriented septum extending from the promontorium, serving as the floor of the auditory tube as in other omomyid skulls (Beard & MacPhee, 1994).

The fenestra vestibuli (fenestra ovalis) is exposed, with the stapedial canal entering its posterior edge. The cochleariform process hooks over the fenestra vestibuli (fenestra ovalis). In life, this process would have provided a pulley for the tensor tympani muscle, as it ran its course from the eustachian (auditory) tube to the muscular process of the malleus. Contractions of this muscle in living primates pull the tympanic membrane medially to restrict its movement. The fossa for the tensor tympani muscle can be seen in the auditory tube, running behind the posteromedial surface of the incus. The course of the second muscle of the middle ear,

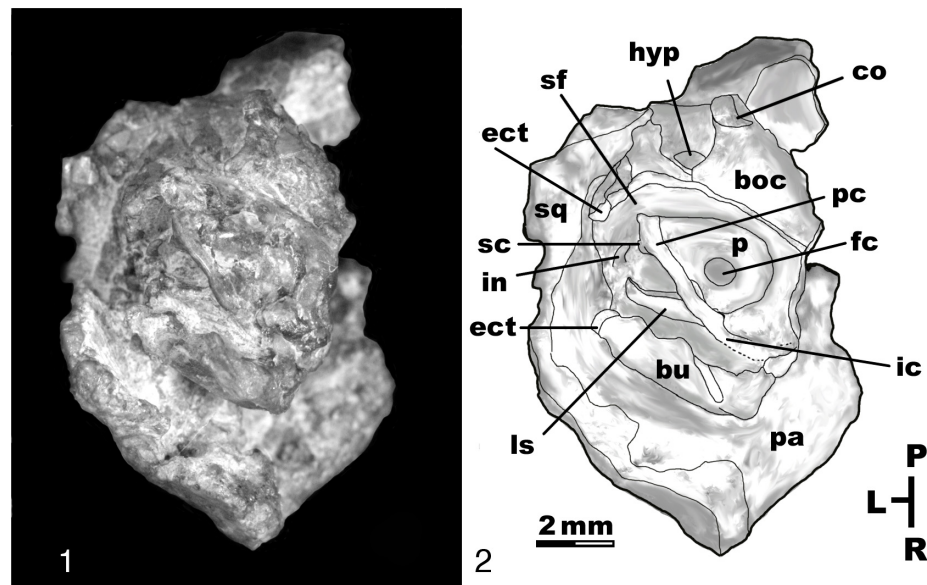


Figure 5. 1, Ventral view of auditory region; 2, ventral view of auditory region; *boc*, basioccipital; *bu*, auditory bulla; *ect*, ectotympanic; *fc*, fenestra cochleae; *hyp*, hypoglossal foramen; *ic*, internal carotid canal; *in*, incus; *ls*, lateral septum; *oc*, occipital condyle; *p*, promontorium; *pa*, parietal; *pc*, promontory canal; *sc*, stapedial canal; *sf*, stylomastoid foramen; *sq*, squamosal; L, lateral; P, posterior; R, rostral (new).

the stapedius, is inferred to have passed down the facial canal, originating from a stapedius fossa, which is preserved dorsal and medial to the sectioned stylomastoid foramen. The position of this fossa outside the auditory bulla has been regarded as a primitive character also found in living tarsiers (MacPhee, 1981; Beard & MacPhee, 1994; Ross, 1994; Ross & Covert, 2000).

Ear ossicles.—Remarkably, the incus and malleus are preserved inside the middle ear cavity, permitting the first description of these bones in an omomyiform primate (Fig. 6.3). The malleus preserves the manubrium, extending medially, with the neck arched laterally and the head articulating with the incus above. The tympanic process is visible as a bulbous tubercle in the middle of the malleus. The muscular process for the tensor tympani can be seen on the exposed surface of the neck of the malleus. The manubrium of the malleus attaches to the tympanic membrane. In mammals that can hear high frequency sounds, such as bats, the manubrium is a slender rod (Henson, 1961). The manubrium in *Omomys* is similar in proportions to those of living primates. The manubrium does not reflect any special adaptations to high frequency sounds, such as found in microchiropterans. The ear bones are morphologically most similar to those of the Eocene adapid *Notharctus* and are unlike anthropoid ear bones, which are more robust (Gregory, 1920). The lateral side of the incus is preserved, with both the long process and short process visible. In life, the short process articulated with the posterior incudal ligament, and the long process articulated with the head of the stapes, via the plate-shaped lenticular process. The broad malleoincudal articular surface exhibited in *Omomys* provides a tight fit between the malleus and incus. Overall, the body of the incus is slightly more slender than in living tarsiers. While the stapes is not preserved on AMNH FM 130000, its position can be inferred from the three preserved landmarks: the stapedial canal running

through the stapedial arch, the fenestra ovalis covered by the foot of the stapes, and the distal end of the long process of the incus attaching to the head of the stapes.

Arteries.—Blood supply from the internal carotid artery passes through the middle ear primitively in primates as two branches: the stapedial and promontorial (Wible, 1983). Considerable research has been undertaken to document the presence, absence, and position of these branches in primates (Gregory, 1920; Klaauw, 1931; Saban, 1963; Russell, 1964; McKenna, 1966; Bugge, 1972; Szalay & Katz, 1973; Cartmill, 1975; Archibald, 1997; MacPhee, 1981; Wible, 1983, 1984, 1993; MacPhee & Cartmill, 1986; Simons & Rasmussen, 1989; Ross, 1994; Beard & MacPhee, 1994; Norris & Harrison, 1998; Ross & Covert, 2000; Bloch & Silcox, 2001; Silcox, 2003). Bony canals or grooves trace the pathways of these arterial branches along the surface of the promontorium. In basal eutherians, the stapedial branch provides blood supply to the brain via the superior rami, and the lower and upper jaw via inferior rami, terminating as the infraorbital and inferior alveolar arteries (MacPhee & Cartmill, 1986). The promontory artery provides blood supply to the brain, via the circle arteriosus (Circle of Willis), which in anthropoids is the sole branch of the internal carotid. In the skull of *Omomys*, the pathways of the arterial branches are clearly delimited by bony canals, with the split between the two branches of the internal carotid occurring near the fenestra ovalis. The promontory canal is slightly smaller than the stapedial canal, but both are rather robust in size. The promontory canal passes ventrolaterally from the fenestra cochleae, and the internal carotid canal does not shield the fenestra cochleae ventrally. The posterior carotid foramen is present medially; however the internal carotid canal is not preserved in this region. Since the major groups of primates can be distinguished solely on the anatomy of the internal carotid canal, it is important to note that *Omomys* exhibits a

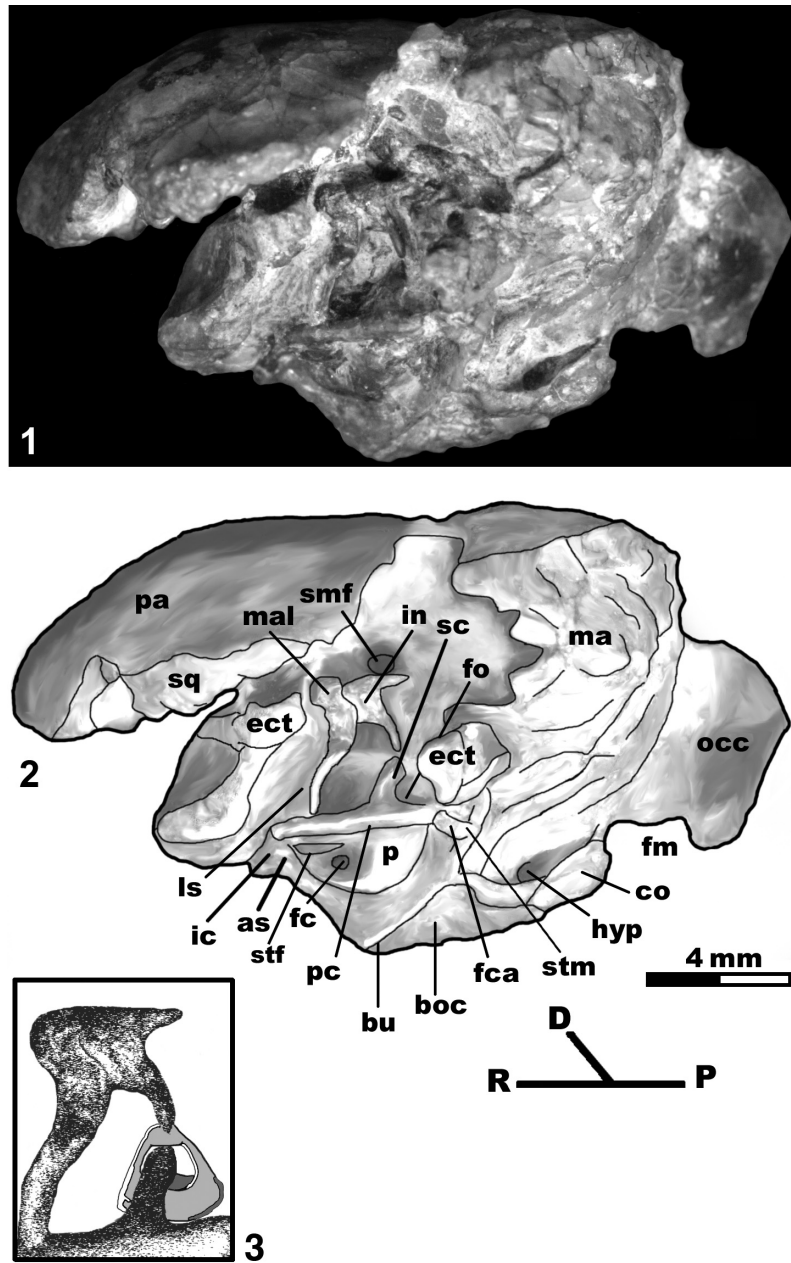


Figure 6. 1, Lateral-ventral view of auditory region; 2, lateral-ventral view of auditory region; *as*, anterior septum; *boc*, basioccipital; *bu*, auditory bulla; *co*, occipital condyle; *ect*, ectotympanic; *fc*, fenestra cochleae; *fca*, facial canal; *fm*, foramen magnum; *fo*, fenestra ovalis; *hyp*, hypoglossal foramen; *ic*, internal carotid canal; *in*, incus; *ls*, lateral septum; *ma*, mastoid; *mal*, malleus; *occ*, occipital; *p*, promontorium; *pa*, parietal; *pc*, promontory canal; *sc*, stapedial canal; *smf*, suprameatal foramen; *sq*, squamosal; *stf*, small transverse flange; *stm*, stylomastoid foramen; *D*, dorsal; *R*, rostral; *P*, posterior; 3, enlargement of ear bones and arterial canals. Inferred position of stapes in gray (new).

completely enclosed bony canal for the internal carotid artery that passes transpromontorially. Furthermore, *Omomys* lacks a transverse septum found in living tarsiers and anthropoids.

Nerves.—The facial nerve (cranial nerve VII) passes posteriorly to the middle ear cavity, with a sharp bend ventrally at the geniculate ganglion; it exits the skull through the stylomastoid foramen. During its course through the periotic region, the facial nerve gives off parasympathic branches for the greater petrosal and chorda tympani nerves. In this specimen of *Omomys*, the pathway of the facial nerve can be inferred based on the preserved primary facial

foramen, facial canal, and stylomastoid foramen. In the isolated petrosals of *Omomys* described by Ross and Covert (2000), the cavum supracochleare was partly preserved, which in life housed the geniculate ganglion. They also noted the presence of a *hiatus Fallopii* for the greater petrosal nerve and secondary facial foramen. None of these structures are visible in the skull of *Omomys*, since the incus and malleus bones overlie the area. The facial canal is partly preserved near the stylomastoid foramen, sectioned along the bullar wall. These structures indicate a direct inferior-posterior path for the facial nerve between the primary facial foramen and

the stylomastoid foramen. The course of the nerves of the tympanic plexus, which provide sympathetic innervation, can be inferred from tiny grooves radiating out of the internal carotid canal and crossing the surface of the promontorium (Ross & Covert, 2000). However, Wible (1983) has noted that the tympanic plexus rarely preserves indentations on the promontorium in living eutherian mammals, so these grooves may be highly variable.

DISCUSSION OF CRANIAL CHARACTERS

Skull and skeletal characters have often been excluded from phylogenetic studies of primates, because they are known for so few species (see Gunnell & Rose, 2002; Muldoon & Gunnell, 2002, for some recent examples). One exception is the phylogenetic analysis performed by Ross (1994), who included 42 cranial characters. He, with others, later expanded the data set to 49 cranial characters (Ross, Williams, & Kay, 1998). Cranial characters have recently been reviewed in light of the petrosal anatomy of *Omomys* (Ross & Covert, 2000). Phylogenetic analyses of cranial characters have strongly supported an omomyiform, tarsier, and anthropoid clade (Cartmill & Kay, 1978; Schmid, 1982; Cartmill, 1983; MacPhee & Cartmill, 1986; Beard, Krishtalka, & Stucky, 1991; Beard & MacPhee, 1994; Ross, 1994; Bloch & others, 1997; Kay, Ross, & Williams, 1997; Ross, Williams, & Kay, 1998; Bajpai & others, 2008; Williams & others, 2010). However, the addition of cranial characters has led to the frequent recognition of a tarsier-anthropoid clade, exclusive of Omomyiformes, which has manifested in recent phylogenies (Ni & others, 2004; Bajpai & others, 2008). These recent studies conflict with several previous studies that have recognized a closer tarsier-Omomyiformes relationship (Gregory, 1915; Rosenberger, 1985; Beard, Krishtalka, & Stucky, 1991; Godinet, & Bown, 1994; Gunnell & Rose, 2002). Rather than choose among published cranial character matrices, a reexamination of the more important cranial characters is presented in the following section. A complete list of cranial characters used in this study is given in Appendix A, and character scores are recorded in Appendix B.

Condition of the intrabullar septum and anterior accessory cavity of the middle ear.—This character is perhaps the most debated of all cranial characters in terms of its distribution among various fossils and yet the most important in terms of understanding omomyid relationships (Ross, 1994; Kay, Ross, & Williams, 1997). The debate stems from whether the anterior accessory cavity of the middle ear is homologous in tarsiers and anthropoids and how this structure may or may not have developed independently among extinct primates. MacPhee and Cartmill (1986) studied the embryological development of fetal tarsiers and anthropoids, noting that the anterior accessory cavity develops similarly in the two groups by a process of pneumatization of the internal carotid canal as it passes through the middle ear. However, they also noted differences: in anthropoids, the anterior accessory cavity is filled with small trabeculae, the orientation of the internal carotid canal is medial, and the endothelium-lined sac that forms the accessory cavity in tarsiers is indistinct in anthropoids. Despite these differences they concluded that the anterior accessory cavity was homologous between tarsiers and anthropoids, and “known omomyids do not express anything comparable” (MacPhee &

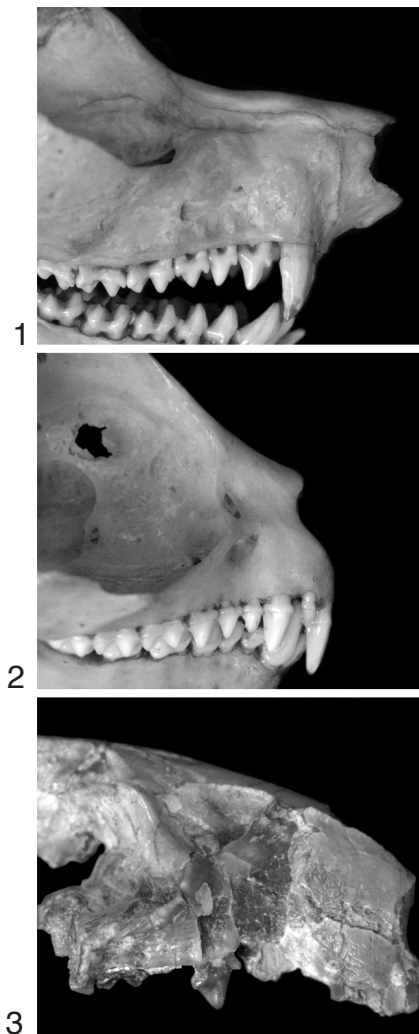


Figure 7. Comparative series of nasal regions; 1, AMNH CA 269, *Nycticebus* sp.; 2, AMNH MM 166856, *Tarsius* sp.; 3, AMNH FM 130000, *Omomys carteri* (new).

Cartmill, 1986, p. 268). These conclusions have been incorporated within a number of studies of the phylogenetic relationships of primates (i.e., Kay, Ross, & Williams, 1997), yet there remains debate over the homology of the anterior accessory cavity among tarsiers and anthropoids (Schwartz, 2003).

Study of the middle ear in fossils omomyids reveals several structures that may be rudimentary to the condition found in tarsiers. Like other primates, *Omomys* exhibits a bony septum extending from the anterior edge of the promontorium (Beard & MacPhee, 1994). This structure is named the anterior septum (Gregory, 1920). *Omomys* also exhibits a lateral bony septum that forms the wall of a passageway between the middle ear and nasopharynx extending from the canal for the internal carotid artery. A similar septum is present in *Tetonius* but is absent in *Necrolemur*. In tarsiers, this septum is contained within the anterior accessory cavity, separating it from the auditory tube and extending as a sheet of bone from the internal carotid canal (Schwartz, 2003), similar in placement to the septum in *Omomys*, *Shoshonius*, and *Tetonius*. In tarsiers, the two bony septa on either side of the internal

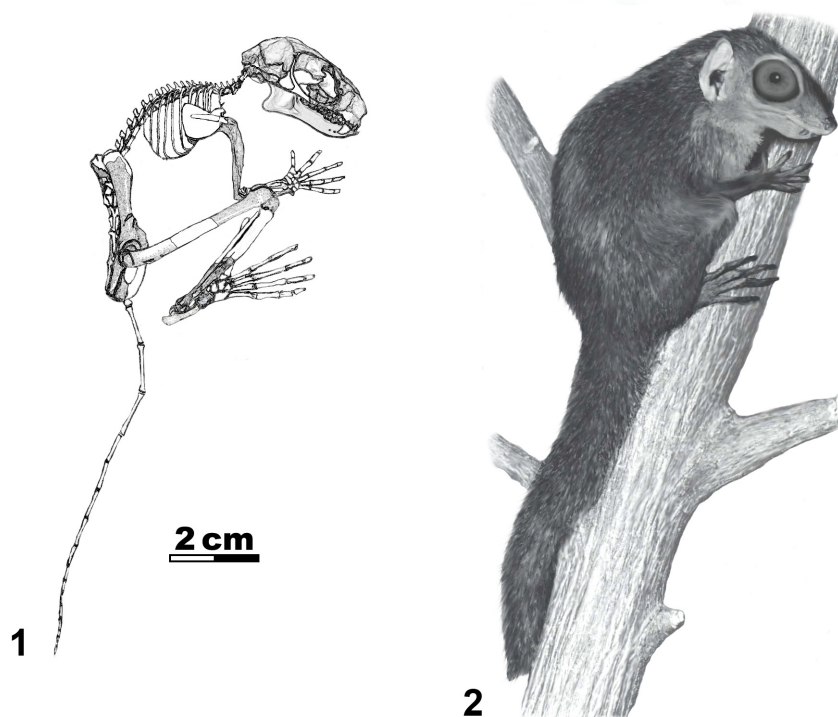


Figure 8. 1, Reconstructed skeleton of *Omomys carteri*, shaded elements are known for *Omomys carteri* (Anemone & Covert, 2000); 2, artist reconstruction of *Omomys carteri*, based on known skeletal elements and newly discovered skull (new).

carotid canal come together to form a transverse bony septum that divides the middle ear cavity anteriorly from the promontorium. In anthropoids, which lack a lateral portion of the septum, the internal carotid canal passes the middle ear medially, and the anterior septum extends from this point across the promontorium to form a single transverse septum, without any contribution from the medial wall of the bulla. Furthermore, the wall separating the auditory tube from the anterior accessory cavity does not extend onto the internal carotid canal, as in tarsiers (Schwartz, 2003, p. 63). These differences and similarities contribute to the debate over the homology of the anterior accessory cavity between tarsiers and anthropoids. Nevertheless, only tarsiers and anthropoids actually exhibit an anterior accessory cavity, while *Omomys* and other fossil omomyids lack this structure.

Mastoid pneumatization from epitympanic recess.—The new specimen of *Omomys* reveals fairly large mastoid cavities of similar proportion to *Necolemur*. Other omomyiforms such as *Shoshonius* and *Tetonius* lack pneumatized mastoid cavities. Mastoid pneumatization is best exemplified in living lorises, in which the mastoid cavity is nearly as large as the middle ear cavity. Anthropoids also have pneumatized mastoid cavities, but they are not as extensive. Furthermore, Adapines exhibit pneumatization of the mastoid, best demonstrated in skulls of *Adapis*.

Pathway of the internal carotid artery into the auditory bulla.—*Omomys* appears to exhibit a similar internal carotid pathway as that of anthropoids and tarsiers. In anthropoids and tarsiers, the internal carotid artery travels inside a diverticulum or canal derived from the medial wall of the auditory bulla (petrosal plate),

rather than simply passing straight through it, forming a partial perbullar pathway (MacPhee & Cartmill, 1986; Ross, 1994). This feature may be related to the formation of the transverse septum, since the pathway of the internal carotid must make a transverse (lateromedial) path across the bulla for the anterior septum (and lateral septum in tarsiers) to separate the middle ear and anterior accessory cavities. In tarsiers, the internal carotid passes into the auditory bulla ventrolaterally, whereas in anthropoids and *Omomys* the internal carotid passes into the bulla in a more medial position. Medially positioned posterior carotid foramina are also found in *Tetonius*, *Necrolemur*, *Plesiadapis*, living lorises, and tree shrews. However, this condition is not viewed as a primitive trait since some Paleocene fossils such as *Ignacius* and *Phenacolemur* exhibit a posterolateral position for the posterior internal carotid foramen (Bloch & Silcox, 2001; Gingerich, 1976; Wible, 1993).

Pathway of the arterial canals across the promontorium.—Once the internal carotid artery enters the middle ear cavity, it passes over the promontorium. In *Omomys*, as well as most primates and tree shrews, the internal carotid artery is encapsulated in a bony canal. As the bony canal runs posteriorly over the promontorium, it splits into two branches, the stapedial and promontorial. Variation in this pattern is found in a number of different primate groups and has often been used in phylogenetic studies of primate relationships. In *Omomys*, the stapedial branch is unreduced.

Ectotympanic bone morphology and position relative to the auditory bulla.—A thin, ring-shaped ectotympanic is enclosed within the lateral edge of the bulla wall in many eutherian mammals. Many primates exhibit this pattern, including lemurs and adapi-

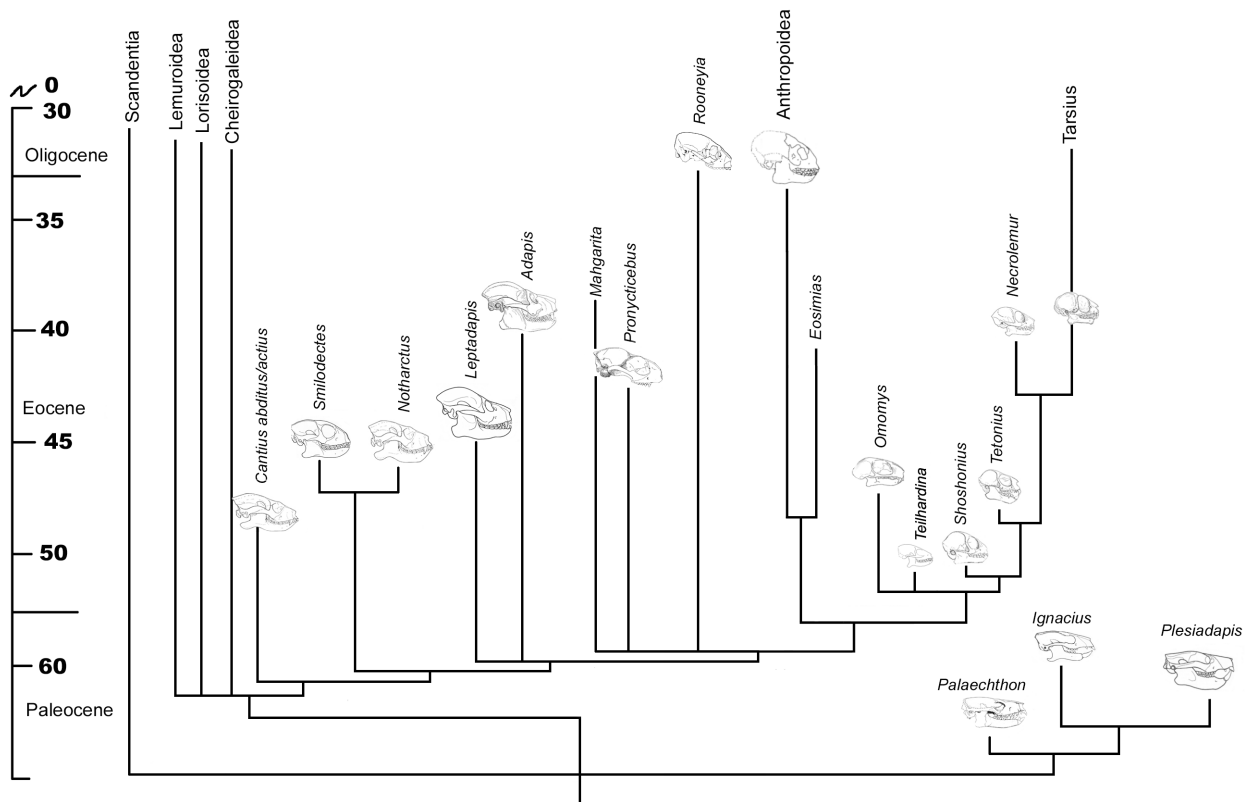


Figure 9. Strict consensus tree of 270 most parsimonious trees, based on the 52 cranial characters presented in this paper; scale in millions of years; skulls not to scale (new).

form primates (Gregory, 1920). In *Omomys*, the ectotympanic slightly extends outside the lateral edge of the bulla. In tarsiers, the ectotympanic is extended into a long, tube-shaped external acoustic meatus. *Plesiadapis tricuspidens*, *Necrolemur antiquus*, and *Rooneyia viejaensis* all have convergently developed, tube-shaped external acoustic meati formed instead by the bulla. In lorises, the external acoustic meatus is formed by the squamosal part of the temporal bone (MacPhee & Cartmill, 1986; Ross, 1994; Ross & Covert, 2000).

Relationship between the auditory bulla and the pterygoid.—In tarsiers, the anterior accessory portion of the auditory bulla is expanded into the pterygoid fossa to such an extent that the pterygoid plates have come to lay flat along the bulla wall (Rosenberger, 1985; Ross, 1994). Despite lacking an anterior accessory cavity, all known omomyiforms demonstrate a similar relationship between the bulla and pterygoid plate (Rosenberger, 1985; Beard & MacPhee, 1994; Ross, 1994). The new skull of *Omomys* does not preserve the pterygoid region, and its condition cannot be assessed. Contact between the pterygoid plate and bulla is fairly common among primates, and when it occurs, the pterygoid plate either lays flat against the bulla wall or forms an articulating suture (Rosenberger, 1985). A pterygoid plate contact is found to occur within various lemur species and in several anthropoids, such as *Erythrocebus patas* in which the pterygoid plates come close to contacting the bulla.

Suprameatal foramen.—Beard and MacPhee (1994) defined the suprameatal foramen as being located above the external

acoustic meatus in the interval bounded by the postgenoid and post-tympanic processes, and they stated it was for an arterial anastomosis between the extracranial posterior auricular artery and the intracranial stapedia artery. They concluded that only in tarsiers did the supra-meatal foramen provide a pathway for this anastomosis into the cranium. They argued that all other references for a supra-meatal foramen were actually for venous drainage from the diploe. *Necrolemur*, *Shoshonius*, and the new skull of *Omomys* all possess openings in the area above the external acoustic meatus, although none of them are as large as that found in *Tarsius*. In *Shoshonius*, the foramen is positioned anteriorly so as to be nearly on the zygomatic process of the squamosal and is identified as a subsquamosal foramen (Beard & MacPhee, 1994). In *Necrolemur*, the foramen is smaller but is located in the same area as in living tarsiers. The new skull of *Omomys* exhibits a very large opening into the cranium, which is nearly identical to that found in living tarsiers.

Parotic fissure.—In many eutherian mammals, the stapedius fossa is never completely incorporated into the middle ear and remains at least partly exposed as a small furrow posterior to the external acoustic meatus. This feature, termed the parotic fissure, is retained in tarsiers, but is lost in all other living primates (MacPhee, 1981; Beard & MacPhee, 1994). The new skull of *Omomys* retains a parotic fissure.

Orbit size and orientation.—The relative size and orientation of the orbits in primate skulls has received much attention, since it has been hypothesized that the common ancestor of both anthro-

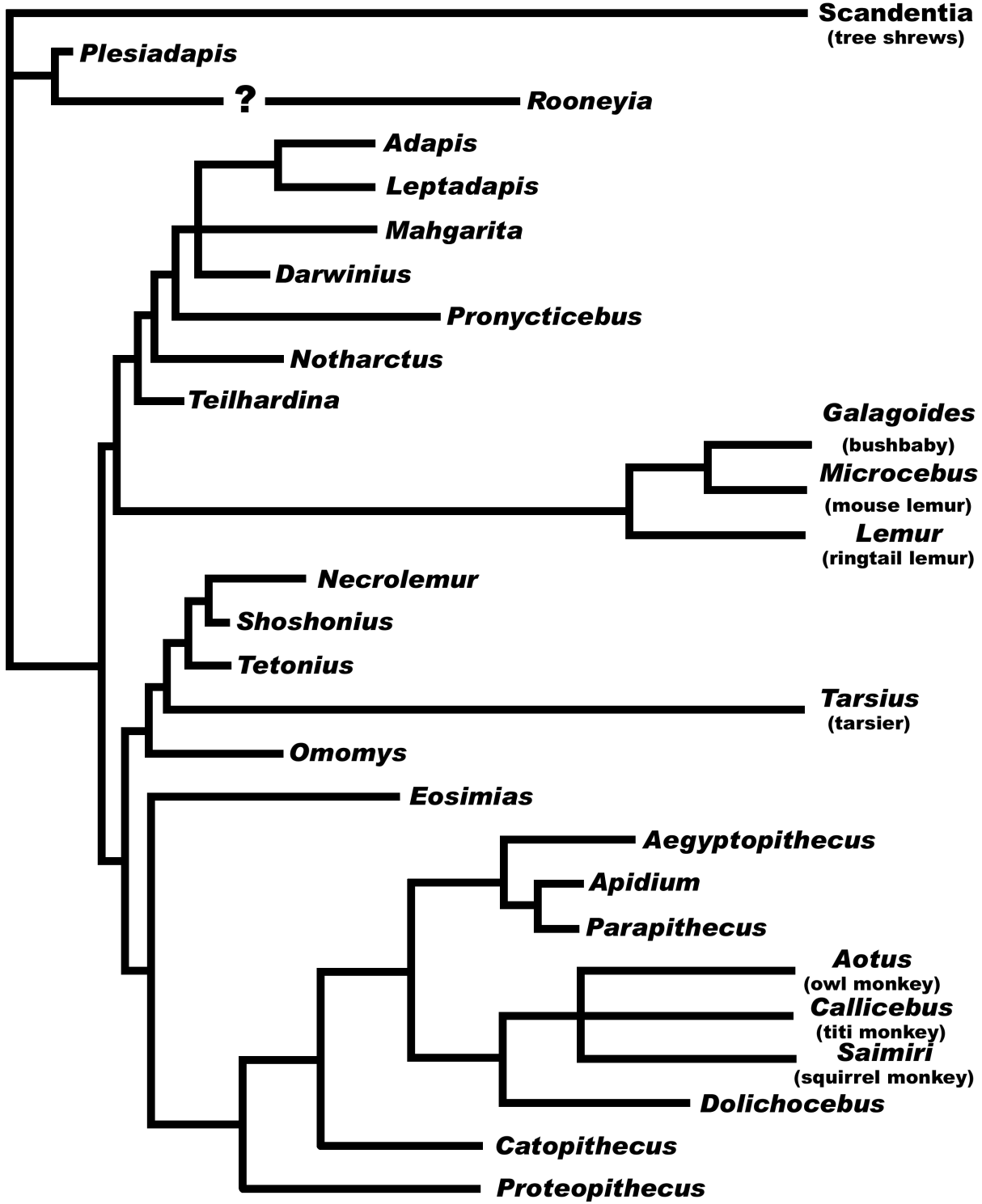
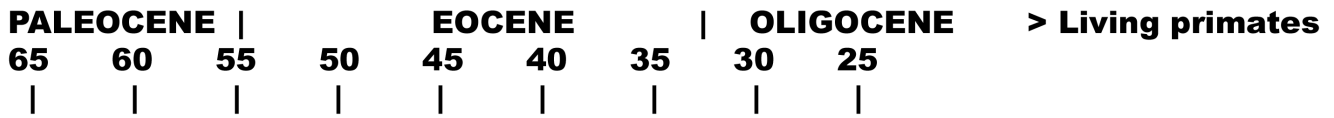


Figure 10. Strict consensus tree of 3 most parsimonious trees, based on a larger dataset including 194 dental, 56 postcranial, and 52 cranial characters. Addition of postcranial and dental characters scored from previous study by Ni and others (2004), with the addition of *Darwinius*; scale in millions of years (new).

poids and tarsiers was a small, diurnal, visual predator with very convergent orbits, which evolved from a small, nocturnal, visual predator (Ross, 1995, 2000). The earliest fossil anthropoids known from complete skulls appear to be diurnal and fugivore-gumivores (Kay & Kirk, 2000; Kirk & Simons, 2001). Omomyiformes, which exhibit large orbits with a moderate degree of orbital convergence and frontation, fit into this model as possible ancestors of anthropoids and tarsiers, since they were likely both nocturnal and insectivorous (Ross, 1995). Based on orbit size, Xijun Ni and colleagues (2004) have argued that the diminutive genus *Teilhardina* was in fact diurnal and that the common ancestor of euprimates was a small diurnal visual predator (Ni & others, 2004). The large orbits exhibited by the new skull of *Omomys* are indicative of nocturnal habit.

Known Paleocene mammals lack postorbital bars. In primates and tree shrews, the postorbital bar serves as an additional insertion point for the anterior temporalis muscle, as well as aiding in the overall protection of the eye. In living tarsiers and anthropoids, the postorbital bar is vertical and wide, forming a postorbital septum that encloses the orbit posteriorly (Martin, 1990). The orbit in tarsiers, anthropoids, omomyiforms, and lorises has expanded inferiorly, separating the zygomatic and lacrimal bones so that the maxilla forms the inferior orbital margin. In tarsiers, *Tetonius*, *Shoshonius*, and *Necrolemur*, the orbits are so close to one another that only a single, thin, bony septum separates them. This intraorbital septum is not found in *Omomys*, but it has been found in small anthropoids and has been inferred to be present ancestrally in anthropoids (Ross, 1994). Skulls of the earliest fossil anthropoids have contradicted this hypothesis, however, since they lack this derived feature (Simons & Rasmussen, 1989; Simons, 1995). In small, large-eyed primates such as tarsiers, lorises, and mouse lemurs, the enlarged orbital wall incorporates a significant portion of the ethmoid plate rostrally, such that it borders the lacrimal bone (Simons & Russell, 1960). This feature is absent in *Necrolemur* but is present in *Tetonius* and anthropoid primates. In lemurs and tree shrews, the lacrimal is encroached upon by the palatine bone posteriorly within the orbit, separating the frontal dorsally and maxilla ventrally. Postorbital closure is present in tarsiers and anthropoids but is not present in the known skulls of omomyiforms. In tarsiers, the postorbital closure is achieved later in development, with the zygomatic frontal process expanding more superiorly to contact the alisphenoid (Schwartz, 2003).

Nasal region.—Since Pocock (1918) divided primates into two suborders (Haplorhini and Strepsirrhini) based on the external appearance of the snout, the nasal region has been used to categorize the major groups of primates. Tarsiers and anthropoids have lost the rhinarium, a moist, glandular area that surrounds the nostril, while lemurs, lorises, and galagos have retained it. While such a division serves to divide living primates, it is more difficult to apply to fossils. The absence of a median gap between the two front incisors has been used to infer which fossil groups lacked a rhinarium (Martin, 1973, 1990); although a more reliable indicator of strepsirrhinism may lay in the overall size and morphology of the nasal region and the extent of the posterior transverse lamina (Asher, 1998). *Necrolemur*, *Pseudoloris*, and *Omomys* all exhibit a median gap between the two front incisors. Despite tarsier-like

enlarged upper incisors known in *Tetonius* and *Shoshonius*, the skulls are not complete enough anteriorly to verify the presence of the median gap for these fossils. The loss of the rhinarium in tarsiers and anthropoids is associated with an overall reduction of the nasal region as a whole. Tarsiers and anthropoids have reduced the number of turbinate bones, shortened the length of the snout, reduced the relative size of the accessory olfactory bulb, and have lost the transverse lamina, such that there is no longer a horizontal partition between the respiratory passage and olfactory chamber of the nasal fossa (Cave, 1967; Martin, 1990). The distribution of these characters among fossil primates is not known despite the considerable diversity in rostrum size among omomyiforms and adapiforms. The shortest snouted omomyiform is *Tetonius*, followed by *Shoshonius*, *Teilhardina*, and *Necrolemur*. *Omomys* retains a very long and wide rostrum, which is even more expanded than in living lorises (Fig. 7). In *Tetonius* and *Shoshonius*, the nasal bones do not extend between the two orbits, whereas in *Necrolemur* and *Omomys*, the nasal bones extend posteriorly. The area around the choanae is constricted in *Tetonius*, *Shoshonius*, and *Tarsius*, narrowing the skull posterior to the third molar (Rosenberger, 1985). Such constriction results in a more medial position for the insertion of the pterygoid muscles and the corresponding bony attachment sites (pyramidal process and pterygoid plates). This arrangement is found to a lesser degree in *Necrolemur* and *Shoshonius* but is absent in other primates, including anthropoids and *Omomys*. In comparison to other omomyiforms, *Omomys* differs dramatically in exhibiting a large, robust rostrum with convex nasal bones, a primitive trait that is shared with plesiadapiforms such as *Megadelphus* and *Plesiadapis*, and adapiforms such as *Pronycticebus*, but it is not found in living tarsiers and anthropoids (Gingerich, 1976; Gunnell, 1989). In sum, North American anatomorphine primates exhibit a tarsiiiform nasal region, whereas *Omomys* exhibits a more robust nose (Fig. 8).

Maxillary and mandibular regions.—A number of characteristics of the maxillary and mandibular regions have provided evidence for various theories of anthropoid and tarsier relationships. Maxillary depth has been shown to be greatest in anthropoids, tarsiers, and omomyids (Ross, 1994). Fusion of the symphysis of the mandible is found in all living anthropoids and several lineages of adapids, including *Notharctus* and *Mahgarita* (Gregory, 1920; Rasmussen, 1990). The temporomandibular joint in *Tarsius* is highly unusual for primates (Szalay, 1976; Rosenberger, 1985). The posterior root of the zygomatic arch extends laterally in *Tarsius* to form a horizontal trough for the mandibular condyle to slide forward during jaw opening. This arrangement effectively increases the gape of the mouth and is likely related to the carnivorous diet of living tarsiers. This specialization is found in *Necrolemur*, and it probably occurs in *Microchoerus* (Rosenberger, 1985). The temporomandibular joint in the skull of *Omomys* is not preserved.

Nerves.—The presence of an enclosed bony canal for the intratympanic portion of the facial is found in modern primates, as well as in *Omomys* (Ross & Covert, 2000). *Ignacius*, *Tupaia*, *Lemur*, as well as cheirogaleids and lorises, lack a foramen rotundum for the passage of the maxillary branch of the trigeminal nerve, CN V₂ (Ross, 1994). A foramen rotundum has been argued to be present in *Plesiadapis* (Silcox, 2001). *Necrolemur* has often been

cited as lacking a foramen rotundum (Ross, 1994; Ross, Williams, & Kay, 1998; Ross & Covert, 2000). In Stehlin's (1916) description of *Necrolemur*, he identified three cranial openings near the alisphenoid's pterygoid wing; the foramen located medial to the pterygoid wing he named the inner opening for the *canalis civinninii*; the others he labeled the foramen ovale and the outer opening for the *canalis civinninii* (Stehlin, 1916, fig. 312). With additional preparation of two skulls of *Necrolemur*, Simons and Russell (1960) identified another small foramen along the external pterygoid plate that opened directly into the cranial cavity at the junction of the other openings. This foramen is here referred to the foramen rotundum, with the other two external openings corresponding to the foramen ovale (the larger one) and foramen spinosum (Stehlin's foramen ovale). The foramen rotundum is present in *Rooneyia*, *Tarsius*, and living anthropoids, but it cannot be determined in *Tetonius*, *Shoshonius*, and the new skull of *Omomyis* (Ross, 1994).

PHYLOGENETIC ANALYSIS

Data from the previously reviewed character analysis were coded for parsimony analysis using PAUP software (version 4.0b10: Swofford, 2001), with Scandentia being specified as the outgroup. Heuristic searching using 20,000 replicates revealed 270 most parsimonious trees with a total length of 159 steps. Using the branch-and-bound search algorithm, no additional trees were discovered. Figure 9 displays a strict consensus of all 270 trees. Each tree has a consistency index of 0.4088, a homoplasy index of 0.5912, and a retention index of 0.6116. These low values reflect the inherited impenetrability of a good resolution in phylogenetic studies associated with missing data coupled with diverse morphological adaptations, as exhibited by basal primates.

A total evidence or character congruence approach was undertaken with the addition of postcranial and dental characters scored from the previous study by Ni and others (2004), based largely on the work of Ross, Williams, and Kay (1998). This larger data set includes 194 dental and 56 postcranial characters, which were added to the cranial data set of 52 characters reviewed previously for a total of 302 characters. The second data set was run for parsimony analysis using PAUP software (version 4.0b10: Swofford, 2001), with Scandentia specified as the outgroup, using only taxa scored with cranial characters. *Cantius*, *Smilodectes*, *Ignacius*, *Megadephus*, and *Palaechthon* were excluded from the previously published study. The recently described *Darwinius* from Messel Germany was added in this larger data set, however. Heuristic searching revealed three most parsimonious trees each with total length of 1327 steps, a consistency index of 0.3557, homoplasy index of 0.6443, and a retention index of 0.5310. The resulting strict consensus tree (Figure 10) differs from the cranial data set in recognizing a monophyletic Adapiformes, with *Teilhardina* as a basal member, and the unusual placement of *Rooneyia* outside of Euprimates. This analysis supports a monophyletic Adapiformes, a monophyletic Lemuriformes clade, a monophyletic Omomyiformes containing *Tarsius*, and as a sister group to Omomyiformes, a monophyletic Anthrozoidea with *Eosimias* as a basal member. Bootstrap analysis reveals weaker support for the placement of basal

members of these clades, however, including unusual placement of *Rooneyia* outside of Euprimates.

The new skull of *Omomyis carteri* influences the phylogenetic relationship between tarsiers and anthropoids. Current phylogenetic studies support an evolutionary scheme where the reduction in the reliance of the sense of smell occurred once in the common ancestor of tarsiers and anthropoids, a hypothesis supported by the discovery of the skull of *Teilhardina* and its proposed basal position (Ni & others, 2004). *Omomyis*, with its more robust nasal region, is enigmatic and contradicts such a simple hypothesis. An alternative evolutionary scheme either involves a retrospective change in *Omomyis* back to a greater reliance on the sense of smell, or *Omomyis* is a more basal member of the Omomyiformes than previously believed.

None of the trees supported an anthropoid-tarsier clade. Perhaps this lack of support is the result of recognizing a progressive acquisition of the intrabullar septa in tarsiers and anthropoids and the primitive nature of *Omomyis*'s rostrum while retaining large orbits. Furthermore, many similarities exist between tarsiers and omomyids such as *Tetonius* and *Necrolemur*. Yet most likely the collective expression of all the characters studied support the hypothesis that living tarsiers form a monophyletic group within a morphologically diverse Omomyiformes. Accordingly, tarsiers should be viewed as surviving members of an ancient lineage of Omomyiformes and should be placed together in Gregory's (1915) monophyletic infraorder Tarsiiformes.

CONCLUSIONS

Each new fossil discovery brings with it more questions as well as a better sense of the true diversity of primates throughout their evolutionary history. The newly described skull of *Omomyis carteri* exhibits many primitive features previously thought absent in the common ancestor of anthropoids, tarsiers, and omomyiforms. A robust rostrum, primitive cranial arterial circulation, primitive ectotympanic morphology, lack of a postorbital septum, wide intraorbital breadth, and an extraorbital lacrimal foramen are all primitive traits found in *Omomyis carteri*, which counter hypotheses in which a reduced rostrum was present in the common ancestor of omomyiforms, tarsiers, and anthropoids. In contrast, the derived large orbit found in *Omomyis carteri* was likely also present in the common ancestor of omomyiforms and tarsiers and likely played a role in the eventual reduction of olfaction that characterizes living haplorhine primates. A revised phylogenetic study of the cranial anatomy of early Eocene primates provides stronger support for a tarsiiform hypothesis, where Omomyiformes are part of a larger clade that incorporates living tarsiers as a sister group to anthropoids, together forming a monophyletic Haplorhini.

ACKNOWLEDGMENTS

Special thanks are extended to J. P. Alexander for his preparation, field logistics, and scientific assistance. M. Tornow, D. Wilcocks, and P. Light are thanked for fieldwork. L. Jolley, J. Eberle, M. Tornow, K. Townsend, K. Rose, C. Ross, M. Silcox, R. Kay, and numerous other reviewers are thanked for their helpful critiques on various drafts of this manuscript. This research was conducted

while employed at the American Museum of Natural History, and I wish to thank the staff for their help and encouragement. The skull was collected under BLM permit number 304WY94, issued to J. P. Alexander.

REFERENCES

- Alexander, J. P. 1992. Alas poor *Notharctus*. *Natural History* 101:54–59.
- Alexander, J. P. 1994. Evidence for sexual dimorphism in the primate family Notharctidae. *Folia Primatology* 63:59–62.
- Alexander, J. P., & R. D. E. MacPhee. 1999. Skull of *Omomys carteri*, an Eocene omomyid primate. *Abstracts of the American Association of Physical Anthropologists* 108(S28):83.
- Anemone, R. L., & H. H. Covert. 2000. New skeletal remains of *Omomys* (Primates, Omomyidae): Functional morphology of the hindlimb and locomotor behavior of a Middle Eocene Primate. *Journal of Human Evolution* 38:607–633.
- Archibald, J. D. 1997. Ectotympanic bone and internal carotid circulation of eutherians in reference to anthropoid origins. *Journal of Human Evolution* 6:609–622.
- Asher, R. J. 1998. Morphological diversity of anatomical strepsirrhinism and the evolution of the lemuriiform toothcomb. *American Journal of Physical Anthropology* 105:355–367.
- Bajpai, S., R. F. Kay, B. A. Williams, D. P. Das, V. V. Kapur, & B. N. Tiwari. 2008. The oldest Asian record of Anthropoidea. *Proceedings of the National Academy of Sciences* 105(32):11,093–11,098.
- Beard, K. C., L. Krishalka, & R. K. Stucky. 1991. First skulls of the Early Eocene primate *Shoshonius cooperi* and the anthropoid-tarsier dichotomy. *Nature* 349:64–67.
- Beard, K. C., & R. D. E. MacPhee. 1994. Cranial anatomy of *Shoshonius* and the antiquity of Anthropoidea. In J. G. Fleagle & R. F. Kay, eds., *Anthropoid Origins*. Plenum Publishers. New York. p. 55–97.
- Bloch, J. I., D. C. Fisher, P. D. Gingerich, G. F. Gunnell, E. L. Simons, M. D. Uhen, R. F. Kay, C. Ross, B. A. Williams, & D. Johnson. 1997. Cladistic analysis and anthropoid origins. *Science* 278:2134–2136.
- Bloch, J. I., & M. T. Silcox. 2001. New basicrania of Paleocene-Eocene *Ignacius*: Re-evaluation of the plesiadapiform-dermopteran link. *American Journal of Physical Anthropology* 116:184–198.
- Bugge, J. 1972. The cephalic arterial system in the insectivores and the primates with special reference to the Macroscelidoidea and Tupaioidea and the insectivore-primate boundary. *Zeitschrift fuer Anatomie und Entwicklungs geschichte* 135:279–300.
- Cartmill, M. 1975. Strepsirhine basicranial structures and the affinities of the Cheirogaleidae. In W. P. Luckett & F. S. Szalay, eds., *Phylogeny of the Primates*. Plenum Press. New York. p. 313–354.
- Cartmill, M. 1983. Accessing tarsier affinities: Is anthropoid description phylogenetically neutral? *Geobios* 6:153–161.
- Cartmill, M., & R. F. Kay. 1978. Cranio-dental morphology, tarsier affinities, and primate suborders. In D. J. Chivers & K. A. Joysey eds., *Recent Advances in Primatology*, vol. 3. Academic Press. London. p. 205–213.
- Cave, A. J. E. 1967. Observations on the Platyrrhine nasal fossa. *American Journal of Physical Anthropology* 26:277–288.
- Franzen, J. L., P. D. Gingerich, J. Habersetzer, J. H. Hurum, W. von Koenigswald, & B. H. Smith. 2009. Complete primate skeleton from the middle Eocene of Messel in Germany: Morphology and paleobiology. *Public Library of Science ONE*: <http://www.plosone.org/article/info:doi/10.1371/journal.pone.0005723>.
- Gazin, C. L. 1958. A review of the middle and upper Eocene primates of North America. *Smithsonian Miscellaneous Collections* 136:1–190.
- Gingerich, P. D. 1976. Cranial anatomy and evolution of early Tertiary Plesiadapidae (Mammalia, Primates). *Papers on Paleontology, University of Michigan* 15:1–116.
- Gingerich, P. D. 1981a. Eocene Adapidae, paleobiogeography, and the origin of South American Platyrrhini. In R. L. Ciochon & A. B. Chiarelli, eds., *Evolutionary Biology of the New World Monkeys and Continental Drift*. Plenum Press. New York. p. 123–138.
- Gingerich, P. D. 1981b. Cranial morphology and adaptations in Eocene Adapidae: I. Sexual dimorphism in *Adapis magnus* and *Adapis parisiensis*. *American Journal of Physical Anthropology* 56:217–234.
- Gingerich, P. D., & R. D. Martin. 1981. Cranial morphology and adaptations in Eocene Adapidae. II. The Cambridge skull of *Adapis parisiensis*. *American Journal of Physical Anthropology* 56:235–257.
- Godinot, M., & S. Couette. 2008. Morphological diversity in skulls of large Adapines (Primates, Adapiformes) and its systematic implications. In E. J. Sargis and M. Dagosto, eds., *Mammalian Evolutionary Morphology: A tribute to Frederick S. Szalay*. Springer. New York. p. 285–313.
- Gregory, W. K. 1915. I. On the relationship of the Eocene lemur *Notharctus* to the Adapidae and to other primates. II. On the classification and phylogeny of the lemuroidea. *Bulletin of Geological Society of America* 26:419–446.
- Gregory, W. K. 1920. On the structure and relations of *Notharctus*, an American Eocene primate. *Memoir of American Museum of Natural History* 3(2):1–243.
- Gunnell, G. F. 1989. Evolutionary history of Microsypoidea (Mammalia, ?Primates) and the relationship between Plesiadapiformes and Primates. *Papers on Paleontology, University of Michigan* 27:1–157.
- Gunnell, G. F. 1995a. New notharctine (Primates, Adapiformes) skull from the Uintan (middle Eocene) of San Diego County, California. *American Journal of Physical Anthropology* 98:447–470.
- Gunnell, G. F. 1995b. Omomyid primates (Tarsiiformes) from the Bridger Formation, middle Eocene, Southern Green River Basin, Wyoming. *Journal of Human Evolution* 28:147–187.
- Gunnell, G. F., P. C. Murphey, R. K. Stucky, K. E. B. Townsend, P. Robinson, J.-P. Zonneveld, & W. S. Bartels. 2009. Biostratigraphic and biochronology of the latest Wasatchian, Bridgerian, and Uinta North American Land Mammal “Ages.” In L. B. Albright, ed., *Papers on Geology, Vertebrate Paleontology, and Biostratigraphy in Honor of Michael O. Woodburne*. Museum of Northern Arizona Bulletin 65:279–330.
- Gunnell, G. F., & K. D. Rose. 2002. Tarsiiformes: Evolutionary history and adaptation. In W. C. Hartwig, ed., *The Primate Fossil Record*. Cambridge University Press. Cambridge. p. 45–83.
- Gunnell, G. F., & V. L. Yarbrough. 2000. Brontotheriidae (Perissodactyla) from the late Early and Middle Eocene (Bridgerian) Wasatch and Bridger Formations, Southern Green River Basin, southwestern Wyoming. *Journal of Vertebrate Paleontology* 20:349–368.
- Hamrick, M. W., & J. P. Alexander. 1996. The hand skeleton of *Notharctus tenebrosus* (Primates, Notharctidae) and its significance for the origin of the primate hand. *American Museum Novitates*, Number 3183:20.
- Heesy, C. P., & C. F. Ross. 2001. Evolution of activity patterns and chromatic vision in primates: Morphometrics, genetics and cladistics. *Journal of Human Evolution* 40:111–149.
- Henson, O. W. 1961. Some morphological and functional aspects of certain structures of the middle ear in bats and insectivores. *University of Kansas Science Bulletin* 42:151–255.
- Hoffstetter, R. 1977. Phylogénie des primates. *Bulletins et Mémoires de la Société d’Anthropologie de Paris (série XIII)* 4:327–346.
- Kay, R. F., & E. C. Kirk. 2000. Osteological evidence for the evolution of activity pattern and visual acuity in primates. *American Journal of Physical Anthropology* 113:235–262.

- Kay, R. F., C. F. Ross, & B. A. Williams. 1997. Anthropoid origins. *Science* 275:797–804.
- Kirk, E. C., & E. L. Simons. 2001. Diets of fossil primates from the Fayum Depression of Egypt: A quantitative analysis of molar shearing. *Journal of Human Evolution* 40:203–229.
- Klaauw, C. J. van der. 1931. The auditory bulla in some fossil mammals. *Bulletin of American Museum of Natural History* 62:1–352.
- Leidy, J. 1869. Notice of some extinct vertebrates from Wyoming and Dakota. *Proceedings of the Academy of Natural Sciences of Philadelphia* 21:63–67.
- Linnaeus, C. 1758. *Systema naturae per regna tria naturae, secundum classes, ordines genera, species, cum characteribus, differentiis, synonymis, locis.*, vol. 1: Regnum animale, 10th ed., revised. Holm. 821 p.
- MacPhee, R. D. E. 1981. Auditory regions of primates and eutherian insectivores. *Contributions to Primatology*, No. 18. Karger. Basel. p. 1–282.
- MacPhee, R. D. E., & M. Cartmill. 1986. Basicranial structures and primate systematics. In D. R. Swisher & J. Erwin eds., *Comparative primate biology, Systematics, Evolution and Anatomy*, vol. 1. Alan R. Liss. New York. p. 219–275.
- Marsh, O. C. 1872. Preliminary description of new Tertiary mammals. Parts I through IV. *American Journal of Science* 4:122–128, 202–224.
- Martin, R. D. 1973. Comparative anatomy and primate systematics. *Zoology Society of London* 33:301–337.
- Martin, R. D. 1990. *Primate Origins and Evolution*. Princeton University Press. New York. p. 296–358.
- Matthew, W. D. 1909. The Carnivora and Insectivora of the Bridger Basin, middle Eocene. *Memoir American Museum of Natural History* 9:289–567.
- McKenna, M. C. 1966. Paleontology and the origin of primates. *Folia Primatology* 4:1–25.
- Muldoon, K. M., & G. F. Gunnell. 2002. Omomyid primates (Tarsiiformes) from the Early Middle Eocene at South Pass, Greater Green River Basin, Wyoming. *Journal of Human Evolution* 43:479–511.
- Murphey, P. C. 2001. Stratigraphy, fossil distribution, and depositional environments of the upper Bridger Formation (Middle Eocene) of southwestern Wyoming, and the taphonomy of an unusual Bridger microfossil assemblage. Ph.D. Dissertation. University of Colorado. Boulder. p. 345.
- Murphey, P. C., A. Lester, B. Bohor, R. Robinson, E. Evanoff, & E. Larson. 1999. ⁴⁰Ar/³⁹Ar dating of volcanic ash deposits in the Bridger Formation (middle Eocene) of southwestern Wyoming. *Geological Society of America Abstracts with Programs*, 1999 Annual Meeting Issue, p. A-233.
- Ni X., Y. Wang, Y. Hu, & C. Li. 2004. A euprimate skull from the early Eocene of China. *Nature* 427:65–68.
- Norris, C. A., & D. L. Harrison. 1998. A possible omomyid periotic (Primates: Omomyidae) from the Eocene deposits at Hordle, Hampshire. *Acta Zoologica Cracoviensia* 41:61–68.
- Pocock, R. I. 1918. On the external characters of the lemurs and of *Tarsius*. *Proceedings of the Zoological Society of London* 88(1):19–53.
- Rasmussen, D. T. 1990. The phylogenetic position of *Mahgarita stevensi*: Protoanthropoid or lemuroid? *International Journal of Primatology* 11:439–469.
- Robinson, P., G. F. Gunnell, S. L. Walsh, W. C. Clyde, J. E. Storer, R. K. Stucky, D. J. Froehlich, I. Ferrusquia-Vilafranca, & M.C. McKenna. 2004. Wasatchian through Duchesnean Biochronology. In M. O. Woodburne, ed., *Late Cretaceous and Cenozoic Mammals of North America: Biostratigraphy and Geochronology*. Columbia University Press. New York. p. 106–155.
- Rose, K. D., M. Godinot, & T. M. Bown. 1994. The early radiation of Euprimates and the initial diversification of Omomyidae. In J. G. Fleagle & R. F. Kay eds., *Anthropoid Origins*. Plenum. New York. p. 1–29.
- Rose, K. D., R. D. E. MacPhee, & J. P. Alexander. 1999. Skull of Early Eocene *Cantius abditus* (Primates: Adapiformes) and its phylogenetic implications, with a reevaluation of '*Hesperolemur actius*'. *American Journal of Physical Anthropology* 109:523–539.
- Rose, K. D., & A. Walker. 1985. The skeleton of early Eocene *Cantius*, oldest lemuriform primate. *American Journal of Physical Anthropology* 66:73–89.
- Rosenberger, A. L. 1985. In favor of the *Necrolemur*-Tarsier hypothesis. *Folia Primatology* 45:179–194.
- Ross, C. F. 1994. The craniofacial evidence for anthropoid and tarsier relationships. In J. G. Fleagle & R. F. Kay eds., *Anthropoid Origins*. Plenum Publishers. New York. p. 469–513.
- Ross, C. F. 1995. Allometric and functional influences on primate orbit orientation and the origins of the Anthropoidea. *Journal of Human Evolution* 29:201–227.
- Ross, C. F. 2000. Into the light: The origin of Anthropoidea. *Annual Review of Anthropology* 29:147–184.
- Ross, C. F., & H. H. Covert. 2000. The petrosal of *Omomys carteri* and the evolution of the primate basicranium. *Journal of Human Evolution* 39:225–251.
- Ross, C. F., B. Williams, & R. F. Kay. 1998. Phylogenetic analysis of anthropoid relationships. *Journal of Human Evolution* 35:221–306.
- Russell, D. E. 1964. Les mammifères Paleocene d'Europe. *Mémoires du Museum National d'histoire Naturelle, Paris (series C)* 13:324.
- Saban, R. 1963. Contribution à l'étude de l'os temporal des primates. Description chez l'homme et les prosimiens. *Anatomie comparée et philogénie*. *Mémoires du Museum National d'histoire Naturelle, Paris (series A)* 29:1–378.
- Schmid, P. 1982. Comparison of Eocene nonadapids and *Tarsius*. In A. B. Chiarelli and R. L. Corruccini, eds., *Primate Evolutionary Biology*. Springer-Verlag. Berlin. p. 6–13.
- Schwartz, J. H. 2003. How close are the similarities between *Tarsius* and other primates?. In P. C. Wright, E. L. Simons, & S. Gursky eds., *Tarsiers: Past, Present and Future*. Rutgers University Press. New Jersey. p. 50–96.
- Silcox, M. T. 2001. A phylogenetic analysis of Plesiadapiformes and their relationship to Euprimates and other archontans. Ph.D. Dissertation. The Johns Hopkins School of Medicine, Baltimore. p. 1–29.
- Silcox, M. T. 2003. New discoveries on the middle ear anatomy of *Ignacius graybullianus* (Paromomyidae, Primates) from ultra high resolution X-ray computed tomography. *Journal of Human Evolution* 44:73–86.
- Simons, E. L. 1995. Crania of Apidium: Primitive anthropoidean (Primates, Parapithecidae) from the Egyptian Oligocene. *American Museum Novitates* 3214:1–10.
- Simons, E. L., & D. T. Rasmussen. 1989. Cranial morphology of *Aegyptopithecus* and *Tarsius* and the question of the Tarsier-Anthropoidean Clade. *American Journal of Physical Anthropology* 79:1–23.

- Simons, E. L., & D. E. Russell. 1960. Notes on the cranial anatomy of *Necrolemur*. *Breviora* 127:1–14.
- Stehlin, H. G. 1916. Die Säugetiere des schweizerischen Eocaens. *Wandlungen der schweizerischen paläontologischen Gesellschaft* 41:1299–1552.
- Swofford, D. 2001. PAUP 4.0b10: Phylogenetic Analysis Using Parsimony. Sunderland, Sinauer Associates. Massachusetts.
- Szalay, F. S. 1976. Systematics of the Omomyidae (Tarsiiformes, Primates) Taxonomy, Phylogeny, and Adaptations. *Bulletin of the American Museum of Natural History* 156:163–441.
- Szalay, F. S., & C. C. Katz. 1973. Phylogeny of lemurs, galagos and lorises. *Folia Primatology* 19:2–3.
- Tornow, M. A. 2008. Systematic analysis of the Eocene Primate family Omomyidae using gnathic and postcranial data. *Bulletin of the Peabody Museum of Natural History* 49:43–129.
- Trouessart, E. L. 1879. Catalogue des Mammifères vivants et fossils. *Revue et Magasin de Zoologie (3rd series)* 7:223–230.
- Wible, J. R. 1983. The internal carotid artery in early eutherians. *Acta Palaeontologica Polonica* 28:281–293.
- Wible, J. R. 1984. The ontogeny and phylogeny of the mammalian cranial arterial pattern. PhD. dissertation. Duke University. p. 1–705.
- Wible, J. R. 1993. Cranial circulation and relationships of the colugo *Cynocephalus* (Dermoptera, Mammalia). *American Museum Novitates* 3072:1–27.
- Williams, B. A. 1994. Phylogeny of the Omomyidae and implications for Anthropoid origins. PhD. Dissertation. University of Colorado, Boulder. 265 p.
- Williams, B. A., R. F. Kay, E. C. Kirk, & C. Ross. 2010. *Darwinius masillae* is a strepsirrhine—A reply to Frazer et al. (2009). *Journal of Human Evolution*, doi: 10.1016/j.jhevol.2010.01.003.
- Wortman, J. L. 1904. Studies of Eocene Mammalia in the Marsh Collection, Peabody Museum. Part II. Primates. *American Journal of Science* 15–17:12–248. Published uncompleted by the Peabody Museum.
- Zonneveld, J.-P., G. F. Gunnell, & W. S. Bartels. 2000. Early Eocene fossil vertebrates from the southwestern Green River Basin, Lincoln and Uinta counties, Wyoming. *Journal of Vertebrate Paleontology* 20:369–386.

Appendix A. Cranial characters used in this study.

Condition of the intrabullar septum and anterior accessory cavity of the middle ear

- 1) Anterior septum, if absent (0), if present (1).
- 2) Lateral septum, if absent (0), if present (1).
- 3) Transverse septum crosses promontorium, if absent (0), if present (1) (Ross, 1994; Ross, Williams, & Kay, 1998).

Mastoid pneumatization from epitympanic recess

- 4) Mastoid pneumatization, if absent (0), if present (1) (Ross, 1994; Ross, Williams, & Kay, 1998).

Pathway of the internal carotid artery into the auditory bulla

- 5) Anterior versus posterior entrance for the internal carotid artery, if posterior (0), if anterior (1), and if ventral (2); unordered (Beard and MacPhee, 1994; Ross, 1994; Ross, Williams, & Kay, 1998).
- 6) Medial versus lateral directed entrance for the internal carotid artery, if lateral (0), if medial (1) (Beard, Krishtalka, & Stucky, 1991; Beard and MacPhee, 1994; Ross, 1994; Ross, Williams, & Kay, 1998).
- 7) Partial Perbullar pathway, if absent (0), if present (1) (Ross, 1994; Ross, Williams, & Kay, 1998).

Pathway of the arterial canals across the promontorium

- 8) Bony canal morphology for the internal carotid artery, if absent (0), if open (1), if closed, but flat (2), and if tube shaped (3); ordered (Beard, Krishtalka, & Stucky, 1991; Beard and MacPhee, 1994; Ross, 1994; Ross, Williams, & Kay, 1998).
- 9) Stapedial branch of the internal carotid artery, if present (0), if reduced (1), if absent (2); ordered (Ross, 1994; Ross, Williams, & Kay, 1998).

Ectotympanic bone morphology and position relative to the auditory bulla

- 10) The position of the ectotympanic relative to the bulla, if extrabullar (0), if intrabullar (1) (Ross, 1994; Ross, Williams, & Kay, 1998).
- 11) The ectotympanic annular bridge is absent (0), formed by the bulla (1), or formed by the ectotympanic (2); unordered (Beard, Krishtalka, & Stucky, 1991; Beard and MacPhee, 1994; Ross, 1994; Ross, Williams, & Kay, 1998).
- 12) Epitympanic crest, absent (0), present (1) (Ross, Williams, & Kay, 1998).
- 13) Tube shaped external acoustic meatus is absent (0), formed by the bulla (1), or formed by the ectotympanic (2); unordered (Beard and MacPhee, 1994).
- 14) The bulla is formed by the petrosal, if true (1), otherwise (0) (Beard and MacPhee, 1994).
- 15) Flange of the basioccipital overlaps the medial bulla wall, if absent (0), is extensive (1) (Beard, Krishtalka, & Stucky, 1991; Beard and MacPhee, 1994; Ross, 1994; Ross, Williams, & Kay, 1998).

Relationship between the auditory bulla and the pterygoid

- 16) The pterygoids contacts with the bulla are flat (2), abutting (1) or absent (0); ordered. (Beard, Krishtalka, & Stucky, 1991; Beard and MacPhee, 1994; Ross, 1994; Ross, Williams, & Kay, 1998).
- 17) The bulla is expanded into the pterygoid fossa (1), or lacks expansion (0) (Ross, 1994; Ross, Williams, & Kay, 1998).

Suprameatal foramen

- 18) Subsquamosal foramen, if present (0), if absent (1).
- 19) Suprameatal foramen, if absent (0), if present (1) (Beard, Krishtalka, & Stucky, 1991; Beard and MacPhee, 1994; Ross, 1994; Ross, Williams, & Kay, 1998).

Parotic fissure

- 20) Parotic fissure, if present (0), if absent (1) (Beard and MacPhee, 1994; Ross, 1994; Ross, Williams, & Kay, 1998).

Orbit size and orientation

- 21) Orbit size relative to skull length, if orbit width divided by skull length is less than 0.275 (0), if greater (1) (Beard, Krishtalka, & Stucky, 1991; Ross, 1994; Ross, Williams, & Kay, 1998).
- 22) Frontation of orbits, frontation below 50 degrees (0), if greater (1).
- 23) Convergence of orbits, convergence below 50 degrees (0), between 50 and 60 degrees (1) and greater than 60 degrees (3); ordered (Ross, 1994; Ross, Williams, & Kay, 1998).
- 24) The inferior orbital margin is composed of the lacrimal and zygomatic bones (0), maxilla (1) (Ross, 1994; Ross, Williams, & Kay, 1998).

- 25) The intraorbital septum is absent (0) or present (1) (Ross, Williams, & Kay, 1998, in part).
- 26) The ethmoid plate is not in the orbital wall (0), posterior to orbital wall (1) or is rostrally expanded (2); unordered.
- 27) The lacrimal-palatine contact, if absent (0), if present (1) (Ross, 1994; Ross, Williams, & Kay, 1998).
- 28) Postorbital bar, if absent (0), if present (1) (Beard and MacPhee, 1994; Ross, Williams, & Kay, 1998).
- 29) Postorbital closure, if absent (0), achieved late in development (1), achieved early in development (2); ordered (Beard, Krishtalka, & Stucky, 1991; Beard and MacPhee, 1994; Ross, 1994; Ross, Williams, & Kay, 1998).
- 30) Position of the lacrimal foramen outside of the orbital margin (0), within the orbit or on the rim (1) (Ross, 1994; Ross, Williams, & Kay, 1998).
- 31) Metopic suture in the adult is unfused (0) or fused (1) (Ross, 1994; Ross, Williams, & Kay, 1998).

Nasal region

- 32) Rostrum shape, if convex (0), if concave (1).
- 33) Rostrum length, if long (0), if short (1) (Beard, Krishtalka, & Stucky, 1991; Beard and MacPhee, 1994; Ross, 1994; Ross, Williams, & Kay, 1998).
- 34) Nasal bones extend between the orbits, if absent (0), if present (1).
- 35) Median gap between the incisors, if present (0), if absent (1) (Ross, 1994; Ross, Williams, & Kay, 1998).
- 36) Choanae shape, if wide (0), if it is constricted (1) (Beard and MacPhee, 1994).
- 37) Number of turbinate bones, if 6 (0), if 5 (1) and if 4 (2); ordered.
- 38) Presence of the transverse lamina in the nasal cavity, if present (0) if absent (1).
- 39) Posterior nasal spine, if absent (0), if distinct (1) (Ross, 1994; Ross, Williams, & Kay, 1998).
- 40) Posterior palatine ridge, if present (0), if absent (1) (Ross, 1994; Ross, Williams, & Kay, 1998).
- 41) The pyramidal process of the pterygoids is medially placed (0) or laterally placed (1) (Ross, 1994; Ross, Williams, & Kay, 1998).
- 42) The medial pterygoid plate is long (0), or short and distinct from the lateral plate (1) or entirely absent (2); ordered (Ross, 1994; Ross, Williams, & Kay, 1998).
- 43) The ascending wing of the premaxilla, if broad and wide (0), if narrow (1) (Ross, Williams, & Kay, 1998).

Maxillary and Mandibular regions

- 44) Maxillary depth, if deep (0), if shallow (1) (Ross, 1994; Ross, Williams, & Kay, 1998).
- 45) Complete symphyseal fusion, if absent (0), if present (1) (Ross, 1994; Ross, Williams, & Kay, 1998).
- 46) Temporomandibular joint morphology, biconcave and transversely wide (0), anteroposteriorly oriented trough (1) (Ross, 1994; Ross, Williams, & Kay, 1998).
- 47) Entoglenoid process, if weak or absent (0), if strong (1) (Ross, 1994; Ross, Williams, & Kay, 1998).
- 48) Coronoid height relative to the mandibular condyle, if very far above (0), if slightly above or equal to the condyle (1) (Ross, Williams, & Kay, 1998).
- 49) Condyle height relative to the tooth row, if at the same level (0), if above (1) is well above the tooth row (2); ordered (Ross, Williams, & Kay, 1998).
- 50) Mandibular corpus robustness, if shallow and thin (0), if deep and wide (1) (Ross, 1994; Ross, Williams, & Kay, 1998).

Nerves

- 51) Enclosure of the intratympanic portion of the facial nerve in a bony canal, if nerve is only in sulcus (0), if in bony canal (1) (Ross, Williams, & Kay, 1998).
- 52) Foramen rotundum, if absent (0), if present (1) (Ross, 1994; Ross, Williams, & Kay, 1998).

