



Glycogen Accumulation in the Ovarian Follicle of Indian Vespertilionid Bat, *Scotophilus heathi* during the Period of Delayed Ovulation

Authors: Singh, Udai P., and Krishna, Amitabh

Source: Zoological Science, 13(6) : 893-897

Published By: Zoological Society of Japan

URL: <https://doi.org/10.2108/zsj.13.893>

BioOne Complete (complete.BioOne.org) is a full-text database of 200 subscribed and open-access titles in the biological, ecological, and environmental sciences published by nonprofit societies, associations, museums, institutions, and presses.

Your use of this PDF, the BioOne Complete website, and all posted and associated content indicates your acceptance of BioOne's Terms of Use, available at www.bioone.org/terms-of-use.

Usage of BioOne Complete content is strictly limited to personal, educational, and non - commercial use. Commercial inquiries or rights and permissions requests should be directed to the individual publisher as copyright holder.

BioOne sees sustainable scholarly publishing as an inherently collaborative enterprise connecting authors, nonprofit publishers, academic institutions, research libraries, and research funders in the common goal of maximizing access to critical research.

Glycogen Accumulation in the Ovarian Follicle of Indian Vespertilionid Bat, *Scotophilus heathi* during the Period of Delayed Ovulation

Udai P. Singh and Amitabh Krishna

Department of Zoology, Banaras Hindu University, Varanasi, 221 005, India

ABSTRACT—Massive accumulation of glycogen in the follicles of *Scotophilus heathi* during the period of delayed ovulation was noticed. The follicles which survive for prolonged periods are morphologically specialized. The accumulation of glycogen was noticed in the granulosa cells. The egg cytoplasm, thecal cells and interstitial cells were almost devoid of glycogen. The first sign of a glycogen deposit in the ovary was noticed during the recrudescence phase (October) in late pre-antral follicles. Most of the morphologically healthy late pre-antral and antral follicles showed a positive reaction with PAS and Best carmine from October to early February. Morphologically atretic follicles showed only a mild glycogen accumulation. Little or no glycogen accumulation was noticed in some of the healthy late-antral follicles before ovulation during late February and early March. HCG-induced antral follicles during quiescence also did not show any accumulation of glycogen. The study suggests that glycogen laden follicles are not suitable for ovulation and may be the reason for the occurrence of delayed ovulation in *S. heathi*.

INTRODUCTION

The remarkable longevity of follicle and prolonged delay in ovulation are unique features in reproductive cycle of hibernating temperate zone vespertilionid bats (Oxberry, 1979). The follicles which survive for prolonged period have been shown to be morphologically specialized, such as hypertrophy and hyperplasia of the granulosa cells. These hypertrophied granulosa cells show heavy accumulation of glycogen which is transferred to the oocyte by follicle cell processes. These modifications are considered to be an adaptation to meet the energy requirements to the ovarian follicle complex during winter dormancy (Wimsatt and Parks, 1966). The specialized ovarian follicles, analogous to the described in temperate zone vespertilionids, are also found in tropical vespertilionids; e.g., *Pipistrellus ceylonicus chrysothrix*, *Pipistrellus mimus mimus* and *Pipistrellus dormeri* (Gopalakrishna *et al.*, 1974). Whether such chemically and morphologically specialized follicle is an adaptation related to period of delayed ovulation or prolonged survival of Graafian follicle is not clearly known. *Scotophilus heathi*, a tropical vespertilionid bat, has been shown to exhibit the phenomenon of delayed ovulation and heavy accumulation of glycogen in follicles, which are about to ovulate (Krishna and Dominic, 1980; Krishna and Singh, 1992). The present investigation was therefore undertaken in *S. heathi* to elucidate the following: whether follicles in all stages of growth or only Graafian follicle exhibit glycogen accumulation; whether glycogen deposit in the ovarian follicle occurred only during the period of delayed ovulation or throughout the year. An additional study was

performed to find out whether antral follicles induced by exogenous hCG during non-breeding phase also accumulate glycogen.

MATERIALS AND METHODS

Bats were trapped alive in every calendar month in the Banaras Hindu University campus and adjacent area. Animals were sacrificed as soon as they were brought to the laboratory. Bats were maintained in small cages with free access to water in a room at 20–25°C and 14 hr light: 10 hr dark schedule. Ovaries were dissected out, fixed in alcoholic Bouin's or calcium formal, embedded in paraffin wax, and serially sectioned at 5 µm. The section were stained with periodic acid Schiff's (PAS) reagent, alcian blue and Best carmine with and without diastase treatment (Pearse, 1968). Follicles were classified as shown in Table 1 and Fig. 1–4.

HCG treatment

HCG (10 IU) in saline were injected as single ip dose after 24 hr of capture. The animal were sacrificed 48 hr after the injection. The ovaries were dissected out and proceed for PAS staining as described earlier.

RESULTS

Morphological features of the follicle during delayed ovulation

S. heathi exhibits a sharply defined annual breeding season. Both ovaries contained numbers of primordial and early pre-antral follicles throughout the year. The first sign of recrudescence of the ovary was noticed in females collected during late September and early October. Large numbers of growing follicles in late pre-antral stage were noticed at this stage (Fig. 1). In November the ovary contains several early

Table 1. Classification of stages of the follicles

Stages	Characteristics
Early pre-antral	Pre-antral follicle with one to three layer of granulosa cells. The size of follicle ranging from 62 μm to 135 μm .
Late pre-antral	Pre-antral follicle with three to eight or more complete layers of granulosa cells. The size of follicle ranging from 135 μm to 220 μm .
Early-antral	Follicle with early sign of antral spaces formation. The size of follicle ranging from 220 μm to 320 μm .
Late-antral	Follicle with a few small to large antral spaces among the granulosa cells. The size of the follicle ranging from 280 μm to 510 μm .

and late antral follicles (Fig. 2). During late January and February, two to four morphologically healthy Graafian follicles (late-antral) were present in each ovary (Fig. 3). Some follicles with distinct morphological sign of atresia were also present in the ovary (Fig. 5). Ovulation occurs during the first week of March. During December to early March, granulosa cells of late-antral follicles underwent hypertrophy resulting in the reduction of the antral cavities to a few small spaces (Fig. 3). The pronounced hypertrophy of the discus proligerus (Fig. 4) and associated follicle cells was a prominent and characteristic feature of the late-antral follicles. The glycogen accumulation was prominent in Graafian follicles having hypertrophied granulosa cells. The intensity of accumulation was much greater in granulosa cells having large frothy appearance as compared with follicles having smaller granulosa cells (Fig. 6).

Histochemical observations

The ovarian sections treated with PAS or Best carmine showed intense positive reaction for glycogen in the antrum and in the cytoplasm of granulosa cells (Table 2, Fig. 7). The egg cytoplasm, thecal cells and interstitial cells, however, showed a negative reaction for glycogen (Fig. 7). The follicle cells also exhibited a positive reaction with alcian blue indicating the presence of acid mucopolysaccharides.

In order to find out whether follicles in all stages or only Graafian follicles exhibit glycogen accumulation, and whether deposits in the ovarian follicles occurred only during the period of delayed ovulation or year round, ovarian sections from

animal collected throughout the year were stained with PAS. Both pre-antral and antral follicles showed glycogen accumulation. The first sign of glycogen deposits was noticed in late pre-antral follicle in the ovaries of bat collected during October. All healthy late pre-antral and antral follicles in the ovaries of bats collected from October to February showed PAS-positive reaction (Table 3). The morphologically atretic follicles exhibited only a mild or negative reaction (Fig. 7). The intensity of PAS reaction showed a gradual increase from late pre-antral to antral follicles. The reaction was not detectable in early pre-antral follicles. The pattern of glycogen accumulation changes just before ovulation during late February and early March. During this period, only late antral follicles were showing mild PAS positive reaction, while most of the pre-antral and a few of the antral follicles did not show any PAS-positive reaction (Table 3, Fig. 8). Neither the early pre-antral follicle (except the zona pellucida) nor other parts of the ovary showed a PAS positive reaction during the period from late March to September. During this period the ovary contains only early pre-antral follicles. The corpus luteum showed no reaction with PAS.

HCG-treatment

Since only early pre-antral follicles were found in the ovary during the period from April to August, the effect of season on glycogen deposition in the antral follicles could not be determined in normal female bats. Treatment of hCG in female bat during this phase causes several changes in the ovary such as intense hyperaemia, hypertrophy of interstitial cells and appearance of numerous late pre-antral and antral follicles. The ovarian section of these hCG treated females did not show any glycogen accumulation in the follicles.

DISCUSSION

The peculiarities in the structure of the antral follicles as noticed in *S. heathi* are comparable to those described in other vespertilionids (Oxberry, 1979; Dominic and Krishna, 1989). These follicles are characterised by a reduced antral cavity and ovum being surrounded by a large discus proligerus, the cells of which are considerably hypertrophied and vesicular. These peculiarities in the antral follicles may be because of the occurrence of delayed ovulation and prolonged survival of the late antral follicle in *S. heathi* (Krishna and Singh, 1992).

- Fig. 1. Portion of ovary showing late pre-antral follicles. An early pre-antral follicle is also seen (arrows). $\times 60$.
 Fig. 2. Portion of ovary showing early antral follicle with few antral cavities (A) among the granulosa cells. $\times 65$.
 Fig. 3. Portion of the ovary showing late antral follicle. The cumulus oophorus attached to mural granulosa cells by several cords of cells or reticula (arrow). Few small antral (A) cavities are also seen. $\times 60$.
 Fig. 4. Portion of the ovary showing hypertrophy of the granulosa cells. $\times 240$.
 Fig. 5. Portion of the ovary showing atretic follicle. Oocyte showing pseudomaturational changes and pyknotic cells are seen among the granulosa cells (arrow). $\times 240$.
 Fig. 6. Portion of the ovary showing the intense positive PAS reaction in the number of antral follicles. Early pre-antral (arrow) and atretic (arrow head) follicles showing mild to negative reaction. $\times 25$.
 Fig. 7. Portion of the ovary showing enormous quantity of glycogen accumulation (PAS) in the antral follicle. Early pre-antral (arrow) showing negative reaction. An atretic follicle showing mild reaction (arrow head). $\times 50$.
 Fig. 8. Portion of the ovary during early March showing some pre-antral and antral follicles with negative PAS reaction except in the zona pellucida and antrum. Note a portion of a antral follicle (arrow) showing intense PAS positive reaction in the granulosa cells. $\times 50$.

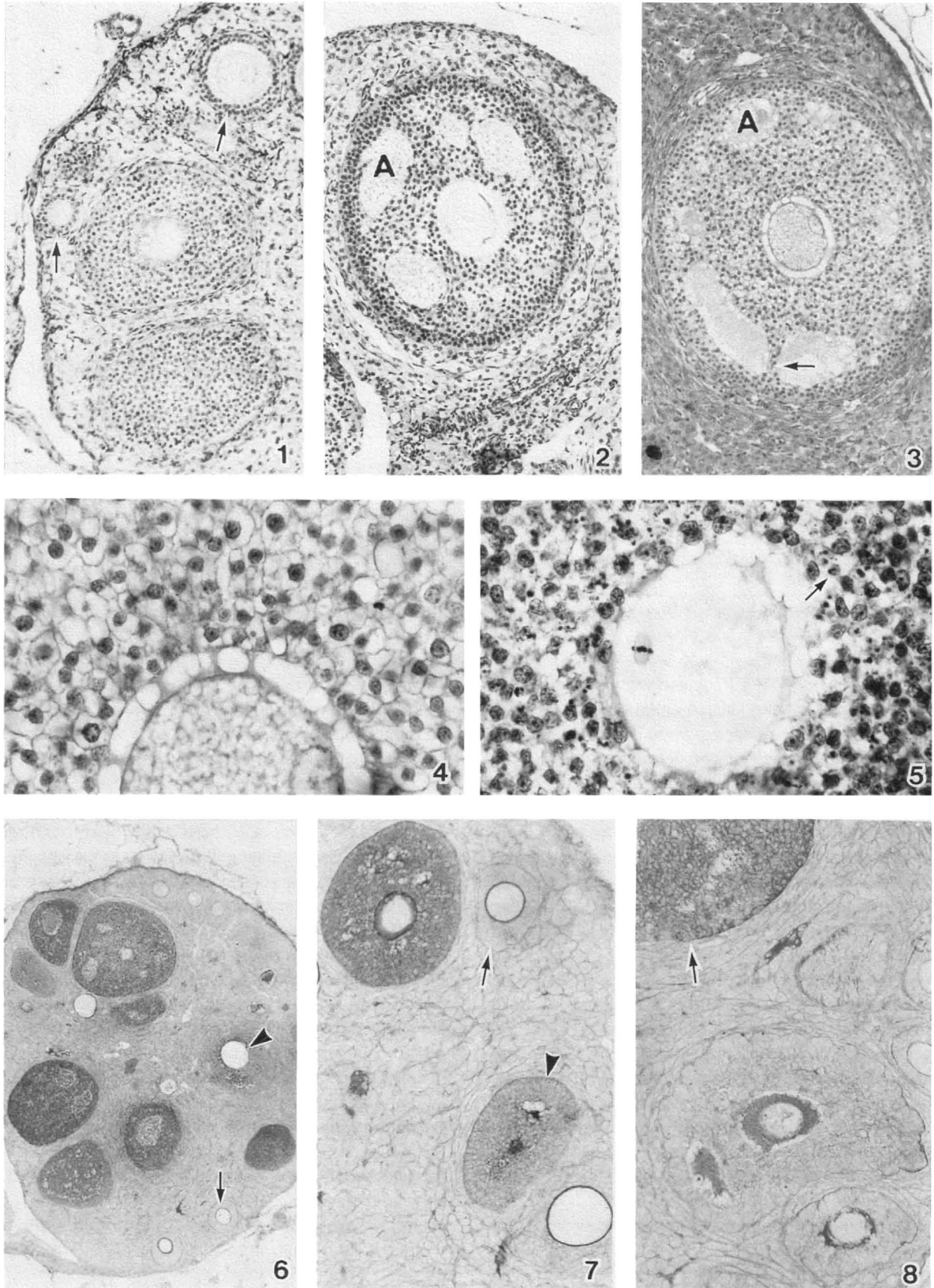


Table 2. Histochemical observation on the mature Graafian follicles

Techniques	Granulosa/ cumulus cells	Antrum	Egg cytoplasm	Thecal cells	ICS	Specificity
PAS	+++	+	-	+	-	1-2-Glycol
Diastase + PAS	+	+	-	-	-	Glycogen
Best carmine	++	+	-	+	-	Glycogen
Diastase + Best carmine	+	+	-	+	-	Control
Alcian blue	+	+	-	-	-	Acid Muco- polysaccharides

+++ = Intense, ++ = Moderate, + = Trace, - = Absent

Table 3. Number of follicles* showing positive PAS reaction in the ovaries of *S. heathi* during ovarian cycle

Month	Early pre-antral	Late pre-antral	Early antral	Late antral
January	0/55	11/11	19/19	19/19
February	0/56	13/18	13/13	9/9
March	0/23	2/12	5/11	7/10
April	0/19	-	-	-
May	0/29	-	-	-
June	0/34	-	-	-
July	0/39	-	-	-
August	0/24	-	-	-
September	0/35	2/13	-	-
October	0/50	15/17	-	-
November	0/80	7/8	15/15	13/13
December	0/70	8/8	25/25	16/16

* Number denotes follicle found positive/total No. of follicle observed from 6 different animals.

In *S. heathi* glycogen accumulation was noticed in most of the morphologically healthy late pre-antral and antral follicles found during the period from September to February (Table 3). Follicle showing morphological sign of atresia had only mild accumulation of glycogen. This is the period when the ovarian recrudescence and delayed ovulation is reported in this species (Krishna and Singh, 1992). It is interesting to note that glycogen accumulation was much greater in antral follicles having hypertrophied granulosa cells. Before ovulation, during the late February and early March only a mild PAS positive reaction was noticed in some of the antral follicles. While most of the pre-antral and some of the antral follicle showed a negative PAS reaction in the granulosa cells. The ovaries of bats collected during late March to August failed to demonstrate any accumulation of glycogen in pre-antral follicles. Glycogen accumulation was also not noticed in both pre-antral and antral follicles in the ovaries of hCG treated bats during this period. These observations indicate that the period of glycogen accumulation in the follicle coincides with the period of prolonged survival of antral follicles and delayed ovulation in *S. heathi*. Glycogen accumulation in most of the follicles decreases drastically before ovulation.

Polysaccharides (glycogen) as a energy source for follicle cells have been regarded as an important aspect of the prolonged survival of the Graafian follicle during hibernation (Oxberry, 1979; Son *et al.*, 1987). The ultrastructural studies of Wimsatt and Parks (1966) on the Graafian follicle of *Myotis*

lucifugus have shown that glycogen stored in the granulosa cells is transferred to the oocyte by follicle cell processes that pass through the zona and penetrate the oocyte surface. These authors consider these modifications as an adaptation to meet the energy requirements of the ovum-follicle complex during winter dormancy in the temperate zone vespertilionid bats. The present studies in *S. heathi*, however, have failed to demonstrate accumulation of glycogen in the oocyte. Since *S. heathi* is a tropical species and does not undergo prolonged hibernation, it is doubtful whether the accumulation of glycogen in the follicle cells has any adaptive value to meet the energy requirement of the ovum follicle complex in this species. Furthermore in *S. heathi*, glycogen accumulation during the period from October to early February is not only found in surviving antral follicles, but in all the follicles beyond early pre-antral stage of development.

Thus, it is reasonable to assume that in *S. heathi*, glycogen accumulation in the follicles may not be an adaptation for prolonged survival of the follicle. Accumulation of glycogen in the follicles in *S. heathi* was found to be seasonal. The follicles recruited during the period from October to early February showed heavy accumulation of glycogen. Previous attempts to induce ovulation in these bats during this period was unsuccessful (Singh and Krishna, 1992). This study thus suggest that antral follicles present in the ovary of *S. heathi* during the period from October to early February may not be suitable for ovulation, this could be because of the presence

of glycogen in the antral follicles. Appearance of glycogen in the cumulus oophorus is generally associated with early sign of follicular atresia (Guraya, 1985). Recent study from our laboratory demonstrated very high rate of androstenedione production from the ovary of *S. heathi* during the period of delayed ovulation (Abhilasha and Krishna, 1996). It is well known that high ovarian androgen production causes number of intra-ovarian effects, which include inhibition of follicular growth and ovulation and enhanced rate of follicular atresia (Billiar *et al.*, 1985; Faiman *et al.*, 1988). This observation further suggest that glycogen-laden follicles present in the ovary of *S. heathi* during the period of delayed ovulation may not be physiologically healthy, although morphologically they do not exhibit classical sign of atresia. This might be the reason for the occurrence of delayed ovulation in *S. heathi*. Interestingly, the morphologically atretic follicles showed depleted glycogen accumulations. This observation suggest that as long as follicles contain sufficient glycogen they remain morphologically healthy and retained in the ovary for prolonged period. Before ovulation, most of the pre-antral and some of the antral healthy follicles were found without any accumulation of glycogen. This is because in *S. heathi*, a second wave of follicular growth, resulting in a fresh recruitment of antral follicles occurs in late February (Krishna and Singh, 1992). This indicate that glycogen accumulation does not occur in the follicles recruited after mid February, which most likely ovulate during early March. The underlying factor(s) which induce the accumulation of glycogen in most of the follicles during the period from October to early February and the factor(s) which later prevents the accumulation of glycogen within follicles just before ovulation in *S. heathi* is obscure.

ACKNOWLEDGMENTS

Rockefeller Foundation USA (AK) and CSIR (UPS) are acknowledged for providing financial support.

REFERENCES

- Abhilasha, Krishna A (1996) High androgen production by ovarian thecal interstitial cells : a mechanism for delayed ovulation in a tropical vespertilionid bat, *Scotophilus heathi*. *J Reprod Fert* 106: 207–211
- Billiar RB, Richardson D, Anderson E, Mahajan D, Little B (1985) The effect of chronic and acyclic elevation of circulating androstenedione or estrone concentration on ovarian function in the rhesus monkey. *Endocrinology* 116: 2209–2220
- Dominic CJ, Krishna, A (1989) Reproductive cycles of mammals : Chiroptera and Insectivora. In "Reproductive Cycles of India Vertebrates" Ed by Saidapur SK, Allied Publishers, New Delhi, India, pp 311–346
- Faiman C, Reyes FI, Dent DW, Fuller GB, Hobson WC, Thliveris JA (1988) Effect of long term testosterone exposure on ovarian function and morphology in the rhesus monkey. *Anat Rec* 222 : 245–251
- Gopalakrishna A, Madhavan A, Thakur RS, Rajgopal G (1974) Graafian follicle in some Indian bats. *Curr Sci* 43: 400–401
- Guraya SS (1985) Biology of Ovarian Follicle in Mammals. Springer-Verlag, Berlin, Heidelberg, Tokyo.
- Krishna A, Dominic CJ (1980) Observation on the Graafian follicle of the vespertilionid bat, *Scotophilus heathi* Horsfield. *Proc Zool Soc Calcutta* 33: 1–7
- Krishna A, Singh UP (1992) Morphometric changes in the ovaries of Indian vespertilionid bat, *Scotophilus heathi* with reference to delayed ovulation. *Eur Arch Biol* 103: 257–264
- Oxberry BA (1979) Female reproductive pattern in hibernating bats. *J Reprod Fert* 56: 359–367
- Pearse AGE (1968) Histochemistry: Theoretical and Applied. Churchill Ltd, London
- Singh UP, Krishna A (1992) Effects of HCG and PMSG on the responsiveness of ovary during the period of delayed ovulation in an Indian vespertilionid bat *Scotophilus heathi*. *Ind J Exp Biol* 30: 670–675
- Son SW, Yoon MH, Mori T, Uchida TA (1987) Sperm storage in the reproductive tract and prolonged survival of the Graafian follicle in the female orange whiskered bat, *Myotis formosus tsuensis* of Korea. *J Mamm Soc Japan* 12: 1–14
- Wimsatt WA, Parks HF (1966) Ultrastructure of the surviving follicle of hibernation and the ovum follicle cell relationship in vespertilionid bat, *Myotis lucifugus*. *Symp Zool Soc Lond* 15: 419–454

(Received December 14, 1995 / Accepted July 26, 1996)