



## **Exfoliative Cytology in Vaginal Vestibule of Female Asian Elephants: Relation to Circulating Progesterone Concentrations**

Authors: Doi, Osamu, Komatsumoto, Mai, Terazono, Minako, Wada, Seitaro, Akihisa, Narito, et al.

Source: Zoological Science, 17(9) : 1303-1309

Published By: Zoological Society of Japan

URL: <https://doi.org/10.2108/zsj.17.1303>

---

BioOne Complete ([complete.BioOne.org](https://complete.BioOne.org)) is a full-text database of 200 subscribed and open-access titles in the biological, ecological, and environmental sciences published by nonprofit societies, associations, museums, institutions, and presses.

Your use of this PDF, the BioOne Complete website, and all posted and associated content indicates your acceptance of BioOne's Terms of Use, available at [www.bioone.org/terms-of-use](https://www.bioone.org/terms-of-use).

Usage of BioOne Complete content is strictly limited to personal, educational, and non - commercial use. Commercial inquiries or rights and permissions requests should be directed to the individual publisher as copyright holder.

---

BioOne sees sustainable scholarly publishing as an inherently collaborative enterprise connecting authors, nonprofit publishers, academic institutions, research libraries, and research funders in the common goal of maximizing access to critical research.

# Exfoliative Cytology in Vaginal Vestibule of Female Asian Elephants: Relation to Circulating Progesterone Concentrations

Osamu Doi<sup>1\*</sup>, Mai Komatsumoto<sup>1</sup>, Minako Terazono<sup>1</sup>, Seitaro Wada<sup>2</sup>, Narito Akihisa<sup>2</sup>,  
Hidefusa Sakamoto<sup>2</sup>, Tsutomu Hamasaki<sup>2</sup>, Hiroshi Yanagimoto<sup>2</sup>,  
Kazuhiko Nakano<sup>2</sup>, Kenji Matsuoka<sup>2</sup>, Atsushi Ito<sup>2</sup>,  
Hiroshi Kusunoki<sup>3</sup> and Takao Nakamura<sup>1</sup>

<sup>1</sup>Faculty of Agriculture, Gifu University, Gifu 501-1193,

<sup>2</sup>Kyoto Municipal Zoo, Sakyo-ku, Kyoto 606-8333,

<sup>3</sup>Experimental Farm, Faculty of Agriculture, Kobe University, Hyogo 675-2103, Japan

---

**ABSTRACT**—The estrous cycle of the Asian elephant (*Elephas maximus*) was monitored by analysis of exfoliative cytology in the vaginal vestibule and serum progesterone concentrations. Appearance frequency of each 5 exfoliative cells; parabasal, intermediate, superficial anuclear and nuclear cells and leukocytes; on the smear collected from two elephants was calculated, and serum progesterone concentrations were measured by radioimmunoassay. Serum progesterone concentrations changed regularly with the cycle between 14 and 17 weeks. Using spectrum analysis (Yule-Walker method) to appearance frequency of exfoliative cells, it was found that the time when a superficial cell markedly appeared in vaginal vestibule corresponded to the time when serum progesterone concentration was almost negligible. It is suggested that the time when numbers of two kinds of superficial (anuclear and nuclear) cells and parabasal and intermediate cells increase to the smear of the elephant, means the period from proestrus to estrus and from metestrus to diestrus, respectively.

---

Research of the estrous period in the elephant has focused especially on changes both in behavior and in hormone concentrations of the blood. The estrous cycle of the working Asian elephant, as determined by teasing with males (Jainudeen *et al.*, 1971), has been reported to have a mean duration of 22 days. In captive Asian elephants, Chappel and Schmidt (1979) have reported their estrous cycle to be an 18-day one, as determined by serum luteinizing hormone analysis. Ramsay *et al.* (1981) have measured estradiol concentrations in the urine and determined the estrous cycle to be 18 to 26 days long (approximately 3 weeks). More recently it has been proven by Hess *et al.* (1983), Brannian *et al.* (1988), Plotka *et al.* (1988) and Taya *et al.* (1991), who monitored changes in the progesterone concentration in the blood, that the estrous cycle of the elephant lasts for 15 to 17 weeks. Observation of the vaginal smear is the most commonly used method for tracking the estrous cycle in experimental animals, and this method thus also appears to be the most feasible in endangered animal species. There are two reports by Jainudeen *et al.* (1971)

and Watson and D'Souza (1975) that describe the smear from the vaginal vestibule or vagina in the elephant. However, Jainudeen *et al.* (1971) has reported no apparent changes in the observed frequency of variform cells accompanied by estrus in the Asian elephant. Watson and D'Souza (1975) have suggested that the estrus of the African elephant is a 16-day cycle based on examinations of mucus for ferning and vaginal cytology. There have been no reports describing identification of the estrous cycle based on observations of both vaginal cytology and fluctuations of sex steroid hormones in the blood.

The purpose of the present report is to clarify the relationship between changes in the smear and serum progesterone concentrations in the blood in the captive Asian elephant of Japan.

## MATERIALS AND METHODS

### Animals and sample collection

Exfoliative cells and blood samples were collected once a week (from January 11, 1994 to November 25, 1996) from two female Asian elephants (16 and 21 years of age) housed at the Kyoto Municipal Zoo in Japan. The long vaginal canal (approximately 1 m) in the

\* Corresponding author: Tel. 058-293-2872.

E-mail: doi@cc.gifu-u.ac.jp

female elephant made it difficult to collect vaginal smears. Smears were, therefore, obtained from the ventral part of the vaginal vestibule. Animals were restrained in the standing position, and a spatula was inserted 20 cm into the vulva. Blood samples were collected with an injection syringe from the vein of the membrum pelvinum. Blood samples were allowed to clot at room temperature for approximately 2 hr, and the serum was collected by centrifugation for 15 min at 3000 rpm. The serum was frozen and kept at  $-20^{\circ}\text{C}$  until assayed.

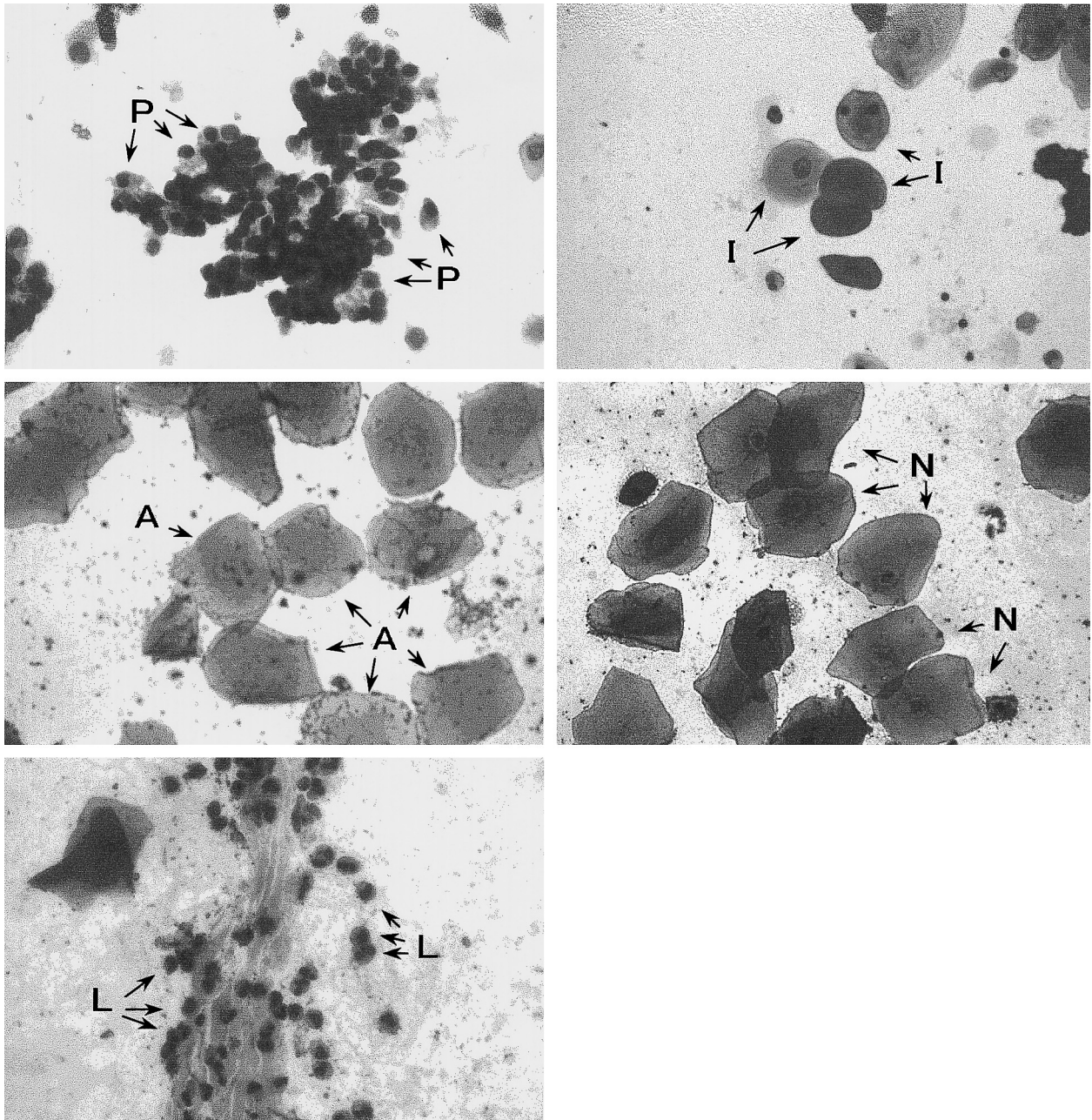
#### Vaginal vestibule cytology

Samples were swabbed on each glass slide, dried in air, fixed in 100% methyl alcohol for 3 to 5 min, and stained with Giemsa solution for 15 to 20 min. Smears were observed by light-microscope, and cells were classified according to the reports of Jainudeen *et al.* (1971)

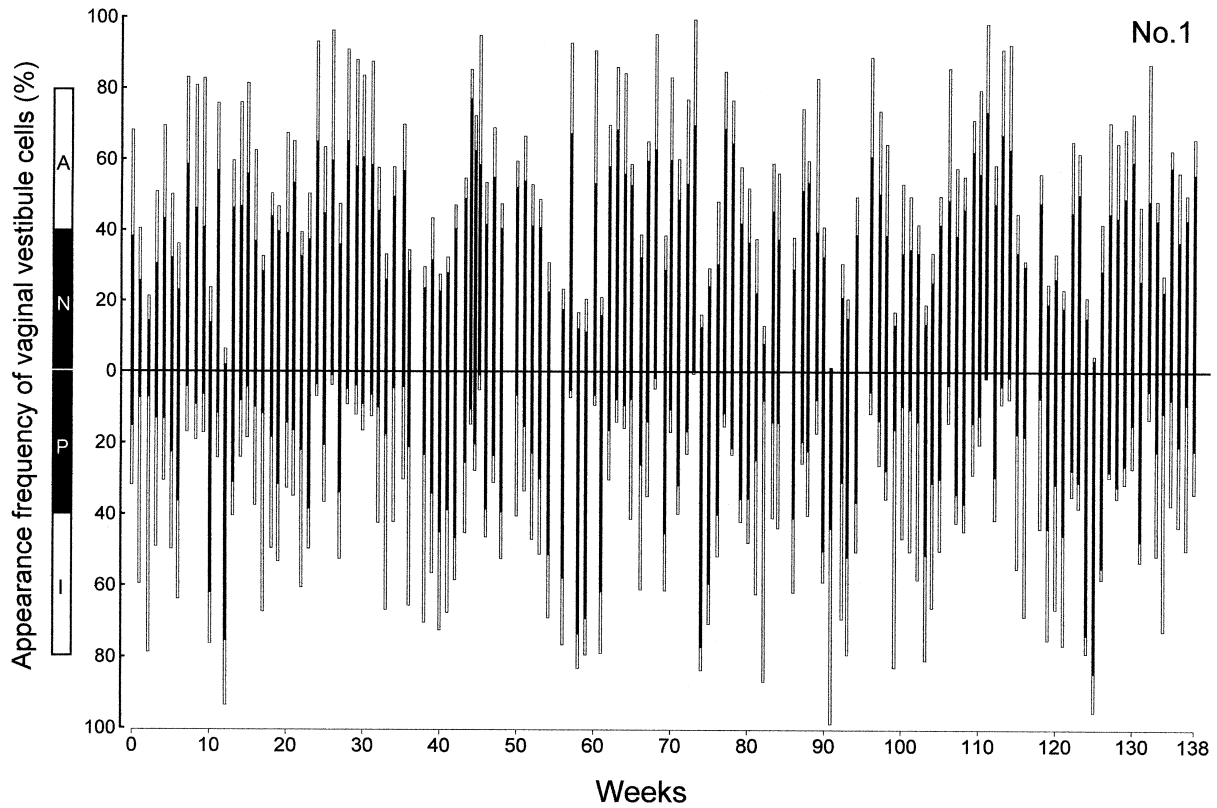
and Herron (1977). Exfoliative cells of the vaginal vestibule were observed more than 500 times in total, and the frequency of appearance of these various cells collected in each estrous period was calculated. Moreover, the ratio of leukocytes to all exfoliative cells observed in the same microscopic view was calculated.

#### Assay of steroids

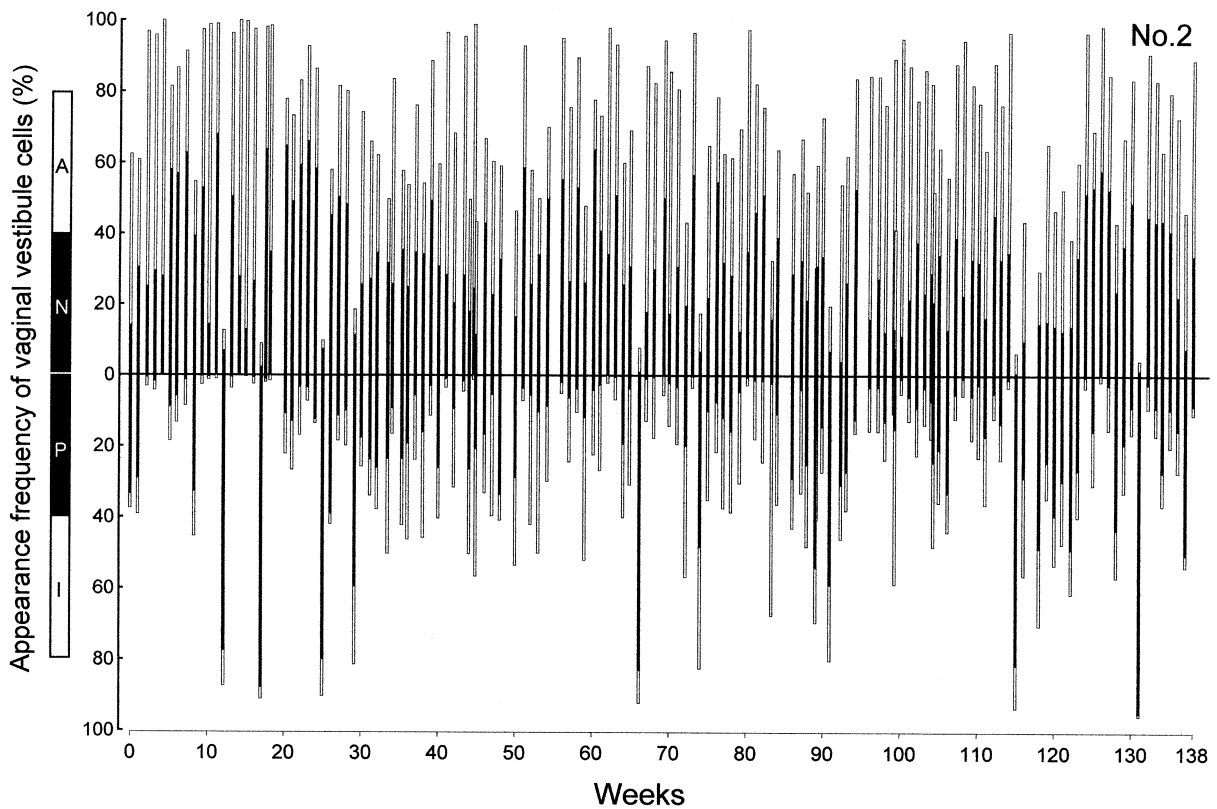
One-tenth to one-half milliliters of serum were used for the determination of progesterone concentrations. For the assay of the serum steroid hormone, samples were extracted three times with diethyl ether. The radioimmunoassay of progesterone in the serum was carried out as described previously (Tanabe *et al.*, 1983). The antibody used for this and the cross-reactivity assay was the same as described previously (Tanabe *et al.*, 1983). Radioactivity was measured with a



**Fig. 1.** Smear of vaginal vestibule collected from the female Asian elephant. The arrows indicate five kinds of exfoliative cells; parabasal (P), intermediate (I), superficial anuclear (A) and nuclear (N) cells and leukocyte (L).



**Fig. 2.** Appearance frequency of four kinds of exfoliative cells except for the leukocyte in the female Asian elephant No.1. A: superficial anuclear cell, N: superficial nuclear cell, P: parabasal cell, I: intermediate cell.



**Fig. 3.** Appearance frequency of four kinds of exfoliative cells except for the leukocyte in the female Asian elephant No.2. A: superficial anuclear cell, N: superficial nuclear cell, P: parabasal cell, I: intermediate cell.

liquid scintillation spectrometer (Tri-Carb 2500TR, Packard USA). The intra- and inter-assay coefficients of variation were determined to be 8.0% and 9.5% for the progesterone assay.

### Statistical analyses

The cells appearing mainly in the vaginal vestibule were studied in relation to changes in the steroid hormone concentrations accompanying the estrous cycle of the Asian elephant. A time series analysis was used to determine whether the frequency of appearance of each cell type had periodicity, and to predict the timing of the next estrus. Spectrum analyses (Yule-Walker method) were carried out to calculate statistically the cellular appearance frequency (Kitagawa and Gersh, 1984).

## RESULTS

Five kinds of exfoliative cells, parabasal, intermediate, superficial anuclear and nuclear cells, and leukocytes, were identified in the smears of the vaginal vestibule collected from the female Asian elephant (Fig. 1). The classification of these cells was performed with reference to reports regarding the elephant (Jainudeen *et al.*, 1971) and the cat (Herron, 1977). We used these reports as a basis to classify the cells in this study. Consequently, nucleated and anucleated cornified cells as well as two kinds of uncornified cells were identified in the vaginal vestibule smear of an elephant. Superficial anuclear and nuclear cells were multi-angular, large cells, while the parabasal and intermediate cells were small circular or oval cells with poor cytoplasm. The cornified cells were in a conglomerate form uniformly stained with Giemsa. The uncornified

cells, some blushed with Giemsa stain and some not, were classified by the form of the cell. The number of cornified cells that appeared in the smear was much greater in Subject B (26 years old at the time of study) than in Subject A (16 at the time of study). A greater change was observed in the cell form of the vaginal vestibule in the younger Subject A. Although there was a period when the leukocyte in the smear suddenly increased in number, that was by no means related to the dynamic movement of sex hormones in the blood. There was also a very small number of erythrocytes in the smear.

The appearance frequency of four kinds of cells, excepting the leukocyte, in two individual elephants, and the changes in the number of leukocytes toward one vaginal vestibule cell, are shown in Figs. 2, 3, and 4. The results of the spectrum analysis of the four kinds of cells recognized in the vaginal vestibule smears of the elephant, and the changes in the serum progesterone concentrations of two individual elephants are shown in Figs 5 and 6. These results show a marked change in the appearance frequency of two kinds of superficial cells recognized in the smear, and seven peaks of the appearance frequency are apparent for the measurement period. On the other hand, the serum progesterone concentrations ranged from 0.09 to 3.08 ng/ml and showed a periodic change from 14 to 17 weeks eight times in total during the experiment. When the appearance frequency of the superficial cells is compared with changes in the serum progesterone concentration, the appearance of superficial cells in the vaginal vestibule appears to correspond to the time when

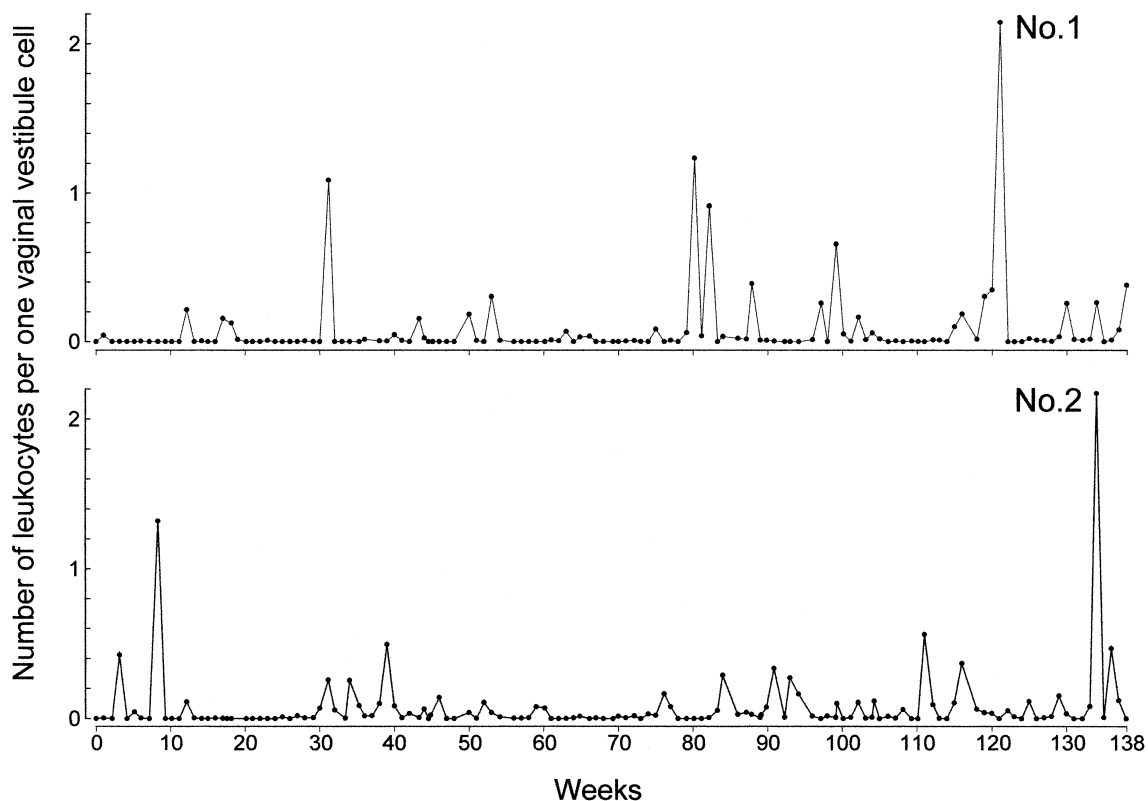
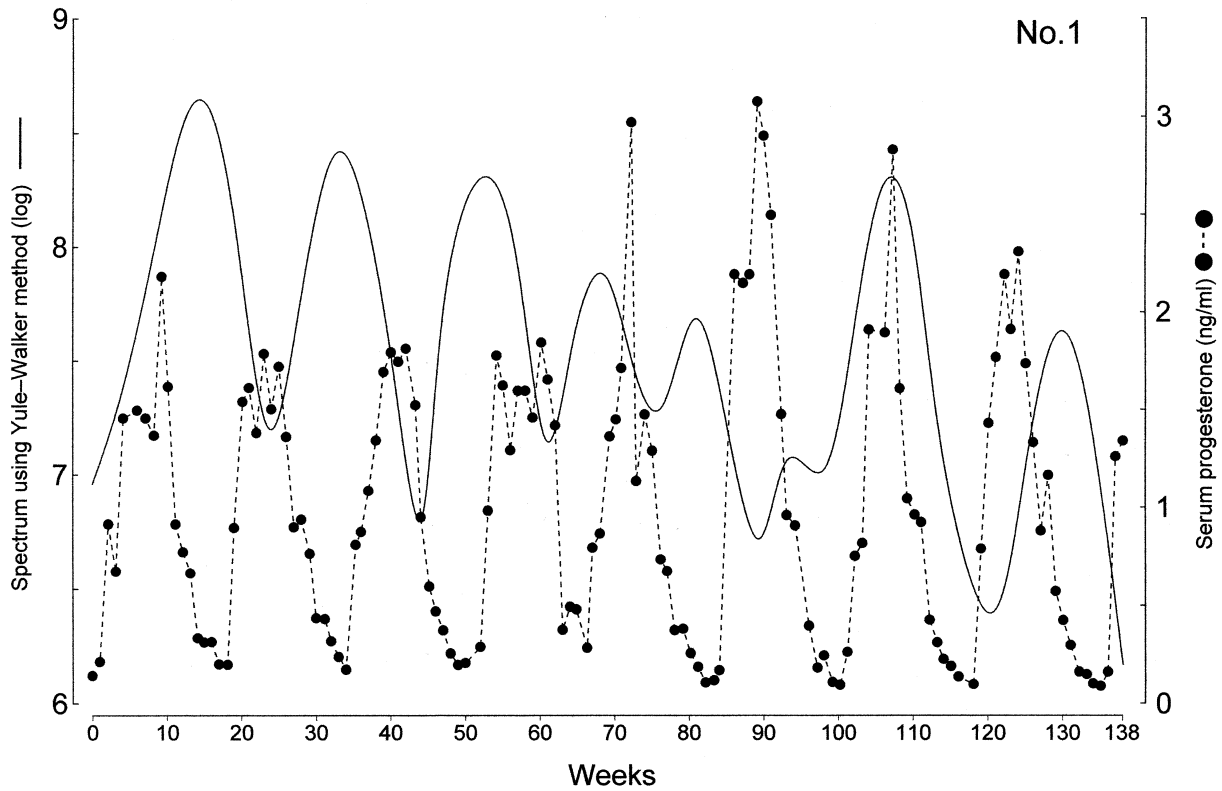
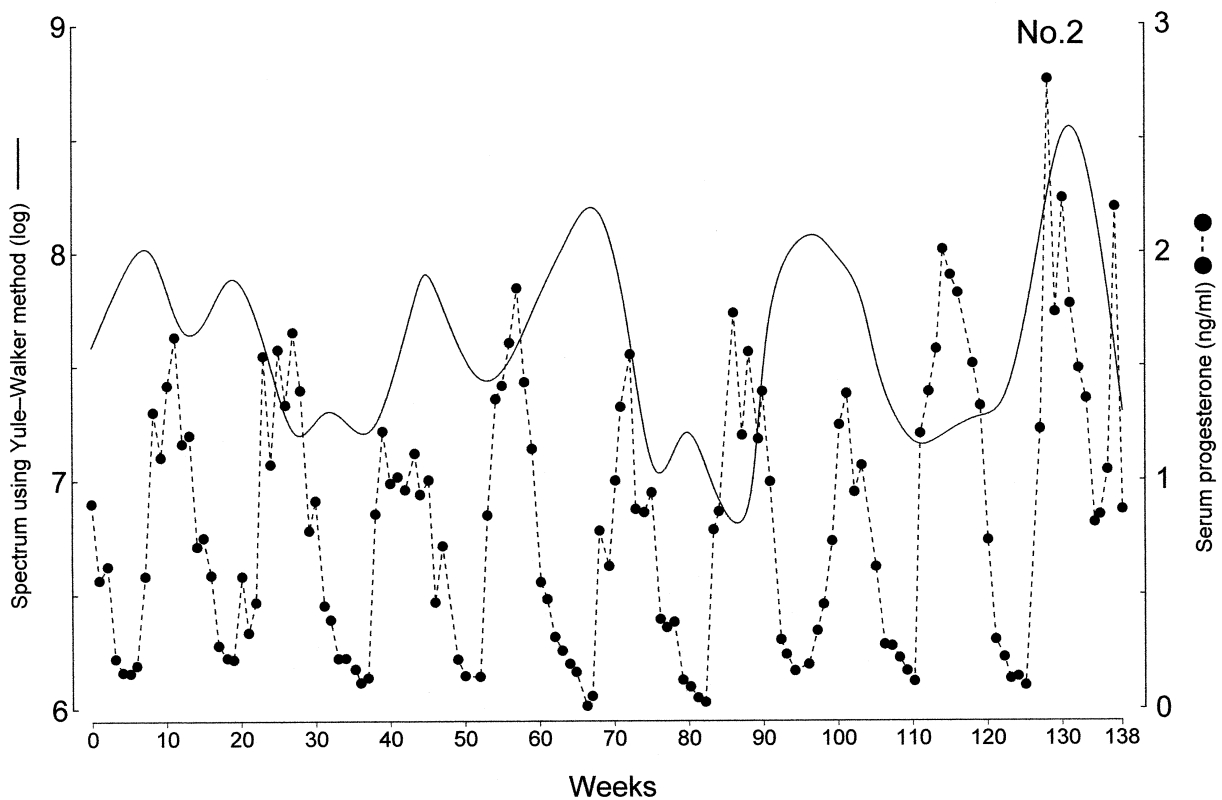


Fig. 4. The change in the number of the leukocyte to one vaginal vestibule cell.



**Fig. 5.** Spectrum by time series analysis (using Yule-Walker method) to the appearance frequency of exfoliative cells in vaginal vestibule of female Asian elephant (No.1) and sequential changes in serum progesterone concentrations.



**Fig. 6.** Spectrum by time series analysis (using Yule-Walker method) to the appearance frequency of exfoliative cells in vaginal vestibule of female Asian elephant (No.2) and sequential changes in serum progesterone concentrations.

progesterone concentrations in the serum are lowest. Leukocytes were not always identified in the smears. Although leukocytes were abundant in the smears many times during the experimental period, these durations appeared to be from 1 to 3 weeks in our result.

## DISCUSSION

Measuring hormone concentrations in the blood is the most reliable method of confirming the timing of the estrous cycle. In recent years, it has been demonstrated that the estrous cycle in the elephant lasts for almost 15 to 17 weeks based on changes in the hormone concentrations in the blood (Plotka *et al.*, 1988; Hess *et al.*, 1983; Brannian *et al.*, 1988; Taya *et al.*, 1991). Our research has also shown that changes in progesterone concentrations in the serum occur over an interval of 14 to 17 weeks, which corresponds well with previously reported results. It is generally very difficult to track the estrous cycle of elephants housed in zoos in Japan based on behavior. It is hoped that being able to rapidly and definitively determine estrus in the zoo will help to increase the future elephant population in Japan. As it is apparently stressful for elephants to collect blood repeatedly over a long period, it would obviously be desirable to determine the timing of estrus by a noninvasive method. Therefore, five kinds of cells that could be collected from the vaginal vestibule in the elephant were observed, and their frequency of appearance was examined in this research. The present investigation was undertaken to track the estrous cycle of the Asian elephant using a smear collected from the vaginal vestibule and to compare these findings with steroid titers in a blood sample collected at the same time.

There have already been many reports of research in cattle (Miroud and Noakes, 1990), the horse (Britton, 1982), sheep (Krajnicakova *et al.*, 1992), swine (Rodgers *et al.*, 1993), the dog (Tammer *et al.*, 1994), the cat (Shille *et al.*, 1979), the guinea pig (Gomez and Boxaca, 1982), the monkey (Jarosz *et al.*, 1977), and the black rhinoceroses (Kock *et al.*, 1991), concerning the onset of estrus and the estrous cycle. External manifestations of estrus such as behavior and vaginal mucus are well known, especially in domestic animals, and changes occurred in the vaginal smears of laboratory rodents during the estrous cycle have been extensively described. But in domestic animals, including cattle (Miroud and Noakes, 1990), horses (Britton, 1982), and sheep (Krajnicakova *et al.*, 1992), vaginal smears are less reliable indicators of ovarian events. Jainudeen *et al.* (1971) have reported that similarly in the elephant, no characteristic patterns are observable in urogenital smears, and the onset of estrus cannot be clearly identified. Watson and D'Souza (1975) have suggested that estrus of the African elephant is a 16-day cycle based on an examination of mucus for ferning and vaginal cytology, but this judgment is not appropriate according to many recent reports of hormone analysis in the elephant (Plotka *et al.*, 1988; Hess *et al.*, 1983; Brannian *et al.*, 1988; Taya *et al.*, 1991). In a study conducted by Taya *et al.* (1991), they successfully

measured the concentration of estrogen in the blood of an Asian elephant and clarified its fluctuations in an extremely small quantity (10 pg/ml or smaller). It was further demonstrated that estrogen concentration in the blood increased at the time when the progesterone concentration level began to rise (Taya *et al.*, 1991). In many cases of our results, there was a large number of cornified cells in the smears when the blood progesterone concentration was low. Considering the fluctuations in the estrogen concentration in the blood reported by Taya *et al.*, the cornified cells would no doubt increase when the estrogen concentration was high. However, of the 17 estrous cycles of the two elephants studied, four cases found that the number of cornified cells did not increase when the blood estrogen concentration was estimated to be high. Our results clearly showed that progesterone concentrations in the blood were lowest when two kinds of superficial (anuclear and nuclear) cells appeared abundantly in the vaginal vestibule, and concentrations of the hormone began to rise as the number of superficial cells decreased. In our study, the fact that there was clearly a cyclic fluctuation in the elephants' smears was verified by examining the cell smears of two elephants on a long-term basis and by conducting a spectrum analysis on the incidence of these cells.

In swine (the Yucatan pig), the combined superficial and large intermediate cell counts have been reported to be significantly higher during estrus than during diestrus or proestrus (Rodgers *et al.*, 1993). In the case of other livestock, the results of the similar experiment have been ambiguous. In the present study, there were occasions when the number of leukocytes observed in the smear increased rapidly in a short period (approximately 1 to 3 weeks). This sharp increase did not always occur in all cases, although the number of the leukocytes tended to increase when progesterone concentrations in the blood were low. Although Rodgers *et al.* (1993) have reported that the moving mean leukocyte count always exceeds the epithelial cell count (regardless of type) except during the 3 to 4 days when pigs exhibit external signs of estrus, we failed to confirm these results in the present experiment. Our results do suggest, however, that increases in the number of two types of superficial cells, parabasal and intermediate cells, in the smear of the elephant indicate the changes from proestrus to estrus and from metestrus to diestrus, respectively. We are, therefore, able to conclude that weekly vaginal smears can be used to determine the stage of estrus in the Asian elephant.

Gathering a vaginal vestibule smear from an elephant is relatively easy if the zoo conducts "free contact" animal training on a regular basis. It is believed to be less stressful to the animal if its steroid hormone is measured from fecal and urinary samples and then the estrous cycle is estimated. However, it takes longer time to get estimated results from fecal and urinary sampling than from blood samples. Although there may be difficulty in collecting a vaginal vestibule smear unless the elephant has been trained with "free contact", it will make the task easier and shorten the time for getting estimated results if we can make judgments from the smears and

estimate the animal's estrous cycle. Yet if we can make judgments from the smears and estimate the animal's estrous cycle, we will be able to receive test results promptly inside the zoo. That is indeed the indispensable and important aspect of this study.

### ACKNOWLEDGEMENT

The authors are grateful to Prof. Y. Tamura and Assist. Prof. S. Sato, the Institute of Statistical Mathematics, Ministry of Education, Science, Sports and Culture in government of Japan (Monbusho) for statistical advice.

### REFERENCES

- Brannian JD, Griffin F, Papkoff H, Terranova PF (1988) Short and long phases of progesterone secretion during the oestrous cycle of the African elephant (*Loxodonta africana*). *J Reprod Fertil* 84: 357–365
- Britton BA (1982) Endometrial change in the annual reproductive cycle of the mare. *J Reprod Fertil (suppl)* 32: 175–180
- Chappel SC, Schmidt M (1979) Cyclic release of luteinizing hormone and the effects of luteinizing hormone-releasing hormone injection in Asiatic elephants. *Am J Veter Res* 40: 451–453
- Gomez MD, Boxaca MC (1982) Desarrollo de un metodo citologico para detectar el estado de preñez en el cobayo. *Acta Physiol Latinoamericana* 32: 163–174
- Herron MA. (1977) Feline vaginal cytologic examination. *Feline Practice* 7: 36–39
- Hess DL, Schmidt AM, Schmidt MJ (1983) Reproductive cycle of the Asian elephant (*Elephas maximus*) in captivity. *Biol Reprod* 28: 767–773
- Jainudeen MR, Eisenberg JF, Tilakeratne N (1971) Oestrous cycle of the asiatic elephant, *Elephas maximus*, in captivity. *Reprod Fertil* 27: 321–328
- Jarosz SJ, Kuehl TJ, Dukelow WR (1977) Vaginal cytology, induced ovulation and gestation in the squirrel monkey (*Saimiri sciureus*). *Biol Reprod* 16: 97–103
- Kitagawa G, Gersh W (1984) A smoothness priors - state space modeling of time series with trend and seasonality. *J Am Stat Assoc* 79: 378–389
- Kock N, Morton D, Kock M (1991) Reproductive parameters in free-ranging female black rhinoceroses (*Diceros bicornis*) in Zimbabwe Onderstepoort. *J Vet Res* 58: 55–57
- Krajnicakova M, Bekeova E, Maracek I, Hendrichovsky V, Elecko J (1992) Dynamika zmien cytologickeho obrazu posvoveho steru a ovarialnych hormonov cirkulujucej krvi v puerperalnom období bahnic. *Veter Med* 37: 449–458
- Miroud K, Noakes DE (1990) Exfoliative vaginal cytology during the oestrous cycle of the cow, after ovariectomy, and after exogenous progesterone and oestradiol-17 beta. *Br Vet J* 146: 387–397
- Plotka ED, Seal US, Zarembka FR, Simmons LG, Teare A, Phillips LG, Hinshaw KC, Wood DG (1988) Ovarian function in the elephant: luteinizing hormone and progesterone cycles in African and Asian elephants. *Biol Reprod* 38: 309–314
- Ramsay EC, Lasley BL, Stabenfeldt GH (1981) Monitoring the estrous cycle of the Asian elephant (*Elephas maximus*), using urinary estrogens. *Am J Veter Res* 42: 256–260
- Rodgers JB, Sherwood LC, Fink BF, Sadove RC (1993) Estrus detection by using vaginal cytologic examination in miniature swine. *Lab Anim Sci* 43: 597–602
- Shille VM, Lundstrom KE, Stabenfeldt GH (1979) Follicular function in the domestic cat as determined by estradiol-17 beta concentrations in plasma: relation to estrous behavior and cornification of exfoliated vaginal epithelium. *Biol Reprod* 21: 953–963
- Tammer I, Blendinger K, Sobiraj A, Bostedt H (1994) Über den Einsatz der exfoliativen Vaginalzytologie im Rahmen der gynäkologischen Befunderhebung bei der Hundin. *Tierärztliche Praxis* 22: 199–207
- Tanabe Y, Yano T, Nakamura T (1983) Steroid hormone synthesis and secretion by testes, ovary, and adrenals of embryonic and postembryonic ducks. *Gen Comp Endocrinol* 49: 144–153
- Taya K, Komura H, Kondoh M, Ogawa Y, Nakada K, Watanabe G, Sasamoto S, Tanabe K, Saito K, Tajima H, Narushima E (1991) Concentrations of progesterone, testosterone and estradiol-17 β in the serum during the estrous cycle of Asian elephant (*Elephas maximus*). *Zoo Biology* 10: 299–307
- Watson PF, D'Souza FD (1975) Detection of oestrus in the African elephant (*Loxodonta africana*). *Theriogenology* 4: 203–209

(Received March 24, 2000 / Accepted July 12, 2000)