



Retinoic Acid Isomers Produce Malformations in Postembryonic Development of the Japanese Flounder, *Paralichthys olivaceus*

Authors: Haga, Yutaka, Suzuki, Tohru, and Takeuchi, Toshio

Source: Zoological Science, 19(10) : 1105-1112

Published By: Zoological Society of Japan

URL: <https://doi.org/10.2108/zsj.19.1105>

BioOne Complete (complete.BioOne.org) is a full-text database of 200 subscribed and open-access titles in the biological, ecological, and environmental sciences published by nonprofit societies, associations, museums, institutions, and presses.

Your use of this PDF, the BioOne Complete website, and all posted and associated content indicates your acceptance of BioOne's Terms of Use, available at www.bioone.org/terms-of-use.

Usage of BioOne Complete content is strictly limited to personal, educational, and non - commercial use. Commercial inquiries or rights and permissions requests should be directed to the individual publisher as copyright holder.

BioOne sees sustainable scholarly publishing as an inherently collaborative enterprise connecting authors, nonprofit publishers, academic institutions, research libraries, and research funders in the common goal of maximizing access to critical research.

Retinoic Acid Isomers Produce Malformations in Postembryonic Development of the Japanese Flounder, *Paralichthys olivaceus*

Yutaka Haga¹, Tohru Suzuki² and Toshio Takeuchi^{1*}

¹*Department of Aquatic Biosciences, Tokyo University of Fisheries, 4-5-7 Konan, Minato-ku, Tokyo 108-8477, Japan*

²*National Research Institute of Aquaculture, Nansai, Mie 516-0193, Japan*

ABSTRACT—We previously reported that characteristic deformities were induced by retinoic acid (RA) treatment of the Japanese flounder, *Paralichthys olivaceus*, at 6–9 days post-hatching (dph). To evaluate the toxic potency of nuclear retinoid receptors in induction of deformities by RA, we here investigated the effects of retinoic acid isomers on postembryonic development of this species. Larvae were exposed to either 25 nM of all-*trans* RA (atRA), 9-*cis* RA (9cRA) or 13-*cis* RA (13cRA) at 6–9 dph. All RA isomers induced deformities in the lower jaw, caudal fin and vertebrae. In the lower jaw, growth retardation of the dentary was evident. In the vertebrae, the major abnormalities were hypertrophy of the centrum, central fusion, and an increase in the number of abdominal vertebrae. Caudal fin deformities included deformity of caudal bone complex and absence of the entire caudal fin. The absence of the hypural primordium at 12 dph was the first sign of abnormality in caudal fin development, and resulted in complete blocking of the caudal fin development. Among the RA isomers, atRA induced the most severe deformity in all skeletons examined. Retinoic acid receptor (RAR) expression was activated by atRA and 9cRA, and *pitx2* expression was inhibited in the lower jaw by atRA and 9cRA. Vitamin D receptor (VDR) expression was specifically inhibited by atRA treatment, suggesting that RA inhibits the lower jaw growth by suppressing the expression of these genes. These results suggest that RA exerted toxic effects on the skeletal systems, mainly through the RAR pathway.

Key words: retinoic acid, deformity, flounder, larvae, development

INTRODUCTION

Teleost fishes are the lowest vertebrates having a mineralized skeleton. In higher vertebrates, the axial skeleton is generally formed by endochondral ossification in which bone is first formed as cartilage and then ossified into mineralized bone. The teleostean axial skeleton is unique in that it is formed by intramembranous ossification in which bone is formed as a bone matrix and directly ossified (Matsuoka, 1987; Ekanayake and Hall, 1988). Generally, marine fish larvae hatch much earlier in their development than other vertebrates. It would therefore seem that the spatio-temporal sequences of skeletal development in teleost are quite different from those of other, higher vertebrates.

It is well known that retinoids are potent teratogens in mammals and birds (Morriss-Kay, 1992; Zile, 1999). Embryonic exposure to retinoids also causes severe malformations in experimental animal models (Thaller *et al.*, 1993;

Minucci *et al.*, 1995). It is well established that these diverse effects depend on the concentration of retinoids and the developmental stage of the embryo (Morriss-Kay, 1992; Zile, 1999). Exposure of late gastrulation-stage rat embryos to retinoid excess has been shown to cause shortening of the preotic hindbrain (Morriss, 1972). Exposure of embryos at later stages than those affecting hindbrain development causes cleft palate and shortening of the facial processes in rat embryos (Morriss, 1972) and shortening of the frontonasal and maxillary processes in the chick (Wedden and Tickle, 1988). And RA treatments have been shown to cause facial malformations in flounder embryos (Suzuki *et al.*, 1998, 1999, 2000b). However, there have been few reports on the effects of RA on postembryonic development in teleosts. In Japanese flounder, exogenous RA treatment causes jaw deformity in postembryonic development (Haga *et al.*, 2002, in press). It is doubtful that jaw deformity occurring in postembryonic development is a causative factor of high mortality in farmed flounder (Sawada *et al.*, 2001). In another report, Haga *et al.* (2002) reported that RA treatment induced abnormalities in the vertebra and caudal fin as

* Corresponding author: Tel. +81-3-5463-0545;
FAX +81-3-5463-0545.
E-mail:take@tokyo-u-fish.ac.jp

well as the lower jaw in postembryonic development of the flounder. The action of RA is mediated through two families of specific retinoid receptors in the nucleus: retinoic acid receptors (RAR) and retinoid X receptors (RXR) (Mangelsdorf *et al.*, 1993). In a report by Suvcov and Evans (1995), these receptors are present in all vertebrates studied, share considerable homology, and have similar spatial-temporal patterns of gene expression during development across species. These receptors act as ligand-inducible transcription factors. RAR is activated by atRA and 9cRA, whereas RXR is activated by 9cRA (Heyman *et al.*, 1992; Allenby *et al.*, 1993). 13cRA does not activate either of the receptors. In our previous studies, we reported that atRA caused skeletal deformities during postembryonic development of the flounder, *Paralichthys olivaceus*, suggesting that RAR mediated these deformities (Haga *et al.*, 2002). It is also suggested that retinoid toxicity in mice, hamsters, and zebrafish is mediated by the RAR pathway but not the RXR pathway (Koccar *et al.*, 1995; Minucci *et al.*, 1995; Willhite *et al.*, 1996). On the other hand, it was reported that similar malformations were induced by 9cRA and RXR (but not RAR) selective ligands in *Xenopus laevis* (Kraft *et al.*, 1994; Minucci *et al.*, 1996). In addition, it has been shown that 9cRA is about 25 times more potent than atRA in induction of wing duplication in chick wing bud (Thaller *et al.*, 1993). This information suggests that RXR is more potent in deformities induced by RA. However, little is known about the toxic potency of RAR/RXR in teleost development. Therefore, we here examined which of the receptors is responsible for the deformities induced by RA by comparing the toxicity of atRA, 13cRA, and 9cRA.

MATERIALS AND METHODS

Animals

Flounder (*Paralichthys olivaceus*) eggs were collected at Kumamoto Prefectural Fisheries Research Institute and reared at the Fisheries Research Station, Graduate School of Kyoto University, Maizuru, Kyoto from January to March 2000. Eggs were divided into four groups in each of three 100 L transparent polycarbonate tanks filled with filtered seawater. At 10 dph, the number of larvae in each tank was adjusted to 1000 individuals. Fish were fed on rotifers and *Artemia* nauplii enriched with DHA ethyl ester (Itochu Co., Tokyo, Japan). From 6 to 9 dph, larvae were soaked with atRA, 9cRA or 13cRA as described in RA Treatments. They were then developed in normal seawater. Immediately after the immersion, the lower jaw was dissected from the larvae and subjected to PCR analysis of RAR, RXR and VDR expression. Larvae were sampled at 9, 12, 26, and 30 dph for skeletal analyses. During rearing, 1/3 of the water in the tank was manually removed and replaced with fresh seawater each day, and the photoperiod was adjusted to 12L:12D. The water temperature was kept at 17.7±1.08°C. At 43 dph, all fish were fixed in 10% neutralized formalin for morphological analysis.

RA Treatments

atRA (Sigma, Tokyo, Japan), 13cRA (Sigma) and 9cRA (Funakoshi, Tokyo, Japan) were dissolved in dimethyl sulfoxide (DMSO) (Wako Pure Chemical Industries, Tokyo, Japan), and added directly to the rearing water to obtain a final concentration of 25 nM. For the

control, only DMSO was added to the fish tanks. The larvae were subjected to RA treatment for 4 days (6–9 dph), corresponding to the B stage (Minami, 1982). During the RA treatments, all tanks were covered with dark brown polyethylene vinyl in order to prevent degradation of the RA by white light. During RA treatment, fish were reared in stationary water containing RA and 1/3 of the rearing water was exchanged each day. After adding the new water, additional RA was added to maintain the concentration of 25nM.

Biological Analysis

The skeleton was double-stained with Alcian Blue and Alizarin Red after the method of Kawamura and Hosoya (1991). After staining, phenotypes of deformity in the lower jaw, caudal fin and vertebrae were observed in 43 dph specimens. Protrusion of the isthmus area was used as a sign of severe lower jaw deformity (Takashima, 1976; Shimizu, 1987). Total length was measured at 12 and 43 dph and body weight was measured at 43 dph.

In situ hybridization

Whole-mount *in situ* hybridization was performed principally as described by Jowett and Yan (1996). Preparation of *pitx2* antisense riboprobe and whole-mount *in situ* hybridization were performed as described by Hashimoto *et al.* (2002). BM purple AP (Roche) was used as an alkaline phosphatase substrate.

RT-PCR Assay

mRNA was extracted from the jaw using a QuickPrep Micro mRNA Purification Kit (Amersham Pharmacia Biotech, Tokyo, Japan) according to the manufacturer's directions with slight modifications. The lower jaw was dissected from larva under a stereomicroscope, and dissolved in 100 µl of extraction buffer by vortexing. Samples were kept at -20°C until mRNA purification. After thawing, 200 µl of elution buffer was added to the solution. Oligo dT cellulose precipitated from 50 µl of oligo dT cellulose solution was suspended in the samples, and the samples were shaken for 10 min. After centrifugation, the oligo dT cellulose was washed twice with high salt buffer and twice with low salt buffer. After centrifugation, the buffer was discarded, and the oligo dT cellulose was suspended in 20 µl of elution buffer heated at 60°C. After brief vortexing, samples were centrifuged and the supernatant was collected. One µl of sample was withed for PCR to check for contamination of the genomic DNA. mRNA was precipitated from the remaining sample with ethanol, resuspended in RNase-free water and transcribed to first strand cDNA using a First-Strand cDNA Synthesis Kit (Amersham Pharmacia Biotech). The PCR primer sequences for flounder RAR (accession number: AB073782), RXR (accession number: AB073785), VDR (Suzuki *et al.*, 2000a) and EF1- α (Suzuki *et al.*, 1999) were as follows: RAR primers, 5'-CCGACCAGATCACTCTGCCTCAAAGC and 5'-TGTTCTGGACCTTCTCGGCAGCTTC; RXR primers 5'-CAGTGCAGGAGTGGGCTCATCTTG and 5'-GAA-GAACAGATGCTCCAGGCACTTG; and VDR-b primers 5'-GGAA-GAAGGACCTTATTCAGAGG and 5'-TGGGCGGTCTGGAGAAAG-CAAAC. EF1- α primers were 5'-TGCTGACCGTTCACGCCCC and 5'-TTGATGACACCGACGCCAC. The length of specific PCR products was 278 bp for RAR, 301 bp for RXR, 729 bp for VDR-b and 308 bp for EF1- α . The parameters of PCR were 95°C for 0.5 min, 60°C for 1 min and 72°C for 2 min. The number of cycles was 28 for RAR and RXR, 29 for VDR-b and 22 for EF1- α . rTag DNA polymerase, PCR buffer and dNTP were supplied by Takara.

Statistical Analysis

After confirming equal variance, the significance of the mean of the value was tested by ANOVA (Steel and Torrie, 1980). When significant differences were detected between individual groups by ANOVA, they were tested by Tukey's multiple tests.

RESULTS

Lower jaw deformity

No obvious anomaly was observed at 9 dph just after

the RA treatments (Fig. 1A and B). However, severe deformity of the lower jaw appeared during successive development until 43 dph (Fig. 1D and E). The growth retardation of the dentary was remarkable. In the lower jaw, the deformity

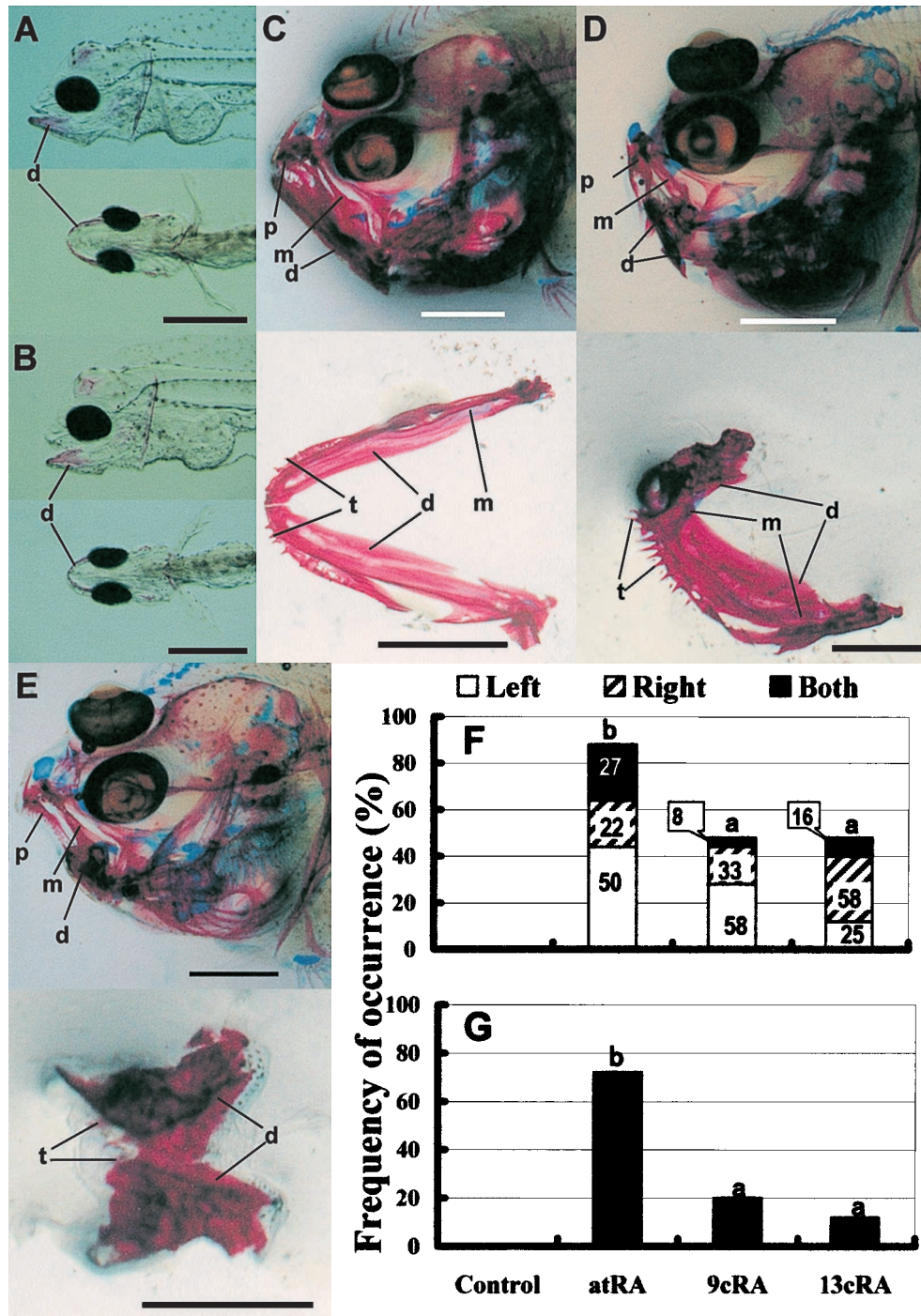


Fig. 1. Phenotypes of the lower jaw of the flounder at 9 and 43 dph. Skeletons were stained with Alizarin Red S. (A) Normal fish in the control group at 9 dph. Upper, lateral view of the larva. Lower, ventral view of the larva. (B) atRA treated-larva at 9 dph. Upper, lateral view of the larva. Lower, ventral view of the larva. (C) Upper, normal fish in the control group at 43 dph. Lower, dorsal view of the lower jaw. (D) Upper, fish showing asymmetrical lower jaw deformity at 43 dph. Lower, dorsal view of the lower jaw. (E) Fish showing paired deformity in the lower jaw at 43 dph. Upper, lateral view of the fish. Lower, dorsal view of the lower jaw. Abbreviations: d, dentary; m, maxilla; p, premaxilla; t, teeth. Bar: 500 μ m (A and B) and 1 mm (C, D and E). (F) Frequency of the occurrence of the lower jaw deformity at 43 dph (n=25). (G) Frequency of the occurrence of the protrusion of the isthmus area at 43 dph (n=25).

was classified into 2 types: asymmetrical deformity and paired deformity (Fig. 1D and E). Asymmetrical deformity was characterized as a lesser development of the jaw on one side, whereas paired deformity was characterized by a lack of development on both sides of the lower jaw. Some

specimens showed fractured Meckel's cartilage in the more affected half of the lower jaw. Fig. 1 shows the frequency of occurrence of the lower jaw deformity (F) and protrusion of the isthmus area (G). There was a significantly higher incidence of the lower jaw deformity in the atRA group. More-

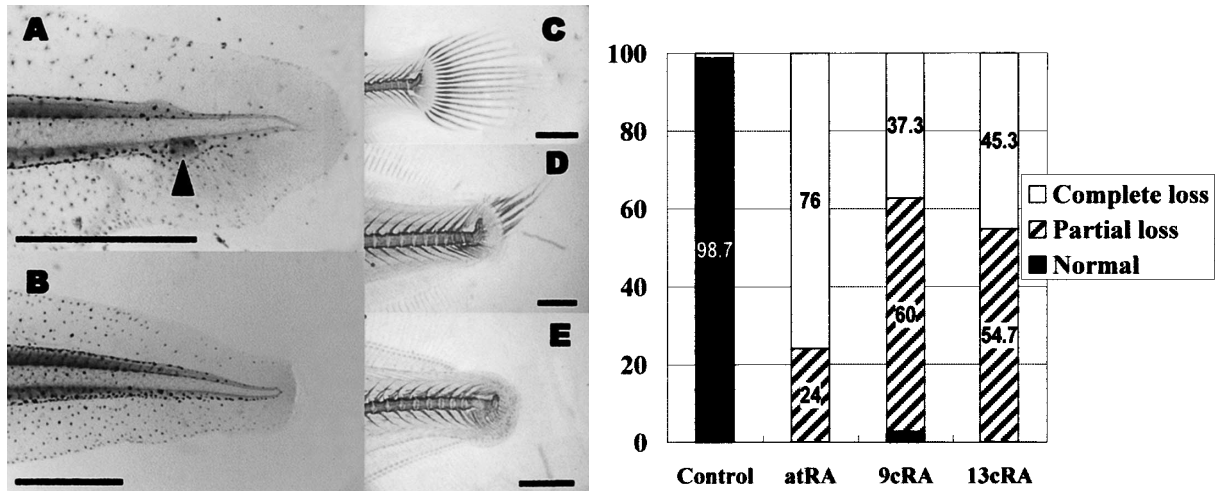


Fig. 2. Phenotypes of the caudal fin and occurrence of deformity in flounder at 43 dph. Skeletons were stained with Alizarin Red S. Cartilages were stained with Alcian Blue. (A) Caudal fin of normal flounder at 12 dph. The arrowhead indicates the hypural primordium in the ventral region of the caudal fin. (B) Caudal fin of flounder at 12 dph treated with atRA. Note the absence of the hypural primordium. (C) Normal caudal fin at 43 dph. (D) Caudal fin of atRA-treated flounder at 43 dph. Note the partial development of the caudal fin. (E) Caudal fin of the atRA-treated flounder at 43 dph. Note the complete absence of the caudal fin rays. Bar: 500 μ m (A and B) and 1 mm (C-E). The graph shows the frequency of the occurrence of caudal fin deformity in flounder at 43 dph (n=25).

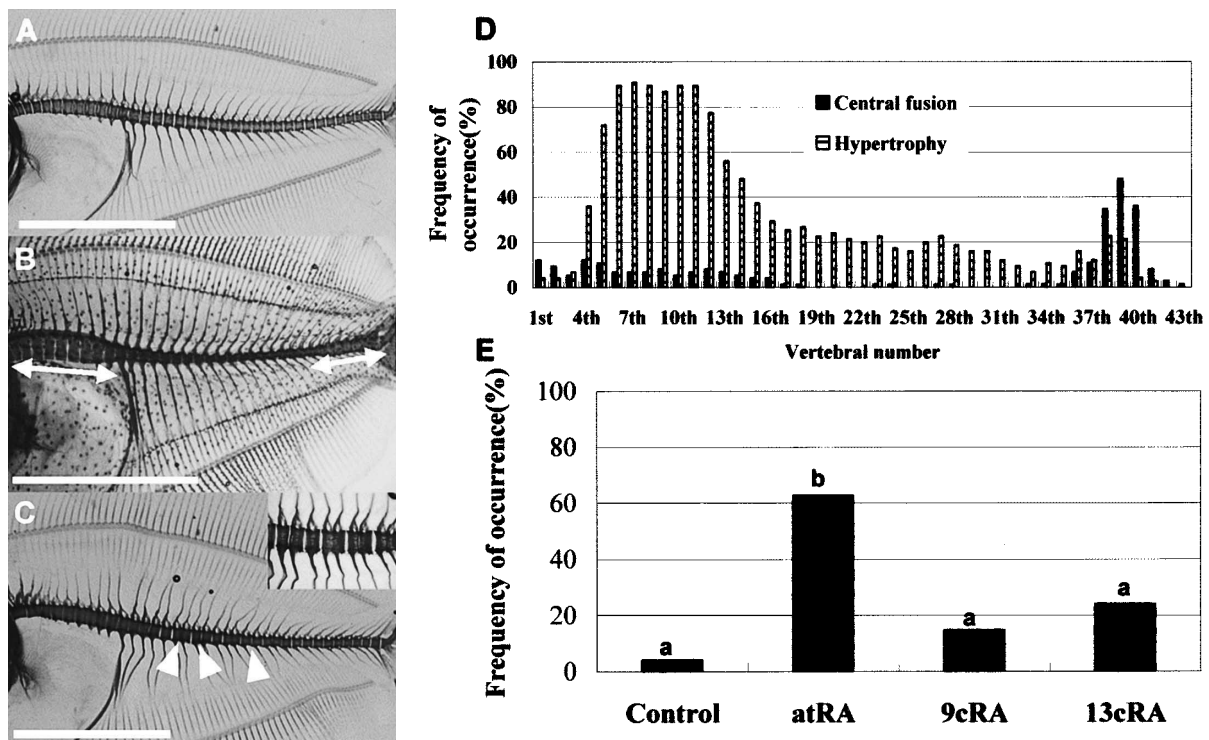


Fig. 3. Phenotypes and occurrence of the vertebral deformity of the flounder at 43 dph. (A) Normal vertebrae. (B) Vertebral hypertrophy in abdominal and caudal vertebrae. The arrow shows the hypertrophic vertebral regions. (C) Central fusion. The arrowhead shows fused vertebrae. Bar: 6mm. (D) Frequency of occurrence of fusion and hypertrophy in the centrum in atRA-treated flounder at 43 dph (n=25). (E) Frequency of occurrence of a 12th abdominal vertebra in flounder at 43 dph (n=25).

over, there was a significantly higher incidence of protrusion in the isthmus area in the atRA group, which was regarded as a sign of severe lower jaw deformity (Takashima, 1976; Shimizu, 1987). There were two types of growth retardation anomaly: asymmetrical deformity and paired deformity. More than 50% of the deformities were in the left half of the lower jaw in the atRA and 9cRA groups (Fig. 1F). On the other hand, in the 13cRA group, most (58%) of the lower jaw deformities occurred on the right side.

Caudal fin deformity

The occurrence of caudal fin deformity at 43 dph is presented in Figure 2. There were two types of deformity: partial caudal fin and complete absence of the caudal fin (Fig. 2D and E). Caudal fin deformity was always accompanied with deformity in the caudal bone complex (Fig. 2D and E). Almost all fish treated with each RA isomer had severe anomalies in the caudal fin (Fig. 2, graph). Complete absence of the caudal fin occurred in 76% of the individuals in the atRA group, whereas it occurred in only 45% of the

Table 1. Total length (mm) of flounder at 12 and 43 dph*¹

	Control	atRA	13cRA	9cRA
12 dph	6.48±0.53b* ²	5.64±0.47a* ²	5.86±0.54a* ²	5.56±0.28a* ³
43 dph* ⁴	18.4±2.84 ^c	13.3±2.66 ^a	15.5±3.30 ^b	15.0±3.03 ^b

*¹ Average±SD.

*² n=20.

*³ n=16.

*⁴ n=25.

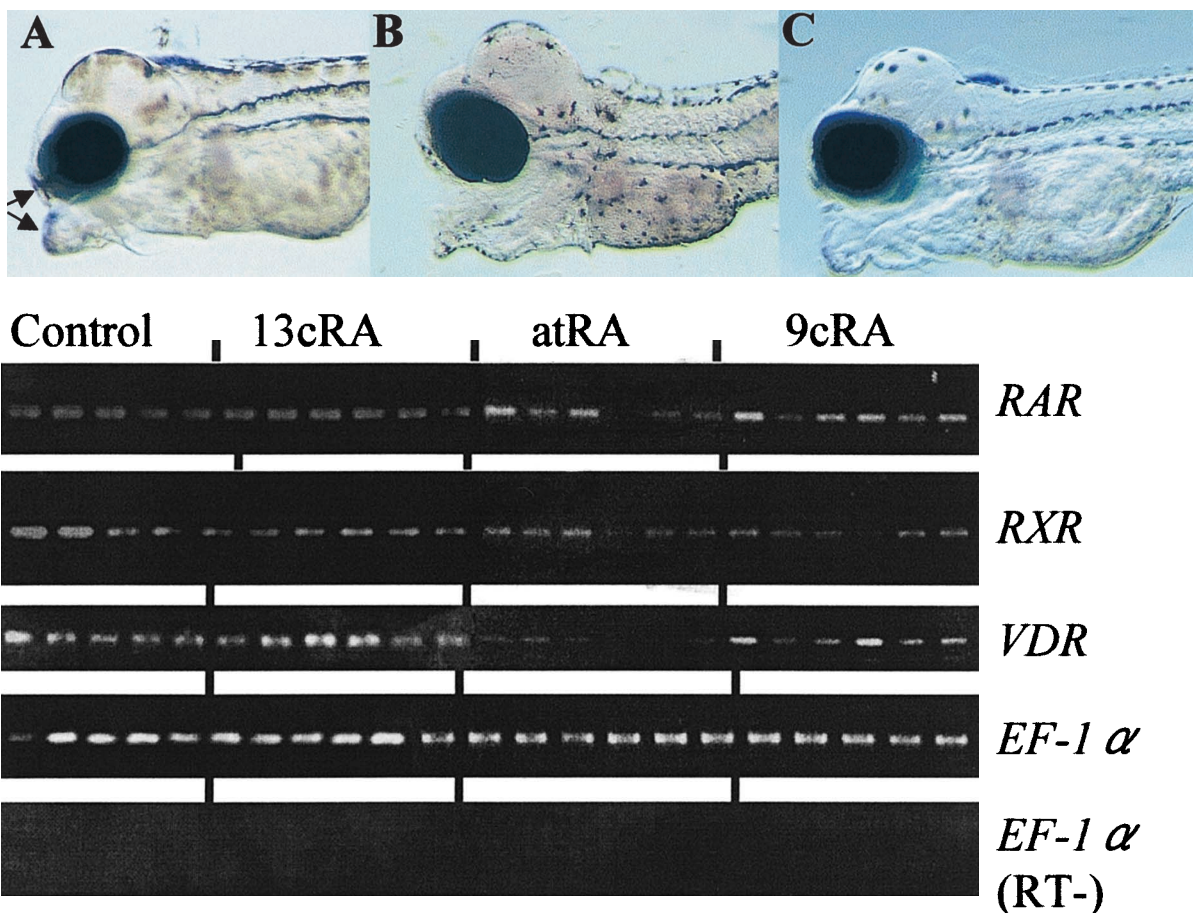


Fig. 4. Results of gene expression analysis in the lower jaw of flounder at 9 dph. Upper, results of whole mount *in situ* hybridization of *pitx2* in fish treated with DMSO (control) (A), atRA (B), or 9cRA (C). Larvae were treated with each RA isomer or DMSO (control) for 6–9 dph and fixed with 4% paraformaldehyde. Note the inhibition of *pitx2* expression in the jaw of fish treated with atRA or 9cRA. Lower, RT-PCR analysis of *RAR*, *RXR*, *VDR* and *EF-1α* expression in the lower jaw. After larvae were treated with atRA, 9cRA, 13cRA or DMSO (control) at 6–9 dph, the lower jaw was dissected and subjected to RT-PCR analysis. Each lane represents a single larva. Note the increase in *RAR* expression in the 9cRA and atRA groups and depression of *VDR* expression in the atRA group.

13cRA group and in only 33% in the 9cRA group. Partial absence of the caudal fin was observed in most of the remaining fish in the three RA groups. The absence of the hypural primordium, which results in the absence of the caudal bone complex, was first identified as an anomaly of the caudal fin at 12 dph in atRA-treated larvae (Fig. 2A and B).

Vertebral deformity

In the vertebrae, there were three types of deformity: central fusion, hypertrophy of the centrum, and additional abdominal vertebrae (Fig. 3A–C). In the atRA group, some specimens showed hypertrophy of the centrum in almost all regions along the body axis (Fig. 3B). These deformities were similar to those already reported in RA-treated flounder (Haga *et al.*, 2002). The occurrence of vertebral hypertrophy and central fusion in fish treated with atRA is shown in Figure 3D. atRA treatment induced these deformities particularly in the 4th–13th and 35th–40th vertebrae. A similar pattern of vertebral deformity was found in the other RA isomer groups. There were no obvious differences in the frequency of occurrence or degree of deformity among the RA groups in terms of vertebral hypertrophy or central fusion. On the other hand, RA induced additional vertebrae in the abdominal vertebra. Fig. 3E shows the occurrence of the 12th abdominal vertebra in fish of 43 dph. A significantly higher incidence of this deformity occurred in the atRA group. The incidence of a 12th abdominal vertebra in the other RA groups was not significantly different from the incidence in the control group.

RA induced growth retardation

Table 1 shows the growth performance of fish in body length at 12 and 43 dph. Although there was no significant difference, the growth in the three RA groups at 12 dph was smaller than that in the control group. At 43 dph, the highest growth was observed in the control group ($p < 0.01$). Growth of the three groups was in the order of 13cRA > 9cRA > atRA ($p < 0.01$). In terms of body weight, only the atRA group was significantly smaller than the control group ($p < 0.01$).

Results of gene expression analysis in the lower jaw

Fig. 4 (upper) shows the results of *in situ* hybridization of *pitx2* in flounder at 9 dph after treatment with atRA, 9cRA or DMSO (control). The *pitx2* transcript was detected in the tip of the upper and lower jaw of the control group, while atRA treatment depressed its expression. *Pitx2* expression of the 13cRA group could not be analyzed due to a lack of appropriate samples. Fig. 4 (lower) shows the results of RT-PCR analysis of RAR, RXR and VDR expression in the lower jaw at just after RA treatment at 9 dph. Both atRA and 9cRA tended to increase the expression of RAR. VDR expression was specifically inhibited by atRA treatment.

DISCUSSION

Toxic potency of RAR/RXR

atRA was found to be much more effective than the other RAs in inducing deformities in all skeletal systems examined. It was therefore suggested that RAR has stronger toxic potency during postembryonic development of Japanese flounder than RXR. Similar results were reported on the fin deformity of Japanese flounder (Miwa and Yamano, 1999). Because RAR is expressed in the lower jaw at the B stage and the expression is successive, we hypothesize that the toxic potency of RA is mediated via the RAR pathway.

Mechanisms of malformations

In Japanese flounder, RA treatment at the hatching period has been shown to disturb pharyngeal cartilage development by affecting the expression of *sonic hedgehog* (*shh*) at the pharyngeal endoderm, resulting in specific malformations (Suzuki *et al.*, 1998, 1999). *Shh* expression was detected in the lower jaw at the B stage by RT-PCR, but the expression level was not affected by RA (data not shown). However, *patched*, a receptor of *shh*, is inhibited by RA treatment during the B stage of Japanese flounder (Haga *et al.*, 2001). Further, *pitx2* has been shown to be inhibited by atRA and 9cRA treatments. Mice lacking *pitx2* expression show gross malformation, especially in the craniofacial skeletons (Lin *et al.*, 1999; Lu *et al.*, 1999), suggesting that misexpression of *pitx2* was involved in the lower jaw deformity. It has also been suggested that *pitx2* was regulated by *shh* (King and Brown, 1999). Therefore, these *shh*-related effectors would be affected by RA treatment and eventually lead to deformities.

In regard to the asymmetrical lower jaw deformity, the toxic effects on the right and left halves of the lower jaw differed among the atRA, 9cRA and 13cRA groups. The growth of fish in the 13cRA group was superior to that in the atRA and 9cRA groups immediately after RA treatment. Since the effect of RA on lower jaw development is stage-dependent in Japanese flounder (Suzuki *et al.*, 2000b; Haga *et al.*, in press), this asymmetrical deformity may reflect a developmental difference among the groups during RA treatment. In the present study, *Pitx2* expression was inhibited by atRA and 9cRA treatments. The specific inhibition of VDR expression by atRA treatment observed in the present study suggests that the lower jaw deformity is partly mediated through suppression of VDR expression. Analyses of VDR null mice clearly show that VDR has an essential role in chondrogenesis (Li *et al.*, 1997; Yoshizawa *et al.*, 1997). At the B stage, Meckel's cartilage has already formed, while the dentary exists as unossified mesenchyme. Therefore, depression of VDR in the lower jaw may contribute to a decrease in the propagation/differentiation of chondrocytes in growing Meckel's cartilage, leading to inhibition of differentiation or growth of the dentary during later development.

Deformity was also observed in the caudal fin and centrum of fish. RA treatment blocked formation of the hypural

primordium. Thus, RA treatment inhibits cartilage differentiation before commencement of chondrocyte formation. The centrum is formed by intramembranous ossification. Therefore, deformities in the caudal fin and vertebrae were induced by a signal pathway other than VDR.

Growth

RA treatment was found to significantly retard growth in terms of both total length and weight gain ($p < 0.01$). After 12 dph, the total length in the groups treated with the RAs was shorter than that in the controls. We also observed less prey in the guts of larvae treated with RA than in the guts of the controls. This suggests that the RA treatments reduced the growth of flounder during the immersion by inhibiting feeding. A similar observation was made by Miwa and Yamano (1999). At 43 dph, the growth was in the order of control $> 13cRA > 9cRA >$ and atRA, indicating that RA treatment at the B stage also reduces the growth at later stages. The poor growth in fish treated with RA isomers was most likely caused by difficulties in feeding due to deformities in the feeding apparatus. Therefore, RA negatively affected growth by direct inhibition of larval appetite during RA immersion as well as by induction of deformities in the feeding apparatus during later development.

Based on the present findings, we propose that toxic effects of RA were mediated by RAR pathway. There are three subtypes of RAR/RXR and it has been suggested that each of them has a different toxic potency (Willhite *et al.*, 1996; Elmazar *et al.*, 1997). This information will help to clarify the molecular mechanism of deformities by RA in farmed-flounder.

ACKNOWLEDGEMENTS

We express our thanks to Prof. Masaru Tanaka, Kyoto University, for kindly providing facilities for the rearing experiment. The expense of this study was defrayed in part by a Sasakawa Scientific Research Grant from The Japan Science Society.

REFERENCES

- Allenby G, Bocquel MT, Saunders M, Krazmer S, Speck J, Rosenberger M, Lovey A, Kastner P, Grippo JF, Chambon P, Levin AA (1993) Retinoic acid receptors and retinoid X receptors: Interactions with endogenous retinoic acids. *Proc Natl Acad Sci USA* 90: 30–34
- Ekanayake S, Hall BK (1988) Ultrastructure of the osteogenesis of acellular vertebral bone in the Japanese medaka, *Oryzias latipes* (Telostei, Cyprinodontidae). *Am J Anat* 182: 241–249
- Elmazar MM, Ruhl R, Reichert U, Shroot B, Nau H (1997). RAR α -mediated teratogenicity in mice is potentiated by an RXR agonist and reduced by an RAR antagonist: dissection of retinoid receptor-induced pathways. *Toxicol Appl Pharmacol* 146: 21–28
- Haga Y, Suzuki T, Kagechika H, Takeuchi T (2001) Teratogenic effects of retinoid agonist on postembryonic development of flounder, *Paralichthys olivaceus*. *Dev Growth Differ* 43(suppl): 90
- Haga Y, Takeuchi T, Seikai T (2002) Influence of all trans retinoic acid on pigmentation and skeletal formation in larval Japanese flounder. *Fish Sci* 68: 560–570
- Haga Y, Suzuki T, Takeuchi T (2002) Retinoids as potent teratogens in larval Japanese flounder, *Paralichthys olivaceus*. *Fish Sci* (in press)
- Hashimoto H, Mizuta A, Okada N, Suzuki T, Tagawa M, Tabata K, Yokoyama Y, Sakaguchi M, Tanaka M, Toyohara H (2002) Isolation and characterization of a Japanese flounder clonal line, reversed, which exhibits reversal of metamorphic left-right asymmetry. *Mech Dev* 111: 17–24
- Heyman RAM, Mangelsdorf DJ, Dyck JA, Stein R, Eichele G, Evans RM, Thaller C (1992) 9-cis retinoic acid is a high affinity ligand for the retinoid X receptor. *Cell* 68: 397–406
- Jowett T, Yan YL (1996) Double fluorescent in situ hybridization to zebrafish embryos. *Trends Genet* 12: 387–389
- Kawamura K, Hosoya K (1991) A modified double staining technique for making a transparent fish-skeletal specimen. *Bull Natl Res Inst Aquaculture* 20: 11–18
- King T, Brown NA (1999). Antagonists on the left flank. *Science* 401: 222–223
- Kochhar DM, Jiang H, Penner JD, Heyman RA (1995) Placental transfer and developmental effects of 9-cis retinoic acid in mice. *Teratology* 51: 257–265
- Kraft JC, Schuh T, Juchau M, Kimelman D (1994). The retinoid X receptor ligand, 9-cis-retinoic acid, is a potential regulator of early *Xenopus* development. *Proc Natl Acad Sci USA* 91: 3067–3071
- Li YC, Pirro AE, Amling M, Delling G, Baron R, Bronson R, Demay MB (1997) Targeted ablation of the vitamin D receptor: An animal model of vitamin D-dependent rickets type II with alopecia. *Proc Natl Acad Sci USA* 94: 9831–9835
- Lin CR, Kioussi C, O'Connell S, Briata P, Szeto D, Liu F, Izpisua-Belmonte JC, Rosenfeld MG (1999) Pitx2 regulates lung asymmetry, cardiac positioning and pituitary and tooth morphogenesis. *Nature* 401: 279–282
- Lu MF, Pressman C, Dyer R, Johnson RL, Martin JF (1999) Function of Rieger syndrome gene in left-right asymmetry and craniofacial development. *Nature* 401: 276–278
- Mangelsdorf DJ, Umeson K, Evans RM (1993) The retinoid receptors. In "The Retinoids" Ed by MB Sporn, AB Roberts, DS Goodman, Academic Press, New York, pp 319–350
- Matsuoka M (1987) Development of the skeletal tissues and skeletal muscles in the red sea bream. *Bull Seikai Reg Fsh Res Lab* 65: 1–114
- Minami T (1982) The early life history of a flounder, *Paralichthys olivaceus*. *Nippon Suisan Gakkaishi* 48: 1581–1588
- Minucci S, Saint-Jeannet J-P, Toyama R, Scita G, DeLuca LM, Taira M, Levin AA, Ozato K, Dawid IB (1996) Retinoid X receptor-selective ligands produce malformations in *Xenopus* embryos. *Proc Natl Acad Sci USA* 93: 1803–1807
- Miwa S, Yamano K (1999) Retinoic acid stimulates development of adult-type chromatophores in the flounder. *J Exp Zool* 284: 317–324
- Morriss GM (1972) Morphogenesis of the malformations induced in rat embryos by maternal hypervitaminosis A. *J Anat* 113: 241–250
- Morriss-Kay G (Ed.) (1992) Retinoids in normal development and teratogenesis. Oxford University Press 299p
- Sawada Y, Hattori M, Suzuki R, Miyatake H, Kurata M, Okada T, Kumai H (2001) Skeletal anomalies in cultured flounder, *Paralichthys olivaceus*, with shortened upper jaw. *Suisanzoshoku* 49: 451–460
- Shimizu H (1987) Bone abnormality of hatchery-reared black porgy, *Acanthopagrus schlegelii* (BLEEKER). *Bull Tokai Reg Fish Res Lab* 122: 1–11
- Soprano DR, Soprano KJ (1995) Retinoids as teratogens. *Annu Rev Nutr* 15: 111–132

- Steel RGD, Torrie JH (1980) Principles and Procedures of Statistics. A Biometrical Approach. McGraw-Hill Book Company Inc., New York
- Sucov HM, Evans RM (1995) Retinoic acid and retinoic acid receptors in development. *Mol Neurobiol* 10: 169–184
- Suzuki T, Oohara I, Kurokawa T (1998) Hoxd-4 expression during pharyngeal arch development in flounder (*Paralichthys olivaceus*) embryos and effects of retinoic acid on expression. *Zool Sci* 15: 57–67
- Suzuki T, Oohara I, Kurokawa T (1999) Retinoic acid given at late embryonic stage depresses sonic hedgehog and Hoxd-4 expression in the pharyngeal area and induces skeletal malformation in flounder (*Paralichthys olivaceus*) embryos. *Dev Growth Differ* 41: 143–152
- Suzuki T, Suzuki N, Srivastava AS, Kurokawa T (2000a) Identification of cDNA encoding two subtypes of vitamin D receptor in flounder, *Paralichthys olivaceus*. *Biochim Biophys Res Commun* 270: 40–45
- Suzuki T, Srivastava AS, Kurokawa T (2000b) Experimental induction of jaw, gill and pectoral fin malformation in Japanese flounder, *Paralichthys olivaceus*, larvae. *Aquaculture* 185: 175–187
- Takashima F (1976) Anomalies in hatchery reared ayu, *Plecoglossus Altivelis* II. Malformation of the skeleton in the larva. *J Tokyo Univ Fish*, 62: 99–112
- Thaller C, Hofmann C, Eichele G (1993) 9-cis-retinoic acid, a potent inducer of digit pattern duplications in the chick wing bud. *Development* 118: 957–965
- Wedden SE, Tickle C (1988) Epithelial-mesenchymal interactions in the development of chick facial primordia and the target of retinoid action. *Development* 99: 341–351
- Willhite CC, Dawson MI, Reichert U (1996) Receptor-selective retinoid agonists and teratogenic activity. *Drug Metab Rev* 28: 105–119
- Yoshizawa T, Handa Y, Uematsu Y, Takeda S, Sekine K, Yoshizawa Y, Kawakami K, Arioka H, Sato H, Uchiyama Y, Masushige S, Fukamizu A, Matsumoto T, Kato S (1997) Mice lacking the vitamin D receptor exhibit impaired bone formation, uterine hypoplasia and growth retardation after weaning. *Nature Genet* 16: 391–396
- Zile MH (1999) Avian embryo as model for retinoid function in early development. *In: Retinoids. The Biochemical and Molecular Basis of Vitamin A and Retinoid Action*. Ed by H Nau, WS Blanner, Springer, Berlin, pp 441–463

(Received December 3, 2001 / Accepted July 1, 2002)