

Decompression Syndrome and Diving Behavior in Odontochelys, the First Turtle

Authors: Rothschild, Bruce M., and Naples, Virginia

Source: Acta Palaeontologica Polonica, 60(1) : 163-167

Published By: Institute of Paleobiology, Polish Academy of Sciences

URL: <https://doi.org/10.4202/app.2012.0113>

BioOne Complete (complete.BioOne.org) is a full-text database of 200 subscribed and open-access titles in the biological, ecological, and environmental sciences published by nonprofit societies, associations, museums, institutions, and presses.

Your use of this PDF, the BioOne Complete website, and all posted and associated content indicates your acceptance of BioOne's Terms of Use, available at www.bioone.org/terms-of-use.

Usage of BioOne Complete content is strictly limited to personal, educational, and non-commercial use. Commercial inquiries or rights and permissions requests should be directed to the individual publisher as copyright holder.

BioOne sees sustainable scholarly publishing as an inherently collaborative enterprise connecting authors, nonprofit publishers, academic institutions, research libraries, and research funders in the common goal of maximizing access to critical research.

Decompression syndrome and diving behavior in *Odontochelys*, the first turtle

BRUCE M. ROTHSCHILD and VIRGINIA NAPLES



Rothschild, B.M. and Naples, V. 2015. Decompression syndrome and diving behavior in *Odontochelys*, the first turtle. *Acta Palaeontologica Polonica* 60 (1): 163–167.

Odontochelys semitestacea, the oldest known turtle, from the Late Triassic of China, shows a pathology. Sharply defined, focal depressions were noted on the articular surfaces of both humeri, documenting avascular necrosis. Diving habits of Mesozoic marine reptiles have been characterized on the basis of this localized form of bone death attributed to decompression syndrome. Pursuit by a predator was likely the cause of dangerously rapid depth changes by swimming turtles. The prevalence of avascular necrosis decreased geometrically from the Cretaceous to the Pleistocene. This study suggests that the habit of repetitive diving in turtles was already present in the Late Triassic, but that protective physiological and behavioral adaptations had not yet evolved.

Key words: Testudines, *Odontochelys*, turtle, diving behavior, bone pathology, avascular necrosis, Triassic, China.

Bruce Rothschild [bmr@ku.edu], Carnegie Museum, 4400 Forbes Ave, Pittsburgh, PA 15272, USA and Department of Medicine, Northeast Ohio Medical University, Rootstown, Ohio 44272, USA.
Virginia Naples [xenosmilus@aol.com], Department of Biological Sciences, Northern Illinois University, Montgomery Hall, 155 Castle Drive, DeKalb, Illinois 60115, USA.

Received 2 October 2012, accepted 15 August 2013, available online 11 October 2013.

Copyright © 2015 B.M. Rothschild and V. Naples. This is an open-access article distributed under the terms of the Creative Commons Attribution License, which permits unrestricted use, distribution, and reproduction in any medium, provided the original author and source are credited.

Introduction

Avascular necrosis, localized bone death, has been identified before in Mesozoic marine reptiles (Motani et al. 1999; Rothschild 1982; Rothschild and Martin 1987, 2006). The condition arises from decompression syndrome (Caisson's disease, the "bends"), the supersaturation of blood and tissues, without sufficient surface time for equilibration, leading to nitrogen bubble formation and subsequent vascular occlusion. The limited collateral circulation of the proximal humerus, except in *Caretta caretta*, makes it a key location for avascular necrosis (Rothschild and Martin 1987). Bone dies within the watershed of the original vascular supply when circulation is blocked, and this makes it susceptible to the compression forces of swimming and it collapses, with visible subsidence (Feldman et al. 1981; Michel et al. 1982; Ratcliffe 1985; Resnick 2002; Rothschild 1982; Rothschild and Martin 2006). Avascular necrosis provides evidence of prolonged, repetitive dives (Andersen 1966; Kooyman et al. 1973; Pauley 1965; Strauss 1970; Strauss and Sampson 1986; Rothschild 1990).

Avascular necrosis, indicating deep diving, has been identified so far in Jurassic and Cretaceous turtles (Rothschild 1987). Here we present evidence of the pathology in

the world's oldest turtle, *Odontochelys semitestacea* from the Late Triassic of southwest China.

Institutional abbreviations.—IVPP V, Institute of Vertebrate Paleontology and Paleoanthropology, Beijing, China.

Material and methods

The materials comprise the proximal portions of humeri of *Odontochelys semitestacea* Li, Wu, Rieppel, Wang, and Zhao, 2008 from the Wayao Member of the Falang Formation, of Guanling, Guizhou Province, southwest China, dated to the early Carnian marine transgression, 220 million years ago (Li et al. 2008). We investigated the humeri of paratype specimen IVPP V 13240. The specimen was examined firsthand and photographed in Beijing. The specimen was well prepared and the bone surface was not damaged during the preparation.

Results

Macroscopic examination revealed bilateral subsidence of the articular surfaces of both humeri (Figs. 1–3) Internal

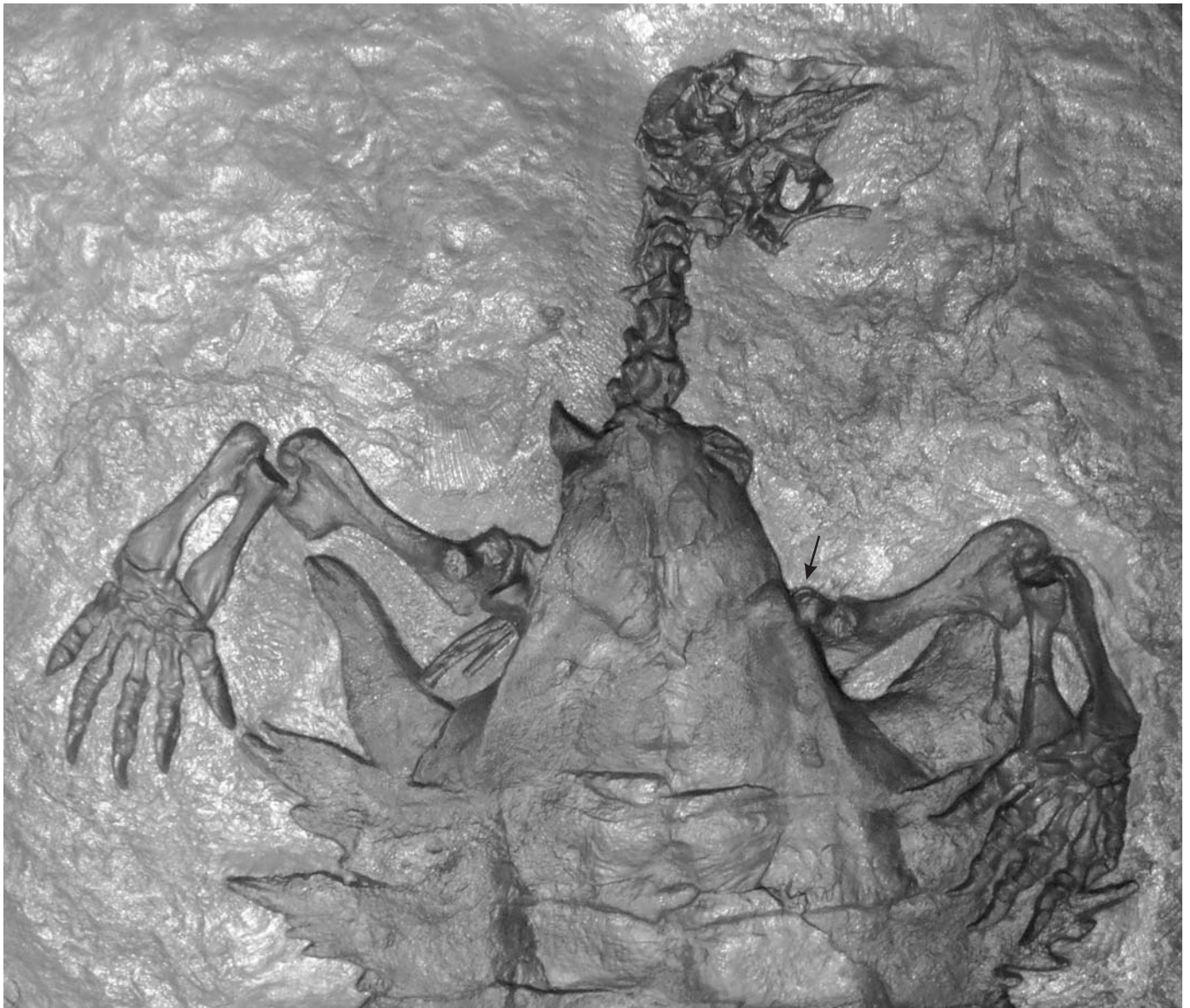


Fig. 1. Ventral view of anterior body of *Odontochelys semitestacea* Li, Wu, Rieppel, Wang, and Zhao, 2008 from the Lower Carnian (Upper Triassic) Wayao Member of the Falang Formation; Guanling, Guizhou Province, southwest China (IVPP V 13240). Defects are present on proximal humeral articular surfaces.

trabeculae were not exposed, allowing taphonomic processes to be excluded (Nielsen-Marsh and Hedges 2000; Rothschild and Martin 2006). The irregular surface defect on the proximal humeral articular surface of IVPP V 13240 contrasts with the smooth continuous surface of healthy turtle humeral articular surfaces (Depecker et al. 2006; Raidal et al. 2006) and allows recognition of avascular necrosis.

The alterations are indistinguishable from previously documented humeral avascular necrosis in turtles (Rothschild 1987, 1988, 1991; Martin and Rothschild 1989) and other marine reptiles (Rothschild and Martin 2006). Macroscopic appearance is sufficiently specific for confident diagnosis (Martin and Rothschild 1989; Rothschild 1987, 1988, 1991; Resnick 2002; Rothschild and Martin 2006). As histological assessment of bone pathology is controversial,

with diagnosis often predicated upon radiologic appearance (Hong et al. 2011) and with no evidence of diagnostic specificity for avascular necrosis (Feldman et al. 1981; Ratchliffe 1985; Resnick 2002; Rothschild and Martin 2006), destructive analysis would not contribute useful information and was not pursued.

Discussion and conclusions

Avascular necrosis is never found in terrestrial turtles (Rothschild 1991), but afflicts 50% of turtles in the Cretaceous (Rothschild 1987, 1988). Decompression syndrome from sudden depth alteration is the most parsimonious explanation. The only other phenomena that could cause such fre-

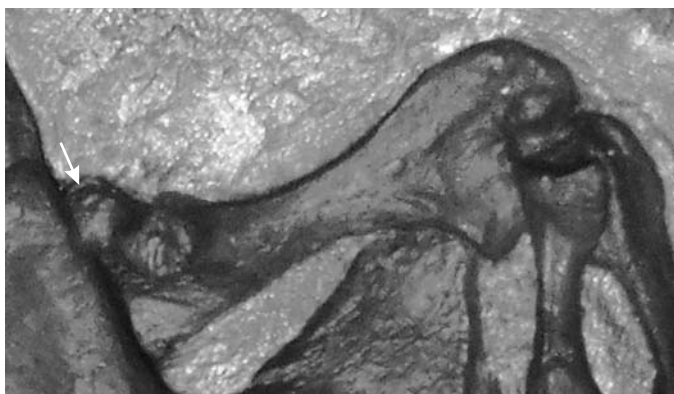


Fig. 2. Enface view of left proximal humeral articular surface of *Odontochelys semitestacea* Li, Wu, Rieppel, Wang, and Zhao, 2008 from the Lower Carnian (Upper Triassic) Wayao Member of the Falang Formation; Guanling, Guizhou Province, southwest China (IVPP V 13240). Irregular defect (arrow) is characteristic for the avascular necrosis found with decompression syndrome.

quent occurrence of avascular necrosis in any population are radiation and bismuth poisoning (Resnick 2002), previously ruled out in mosasaur avascular necrosis by scintigraphy and electron probe analyses (Rothschild and Martin 1987).

The differential diagnostic considerations for articular pathology include osteoarthritis, a rheumatoid arthritis-like inflammatory arthritis called spondyloarthropathy, gout, infection and failure of cartilage transformation into bone (osteochondrosis or cartilage rests) (Resnick 2002; Rothschild and Martin 2006). The sharply defined focal articular surface defect defining the latter (Resnick 2002; Rothschild and Martin 2006) is easily distinguished from the irregular defect observed in IVPP V 04415.

Review of the literature (Rothschild et al. 2012a, 2013) on bony alterations in turtles other than avascular necrosis revealed only one article in which shoulder pathology was reported. Raidal et al. (2006) reported proximal humeral articular surface erosion associated with reactive bone proliferation in a Recent *Caretta caretta*. While they diagnosed osteoarthritis, we suggested (Rothschild et al. 2012a) that spondyloarthropathy was a more likely diagnosis. Osteoarthritis produces bone spurs (osteophytes, absent in the case reported by Raidal et al. [2006] and in IVPP V 04415) at articular surface peripheries (Resnick 2002; Rothschild and Martin 2006), but does not produce the surface irregularities seen in the Raidal et al. (2006) case, nor in IVPP V 13240. Spondyloarthropathy characteristically erodes articular surfaces and is associated with reactive new bone formation (Rothschild and Woods 1991; Rothschild and Martin 2006; Rothschild 2010). Spondyloarthropathy has been well recognized in other reptiles (Rothschild 2010), but the report by Raidal et al. (2006) appears to be the first evidence of that disease in turtles. However, IVPP V 04415 did not have evidence of such bone alteration. Defects at sites of tendon or ligament attachment may complicate spondyloarthropathy (Resnick 2002; Rothschild and Martin 2006), but do not affect the actual articular surface (Shaibani et al. 1993).

Gout is another form of erosive arthritis, and it has been reported in the elbow or stifle of *Trachemys scripta elegans* (Marcus 1981; McArthur 1996, 2004; López del Castillo 1998), *Testudo graeca graeca* (Appleby and Siller 1960; McArthur 2004), *Testudo denticulata* (Appleby and Siller 1960), *Testudo hermanni* (Appleby and Siller 1960), *Geochelone agassizii* (Frye 1984; Homer et al. 1998) and *Mauremys leprosa* (Figueres 1997), but has a very different appearance (see below) and apparently has not been recognized in turtle shoulder joints. It produces well-defined peripheral and para-articular erosions with new bone formation producing characteristic overhanging edges (Casimire-Etzioni et al. 2004; Resnick 2002; Rothschild and Martin 2006), very different from what was observed in IVPP V 04415.

Infectious or septic arthritis is well recognized in turtles, having been noted in *Dermochelys coriacea* (Ogden et al. 1981; Coquelet 1983; Brogard 1987), *Lepidochelys kempii* (Harms et al. 2002; Greer et al. 2003; Jacobson 2007), *Geochelone agassizii* (Frye 1984; Homer et al. 1998), *Geochelone elegans* (McArthur 2004) and *Acanthochelys macrocephala* (Rhodin et al. 1990), but always limited in distribution to elbow, knee, and manus or pes. Jacobson (2007) suggested that these infections represent complications of injury. His perspective is supported by absence of infectious arthritis

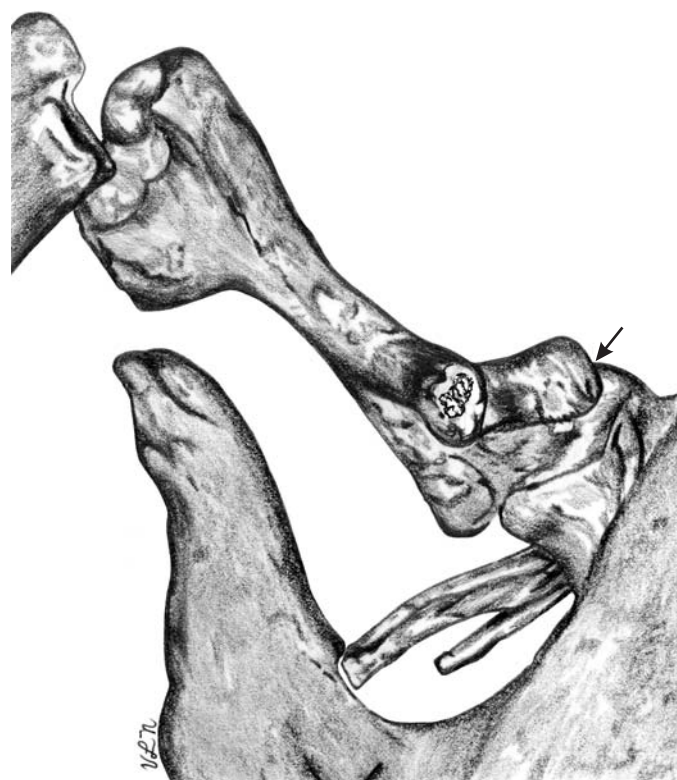


Fig. 3. Enface view of right proximal humeral articular surface of *Odontochelys semitestacea* Li, Wu, Rieppel, Wang, and Zhao, 2008 from the Lower Carnian (Upper Triassic) Wayao Member of the Falang Formation; Guanling, Guizhou Province, southwest China (IVPP V 13240). Irregular defect (arrow) is characteristic for the avascular necrosis found with decompression syndrome.

in the shoulder, which is protected from predators by the carapace and plastron.

This study suggests that the habit of repetitive diving in turtles was already established in the Late Triassic. The relatively small size of Triassic turtles, 1 m or less in *Odontochelys*, may be an important clue (Li et al. 2008), distinguishing them from ichthyosaurs. Avascular necrosis was extremely rare in Triassic ichthyosaurs (Rothschild et al. 2012b). Pursuit by a predator may have been a common cause of dangerously rapid depth changes by swimming turtles, as has been proposed for *Protostega* in the Cretaceous (Sternberg 1909: 115). The deepest diving extant sea turtle, the leatherback (*Dermochelys coriacea*) relies largely on blood and muscle oxygen stores to sustain deep dives (Lutcavage and Lutz 1997). The lack of large lung oxygen stores in this species limits the tendency for nitrogen to dissolve in blood during long dives and may reduce the risk of decompression sickness. In addition, behavioral mechanisms, such as gradual ascents, which are seen in both leatherback and other extant species of sea turtle (Fossette et al. 2010), may limit the risk of decompression syndrome.

The frequency of avascular necrosis is indistinguishable across all sizes (surrogate for age) in a species. Additional damage does not continue to accrue in adults, so decompression syndrome appears to be a phenomenon of juveniles or adolescents both in living turtles and in mosasaurs (Rothschild and Martin 2006). Juvenile sea turtles tend to be relatively shallow divers with, for example, post-hatchlings being positively buoyant and largely drifting at the ocean surface (Bjorndal et al. 2003; Scott et al. 2012). This positive buoyancy limits diving behavior and hence presumably also the risk of decompression sickness. In modern forms, juveniles and subadults presumably suffer decompression syndrome and avascular necrosis in unexpected situations, when they are forced by predators to dive deeper than normal. It is unclear at what stage of life (juvenile, adolescent or adult) the Triassic damage occurred.

The occurrence of avascular necrosis through the history of turtles shows that it was more frequent in the Mesozoic than today, suggesting that early forms had not yet evolved mechanisms to avoid the bends.

Turtles today show almost total resistance to avascular necrosis (Rothschild 1991), probably having evolved behavioral and physiological means to avoid the problem. For example, extant turtles ascend gradually to the surface to minimize decompression sickness. Further, freshwater turtles have effective extrapulmonary gas exchange, seen in mud and musk (kinosternid), soft-shelled (trionychid) and emydid turtles (Smith and Nickon 1961; Ultsch and Jackson 1982; Ultsch 1985). It is unclear when the buccal and cloacal respiratory mechanisms evolved (Heiss et al. 2010), but their presence would certainly afford the advantage of an additional gas (including nitrogen) exchange mechanism. The low nitrogen (N₂) content of water, 47.5% compared to 78% in air, augments diffusion from the blood and therefore the tissues, providing protection from decompression syndrome.

Odontochelys was likely a descendant of an older, land living turtle, and so its body shape and limbs had probably not become entirely modified for its new aquatic environment (Reisz and Head 2008). The degree of keratinization of *Odontochelys* skin is unknown, but could also have been a factor that compromised trans-dermal respiration.

Acknowledgements

Appreciation is expressed to Li Chun (Institute for Vertebrate Paleontology and Paleoanthropology, Beijing, China) for facilitating access to the specimen and to the very constructive comments of referees.

References

- Andersen, H.T. 1996. Physiological adaptations in diving vertebrates. *Physiological Review* 46: 212–258.
- Appleby, E.C. and Siller, W.G. 1960. Some cases of gout in reptiles. *Journal of Pathology and Bacteriology* 80: 427–430.
- Bjorndal, K.A., Bolten, A.B., and Martins, H.R. 2003. Estimates of survival probabilities for oceanic-stage loggerhead sea turtles (*Caretta caretta*) in the North Atlantic. *Fishery Bulletin* 101: 732–736.
- Brogard, J. 1987. *Les maladies des reptiles*. 336 pp. Maisons-Alfort: Point Vétérinaire, Paris.
- Casimire-Etzioni, A.L., Wellehan, J.F., Embury, J.E., Terrell, S.P., and Raskin, R.A. 2004. Synovial fluid from an African spur-thighed tortoise (*Geochelone sulcata*). *Veterinary Clinical Pathology* 33: 43–46.
- Coquelet, J.P. 1983. *Contribution à l'étude de la pathologie des tortues marines, Observations personnelles dans un élevage de Chelonia mydas (Linné)*. 177 pp. Thèse Doctoral Médecine Vétérinaire, Université de Nantes, Nantes.
- Depecker, M., Berge, C., Penin, X., and Renous, S. 2006. Geometric morphometrics of the shoulder girdle in extant turtles (Chelonii). *Journal of Anatomy* 208: 35–45.
- Feldman, J.L., Menkes, C.J., Amor, B., Cherot, A., and Delbarr, F.L. 1981. Osteonecrosis vertébrale de l'adults. *Révue de Rhumatologie* 48: 773–780.
- Figueres, J.M. 1997. Treatment of articular gout in a Mediterranean pond turtle, *Mauremys leprosa*. *Proceedings of the Association of Reptilian and Amphibian Veterinary Medicine* 7 (4): 5–7.
- Fossette, S., Gleiss, A.C., Myers, A.E., Garner, S., Liebsch, N., Whitney, N.M., Hays, G.C., Wilson, R.P., and Lutcavage, M.E. 2010. Behaviour and buoyancy regulation in the deepest diving reptile: The leatherback turtle. *Journal of Experimental Biology* 23: 4074–4083.
- Frye, F.L. 1984. *Biomedical and Surgical Aspects of Captive Reptile Husbandry*. Vol. 1. 456 pp. Krieger Publishing Company, Malabar.
- Greer, L.L., Strandberg, J.D., and Whitaker, B.R. 2003. *Mycobacterium chelonae* osteoarthritis in a Kemp's Ridley sea turtle (*Lepidochelys kempii*). *Journal of Wildlife Diseases* 39: 736–741.
- Harms, C.A., Lewbart, G.A., and Beasley, J. 2002. Medical management of mixed nocardial and unidentified fungal osteomyelitis in a Kemp's Ridley sea turtle, *Lepidochelys kempii*. *Journal of Herpetological Medicine and Surgery* 12 (3): 21–26.
- Heiss, E., Natchev, N., Beisser, C., Lemell, P., and Weisgram, J. 2010. The fish in the turtle: On the functionality of the oropharynx in the common musk turtle *Sternotherus odoratus* (Chelonia, Kinosternidae) concerning feeding and underwater respiration. *Anatomical Record* 293: 1416–1424.
- Homer, B.L., Berry, K.H., Brown, M.B., Ellis, G., and Jacobson, E.R. 1998. Pathology of diseases in wild desert tortoises from California. *Journal of Wildlife Disease* 34: 508–523.

- Hong, W., Sung, M.S., Chun, K.-A., Kim, J.-Y., Park, S.-W., Lee, K.-H., Lim, H.W., Lim, Y.S., Yoo, W.J., and Chung, M.H. 2011. Emphasis on the MR imaging findings of brown tumor: A report of five cases. *Skeletal Radiology* 40: 205–213.
- Jacobson, E.R. 2007. Bacterial diseases of reptiles. In: E.R. Jacobson (ed.), *Infectious Diseases and Pathology of Reptiles, Color Atlas and Text*, 461–526. Taylor and Francis, Boca Raton.
- Kooyman, G.L., Schroeder, J.P., Green, D.G., and Smith, V.A. 1973. Gas exchange in penguins during simulated dives to 30 and 68 meters. *American Journal of Physiology* 225: 1467–1471.
- Li, C., Wu, X.C., Rieppel, O., Wang, L.-T., and Zhao, L.J. 2008. An ancestral turtle from the Late Triassic of southwestern China. *Nature* 456: 497–501.
- López del Castillo, C. 1998. Metabolic diseases: Gout and articular pseudogout. *Reptilia* 3: 13–16.
- Lutcavage, M.E. and Lutz, P.L. 1997. Diving physiology. In: P.L. Lutz and J.A. Musick (eds.), *The Biology of Sea Turtles, Vol. 1*, 276–296. CRC Press, Boca Raton.
- Marcus, L.C. 1981. *Veterinary Biology and Medicine of Captive Amphibians and Reptiles*. 239 pp. Lea and Febiger, Philadelphia.
- Martin, L.D. and Rothschild, B.M. 1989. Paleopathology and diving mosasaurs. *American Scientist* 77: 460–467.
- McArthur, S. 1996. *Veterinary Management of Tortoises and Turtles*. 170 pp. Blackwell Science, Cambridge.
- McArthur, S. 2004. Interpretation of presenting signs. In: S. McArthur, R. Wilkinson, and J. Meyer (eds.), *Medicine and Surgery of Tortoises and Turtles*, 273–307. Blackwell, Oxford.
- Michel, J.L., Bouzat, J., Rivoal, A., De Pradelde Lamaze, P.H., Viallet, J.F., Belin, J., and Merle, P. 1982. La dissection gazeuse du corps vertébral ou phénomène du vide intrasomatique vertébral. *Journal de Radiologie* 63: 479–484.
- Motani, R., Rothschild, B.M., and Wahl, W., Jr. 1999. Large eyeballs in diving ichthyosaurs. *Nature* 402: 747.
- Nielsen-Marsh, C.M. and Hedges, R.E. 2000. Patterns of diagenesis in bone I: The effects of site environments. *Journal of Archaeological Science* 27: 1139–1150.
- Ogden, J.A., Rhodin, A., Conlogue, G.J., and Light, T.R. 1981. Pathobiology of septic arthritis contiguous osteomyelitis in a leatherback turtle (*Dermochelys coriacea*). *Journal of Wildlife Diseases* 17: 277–287.
- Pauley, P. 1965. Decompression sickness following repeated breath-hold dives. *Journal of Applied Physiology* 20: 1028–1031.
- Raidal, S.R., Shearer, P.L., and Prince, R. 2006. Chronic shoulder osteoarthritis in a loggerhead turtle (*Caretta caretta*). *Australian Veterinary Journal* 84: 231–234.
- Ratcliffe, J.F. 1985. Anatomic basis for the pathogenesis and radiologic features of vertebral osteomyelitis and its differentiation from childhood discitis: A microarteriographic investigation. *Acta Radiologica* 26: 137–143.
- Reisz, R.R. and Head, J.J. 2008. Palaeontology: Turtle origins out to sea. *Nature* 456: 450–451.
- Resnick, D. 2002. *Diagnosis of Bone and Joint Disorders*. 4944 pp. Saunders, Philadelphia.
- Rhodin, A.G., Anders, G.J., Russell, A., and Mittermeier, R.A. 1990. *Acanthochelys macrocephala*. *Catalogue of American Amphibians and Reptiles* 481: 1–2.
- Rothschild, B.M. 1982. *Rheumatology: A Primary Care Approach*. 416 pp. Yorke Medical Press, New York.
- Rothschild, B.M. 1987. Decompression syndrome in fossil marine turtles. *Annals of the Carnegie Museum* 56: 253–358.
- Rothschild, B.M. 1988. Avascular necrosis in diving vertebrates: The turtle test. *Journal of Vertebrate Paleontology* 8 (Supplement to 3): 25A.
- Rothschild, B.M. 1990. Absence of decompression syndrome in recent and fossil Mammalia and Reptilia. *Annals of the Carnegie Museum* 59: 287–293.
- Rothschild, B.M. 1991. Stratophenetic analysis of avascular necrosis in turtles: Affirmation of the decompression syndrome hypothesis. *Comparative Biochemistry and Physiology* 100A: 529–535.
- Rothschild, B.M. 2010. Macroscopic recognition of non-traumatic osseous pathology in the post-cranial skeletons of crocodylians and lizards. *Journal of Herpetology* 44: 13–20.
- Rothschild, B.M. and Martin, L.D. 1987. Avascular necrosis: Occurrence in diving Cretaceous mosasaurs. *Science* 236: 75–77.
- Rothschild, B.M. and Martin, L.D. 2006. *Skeletal Impact of Disease*. 226 pp. New Mexico Museum of Natural History, Albuquerque.
- Rothschild, B.M. and Woods, R.J. 1991. Spondyloarthropathy: Erosive arthritis in representative defleshed bones. *American Journal of Physical Anthropology* 85: 125–134.
- Rothschild, B.M., Schultze, H.-P., and Pellegrini, R. 2012a. *Macroscopic Osteopathology: Bibliography of Amphibian and Reptile Pathology*. 450 pp. Springer, New York.
- Rothschild, B.M., Schultze, H.-P., and Pellegrini, R. 2013. Osseous and other hard tissue pathologies in turtles. In: D. Brinkman, J. Gardner, and P. Holroyd (eds.), *Morphology and Evolution of Turtles*, 501–534. Springer, New York.
- Rothschild, B.M., Xiaoting, Z., and Martin, L.D. 2012b. Adaptations for marine habitat and the effect of Triassic and Jurassic predator pressure on development of decompression syndrome in ichthyosaurs. *Naturwissenschaften* 299: 443–448.
- Scott, R., Marsh, R., and Hays, G.C. 2012. A little movement oriented to the geomagnetic field makes a big difference in strong flows. *Marine Biology* 159: 481–488.
- Shaibani, A., Workman, R., and Rothschild, B. 1993. The significance of enthesitis as a skeletal phenomenon. *Clinical and Experimental Rheumatology* 11: 399–403.
- Smith, H.M. and Nickon, D.C. 1961. Preliminary experiments on the role of the cloacal bursae in hibernating turtles. *Natural History Miscellanea of the Chicago Academy of Sciences* 178: 1–8.
- Sternberg, C.H. 1909. *The Life of a Fossil Hunter*. 286 pp. Henry Holt and Company, New York.
- Strauss, M.B. 1970. Physiological aspects of mammalian breath-hold diving: A review. *Aerospace Medicine* 41: 1362–1381.
- Strauss, M.B. and Sampson, R.L. 1986. Decompression syndrome: An update. *Physician and Sports Medicine* 14 (3): 1–9.
- Ultsch, G.R. 1985. The viability of Nearctic freshwater turtles submerged in anoxia and normoxia at 3 and 10°C. *Comparative Biochemistry and Physiology* 81A: 607–611.
- Ultsch, G.R. and Jackson, D.C. 1982. Long-term submersion at 3°C of the turtle *Chrysemys picta bellii*, in normoxic and severely hypoxic water. I. Survival, gas exchange and acid-base status. *Journal of Experimental Biology* 96: 11–28.