

ANTHRAX IN CAPTIVE CARNIVORES IN IBADAN, NIGERIA

Authors: IKEDE, B. O., FALADE, S., and GOLDING, R. R.

Source: Journal of Wildlife Diseases, 12(2) : 130-132

Published By: Wildlife Disease Association

URL: <https://doi.org/10.7589/0090-3558-12.2.130>

BioOne Complete (complete.BioOne.org) is a full-text database of 200 subscribed and open-access titles in the biological, ecological, and environmental sciences published by nonprofit societies, associations, museums, institutions, and presses.

Your use of this PDF, the BioOne Complete website, and all posted and associated content indicates your acceptance of BioOne's Terms of Use, available at www.bioone.org/terms-of-use.

Usage of BioOne Complete content is strictly limited to personal, educational, and non - commercial use. Commercial inquiries or rights and permissions requests should be directed to the individual publisher as copyright holder.

BioOne sees sustainable scholarly publishing as an inherently collaborative enterprise connecting authors, nonprofit publishers, academic institutions, research libraries, and research funders in the common goal of maximizing access to critical research.

ANTHRAX IN CAPTIVE CARNIVORES IN IBADAN, NIGERIA

B. O. IKEDE, S. FALADE and R. R. GOLDING, Department of Veterinary Pathology and The Zoological Garden, University of Ibadan, Ibadan, Nigeria.

Abstract: Between 20 and 22 June 1974, three captive carnivores (two genets, *Genetta* sp. and one caracal, *Felis caracal*) died suddenly in the University of Ibadan Zoological Garden without previous signs of illness. *Bacillus anthracis* was isolated from their blood and tissues. The organism was highly pathogenic to laboratory animals. The disease was believed to have been contracted from meat fed the animals.

INTRODUCTION

Anthrax is enzootic in many parts of Africa where it chiefly affects livestock. There are also reports of the disease in wild animals in southern and eastern Africa, as well as in animals kept at zoological gardens and menageries in many parts of the world.^{1,2} Infection of wild or captive animals can usually be traced to the ingestion of contaminated food and water although insects may play a role in dissemination.^{2,3} In captive carnivores the disease may occur in two forms, a peracute form in which the animal dies without premonitory signs, and an acute form characterized by anorexia, dullness, dyspnoea, prostration and inflammation of the lips and tongue before death.¹ Diagnosis of anthrax in wild animals, as in livestock, is based on the microscopical and bacteriological examination of material from cadavers.

The cases reported in this communication resulted in the death of two genets (*Genetta* sp) and one caracal (*Felis caracal*) kept at the University of Ibadan Zoological Garden, a collection including carnivorous, omnivorous and herbivorous mammals, birds and reptiles. Carnivores are fed raw goat meat; goats are purchased from a local market and kept in isolation in the zoo for 1-5 days before slaughter. They are also fed raw beef purchased regularly from a single source.

CASE HISTORY

In the afternoon of 20 June 1974, an adult male genet was found dead with frothy fluid oozing from the mouth and

nostrils. Poisoning was strongly suspected, particularly as the animal appeared normal at 10.00 hrs when last seen alive by the keeper. The genet had been in the cage with another adult male genet for several years. That afternoon, the second genet was normal; however, on 21 and 22 June respectively, the second genet and a 7-year-old female caracal kept in a nearby cage were found dead. The three animals were examined post-mortem on the 22nd, without any suspicion of anthrax, as the disease has never been reported in the area. The following observations were made at necropsy:

First genet:

The alimentary tract was virtually empty except for bile-stained frothy fluid in the stomach and bloody mucus in the upper intestine. Both kidneys were dark-red and swollen and cut surfaces revealed prominent haemorrhagic streaks; the spleen and lymph nodes showed no macroscopic lesions; the urine was normal.

Second genet:

There were moderate haemorrhages around the larynx and upper trachea. There was no food in the alimentary tract but haemorrhages were evident in the intestine and kidneys. The spleen, liver and brain were congested.

Caracal:

Severe diffuse haemorrhages were present in the lungs, epi- and endo-cardium,

kidneys and serosal surface of the stomach. The spleen was markedly enlarged and dark-red. The stomach was full of pieces of undigested beef.

Smears of blood, spleen and brain from each animal were stained with Giemsa. Portions of intestine, spleen, lymph nodes, kidney, lung, heart, brain and liver were fixed in 10% formal-saline and processed for routine histopathologic examination. Portions of the spleen and kidney and pieces of meat from the stomach were also examined bacteriologically.

MICROSCOPIC EXAMINATION

In smears of blood and spleen, numerous, straight, long, encapsulated bacilli were present in long chains suggestive of *Bacillus anthracis*. There were no spores. Haemorrhagic necrosis of the intestinal mucosa was associated with the invasion of the tips of the intestinal villi by bacilli. In the first genet, examination of spleen and lymph nodes revealed numerous mas-

ses of bacilli in the congested sinusoids. In the remaining two animals, acute necrosis of splenic corpuscles and neutrophilic infiltration of the red pulp were evident along with masses of bacteria and severe congestion (Fig. 1). In the first genet, there was severe renal tubular degeneration and acute pulmonary congestion. Bacilli were abundant in blood vessels, capillaries and in the alveolar lumen. Other organs showed haemorrhages and disseminated bacterial embolism.

BACTERIOLOGY

Specimens for bacteriologic examination were cultured on 5% human blood agar and incubated at 37 C for 24 h. There was abundant growth both from tissues and stomach contents. The colonies were irregular, dull opaque, greyish white and about 3 mm in diameter and slightly haemolytic. Staining revealed gram-positive rods in long chains with a few oval centrally-located spores. The organism was non-motile.

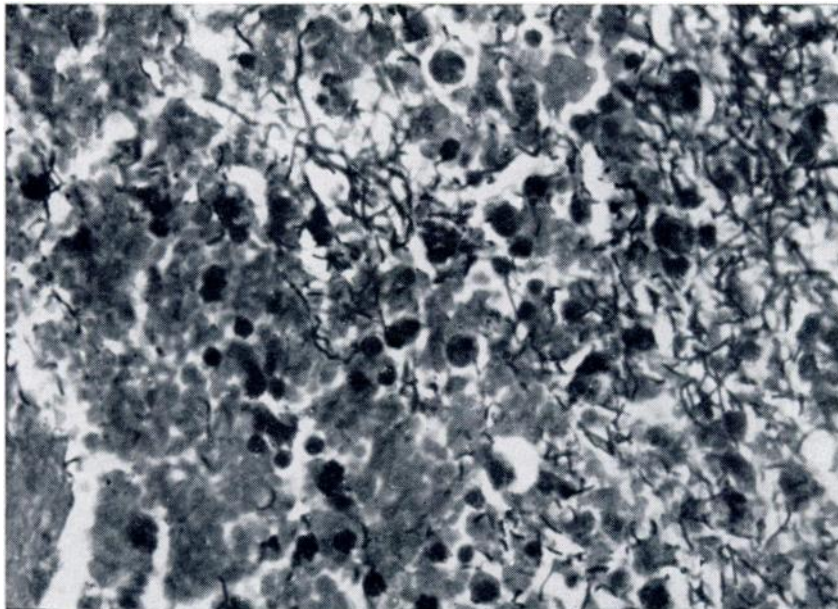


FIGURE 1: Spleen showing chains of *Bacillus anthracis* in the congested red pulp. Gram: X 1000.

PATHOGENICITY TESTS

Four guinea-pigs were inoculated, two intramuscularly and two by skin scarification, with 0.5 ml suspension of either the spleen of the caracal or the pure culture from one of the genets. Similarly four mice were inoculated using 0.2 ml suspension. All eight animals died within 24-48 h, showing a haemorrhagic gelatinous exudate at the sites of inoculation and enlarged congested spleens. Bacilli were abundant in smears of blood, spleen, liver, heart, lung and oedema fluid, and were recovered pure on blood agar, thus confirming the diagnosis of anthrax.³

DISCUSSION

The precise source of the anthrax bacilli could not be determined, but the beef fed to the animals was strongly suspected, although the goat meat could not be excluded. Anthrax bacilli were cultured from pieces of beef in the stomach of one animal but we cannot rule out contamination of the beef after ingestion or during the process of necropsy in view of the massive bacteraemia. The other two animals had acute haemorrhagic enteritis, with anthrax bacilli invading the

intestinal mucosa. This would suggest a similar oral route of infection for all three animals.

Two other caracals in the zoo, as well as the other carnivorous mammals and birds presumably fed the same meat, did not contract the disease, although anthrax bacilli were cultured from the faeces obtained from two adjacent cages, one containing the caracals and the other, two civet cats (*Viverra zibetha*). This may be due to variation in individual or species susceptibility or differences in the amount of infected material that was ingested. This may also explain why the three animals died over a 3-day period.

Soon after the diagnosis was confirmed, the zoo and necropsy attendants were questioned. None of them had "carbuncles" or any other related illness. However, the necropsy attendants were treated prophylactically with antibiotics. The post-mortem room and the cages of the dead animals were thoroughly washed and sprayed with 5% sodium hydroxide followed by 10% formalin. The government veterinary services were notified. No other case of anthrax has since occurred in the vicinity.

LITERATURE CITED

1. CHOQUETTE, L. P. E. 1970. Anthrax. In: *Infectious Diseases of Wild Mammals*, edited by J. W. Davis *et al.* Iowa State University Press, Ames, Iowa. pp. 256-266.
2. JORDAN, W. J. 1964. An outbreak of acute disease in Chester Zoo diagnosed as anthrax. *Vet. Rec.* 76: 927-930.
3. WILSON, G. S. and A. A. MILES, 1966. *Topley and Wilson's Principles of Bacteriology and Immunity*. Edward Arnold (Publishers) Ltd. 5th ed. vol. 2: 2079-2094.

Received for publication 30 January 1975