

MALARIA IN A CAPTIVELY-PRODUCED F1 GYRFALCON AND IN TWO F1 PEREGRINE FALCONS 1

Authors: KINGSTON, NEWTON, REMPLE, JOHN DAVID, BURNHAM, WILLIAM, STABLER, ROBERT M., and MCGHEE, R. BARCLAY

Source: Journal of Wildlife Diseases, 12(4) : 562-565

Published By: Wildlife Disease Association

URL: <https://doi.org/10.7589/0090-3558-12.4.562>

BioOne Complete (complete.BioOne.org) is a full-text database of 200 subscribed and open-access titles in the biological, ecological, and environmental sciences published by nonprofit societies, associations, museums, institutions, and presses.

Your use of this PDF, the BioOne Complete website, and all posted and associated content indicates your acceptance of BioOne's Terms of Use, available at www.bioone.org/terms-of-use.

Usage of BioOne Complete content is strictly limited to personal, educational, and non-commercial use. Commercial inquiries or rights and permissions requests should be directed to the individual publisher as copyright holder.

BioOne sees sustainable scholarly publishing as an inherently collaborative enterprise connecting authors, nonprofit publishers, academic institutions, research libraries, and research funders in the common goal of maximizing access to critical research.

MALARIA IN A CAPTIVELY-PRODUCED F₁ GYRFALCON AND IN TWO F₁ PEREGRINE FALCONS^[1]

NEWTON KINGSTON,^[2] JOHN DAVID REMPLE,^[3] WILLIAM BURNHAM,^[4]

ROBERT M. STABLER^[5] and R. BARCLAY MCGHEE^[6]

Abstract: One *Falco rusticolus* and two of 24 *Falco peregrinus* were positive for *Plasmodium relictum*. Sixteen percent of the erythrocytes (RBC) of the gyrfalcon were parasitized. Following treatment with chloroquine the parasite burden was dramatically reduced (to less than 0.01%). Infection in peregrine falcons was low (0.01-0.4% RBCs were parasitized). This is the second report of *Plasmodium* in the gyrfalcon and the first report in the peregrine falcon.

INTRODUCTION

The peregrine falcon, *Falco peregrinus*, is an endangered species in North America. Cornell University's Peregrine Fund in attempting to re-establish viable breeding populations of this species maintains two facilities, one near Ithaca, New York, and the other near Fort Collins, Colorado. The eastern project concentrates its propagation efforts towards the goal of providing birds for the reintroduction of the eastern United States peregrine falcon. The Colorado project produces birds to stabilize and increase the dwindling remnant western peregrine falcon population. Gyrfalcons, *Falco rusticolus*, while not endangered, also have been reared to assist in developing captive breeding methodology. Forty-eight peregrine falcons and five gyrfalcons were produced in 1974-75. This report is concerned with birds held at the Colorado facility.

The birds occupy 2-story breeding chambers essentially open to the exterior on one face. Daily observations are made of each falcon held in the project, and

occasionally a bird may be exercised as in falconry. In mid-September, 1975, a loss of stamina and a developing listlessness was noted in a female gyrfalcon that was being exercised. The gyrfalcon was one of three produced in captivity in 1975 at the New York location and moved to the Colorado project at 10 days of age.

CASE REPORT

The gyrfalcon was clinically examined on 19 September using a number of diagnostic procedures. Throat cultures were taken for bacteria, fungi and pathogenic trichomonads. Fecal cultures were taken for bacteria and fungi. A fecal flotation examination was performed for parasite identification. Throat cultures revealed a non-pathogenic *Staphylococcus* sp. to be the predominating organism. A non-haemolytic *Streptococcus* sp. and an unidentified gram negative rod also were recovered. Only coliforms were recovered from the fecal swab. All cultures were negative for fungi. Several colonies of

[1] Publication approved by Director, Agriculture Experiment Station, College of Agriculture, University of Wyoming, Laramie, Wyoming 82071, USA as JA 797.

[2] Division of Microbiology and Veterinary Medicine, College of Agriculture, University of Wyoming, Laramie.

[3] Skyline Animal Hospital, Laramie.

[4] The Peregrine Fund, Cornell University, Ithaca, New York 14853, USA.

[5] Department of Biology, Colorado College, Colorado Springs, Colorado 80903, USA.

[6] Department of Zoology, University of Georgia, Athens, Georgia 30601, USA.

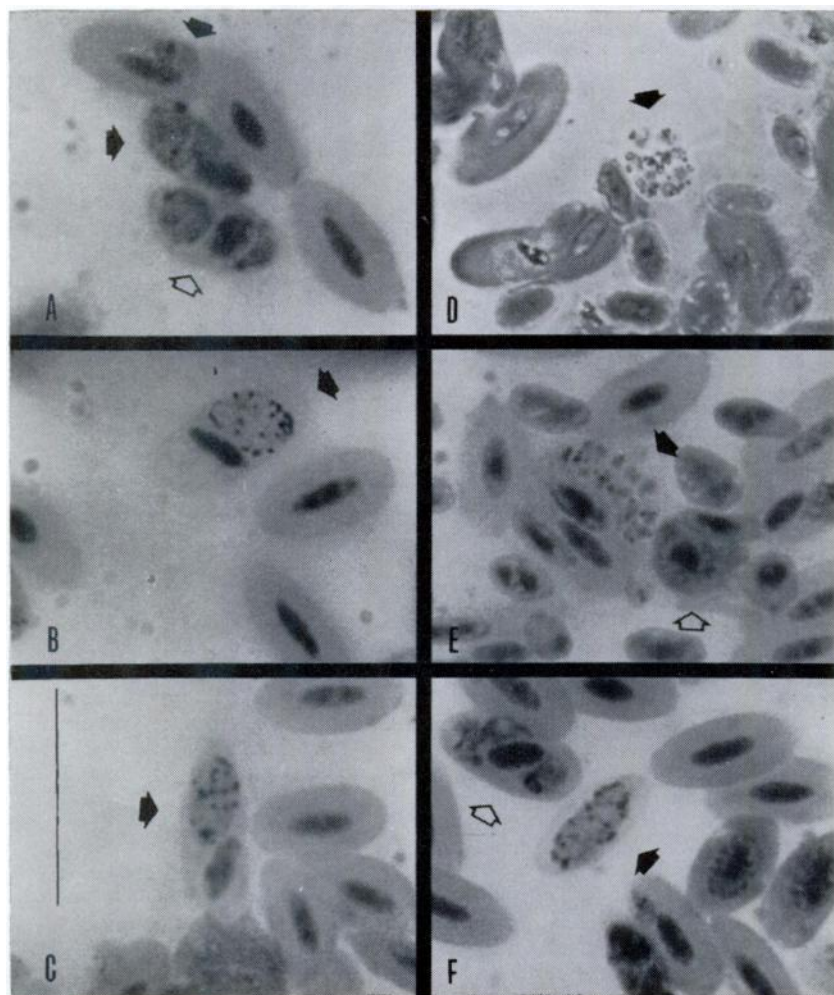
what appeared to be ordinary yeast without encapsulation, hyphae, or pseudo-hyphae were recovered from the fecal culture. Fecal parasite examination was negative. Two microhematocrit tubes of blood were collected from the left superficial brachial vein, which, upon examination, yielded a packed cell volume of 37%. Range of PCV for five apparently healthy peregrine falcons was 45-50%. A Giemsa-stained thin blood film revealed parasitized red blood cells (RBCs) containing pigmented schizonts with up to 14 merozoites (Fig. 1 D,E); rounded, terminal, pigmented gametocytes (Fig. 1 B,C); and small to older trophozoites with some multiple infected RBCs (Fig. 1 A,F). Often the host cell nucleus (HCN) was displaced (Fig. 1 B,C) but only rarely were RBCs enucleated (Fig. 1F). Pigment granules were rounded and numerous (Fig. 1 B,C,F) and appeared yellow to dark brown in color. Free merozoites were seen extracellularly. Approximately 16% of the RBCs were infected; a further 12-14% of the RBCs were immature, dark-staining, haemoglobin-poor cells with enlarged nuclei (erythroblasts) (Fig. 1 C,E,F). The functional O_2 -transport capacity of the bird was thus impaired possibly by as much as one-third. The parasite was identified as *Plasmodium* (*Haemamoeba*) *relictum* (Grassi and Feletti, 1891), a virulent species of avian malaria common to passerine birds.²

On 20 September oral treatment with chloroquine phosphate (7-chloro-4-((4 (diethylamino) -1- methylbutyl) amino) quinoline phosphate was initiated.⁷ A total dose of 25 mg of Aralen base (300 mg base-500 mg tablet) per kg of body weight was administered over a three day schedule. An initial dose of 10 mg base per kg body weight was given in an oral aqueous suspension. The second dose of 5 mg base per kg body weight was administered 6 hr after the first dose. The third dose of 5 mg base per kg body weight was administered 18 hr after the second dose. The fourth and final dose of 5 mg base per kg body weight was given 24 hr after the third dose.

Clinical improvement in the bird's condition was apparent 24 hr following treatment. Examination of blood films from the clinically recovered bird on 24 September revealed a dramatic decrease in the number of parasitized RBCs (down to 0.08%). Mostly gametocytes were seen at this time as gametocytes are little affected and tissue stages (exoerythrocytic schizonts) are unaffected by chloroquin.⁴ Blood films made on 1 October revealed a further drop in parasitized RBCs (down to 0.03%); some of these infected cells showed young ring stages which were probably the result of small numbers of new parasites being released from exoerythrocytic tissue multiplication. Blood films made on 23 October apparently were free of parasites.

As a result of detecting the *Plasmodium* infection in the gyrfalcon, we felt it imperative to examine the other falcons in the breeding program. Thin blood films of 12 peregrine falcons produced in captivity were prepared on 24 September and two of the birds (a 1974 hatched, mature female *Falco peregrinus tundrius*; and a 1975 hatched immature male *F. p. anatum*) were positive for *Plasmodium relictum* in low numbers (0.01% parasitized RBCs in each bird). The other 10 birds were apparently negative or the parasitemia was at a sufficiently low level that oil-immersion examination of two slides from each bird for from 10 to 15 min each did not reveal parasitized RBCs. Subsequent examination of these two positive birds on 1 October showed an increased parasitemia in the *tundrius* bird (to 0.4%) while that of the *anatum* bird remained stable. Blood film examination of these two birds on 23 October revealed no evident parasitemia. Thin blood films from an additional 12 peregrine falcons not previously examined were considered to be negative for infection with *Plasmodium*. No treatment was given the infected peregrine falcons owing to the low level of infection.

⁷ Aralen, ® Winthrop Laboratories, 90 Park Avenue, N.Y. 10016, USA.



A. Three RBCs infected with *Plasmodium relictum* (arrows); one (light arrow) with double infection. Dark object in cell is HCN which is displaced from central position; compare with uninfected cells.

B. Rounded, male gametocyte (arrow) in terminal position in RBC with partially displaced HCN. Dark granules are pigment granules, mostly peripheral.

C. Rounded, terminal, female gametocyte (arrow) with markedly displaced HCN, pigment granules not primarily peripheral.

D. Rounded, not completely mature segmenter (schizont) with 10-11 merozoites (arrow); when mature these break out of parasitized cell and invade other RBCs.

E. Fully developed, elongate segmenter with 14-15 merozoites (dark arrow); evident is a dark-staining, haemoglobin-poor erythroblast (light arrow).

F. Gametocyte in anucleate RBC (dark arrow), host cell just above has a double infection (light arrow).

A-C, E, F light microscopy; D phase-contrast microscopy.

Scale = 20 μ m

Plasmodium was first reported from falcons in this hemisphere in an American kestrel (*Falco sparverius*)³ and was later identified as *P. relictum*. In 1956, a dead gyrfalcon from the Colville River region of Alaska examined by Dr. Morgan Berthrong, Penrose Hospital, Colorado Springs, Colorado¹ was found to have died of a fulminating malaria which was later diagnosed as *P. relictum* by Dr.

Reginald D. Manwell, Syracuse University, Syracuse, New York.

This is the second report of *Plasmodium* in the gyrfalcon, the first in peregrine falcons; it is to be hoped that this report will alert those who are concerned with the care and management of these birds to the dangers presented by this parasite.

Acknowledgments

We thank Dr. Tom Thorne, Wyoming Game and Fish Department Research Veterinarian; Dr. Kenneth L. Diem, Department of Zoology, College of Arts and Sciences; and Dr. E. Lee Belden, Division of Microbiology and Veterinary Medicine, University of Wyoming for their critical reading of the manuscript.

LITERATURE CITED

1. BEEBE, F. L. and H. M. WEBSTER. 1964. In *North American Falconry and Hunting Hawks*. North American Falconry and Hunting Hawks Press. p. 283.
2. GARNHAM, P. C. C. 1966. *Malaria parasites and other haemosporidia*. Blackwell Scientific Publishers, Oxford. 3-1114.
3. STABLER, R. M. and R. J. DATEL. 1959. First record of malaria in American Falcons (*Falco sparverius*). *J. Colo.-Wyo. Acad. Sci.* 4: 59.
4. STECK, E. A. 1971. The chemotherapy of protozoan diseases. Division of Medicinal Chemistry, Walter Reed Army Institute of Research, Washington, III.4/5 23: 211.

Received for publication 7 April 1976