



## BESNOITIOSIS IN A WOODLAND CARIBOU

Author: WOBESER, G.

Source: Journal of Wildlife Diseases, 12(4) : 566-571

Published By: Wildlife Disease Association

URL: <https://doi.org/10.7589/0090-3558-12.4.566>

---

BioOne Complete ([complete.BioOne.org](https://complete.BioOne.org)) is a full-text database of 200 subscribed and open-access titles in the biological, ecological, and environmental sciences published by nonprofit societies, associations, museums, institutions, and presses.

Your use of this PDF, the BioOne Complete website, and all posted and associated content indicates your acceptance of BioOne's Terms of Use, available at [www.bioone.org/terms-of-use](https://www.bioone.org/terms-of-use).

Usage of BioOne Complete content is strictly limited to personal, educational, and non - commercial use. Commercial inquiries or rights and permissions requests should be directed to the individual publisher as copyright holder.

---

BioOne sees sustainable scholarly publishing as an inherently collaborative enterprise connecting authors, nonprofit publishers, academic institutions, research libraries, and research funders in the common goal of maximizing access to critical research.

## BESNOITIOSIS IN A WOODLAND CARIBOU

G. WOBESER, Department of Veterinary Pathology, Western College of Veterinary Medicine, University of Saskatchewan, Saskatoon, Saskatchewan, S7N 0W0

**Abstract:** Besnoitiosis was diagnosed in an adult male woodland caribou found dead in northern Saskatchewan. The lesions present were comparable to those of chronic besnoitiosis in cattle, and were much more severe than those previously described in domestic reindeer and barren-ground caribou.

### INTRODUCTION

The disease "Besnoitiosis" due to infection with the protozoan parasite *Besnoitia besnoiti* is an economically important disease of cattle in certain areas of Africa, Europe and Israel.<sup>19,6,15</sup> Natural infection with *Besnoitia* organisms also has been reported in domestic goats,<sup>12</sup> horses and burros,<sup>19,20,22</sup> various species of African antelope,<sup>3</sup> reindeer and barren-ground caribou<sup>11,9</sup> opossums,<sup>21,10</sup> lizards,<sup>18</sup> and rodents.<sup>9,10</sup> The purpose of this report is to describe a case of besnoitiosis in a woodland caribou found dead in northern Saskatchewan.

### CASE HISTORY AND METHODS

In January, 1976, an adult male woodland caribou was found dead by commercial fishermen on Acheninni Lake about 75 km west of the town of Creighton, Saskatchewan. The animal was described as being in poor body condition with "scabs and sores all over its body and head". There was no evidence of traumatic injury. Because of difficulty in moving the entire frozen carcass from the bush the head was removed and submitted to the Department of Veterinary Pathology for examination.

After the head was thawed portions of skin and exudate from the affected areas of skin were examined grossly and micro-

scopically for ectoparasites and microbial agents. Portions of skin and hair were cultured for bacteria, dermatophytes and special techniques were used for possible isolation of *Dermatophilus congolensis*.<sup>7</sup>

Portions of skin and underlying tissue, nasal and pharyngeal mucosa, tongue, lymph node, eye, brain, pituitary and superficial vessels were fixed in 10% buffered formalin, processed routinely for histopathology and stained with hematoxylin-eosin (H&E).

### Gross Pathologic Findings

There was bilateral alopecia about the muzzle and nose, on the ventral aspect of the mandible and about the eyes (Fig. 1). The skin in these areas was grey in color and markedly thickened and folded, particularly over the bridge of the nose. Scaly to moist exudate was evident on the surface in some areas. When the thickened skin was reflected numerous 0.5 mm clear cyst-like structures were evident in the subcuticular fascia. The mucosa of the external nares was granular in texture and large plugs of fibrinopurulent exudate were present in the anterior nasal cavity and covering portions of the turbinates. The mucosa of the turbinates was deep red in color and granular in texture as was that of the nasopharynx (Fig. 2).

□ Domesticated reindeer, barren-ground caribou and woodland caribou are all considered to be of one species (*Rangifer tarandus*) but barren-ground and woodland caribou are of different subspecies, *R. t. groenlandicus* and *R. t. caribou*, respectively.<sup>1</sup>

When the mucosa was stripped from the turbinates the underlying bone was pitted with numerous 0.5-1.0 mm cavities which appeared to have enclosed cysts located in the periosteum or mucosa. Numerous 0.5 mm cysts were found bulging into the lumen of major veins of the head, and similar cysts were evident on the conjunctiva and sclera of both eyes. The suprapharyngeal lymph nodes were edematous and had a yellowish discoloration on section. No gross lesions were detected in the oral cavity or brain.

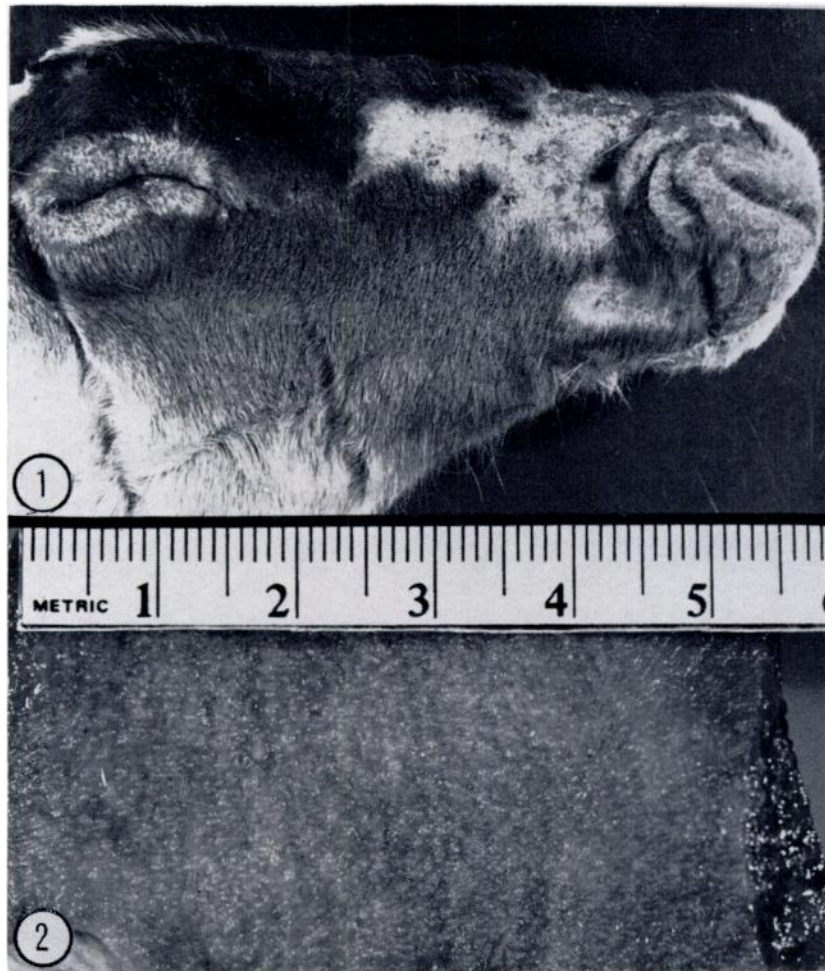

FIGURE 1. Lateral view of head of woodland caribou. Alopecia over nose and about eye, with thickening and folding of skin about nares.

FIGURE 2. Nasopharyngeal mucosa showing granularity due to massive numbers of *Besnoitia* cysts.

### Histopathologic Findings

The most striking feature on histopathologic examination was the occurrence of large numbers of mature *Besnoitia* cysts in nearly all structures examined.

In sections of skin and subcuticular tissues the cysts were most concentrated in the dermis (Fig. 3); however, individual cysts could be found in the epidermis, subcuticular fascia and underlying muscle. There was little or no inflammatory reaction except for occasional collections of mononuclear cells in association with apparently degenerating cysts. The cysts were spherical or oval in outline and 200-400  $\mu\text{m}$  in diameter. The outer layer was eosinophilic and somewhat birefringent with polarized light. Host cell nuclei and cytoplasm were compressed about the mass of merozoites (Fig. 4). Many of the cysts were distorted, probably as an artefact of freezing and fixation. In some areas of the skin, numerous gram-positive cocci were present in the superficial exudate, and occasionally small discrete granulomatous lesions were found deep in the dermis. These granulomata surrounded well-developed bacterial colonies. The colonies were found to contain gram-positive cocci similar to those present in the superficial exudate and remnants of hair shafts were present in some granulomata. These granulomata likely represented inflammatory response to traumatically implanted hair and bacteria.

Large numbers of mature *Besnoitia* cysts were present in the nasal mucosa, and there was a rather diffuse exudative rhinitis present with fibrin and inflammatory debris adherent to the mucosa. *Besnoitia* cysts were found lying just beneath the intima of many large veins (Fig. 5), within the sclera, ciliary process and iris of the eye (Fig. 6) and in the *pars intermedia* and *pars anterior* of the pituitary. A few cysts were present in the subcapsular sinuses of the supra-pharyngeal lymph node, and the medulla of this node contained large numbers of macrophages laden with yellow-brown pigment. In addition to the *Besnoitia* cysts, numerous cysts of *Sarcocystis* also were present in the skeletal muscle.

### Microbiologic Findings

No significant bacterial or fungal agents were isolated from the portions of skin cultured. The nasal exudate yielded a mixed culture of *Staphylococcus aureus*, *Escherichia coli*, *Klebsiella pneumoniae* and *Streptococci*.

### DISCUSSION

The gross and histopathologic lesions in this caribou are comparable to those described in the "sclerodermatous" or chronic form of besnoitiosis of cattle<sup>10, 17, 14, 2</sup> and appear to be much more severe than those previously described in reindeer or caribou.

Hadwen<sup>11</sup> reported that *Besnoitia tarandi* (Hadwen, 1922)<sup>12</sup> caused the condition "corn-meal disease" in domestic reindeer. The disease received its name because of the gritty texture of fibrous connective tissue, particularly the periosteum and on tendons. Hadwen<sup>11</sup> described "pitting" of bones in association with the presence of parasites in the periosteum, but did not describe skin, ocular or nasal lesions, and felt that the main affect of the parasites would be mechanical.

Choquette *et al.*<sup>9</sup> and Broughton and Choquette<sup>5</sup> have reported skin lesions due to *Besnoitia* infection in barren-ground caribou from the Northwest Territories and Manitoba but did not report bone, nasal or intra-vascular lesions in these animals. The animals were all in good body condition.<sup>5, 8</sup>

Bovine besnoitiosis may result in sub-clinical infection or varying degrees of clinical disease. Severe cases, showing the full range of lesions occur relatively infrequently.<sup>17</sup> This same range of clinical expression would appear to occur in caribou. One of the most important aspects of bovine besnoitiosis is that bulls which survive infection become either temporarily or permanently sterile<sup>17, 19</sup> and the same sequelae have been reported in experimentally-infected sheep and goats.<sup>17</sup> Broughton and Choquette<sup>5</sup> did not find any involvement of the male genitalia in barren-ground caribou.

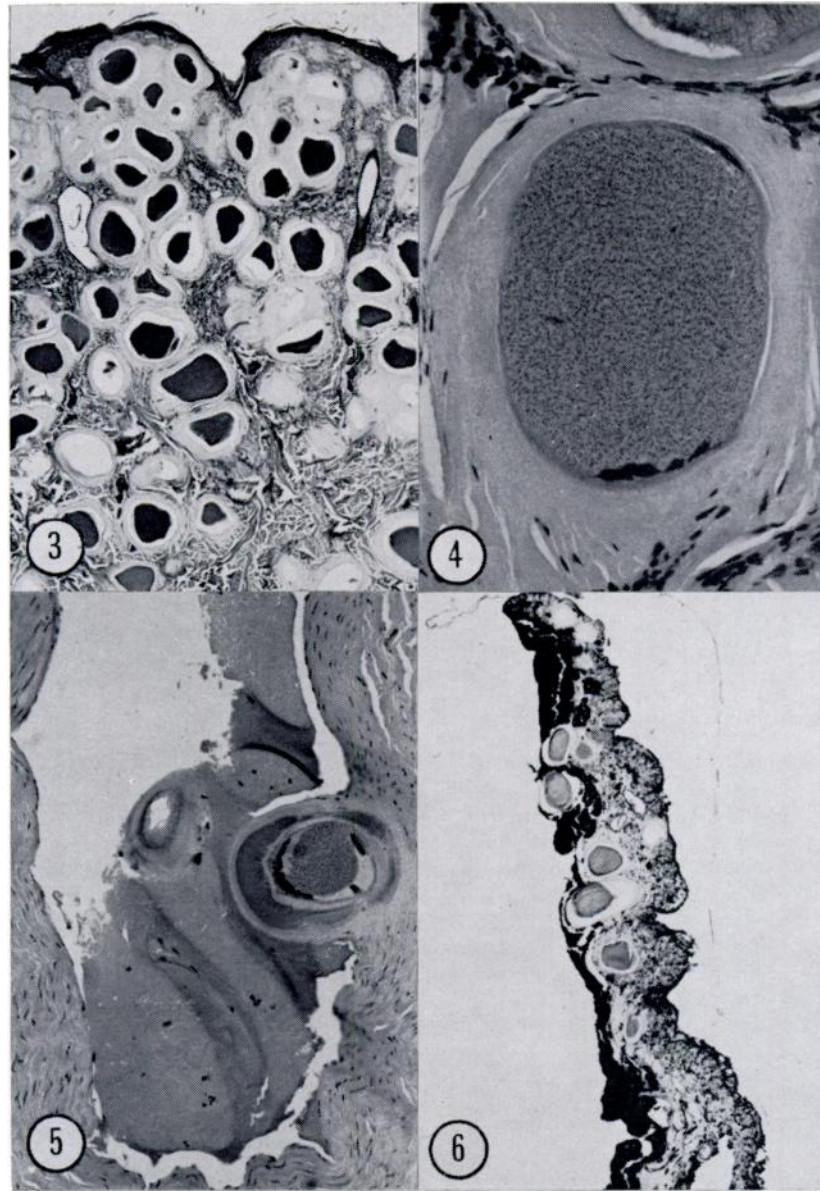


FIGURE 3. Skin, numerous mature *Besnoitia* cysts in dermis and subcuticular tissue with little inflammatory response. H&E x 45

FIGURE 4. Mature *Besnoitia* cyst, note thick collagenous outer layer, flattened host cell nuclei and numerous merozoites. H&E x 280

FIGURE 5. *Besnoitia* cyst beneath intima of large vein. H&E x 112

FIGURE 6. *Besnoitia* cysts in the iris of the eye. H&E x 40

The identity of various *Besnoitia* species is largely based upon the host animals from which they have been recovered. *Besnoitia* from cattle and various African antelope are considered to be of a single species, *B. besnoiti*,<sup>2</sup> but strains from antelope are of low pathogenicity for cattle.<sup>4</sup> *Besnoitia jellisoni* from rodents is serologically distinct from *B. besnoiti*, but protects against challenge with *B. darlingsi* isolated from lizards and opossums.<sup>10</sup> *Besnoitia tarandi* has not been compared serologically with any of the other species, nor has this agent been cultured in experimental animals. Attempts to infect rabbits with cyst material using the methods of Bigalke *et al.*<sup>4</sup> and to orally infect dogs with material from the present case were unsuccessful, probably because the material had been frozen prior to submission.

The mode of transmission of besnoitiosis is still unclear, but Peteshev *et al.*<sup>16</sup> have reported sexual sporogony and oocyst formation in cats (*Felis libyca*) fed *B. besnoiti* material of bovine origin. This would suggest that *Besnoitia* has a life-cycle similar to the closely related genera *Toxoplasma* and *Sarcocystis*.

The cause of death of the present animal could not be determined from the tissues available for examination. Cattle which survive the acute and subacute stages of the disease usually do not die directly from the disease; however, the skin lesions in the chronic form tend to persist<sup>17</sup> and alopecia over large areas of the body is undoubtedly of greater significance for a caribou in a northern Canadian winter, than for a bovine in a Mediterranean or central African climate.

#### Acknowledgements

Murdock Carriere, Department of Northern Saskatchewan is thanked for submission of the specimen and for providing additional information about the case.

#### LITERATURE CITED

1. BANFIELD, A. W. F. 1961. A revision of the reindeer and caribou, genus *Rangifer*. Nat. Mus. Can. Bull. 177 (Biol. Sci. No. 66). 137 p.
2. BASSON, P. A., R. M. McCULLY and R. D. BIGALKE. 1970. Observations on the pathogenesis of bovine and antelope strains of *Besnoitia besnoiti* (Marotel, 1912) infection in cattle and rabbits. Onderstepoort J. vet. Res. 37: 105-126.
3. BASSON, P. A., J. W. VAN NIEKERK, R. M. McCULLY and R. D. BIGALKE. 1965. Besnoitiosis in South African antelopes: a preliminary note on the occurrence of *Besnoitia* cysts in the cardiovascular system. J. S. Afr. vet. med. Ass. 36: 578.
4. BIGALKE, R. D., J. W. VAN NIEKERK, P. A. BASSON and R. M. McCULLY. 1967. Studies on the relationship between *Besnoitia* of blue wildebeest and impala, and *Besnoitia besnoiti* of cattle. Onderstepoort J. vet. Res. 34: 7-28.
5. BROUGHTON, E. and L. P. E. CHOQUETTE. 1969. Additional information and comments on disease conditions and parasites of barren-ground caribou. Trans. 33rd Fed. Prov. Wildl. Conf.: 30-39.
6. BUCHEV, K. N., I. L. UVALIEV, K. S. OMAROV, N. N. GIEBOVA, G. I. LOPATNIKOV and N. G. SAMOILOV. 1964. *Besnoitia* infection of cattle in the pre-Balklash area (of Kazakhstan). Veterinariya, Mosco. 41: 59. (Abst. No. 4475, Vet. Bull. 34 (12): 1964).
7. CARTER, G. R. 1973. *Diagnostic procedures in Veterinary microbiology*. 2nd ed. Charles C. Thomas, Springfield, Illinois. 362 p.

8. CHOQUETTE, L. P. E., E. BROUGHTON, F. L. MILLER, H. C. GIBBS and J. G. COUSINEAU. 1967. Besnoitiosis in barren-ground caribou in northern Canada. *Can. vet. J.* 8: 282-287.
9. FRENKEL, J. K. 1953. Infections with organisms resembling *Toxoplasma*, together with the description of a new organism *Besnoitia jellisoni*. *Atti. del VI Cong. Int. Microbiol.* 5: 426-434.
10. ———. 1973. Toxoplasmosis: Parasite life cycle, pathology and immunology. p. 343-410. In: *The Coccidia*. [ed.] D. M. Hammond. University Park Press. Baltimore.
11. HADWEN, S. 1922. Cyst-forming protozoa in reindeer and caribou, and a sarcosporidian parasite of the seal (*Phoca richardi*). *J. Am. vet. med. Ass.* 61: 374-382.
12. KALINER, G. 1973. Vorkommen von Besnoitienzysten in der Ziegenlunge. *Berl. Munch. Tierarztl. Wschr.* 86, 5: 229-230.
13. LEVINE, N. D. 1961. *Protozoan parasites of domestic animals and of man*. Burgess Publishing Co., Minneapolis. pp. 337-341.
14. McCULLY, R. M., P. A. BASSON, J. W. VAN NIEKERK and R. D. BIGALKE. 1966. Observations on *Besnoitia* cysts in the cardiovascular system of some wild antelopes and domestic cattle. *Onderstepoort J. vet. Res.* 33: 245-276.
15. NEUMAN, M. 1972. Serological survey of *Besnoitia besnoiti* (Marotel, 1912) infection in Israel by immunofluorescence. *Zbl. Vet. Med. B.* 19: 391-396.
16. PETESHEV, V. M., I. G. GALUZO, A. P. POLOMOSHNOV. 1974. Koshki-definitivnye khozyaeva besnoitii. *Investiya Akademii Nauk Kazakskoi SSR, Seria Biologicheskaya* (1974) 1: 33-38.
17. POLS, J. W. 1960. Studies on bovine besnoitiosis with special reference to the aetiology. *Onderstepoort J. vet. Res.* 28: 265-356.
18. SCHNEIDER, C. R. 1965. *Besnoitia panamensis*, sp. n. (Protozoa: Toxoplasmatidae) from Panamanian lizards. *J. Parasit.* 61: 340-344.
19. SCHULTZ, K. C. A. 1961. A report on naturally acquired besnoitiosis in bovines with special reference to its pathology. *J. S. Afr. vet. med. Ass.* 31: 21-44.
20. SMITH, H. A., T. C. JONES and R. D. HUNT. 1972. *Veterinary Pathology*. pp. 698. Lea & Febiger, Philadelphia 1972.
21. STABLER, R. M. and K. WELCH. 1961. *Besnoitia* from an opossum. *J. Parasit.* 47: 576.
22. TERRELL, T. G. and J. L. STOOKEY. 1973. *Besnoitia bennetti* in two Mexican burros. *Vet. Path.* 10: 177-184.

Received for publication 7 April 1976