

SELENIUM AND WHITE MUSCLE DISEASE IN WOODCHUCKS

Authors: FLEMING, W. JAMES, HASCHEK, WANDA M., GUTENMANN, WALTER H., CASUCK, JAMES W., and LISK, DONALD J.

Source: Journal of Wildlife Diseases, 13(3) : 265-268

Published By: Wildlife Disease Association

URL: <https://doi.org/10.7589/0090-3558-13.3.265>

BioOne Complete (complete.BioOne.org) is a full-text database of 200 subscribed and open-access titles in the biological, ecological, and environmental sciences published by nonprofit societies, associations, museums, institutions, and presses.

Your use of this PDF, the BioOne Complete website, and all posted and associated content indicates your acceptance of BioOne's Terms of Use, available at www.bioone.org/terms-of-use.

Usage of BioOne Complete content is strictly limited to personal, educational, and non - commercial use. Commercial inquiries or rights and permissions requests should be directed to the individual publisher as copyright holder.

BioOne sees sustainable scholarly publishing as an inherently collaborative enterprise connecting authors, nonprofit publishers, academic institutions, research libraries, and research funders in the common goal of maximizing access to critical research.

SELENIUM AND WHITE MUSCLE DISEASE IN WOODCHUCKS

W. JAMES FLEMING,¹ WANDA M. HASCHKE,² WALTER H. GUTENMANN,³

JAMES W. CASLICK¹ and DONALD J. LISK³

Abstract: Gross and histologic examination of woodchucks (*Marmota monax*) trapped on farms in Central New York revealed white muscle disease (WMD). The concentration of selenium in the animal tissues, vegetation and soils in the vicinity of trapping did not consistently correlate with the presence of WMD.

INTRODUCTION

Minute amounts of selenium were first shown to be essential for preventing necrotic liver degeneration in the rat.^{5,6} Selenium is now believed necessary for prevention of white muscle disease (WMD) and other degenerative processes in animals. The soils of the Northeastern portion of the United States are generally considered to be deficient in plant-available selenium to meet the minimum requirement of this element for foraging animals.⁴ Whereas most studies of WMD in animals have dealt with livestock, its occurrence in rats, mice, birds, deer⁴ and mountain goats² has been reported. In the work reported, woodchucks (*Marmota monax*) trapped in Central New York in September, 1976, were found to have WMD. The concentrations of selenium in tissues of woodchucks and in plants and soils near the trapping sites were determined. The objective of the study was to examine possible associations between concentrations of the element in diets and tissues of woodchucks showing WMD and control animals without this lesion.

MATERIALS AND METHODS

Woodchucks were live-trapped near their burrows on each of two farms near Ithaca, New York. Live traps with an opening 25 x 30 cm and 81 cm long were used. Trapped animals were kept in the traps for several days and during this period were fed apples grown near

Ithaca. Animals were then asphyxiated using carbon dioxide, and were examined at necropsy for gross and histologic lesions of WMD. Liver was sampled for determination of selenium.

Samples of soil and vegetation were collected on 12 October 1976, for the determination of selenium. Five soil samples and representative vegetation were taken within 25 m of capture sites. The upper 12-20 cm of legumes and grasses not exceeding 45 cm in height were collected. Soil and vegetation samples were pooled for subsampling by sample type and farm. Additional woodchucks were trapped at other sites in Tompkins County and examined for WMD. Liver selenium also was determined in some of these latter animals.

Plant and liver samples were freeze-dried, ground and mixed. Soil samples were air dried and screened through a No. 10 sieve with 1.9 mm openings. Selenium concentration in soil, plant and liver was determined by the method of Olsen.³ The procedure involved wet digestion of the sample and measurement of piaszelenol resulting from reaction of selenium with 2,3-diaminonaphthalene. The limit of detection of the method was about 0.02 ppm of selenium in tissues, on a dry weight basis.

Tissues for histologic examination were fixed in 10% neutral buffered formalin, routinely prepared, sectioned at 6 μ m, and stained with hematoxylin and eosin.

¹ Department of Natural Resources.

² Department of Veterinary Pathology.

³ Pesticide Residue Laboratory, Department of Food Science, Cornell University, Ithaca, New York 14853, USA.

RESULTS

Thirteen of 24 woodchucks trapped in September, 1976, in the Ithaca area showed various degrees of WMD. Grossly, WMD was manifested by the appearance of discrete pale streaks of varying size in the musculature, especially in the forelimbs and neck (Fig. 1). The distribution of WMD in the 13 woodchucks with gross lesions were: forelimb muscles, 11; neck muscles, 5; ribcage muscles, 3; and muscles of the hindlimbs, 1. Histologically, the muscles examined showed changes in individual muscle fibers as well as areas of more diffuse involvement. Affected muscle fibers showed either swelling, loss of cross striation and hyalinization, or fragmentation and loss of sarcoplasm. An apparent increase in nuclei and minimal cellular infiltration were pre-

sent in severely affected areas. These lesions are compatible with the lesions of vitamin E/selenium responsive diseases.

Table 1 characterizes the presence and extent of WMD and the concentration of liver selenium in each of ten woodchucks. The number of woodchucks examined was too small to draw valid conclusions concerning the presence or extent of WMD as a function of the location of trapping, selenium concentration in liver, age, sex, or other factors. Table 2 gives the concentration of selenium in soil and vegetation in proximity to the location of trapping on the two farms. There was no obvious relationships between the levels of selenium in the vegetation on the farms and the presence or absence of WMD in the animals trapped there.

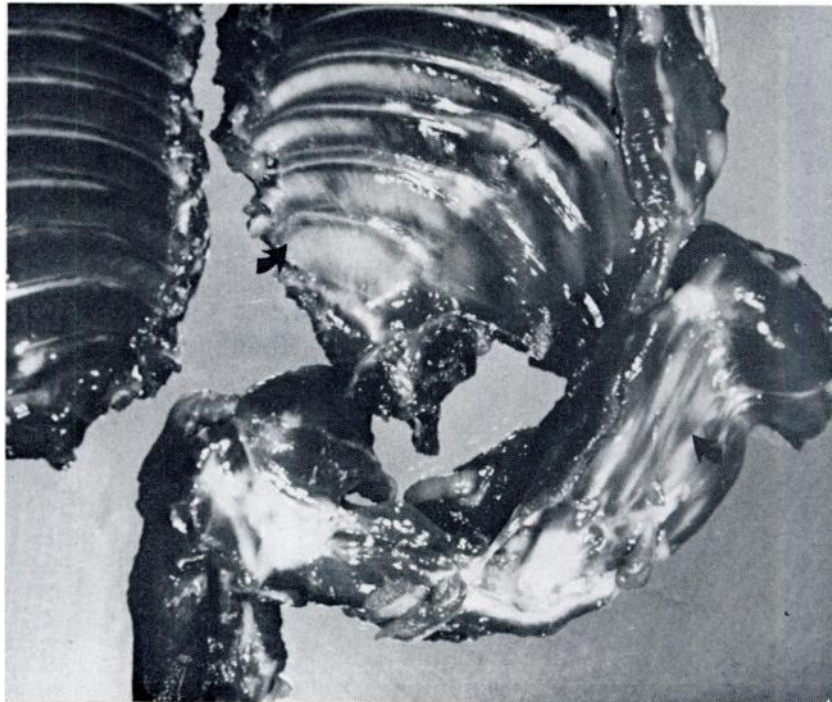


FIGURE 1. White muscle disease in the musculature of the thorax and foreleg of a woodchuck. Note the discrete pale striations (arrows) in contrast to the normal intercostal muscles (left).

TABLE 1. Selenium in livers of woodchucks live-trapped in Central New York with and without white muscle disease (WMD).

Sex	Age (years)	Woodchuck statistics		Selenium in liver ppm (dry wt.)	Distribution and extent of WMD
		Weight (grams)	Days in captivity		
					Farm #1
M	adult	2640	2	0.32	extensive WMD bilaterally in muscles of the forelimbs; also in rear legs distally
M	adult	3120	2	0.42	extensive WMD especially in intercostal muscles and forelimbs
					Farm #2
M	adult	4075	7	0.53	none
F	adult	3510	3	0.67	none
F	adult	3070	1	0.52	none
					Other Central New York Locations
M	adult	2600	16	1.06	WMD was slight on posterior-dorsal side of both forelimbs
M	adult	3490	15	0.73	none
F	adult	3540	8	0.30	extensive WMD in dorsal neck muscles and ventral muscles of forelimbs
F	juvenile	1810	6	0.31	none
M	juvenile	2600	4	0.40	WMD was pronounced in intercostal muscles but was slight in dorsal neck muscles and undersides of forelegs

* days in captivity prior to euthanasia

TABLE 2. Selenium in soils and vegetation on two farms and the occurrence of white muscle disease in woodchucks from these farms.

Farm	Total selenium ppm dry weight in:				No. of woodchucks showing WMD	
	soil	dandelion ^a	mixed legumes	timothy ^b		wild mustard ^c
#1	0.72		0.02	0.04	0.03	2/2
#2	0.38	0.05	0.03	0.04		0/3

^a *Taraxacum officinale*

^b *Phleum pratense*

^c *Brassica kaber*

DISCUSSION

The woodchuck is a burrowing rodent and normally confines its seasonal activities to an area within 50-100 m of its burrow. Its mobility thus limits the soil and plant types from which nutrition is derived. This may, in part, determine the variations in occurrence of WMD even over a small geographic area.

The failure to observe a relationship between liver selenium and WMD in woodchucks is similar to findings in other species. Allaway *et al.*¹ reported the presence and absence of WMD in lambs even though their levels of selenium were similar. There are several known factors, aside from dietary selenium, which can affect the development of WMD in animals. Elevated levels of sulfur in animal diets may antagonize the ability of selenium to prevent the disease. Vitamin E and selenium appear to be interrelated in their function of

preventing WMD. Deficient levels of vitamin E in the diet may therefore lower the efficacy of selenium in preventing the syndrome. Stress may also contribute to initiation of WMD.⁴ Capture myopathy has been described for a variety of wild species and is characterized by degeneration of skeletal muscle as has been reported here. It is possible that the stress of captivity did induce the disease in woodchucks. However, during the course of investigations by the first author, woodchucks have been kept in captivity for up to 2 years without loss of muscular function. No deaths of captive animals have been attributed to this myodegenerative process. Additionally, gross visible lesions were present in animals in captivity for only 2 days. It is also conceivable that pressures of hunting, heavy predation or high population might precipitate this disease.

LITERATURE CITED

1. ALLAWAY, W. H., D. P. MOORE, J. E. OLDFIELD and O. H. MUTH. 1966. Movement of physiological levels of selenium from soils through plants to animals. *J. Nutr.* 88: 411-418.
2. HEBERT, D. M. and I. M. COWAN. 1971. White muscle disease in the mountain goat. *J. Wildl. Manage.* 35: 752-756.
3. OLSEN, O. E. 1969. Fluorometric analysis of selenium in plants. *J. Assoc. Official Analytical Chemist.* 52: 627-634.
4. ROSENFELD, I. and O. A. BEATH. 1964. *Selenium—Geobotany, Biochemistry, Toxicity, and Nutrition*. Academic Press, New York.
5. SCHWARZ, K. 1951. Production of dietary necrotic liver degeneration using American *Torula* yeast. *Proc. Soc. Exptl. Biol. Med.* 77: 818-823.
6. ————. 1951. Production of dietary necrotic liver degeneration using American *Torula* yeast. *Proc. Soc. Exptl. Biol. Med.* 78: 852-856.

Received for publication 7 February 1977