



## **AVIAN POX INFECTION, ASPERGILLOSIS AND RENAL TREMATODIASIS IN A ROYAL TERN 1**

Authors: JACOBSON, ER, RAPHAEL, B.L., NGUYEN, H.T., GREINER, E.C., and GROSS, T.

Source: Journal of Wildlife Diseases, 16(4) : 627-631

Published By: Wildlife Disease Association

URL: <https://doi.org/10.7589/0090-3558-16.4.627>

---

BioOne Complete ([complete.BioOne.org](https://complete.BioOne.org)) is a full-text database of 200 subscribed and open-access titles in the biological, ecological, and environmental sciences published by nonprofit societies, associations, museums, institutions, and presses.

Your use of this PDF, the BioOne Complete website, and all posted and associated content indicates your acceptance of BioOne's Terms of Use, available at [www.bioone.org/terms-of-use](https://www.bioone.org/terms-of-use).

Usage of BioOne Complete content is strictly limited to personal, educational, and non - commercial use. Commercial inquiries or rights and permissions requests should be directed to the individual publisher as copyright holder.

---

BioOne sees sustainable scholarly publishing as an inherently collaborative enterprise connecting authors, nonprofit publishers, academic institutions, research libraries, and research funders in the common goal of maximizing access to critical research.

## AVIAN POX INFECTION, ASPERGILLOSIS AND RENAL TREMATODIASIS IN A ROYAL TERN<sup>□</sup>

E.R. JACOBSON, B.L. RAPHAEL, H.T. NGUYEN, E.C. GREINER and T. GROSS, College of Veterinary Medicine, University of Florida, Gainesville, Florida 32610, USA.

**Abstract:** Poxvirus infection and aspergillosis were diagnosed in a Royal tern (*Thalasseus maximus*) based on gross and microscopic lesions. This represents the first known report of avian pox in a tern. Renal trematodiasis, caused by a species of *Renicola* also is described.

### INTRODUCTION

Avian pox has been reported in at least 60 species of birds belonging to 20 different families.<sup>3</sup> Relatively few cases of pox have been documented in the Charadriiformes (shorebirds, gulls, auks, and terns) with cutaneous and diphtheritic forms of pox reported only in the common murre (*Uria aalge*).<sup>1,2</sup> Although aspergillosis has been reported in a variety of both captive and free-living avian species<sup>6</sup> there is only a single report of combined avian pox infection and aspergillosis.<sup>4</sup> This case study documents avian pox, aspergillosis and *Renicola* in a royal tern (*Thalasseus maximus*).

### CASE HISTORY

An adult male royal tern captured northeast of Jacksonville, Florida by a professional zoologist was presented for physical examination to the Veterinary Medical Teaching Hospital, University of Florida. At the time of capture (several weeks prior to examination) nodular proliferations of the skin were noted on both legs. On routine examination the bird was found to be extremely thin and dyspneic. Proliferative lesions on the legs and toe webs were consistent with pox infection. No proliferative lesions were noted about the head or within the

oral cavity. Lung washings revealed branching septate hyphae, but the bird died before therapy could be initiated. The tern was presented for postmortem evaluation.

The tern was emaciated, as evidenced by an absence of internal fat and an extreme atrophy of the musculature overlying the keel. The right lung lobes, primarily middle and caudal, contained multiple small white focal lesions throughout. Incision of the lung tissue revealed a focal caseous area extending into a right abdominal air sac and adhered to the cranial portion of the right kidney. The right abdominal air sac contained a fibrinopurulent exudate and a small amount of white fluid. This air sac was also adhered to the small intestine. At the point of adhesion two small, dark, firm masses were present within the intestinal wall. A circular area of ulceration was associated with these masses where the intestinal mucosa was penetrated. No parasites were noted in the gastrointestinal tract.

### MATERIALS AND METHODS

Tissue specimens of the nodular skin proliferations, lung, liver, spleen, kidney and small intestine were fixed in neutral buffered 10% formalin, embedded in paraffin, sectioned at 7 $\mu$ m and stained

<sup>□</sup> Published as Florida Agricultural Experiment Station Journal Series No. 2286.

with hematoxylin and eosin. Specimens of skin lesions were additionally fixed in a formaldehyde glutaraldehyde mixture,<sup>7</sup> subsequently washed in 0.1 M cacodylate buffer (pH 7.2), post-fixed in 1% osmium tetroxide, dehydrated in a graded ethanol series and embedded in eponaraldite. Thick sections (0.5  $\mu\text{m}$ ) were stained with toluidine blue and examined by light microscopy. Ultrathin sections were post-stained with saturated aqueous uranyl acetate followed by Reynold's lead citrate. Specimens were examined with a Hitachi HU-11E electron microscope.

Tissue specimens of lung and air sac were cultured on blood agar, MaConkey's agar and Sabouraud's media.

Trematodes were gently extracted from formalin fixed kidney. Intact specimens were stained with Gomori's trichrome stain.

## RESULTS

Histologic examination of skin lesions revealed a thickened squamous epithelium with areas of necrosis. Epithelial cells were hyperplastic and hypertrophic and contained round eosinophilic intracytoplasmic inclusions consistent with pox inclusions. The dermis contained multiple foci of heterophils and occasional plasma cells. Electron microscopic examination of skin specimens demonstrated virus particles consistent with pox virus (Figure 1). Virus particles measured 200 to 310 nm by 130 to 190 nm.

The architecture of the lung tissue was replaced by multiple, large, eosinophilic areas of necrosis. Within these large foci, branching septate hyphae were closely packed together. Hyphae were also seen in large accumulations in and around airways, often containing fruiting bodies

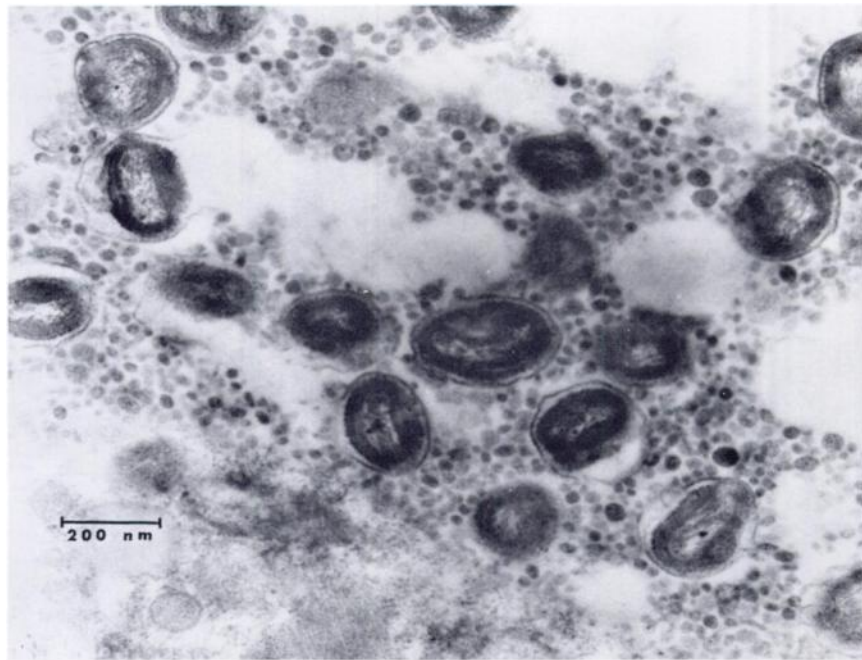


FIGURE 1. Transmission electron micrograph of avian pox virus particles within the cytoplasm of an epithelial cell.  $\times 64,000$ .

(Figure 2). Moderate accumulations of lymphocytes and heterophils were present around the affected airways and occasionally in the lumens.

In two sections of small intestine there was a large, thick, serosal mass of homogeneous eosinophilic material which was wide at the base, just above the serosa, and then narrowed slightly to form a nodule. Hyphal structures and bacteria were demonstrated throughout this area. An area of necrosis extended through the mucosal surface where there was an absence of villi and increased numbers of plasma cells and lymphocytes in the adjacent lamina propria.

Histologic examination of kidney revealed multiple cross-sections of trematodes (Figure 3). Most often the trematodes were present within cystic spaces lined by cuboidal cells. Adjacent

kidney parenchyma was often compressed with obliteration of the tubule lumens. Intact trematode specimens stained with Gomori's trichrome stain were identified as a species of *Renicola*. Eggs measured 28 to 34  $\mu\text{m}$  by 16 to 18  $\mu\text{m}$ .

Microbial culture of lung and air sac resulted in the isolation of *Proteus mirabilis*, *Enterobacter agglomerans* and *Aspergillus flavus*.

#### DISCUSSION

Pox virus particles were demonstrated by transmission electron microscopy in cutaneous lesions typical of avian pox. Although the majority of wild bird pox infections are mild and generally self limiting,<sup>4</sup> the concomitant *Aspergillus* pneumonia probably resulted in the death of the bird. Since both infections represent chronic processes it would be

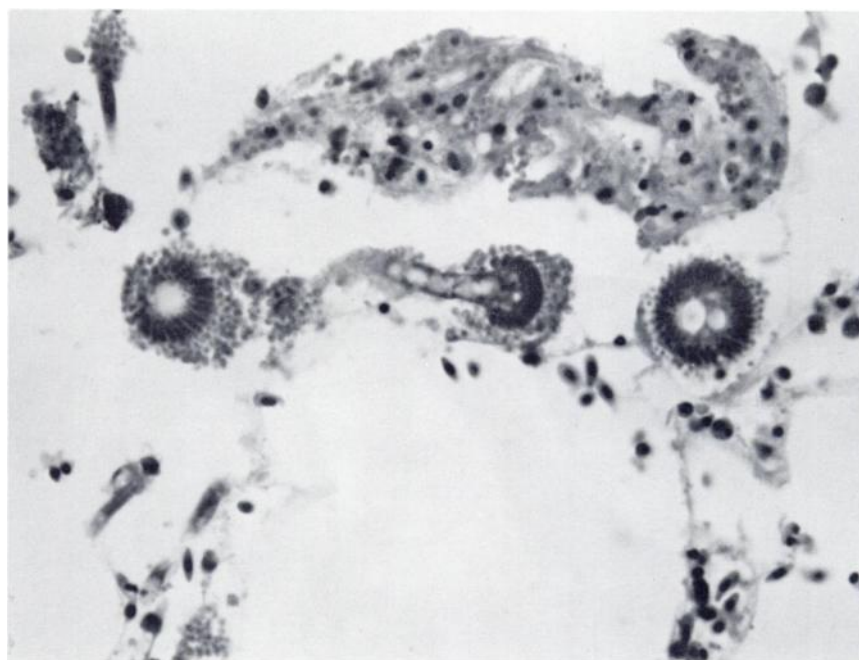


FIGURE 2. *Aspergillus flavus* fruiting bodies within an airway of lung tissue. H&E  $\times 540$ .

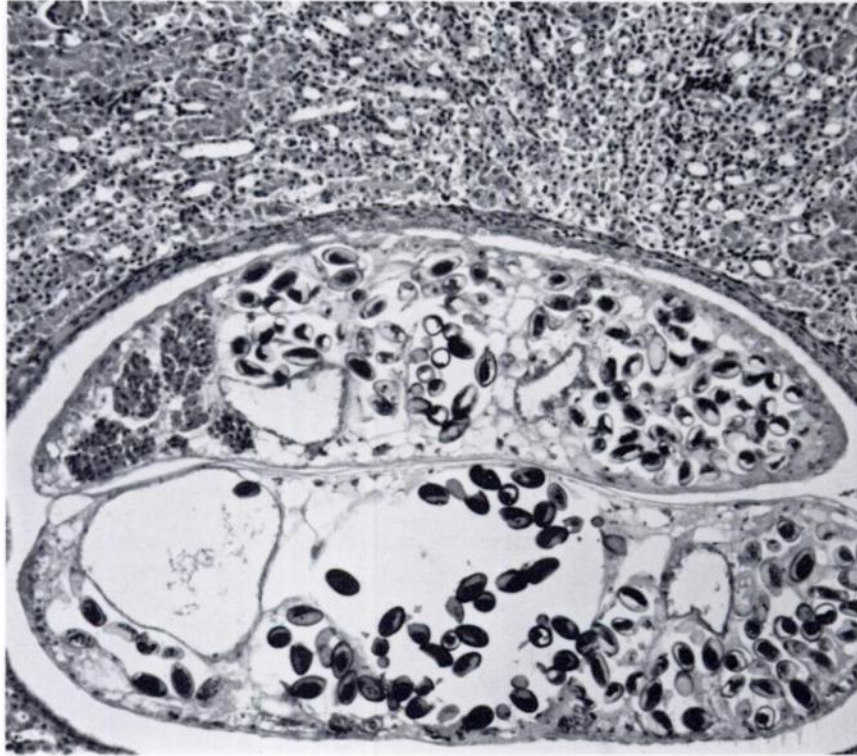


FIGURE 3. Photomicrograph of a cross-section of two *Rencicola* within the kidney. Tubules adjacent to the parasites are flattened with lumens obliterated. H&E  $\times 190$ .

difficult to identify which was primary and which secondary.

*Aspergillus* can involve not only lung and air sac but almost any organ. In the present report the intestinal lesions probably resulted from extension of the air sac lesions onto the serosa and through the mucosa. Coliform organisms demonstrated on the serosal surface of the intestine and isolated from lung tissue probably resulted from retrograde coliform movement out of the intestinal tract.

Although the distinctions between described *Rencicola* spp. are so tenuous that specific identification is difficult, if not impossible,<sup>6</sup> the trematodes recovered from the kidneys most closely

fit the description of *R. cruzi* described in part from specimens obtained from royal terns in Brazil.<sup>7</sup> The egg dimensions in the present report (28 to 34  $\mu\text{m}$  by 16 to 18  $\mu\text{m}$ ) are slightly smaller than those given for *R. cruzi* (34 to 42  $\mu\text{m}$  by 17 to 21  $\mu\text{m}$ ). In the present report the lesions attributed to *Rencicola* infection were similar to those described for *R. lari* in *Larus argentatus*.<sup>8</sup> There was little or no host tissue reaction. Compression and occlusion of adjacent parenchyma was the primary feature. This is in contrast to *Rencicola* infections in fulmars (*Fulmarus glacialis*) where a range in fibrotic response by the host was noted.<sup>9</sup> The effects of this parasite on the clinical status of the bird could not be assessed.

**LITERATURE CITED**

1. HARRIS, J.M., A.S. WILLIAMS and F.R. DUTRA. 1978. Avian pox in a group of common (California) murrelets (*Uria aalge*). *Vet. Med./Small Anim. Clin.* 73: 918-919.
2. HILL, J.R. and G. BOGUE. 1978. Natural pox infection in a common murre (*Uria aalge*). *J. Wildl. Dis.* 14: 337-338.
3. KIRMSE, P. 1967. Pox in wild birds. An annotated bibliography. *Wildl. Dis.* 49.
4. LOCKE, L.N., W.O. WIRTZ, II and E.E. BROWN. 1965. Pox infection and a secondary cutaneous mycosis in a red-tailed tropicbird (*Phaethon rubricauda*). *Bull. Wildl. Dis. Ass.* 1: 60-61.
5. MCDOWELL, E.M. and B.F. TRUMP. 1976. Histologic fixatives suitable for diagnostic light and electron microscopy. *Arch. Pathol. Lab. Med.* 100: 405-414.
6. O'MEARA, D.C. and J.F. WITTER. 1971. Aspergillosis pp 153-162. In: *Infectious and Parasitic Disease of Wild Birds*, Davis, J.N., R.C. Anderson, L. Karstad and D. O. Trainer, eds. Iowa State University Press, Ames, Iowa. 344 pp.
7. RILEY, J. and R.W. OWEN. 1972. *Renicola glacialis* sp. nov., a new trematode from the North Sea fulmar, *Fulmarus glacialis* (L.), with observations on its pathology. *J. Helminth.* 46: 63-72.
8. STUNKARD, H.C. 1964. Studies on the trematode genus *Renicola*: observations on the life-history, specificity, and systematic position. *Biol. Bull.* 126: 467-489.
9. TIMON, D.J. 1933. Sur une nouvelle espece de *Renicola* trematode parasite du rein des larides. *Bull. Inst. Oceanog. Monaco.* 616: 1-16.
10. WRIGHT, C.A. 1954. Trematodes of the genus *Renicola* from kidneys of birds in Brazil. *Rev. Brasil Biol.* 14: 61-64.

*Received for publication 8 April 1980*

---