



Severe Ulcerative Dermatitis in Platypus (Ornithorhynchus anatinus)

Authors: Munday, B. L., and Peel, B. F.

Source: Journal of Wildlife Diseases, 19(4) : 363-365

Published By: Wildlife Disease Association

URL: <https://doi.org/10.7589/0090-3558-19.4.363>

BioOne Complete (complete.BioOne.org) is a full-text database of 200 subscribed and open-access titles in the biological, ecological, and environmental sciences published by nonprofit societies, associations, museums, institutions, and presses.

Your use of this PDF, the BioOne Complete website, and all posted and associated content indicates your acceptance of BioOne's Terms of Use, available at www.bioone.org/terms-of-use.

Usage of BioOne Complete content is strictly limited to personal, educational, and non - commercial use. Commercial inquiries or rights and permissions requests should be directed to the individual publisher as copyright holder.

BioOne sees sustainable scholarly publishing as an inherently collaborative enterprise connecting authors, nonprofit publishers, academic institutions, research libraries, and research funders in the common goal of maximizing access to critical research.

tions and portions of skin from the back and ear and portions of the kidney and liver yielded colonies of *D. congolensis*. These were 1 mm in diameter, white to yellow, rough, round, raised and adherent to the surface.

Giemsa-stained smears from crusts on the back and the ear canal showed the typical filaments of *D. congolensis* (Fig. 2). Coccoid bodies as would be observed with the fragmentation of *Dermatophilus* filaments, were noted in sections of the lymph node. Methenamine silver and Giemsa-stained sections of the skin revealed several actinomycete "granules" in the epidermis and dermis (Fig. 3). The granules were composed of short, generally nonbranching, multiseptate filaments in a radiating configuration and surrounded primarily by degenerating neutrophils. Hematoxylin and eosin-stained sections showed extensive hyperkeratosis, with areas of parakeratosis and epithelial erosion. While the skin remained fairly well intact, the freezing of the carcass caused extensive autolysis which rendered the sections of the liver, kidney, and bladder microscopically uninterpretable.

While *D. congolensis* generally is associated with epidermitis, it has also been reported in subcutaneous infections. On one occasion it was isolated from a draining subcutaneous abscess near the popliteal lymph node of a cat (*Felis domesticus*) (Jones, 1976, J. Comp. Pathol. 86: 415-421). Dermatophilic granulomata of the glossal muscle, urinary bladder and tongue have also been described in that species (O'Hara and Cordes, 1963, N.Z. Vet. J. 11: 151-154; Baker et al., 1972, J. Small Anim. Pract. 13: 649-653). Subcutaneous abscesses due to *Dermatophilus*

were found in a bearded dragon lizard (*Amphibolurus barbatus*) (Simmons et al., 1972, Aust. Vet. J. 48: 465-466). As noted previously, subcutaneous and lymph node granulomas as well as granules were recently observed in a steer (Gibson et al., 1983, op. cit.).

Our present report of the isolation of the etiologic agent from the kidney and liver and the observation of coccoid bodies suggestive of *Dermatophilus* filaments in the lymph node, suggest a transient septicemia and possible systemic infection. The precautions used in excising the liver and kidney preclude, in our opinion, the contamination of these organs through contact with the surface of the carcass.

The *Dermatophilus* granules in the present case were found in the epidermis and dermis tissues whereas those formed by other actinomycetes are primarily seen in subcutaneous tissue. The granules noted in the white-tailed deer consisted simply of radiating, tightly packed, and evenly stained (Giemsa stain) *Dermatophilus* filaments while other actinomycotic granules are dense, round to irregular in shape and stain unevenly (hematoxylin and eosin) with a dark center and a light periphery.

The fawn may have acquired the infection through direct contact or by insect vectors. The lesions around the mouth and the spread of the infection to the hocks and feet may have limited the animal's ability to forage for food. This combined with the pressures of a harsh winter, the loss of hair, and loss of insulation, could have led directly to its debilitated condition. Its weakened state also may have contributed to a transient septicemia and dissemination of the etiologic agent to the kidney and liver.

Journal of Wildlife Diseases, 19(4), 1983, pp. 363-365
© Wildlife Disease Association 1983

Severe Ulcerative Dermatitis in Platypus (*Ornithorhynchus anatinus*)

B. L. Munday and B. F. Peel, Mt. Pleasant Laboratories, P.O. Box 46, Launceston South, Tasmania 7250, Australia

During the autumn of 1982, three moribund and one debilitated platypus were collected by a local resident on the banks of the Elizabeth River at Campbell Town, Tasmania. The de-

bilitated animal was returned to the river, and two of the moribund platypus, which died, were submitted for necropsy.

The collector noted that all the animals suffered from skin ulceration. The two animals examined at the laboratory were mature fe-

Received for publication 16 August 1982.

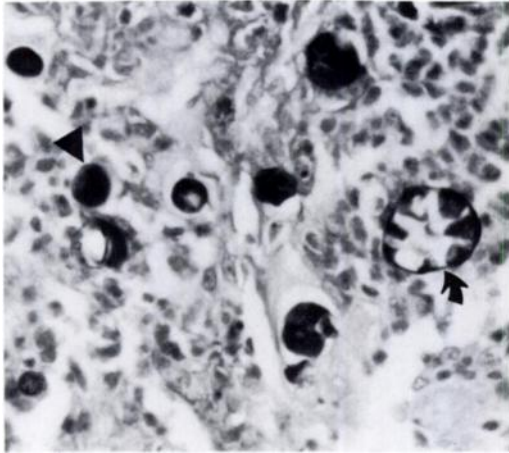


FIGURE 1. Presumed viable (arrow head) and non-viable (arrow) organisms in an inflammatory lesion. PAS. $\times 1,700$.

males in reasonable body condition. The ulcers had a rough, greyish, granulating surface and, in places, invaded the musculature to a depth of 10 mm below the skin. Lesions were noted on the bill (10×10 and 10×12 mm) and tail (50×15 and 30×30 mm) of both animals. One platypus also had a lesion 45×45 mm on its back and the other had lesions up to 10×7 mm on the right manus and pes. The former animal also had bilaterally symmetrical thickenings 20×30 mm on the ventral aspect of the tail base and the left periorbital area was thickened.

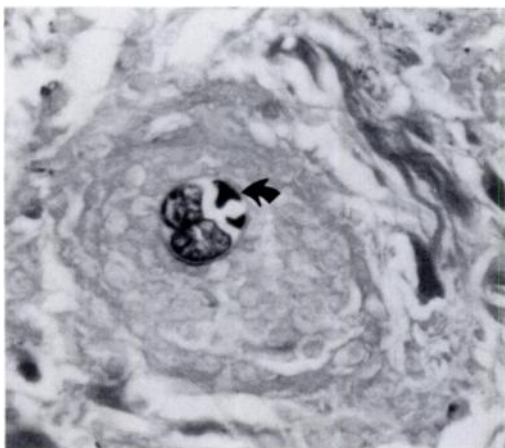


FIGURE 2. Organism containing daughter cells. Note degenerate appearance of one daughter cell (arrow). Gomori AgNO_3 . $\times 1,700$.

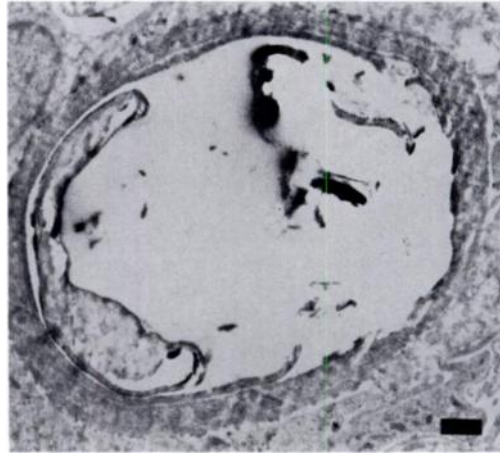


FIGURE 3. Electronmicrograph illustrating degenerate organism. Bar = $1 \mu\text{m}$.

These lesions were yellow in cross section. This platypus had miliary lesions, approximately 1 mm in diameter, throughout its lungs. After necropsy, selected portions of the carcasses were taken for histopathological, electronmicroscopic and microbiological procedures. Tissues for histopathology were fixed in 10% formal-saline, embedded in paraffin, sectioned at $5 \mu\text{m}$ and stained with hematoxylin and eosin, periodic acid-Schiff (PAS) and Gomori's silver-nitrate technique. For electronmicroscopy formalin-fixed material was post-fixed in osmium tetroxide, embedded in araldite and ultrathin sections were stained with lead citrate and uranyl ace-

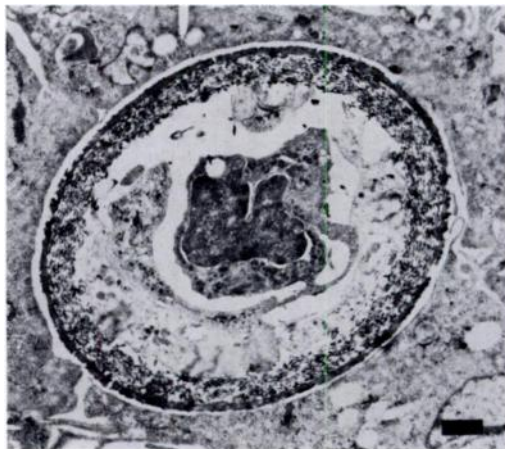


FIGURE 4. Electronmicrograph illustrating viable organism. Bar = $1 \mu\text{m}$.

tate. Prior to microbiological sampling, the surface of the ulcers was seared and deep samples were removed by pipette and inoculated onto Sabouraud's agar, algae culture agar and algae culture broth. Liver samples were analyzed for heavy metals by atomic absorption spectrophotometry after digestion in nitric/perchloric acid. Gas chromatography was used to detect organochlorine residues in solvent-extracted liver samples.

Histological examination of the ulcers and thickened skin lesions revealed a severe, suppurating, caseating granulomatous dermatitis/myositis associated with the presence of large round organisms. In some areas the lesions assumed the appearance of caseo-purulent "microabscesses" whereas in others the process was more diffuse in nature. In these latter areas macrophages, fibroblasts and giant cells were prominent with very few plasma cells or lymphocytes being present. The organisms measured 13–23 μm (mean of 15 organisms 18 μm) in hematoxylin and eosin sections and 17–30 μm (mean of 6 organisms 25 μm) in unstained araldite sections. In hematoxylin and eosin sections the wall was thick and stained mauve, but with PAS and Gomori's stains only the inner rim of the wall stained specifically. The contents varied considerably. Some organisms appeared to be unicellular with amorphous cytoplasm (Fig. 1). Others contained one or more elements which did not occupy the entire cell (Figs. 1, 2) and which stained less intensely. The animal with lung lesions had a granulomatous pneumonitis associated with organisms identical to those seen in the skin.

Electronmicroscopy revealed that most of the organisms were not viable (Fig. 3), and an exhaustive search was required to find apparently viable organisms (Fig. 4). The ultrastructural findings did not assist significantly with identification. The only organism isolated was a *Mucor* sp. which grew on the Sabouraud's agar.

From the available data it has not been possible to positively identify the organism in the lesions. It is not likely to have been the *Mucor* sp. as no hyphae were detected in the lesions. If it was an alga its failure to grow on algae media is puzzling, although it is probably pertinent that most of the tissue organisms appeared non-viable. The lesions and the organ-

isms are suggestive of a *Prototheca* sp. infection although the organisms in the platypus were larger than those reported in dogs (Innes et al., 1977, Onderstepoort J. Vet. Res. 44: 1–6; Tyler et al., 1980, J. Am. Vet. Med. Assoc. 176: 987–993). Tentatively, the diagnosis is infection with an achloric alga. The *Mucor* sp. was probably a surface contaminant.

The likely pathogenesis and epidemiology of the condition are intriguing. The most likely route of entry of the organism would have been through superficial skin wounds and this would adequately explain the dermal lesions. However, one animal had skin lesions without ulceration as well as pneumonitis. Probably these occurred as a result of hematogenous spread from primary skin lesions. It would be less likely that there was a primary hematogenous phase with localization mainly in the skin. The fact that four affected animals were found in a short stretch of river suggests that the morbidity was quite high, especially as not all affected platypus would have been found by the one interested observer. It may be pertinent that the river was very low as a result of drought conditions and chloric algal growth was unusually abundant suggesting that conditions for algal growth were particularly favorable. An inspection of the particular stretch of the river did not reveal any source of pollution, and heavy metal (zinc 28 and 33 ppm, copper 3 ppm) and organochlorine (nil detected) levels in the animals' livers were insignificant. It is probable that platypus normally suffer abrasions, especially to their bills which are used for foraging and, under the particular environmental conditions, these became colonized by achloric algae.

A particularly interesting incidental finding in both animals was the presence of a previously unreported dermal trichinelloid nematode (? *Capillaria* sp.; Spratt, pers. comm.; filed in Helminth Collection, CSIRO Division of Wildlife and Rangelands Research, accession no. P 22).

Thanks are due to Dr. A. R. Butler of Campbell Town who collected the specimens, Dr. D. M. Spratt who identified the dermal nematode, Mr. D. Munro for preparation of the electronmicrographs and the Government Analyst Laboratory for chemical analyses.