



Comparative Morphology of the Eggs of the Paramphistomid Trematodes of the Agile Wallaby, *Macropus agilis* (Gould, 1842)

Author: Speare, Richard

Source: Journal of Wildlife Diseases, 19(4) : 368-370

Published By: Wildlife Disease Association

URL: <https://doi.org/10.7589/0090-3558-19.4.368>

BioOne Complete (complete.BioOne.org) is a full-text database of 200 subscribed and open-access titles in the biological, ecological, and environmental sciences published by nonprofit societies, associations, museums, institutions, and presses.

Your use of this PDF, the BioOne Complete website, and all posted and associated content indicates your acceptance of BioOne's Terms of Use, available at www.bioone.org/terms-of-use.

Usage of BioOne Complete content is strictly limited to personal, educational, and non - commercial use. Commercial inquiries or rights and permissions requests should be directed to the individual publisher as copyright holder.

BioOne sees sustainable scholarly publishing as an inherently collaborative enterprise connecting authors, nonprofit publishers, academic institutions, research libraries, and research funders in the common goal of maximizing access to critical research.

cit.) and *H. danilewskyi* (Fallis and Bennett, 1961, op. cit.). Neither *Culicoides edeni*, *C. hinmani* nor *C. arboricola* have been previously implicated as vectors of haemosporidian parasites. Besides *C. crepuscularis*, none of the previously proven vectors are present in Florida.

The Bennett trap collections of *Culicoides* attracted to bait turkeys are the first biting records for *C. edeni* and *C. nanus* and the first biting record of *C. baueri* for birds. Biting collections of the remaining species have been made from both birds and mammals (Blanton and Wirth, 1979, The Sand Flies (*Culicoides*)

of Florida, Fl. Dept. Agric. Consumer Services, Gainesville, Florida, 204 pp.).

Supported in part by grant number 1270-G from the Florida Game and Fresh Water Commission. A contribution of Federal Aid to Wildlife Restoration, Florida Pittman-Robertson Project W-41. Florida Agricultural Experiment Station Journal Series No. 4809. The cooperation of the Florida Department of Natural Resources and the personnel at Paynes Prairie State Preserve as well as the advice and assistance of Lovett E. Williams, Jr. are gratefully acknowledged.

Journal of Wildlife Diseases, 19(4), 1983, pp. 368-370
© Wildlife Disease Association 1983

Comparative Morphology of the Eggs of the Paramphistomid Trematodes of the Agile Wallaby, *Macropus agilis* (Gould, 1842)

Richard Speare, Department of Tropical Veterinary Science, James Cook University of North Queensland, Townsville, Queensland, 4811, Australia

The paramphistomid trematodes, *Gemellitocotyle wallabicola* Prudhoe, 1975 and *Macropotrema pertinax* Blair, Beveridge and Speare, 1979 are both parasites of the agile wallaby. *Gemellitocotyle wallabicola* which occurs in the stomach, was first described from the agile wallaby from the Bula Plains in Papua New Guinea (Prudhoe, 1975, Dr. B. S. Chauhan, Comm. Vol., pp. 63-68), while *M. pertinax*, which inhabits the cecum and colon, was described from four locations in northern Australia (Blair et al., 1979, Ann. Parasitol. Hum. Comp. 54: 585-592). In a survey of parasites of agile wallabies (Speare et al., 1983, Aust. Wildl. Res. 10: 89-96), *G. wallabicola* was found near Darwin (Northern Territory) and at Ingham and at Stone's Crossing, Wenlock River (Queensland). In the same survey, *M. pertinax* was found in wallabies from near Darwin (Northern Territory) and from Cardwell, Ingham, Stone's Crossing and Townsville (Queensland). The geographical ranges of these paramphistomes overlap and may with further collecting prove to be the

same. As the life cycles of both paramphistomes and the significance of their associated pathological changes are unknown, it may prove useful to be able to identify naturally infected wallabies prior to necropsy. This paper compares the morphology of the eggs of both species and describes their differentiation in fecal samples.

A mature, wild female *M. agilis* was collected after being killed by a motor vehicle 15 km south of Ingham, Queensland. At necropsy, nine *G. wallabicola* were found in the stomach and 120 *M. pertinax* were recovered from the cecum and upper 15 cm of colon. These live parasites were washed in normal saline until free of gut contents and three *G. wallabicola* and 20 *M. pertinax* were selected randomly and placed separately in two petri dishes containing 0.85% saline. The petri dishes were kept at 22 C for 6 hr, the trematodes removed, and the eggs stored in saline at 4 C for a further 6 hr. Twenty-five eggs of each species were chosen at random and measured using an ocular micrometer, measurements being given in μm as mean \pm standard deviation (range).

Direct fecal smears were examined from the original wallaby and from a second wild agile

Received for publication 26 November 1982.

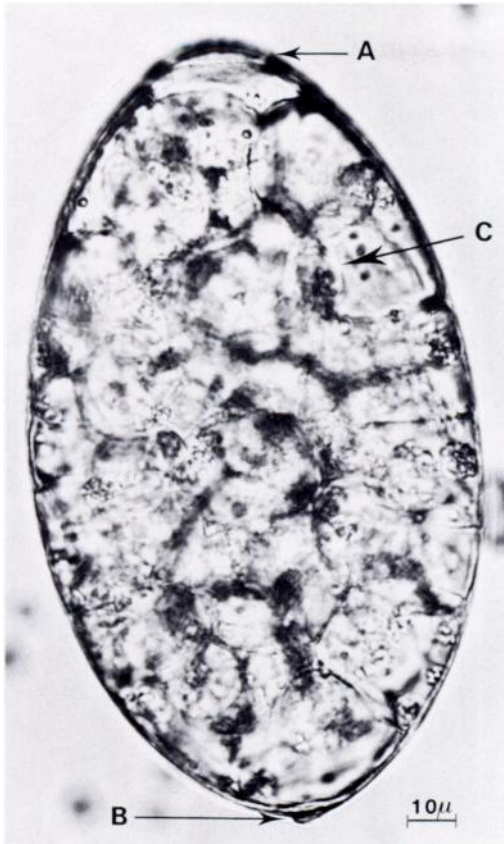


FIGURE 1. Photomicrograph of the egg of *Gemellicotyle wallabicola* from the agile wallaby, *Macropus agilis*. A, operculum; B, polar thickening; C, morula.

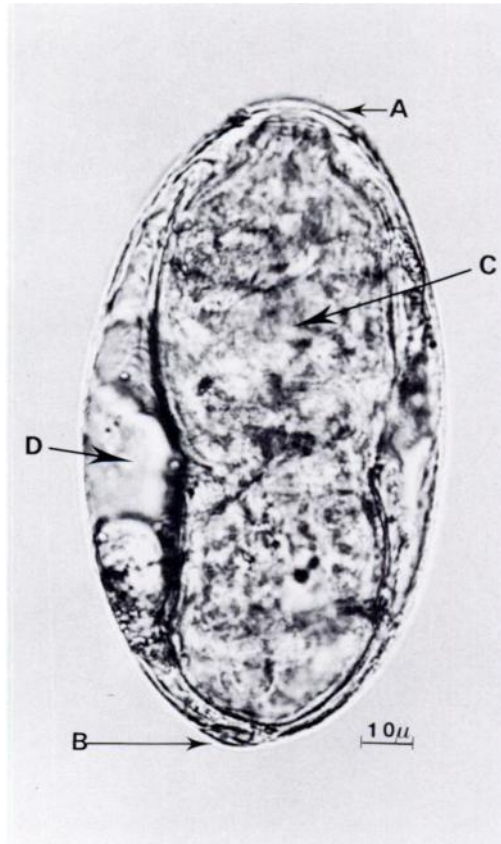


FIGURE 2. Photomicrograph of the egg of *Macrotrrema pertinax* from the agile wallaby, *Macropus agilis*. A, operculum; B, polar thickening; C, miracidium; D, refractile cells or gas bubbles beside miracidium.

wallaby infected solely with *G. wallabicola* and dead near Ingham from vehicular trauma.

The eggs of both species were colorless, oval in shape with a small operculum at one pole and a thickening of the shell at the other (Figs. 1, 2). The thickening opposite the operculum was more prominent for the egg of *G. wallabicola* forming a distinct knob, whereas the egg of *M. pertinax* had a slight bulge. The egg of *G. wallabicola* was larger than that of *M. pertinax*, with dimensions of $156 \pm 7 \mu\text{m}$ ($144\text{--}177 \mu\text{m}$) by $93 \pm 7 \mu\text{m}$ ($86\text{--}102 \mu\text{m}$) and $134 \pm 4 \mu\text{m}$ ($124\text{--}139 \mu\text{m}$) by $76 \pm 3 \mu\text{m}$ ($71\text{--}82 \mu\text{m}$), respectively. A morula was present in the egg of *G. wallabicola*, while that of *M. pertinax* contained a fully developed miracidium.

In direct fecal smears of rectal feces from both wallabies the stage of development for each

species was similar to that found for the eggs deposited in saline, the eggs of *G. wallabicola* containing a morula and those of *M. pertinax* containing an actively moving miracidium. After 24 hr at room temperature hatching of *M. pertinax* occurred when feces were examined in wet smears, while *G. wallabicola* had not progressed beyond the morula stage.

Only two species of paramphistomid trematodes have been reported from Macropodidae, both from the agile wallaby. Both species can occur in the same animal and pathological changes have been described for each species. *G. wallabicola* affects discrete areas in the glandular midstomach causing a hyperplasia of mucosa with ulceration and microhemorrhages at sites of attachment (Speare et al., 1983, op. cit).

M. pertinax was originally reported to cause atrophy of mucosa at attachment sites (Blair et al., 1979, op. cit.), but in heavier infections with a hundred or so parasites, a hyperplastic response is seen (Speare et al., 1983, op. cit.). In fecal samples it is possible to differentiate the eggs of the two species by size, shape, and state of development. The egg of *G. wallabicola* is larger than that of *M. pertinax*.

Length of 139 μm (133–144 μm) and width of 80 μm (77–83 μm) given in the original description of *M. pertinax* are slightly larger than in the present study. The width of eggs of *G. wallabicola* in this report are larger than in the original description (82–90 μm), while lengths are similar, the lengths in the original report ranging from 145 to 160 μm . The original mea-

surements for *M. pertinax* were on fresh material, while those for *G. wallabicola* were from fixed parasites. The measurements in this study and in previous descriptions, however, agree fairly closely. In the present study the dimensions of the eggs of each species were significantly different ($P < 0.001$; Student's *t*-test) with no overlap of ranges. If the previously reported dimensions are also taken into account, however, some eggs of *M. pertinax* from the upper end of its range may have the same dimensions as eggs of *G. wallabicola* from the lower end of its range. The simplest feature for differentiation is the presence of an active miracidium in the egg of *M. pertinax*. Additionally, the polar thickening is more prominent and knob-like in the egg of *G. wallabicola*.

Journal of Wildlife Diseases, 19(4), 1983, pp. 370–371
© Wildlife Disease Association 1983

Fatal Enteritis Caused by *Sphaeridiotrema globulus* (Trematoda: Psilostomidae) in a Whistling Swan¹

Douglas E. Roscoe, New Jersey Division of Fish, Game and Wildlife, Pathology Laboratory, Clinton Wildlife Management Area, Box 409, RD, Hampton, New Jersey 08827, USA; and **Jane E. Huffman**, Department of Zoology and Physiology, Parasitology Laboratory, Rutgers University, Newark, New Jersey 07102, USA

Sphaeridiotrema globulus infections have been reported to cause mortality in American coots (*Fulica americana*) (Trainer and Fischer, 1963, *J. Wildl. Manage.* 27: 483–486), lesser scaup (*Aythya affinis*) (Price, 1934, *Proc. Helminthol. Soc. Wash.* 1: 31–34), canvasbacks (*Aythya valisineria*) (Cornwell and Cowan, 1963, *Trans. N. Am. Wildl. Nat. Resour. Conf.* 23: 173–199), oldsquaw (*Clangula hyemalis*) (Sileo, pers. comm.), Muscovy ducks (*Cairina moschata*) (Campbell and Jackson, 1977, *Aust. Vet. J.* 53: 29–31), and a mute swan (*Cygnus olor*) (Speckman et al., 1972, *J. Wildl. Dis.* 8: 1–2). Infections of mute swans have been enzootic at Lake Musconetcong in northern New Jersey since 1970 (Roscoe and Huffman, 1982, *Avian Dis.* 26: 214–224). The swans contracted

parasites presumably from ingesting the intermediate host snail *Goniobasis virginica* which was the only species of snail in the lake found to harbor infective metacercariae of *S. globulus* (Huffman and Fried, 1983, *J. Parasitol.* 69: 49).

On December 3, 1981 three adult and two 7-month-old whistling swans (*Olor columbianus*) were observed on Lake Musconetcong in Netcong, New Jersey. The following day one of the juveniles was observed attempting to climb onto skim ice. It exhibited signs of weakness which included "limber neck" and "wing droop." The bird was found dead on December 5, 1981.

The bird was immediately necropsied. Blood smears were stained with Diff-Quik (Dade Diagnostics, Inc., Aguada, Puerto Rico 00602, USA). Trematodes and cestodes were fixed in hot AFA and stained with Gower's Carmine (Gower, 1939, *Stain Technol.* 14: 31–32). Portions of brain, liver, lung, spleen, heart, kidney, proventriculus, femoral marrow, cecum and in-

Received for publication 15 November 1982.

¹ A contribution from the New Jersey Division of Fish, Game and Wildlife P-R Project W-58-R-6 and a Research in Aid Grant from Sigma Xi.