

HISTOLOGICAL ASPECTS OF NATURAL EUSTRONGYLOID INFECTIONS OF THE NORTHERN WATER SNAKE, NERODIA SIPEDON

Author: Bursey, C. R.

Source: Journal of Wildlife Diseases, 22(4) : 527-532

Published By: Wildlife Disease Association

URL: <https://doi.org/10.7589/0090-3558-22.4.527>

BioOne Complete (complete.BioOne.org) is a full-text database of 200 subscribed and open-access titles in the biological, ecological, and environmental sciences published by nonprofit societies, associations, museums, institutions, and presses.

Your use of this PDF, the BioOne Complete website, and all posted and associated content indicates your acceptance of BioOne's Terms of Use, available at www.bioone.org/terms-of-use.

Usage of BioOne Complete content is strictly limited to personal, educational, and non - commercial use. Commercial inquiries or rights and permissions requests should be directed to the individual publisher as copyright holder.

BioOne sees sustainable scholarly publishing as an inherently collaborative enterprise connecting authors, nonprofit publishers, academic institutions, research libraries, and research funders in the common goal of maximizing access to critical research.

HISTOLOGICAL ASPECTS OF NATURAL EUSTRONGYLOID INFECTIONS OF THE NORTHERN WATER SNAKE, *NERODIA SIPEDON*

C. R. Bursey

Department of Biology, Pennsylvania State University, Shenango Valley Campus, Sharon, Pennsylvania 16146, USA

ABSTRACT: Encapsulated as well as unencapsulated fourth stage larvae of *Eustrongylides* sp. were found in four northern water snakes, *Nerodia sipedon*, from Virginia. Unencapsulated nematodes occurred within muscle, subcutaneous tissue and in the coelom. Encapsulated nematodes occurred in three forms: recently encapsulated, degenerating, or sclerotic; they were found on the mesentery, in muscle and subcutaneous tissue. Encapsulation was associated with muscular hypertrophy, fibroplasia and eosinophilia.

INTRODUCTION

Although species of *Eustrongylides* are important parasites of vertebrates, little is known about their effect on wild populations of snakes. Winsor (1948) reported the occurrence of eustrongyloid nematodes in 22 captive snakes examined after death at the Philadelphia Zoo during the years 1925-1931: four black snakes, *Coluber constrictor*; one whip snake, *Masticophis flagellum*; one Jersey pine snake, *Pituophis melanoleucus melanoleucus*; two Texas pine snakes, *Pituophis melanoleucus ruthveni*; five eastern garter snakes, *Thamnophis sirtalis*; four red-sided garter snakes, *Thamnophis sirtalis parietalis*; one fer-de-lance, *Bothrops atrox*; one copperhead, *Agkistrodon contortrix*; and three pythons, Boidae (unidentified as to species). In addition, two water snakes, *Nerodia sipedon*, from the Fairmount Park Aquarium of Philadelphia were found to be infected (Winsor, 1948). Lichtenfels and Lavies (1976) described the death of captive red-sided garter snakes, *Thamnophis sirtalis parietalis*, due to an accidental infection by *Eustrongylides* sp. as well as the location of the parasite, signs of infection, and the successful surgical

treatment of infected snakes. Jones (1978) recovered two immature female *Eustrongylides acrochordi* from the stomach of a Javan wart snake, *Acrochordus javanicus*, which had been preserved in the Queensland Museum of Australia. The present report presents histological aspects of natural infections of northern water snakes, *Nerodia sipedon*, by eustrongyloid nematodes.

MATERIALS AND METHODS

During a faunal survey of Little Mosquito Creek, Accomack County, Virginia (37°95'N, 75°45'W), March-May 1981, six northern water snakes, *Nerodia sipedon*, were captured. The normal, smooth appearance of the body wall was broken by localized swellings which gave each snake a "lumpy" appearance. The number of swellings per snake ranged from six to 22. In a follow-up survey, March-May 1982, 12 northern water snakes were captured. All had swellings (two to eight). Two snakes from each survey were necropsied.

The swellings contained encapsulated nematodes which, along with surrounding tissues, were excised and fixed in 10% formalin. Excised material was dehydrated in graded ethanol, cleared in cedarwood oil and embedded in paraffin. Sections of 10- μ m thickness were cut, mounted on glass slides, stained with hematoxylin and eosin and examined by light microscopy.

Several nematodes were removed to an ethanol-glycerin preservative and deposited in the U.S. National Parasite Collection, Beltsville, Maryland 20705, USA (Accession No. 79036).

Received for publication 30 September 1985.



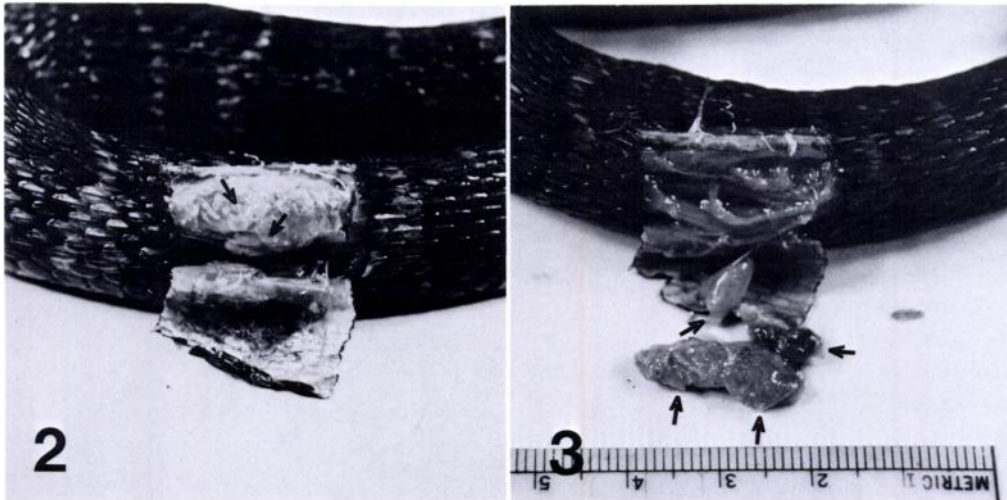
FIGURE 1. Subcutaneous swellings (arrows) on a northern water snake. The snake was 78 cm in length.

RESULTS AND DISCUSSION

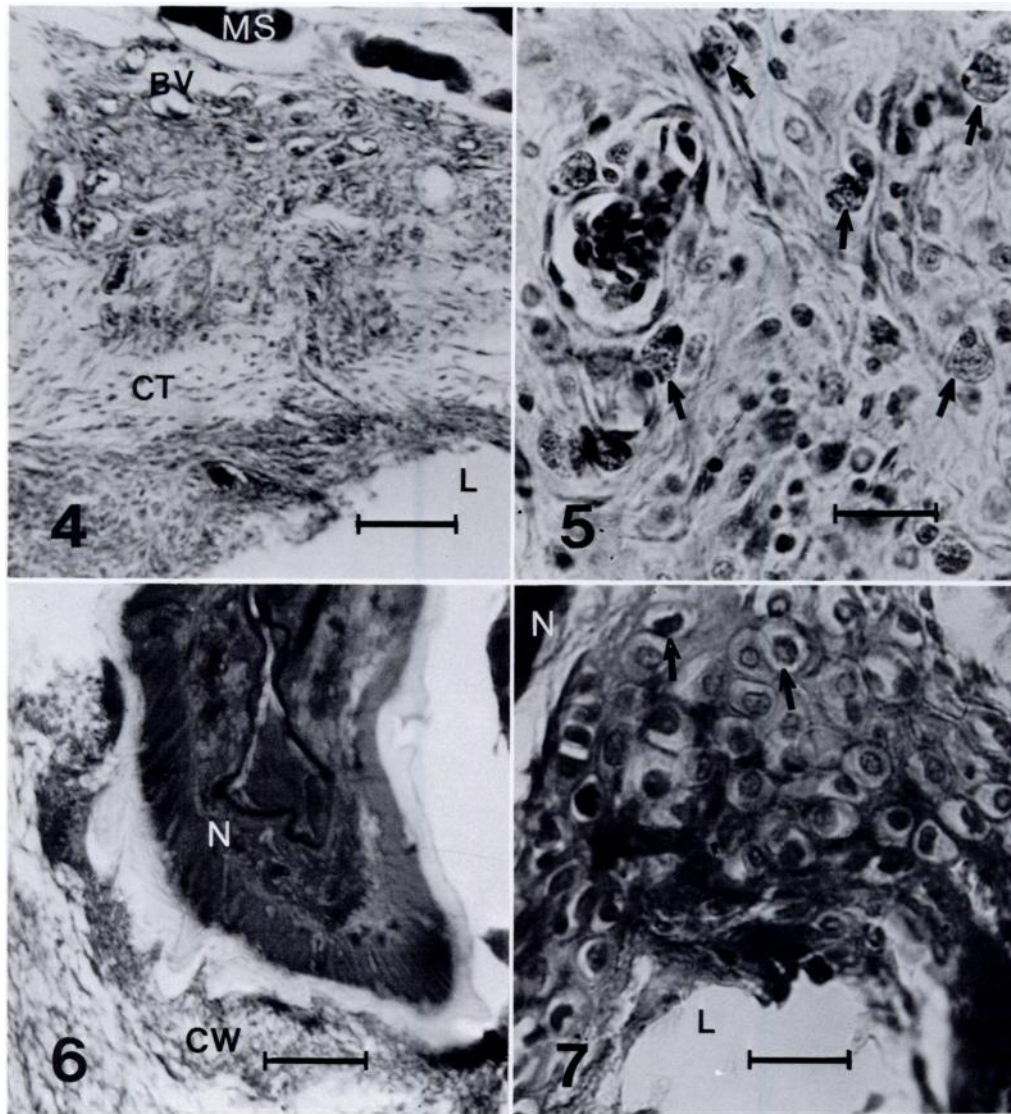
Swellings occurred most frequently in the middle third of the body of a snake (Fig. 1). Removal of a section of integu-

ment at a swelling (Fig. 2) revealed the presence of oval, fibrous-walled capsules, 10–12 mm long, 3–5 mm wide. Capsules were easily teased from surrounding tissues (Fig. 3); each contained a single, coiled nematode. As many as six capsules were present in a swelling. Encapsulation caused displacement of overlying integument and underlying muscle; fibrous hyperplasia and muscle hypertrophy were also present.

Necropsy revealed the presence of unencapsulated nematodes within muscle tissue, subcutaneous tissue and the coelom. These fourth-stage nematodes were 60–100 mm long by 0.8 mm in diameter and bright red when alive; the head had 12 papillae, two circles of six each, characteristic of the genus *Eustrongylides* (with one exception, *E. perpapillatus*). Encapsulated nematodes of similar size and with characteristic papillae were found also at necropsy on the mesentery, within muscles and under the visceral peritoneum of the stomach and intestine. Microscopically, three forms of encapsulated nematodes could be identified: re-



FIGURES 2, 3. 2. A mass of encapsulated, coiled, eustrongyloid nematodes (arrows) under the integument of a northern water snake. The mass was 10 mm wide, 20 mm long and 6 mm thick. 3. Four encapsulated eustrongyloid nematodes (arrows) under the integument of a northern water snake and from the mass seen in Figure 2.



FIGURES 4-7. 4. Fibrous connective tissue network (CT) of a subintegumental capsule from a northern water snake with lumen (L), blood vessels (BV), and muscle cells (MS). Scale = 10 μ m. 5. Eosinophils (arrows) within the connective tissue network of a subintegumental capsule from a northern water snake. Scale = 20 μ m. 6. Translucent eustrongyloid nematode (N) within a sclerotized capsule from a northern water snake (CW, capsule wall). Scale = 10 μ m. 7. Matrix vesicles (arrows) of a sclerotized capsule from a northern water snake with eustrongyloid nematode (N) and lumen (L). Oblique section, scale = 20 μ m.

cently encapsulated, i.e., the hypodermis and muscle cells of the body wall of the nematode were obvious; degenerating, cells of the body wall were indistinct; or sclerotized, the body wall of the nematode was highly refractile.

In recent encapsulations the nematode frequently was recovered alive; no cellular debris or fluid was evident within the encapsulation. Histologically, the fibrous network of the wall of the capsule was well organized (Fig. 4) and varied from

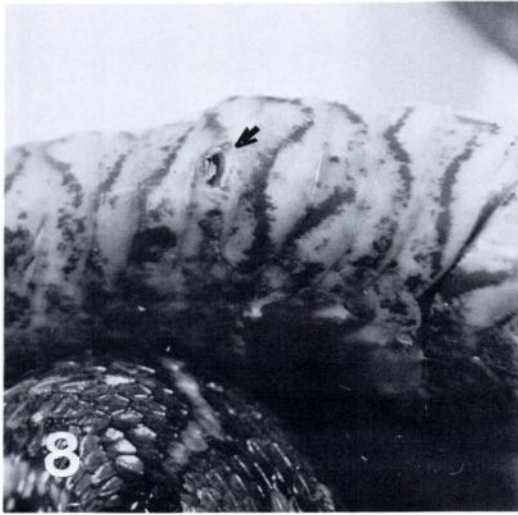

FIGURE 8. Integumental lesion, 1.5 × 5 mm (arrow), of a northern water snake.

100 to 400 μm in thickness. The internal surface was smooth and covered with squamoid cells. Cells within the wall were obvious; nuclei and cell membranes were well defined. Fibroblasts and their attendant fibers predominated. The region of the capsule adjacent to normal connective tissue elements was highly vascular (Fig. 4). Cells with little affinity for stain, probably macrophages, were present as were large numbers of eosinophils (Fig. 5).

Where degeneration of the nematode was occurring, capsules were filled with a flocculant material, apparently fixed serous exudate. Some cellular debris was present. Fibers of the capsule were thicker and more ordered than before; fibroblasts were less numerous. Cell boundaries were less distinct and cells appeared to be agranular and distorted. Pyknotic nuclei as well as karyorrhetic and karyolytic changes were noted. A distinct basophilia was present; but, within the wall of the capsule, macrophages and eosinophils were still evident. These encapsulations might be cited as instances of caseous necrosis.


Where sclerotization had occurred, the

capsules were filled with a homogeneous material, perhaps coagulated serous exudate. Here, the nematode had a mineralized quality not seen in the previous sections (Fig. 6). These tissues were hard and difficult to cut. Such encapsulations might be cited as instances of coagulation necrosis. In some cases, small matrix vesicles (Fig. 7) were seen in the wall of the capsule—a tissue pattern often indicative of a sclerogenous process.

An integumental lesion was found in one snake (Figs. 8, 9). It was filled with cellular debris and the posterior end of a sclerotized nematode. Removal of a section of integument surrounding the lesion revealed a “knot” of six nematodes (Fig. 10), four of which were partially sclerotized; two were recently encapsulated.

The biology of North American species of *Eustrongylides* is known incompletely. Piscivorous birds generally are considered to be the definitive host (Chitwood, 1969); the first intermediate host is thought to be freshwater oligochaetes (Karmanova, 1968); and fish are assumed to be the second intermediate host (von Brand, 1944; Cullinan, 1945; Fastzkie and Crites, 1977). Numerous paratenic hosts have been described (Canavan, 1929; Modzelewski and Culley, 1974; Cooper et al., 1978a)

The biology of adult *Eustrongylides tubifex* has been examined. Cooper et al. (1978b) studied natural and experimental infections of birds. At necropsy, adult nematodes were found to be encapsulated within the serosa of the proventriculus. Male nematodes were dead and disintegrating after 16 days while gravid females oviposited for 16–24 days, then died. Wiese et al. (1977) described an episode of extensive mortality of nesting ardeids. Some affected nestlings had integumental ulcers through which nematodes protruded; however, lesions frequently were found to be regressing in older (4 wk of age) nestlings. Gravid female nematodes were recovered from some of the nestlings.



FIGURES 9, 10. 9. Sclerotized eustrongyloid nematode mass from an integumental lesion of a northern water snake. Scale = 10 mm. 10. A recently encapsulated eustrongyloid nematode of a northern water snake taken from the mass seen in Figure 9. Scale = 10 mm.

Some adult birds had evidence of previous infections, but live nematodes were not recovered from adult birds. Adult *Eustrongylides* are apparently short-lived.

Aspects of the biology of eustrongyloid larvae infecting intermediate and paratenic hosts have been studied. Von Brand (1944) dissected several thousand killifish, *Fundulus heteroclitus*, and found all nematode larvae to be alive. In other fish species, many nematodes were dead and disintegrating. Cullinan (1945) observed that infections of *Eustrongylides* in *F. heteroclitus* did not cause an immunological response; in addition, the nematode larvae in these infections were encapsulated along the mesentery. Similar observations have been reported in yellow perch, *Perca flavescens* (Cooper et al., 1978a). Others (Hunter, 1942; von Brand, 1944; Cone and Anderson, 1977) have found larvae encapsulated within muscle. Reinfection experiments have been successful (von Brand and Cullinan, 1943; von Brand, 1944; Fastzkie and Crites, 1977; Cooper et al., 1978b). If an intermediate or paratenic host is eaten during the in-

fective period (apparently any time before larval death), a new infection may be established. Reinfection is apparently common. Older fish are most intensely infected (Cooper et al., 1978a); this may reflect the increased carnivorous habits of larger fish. Herbivorous fish (Wiese et al., 1977) and carp, *Cyprinus carpio* (von Brand, 1944), were not found to be infected. Since dead nematodes are found frequently in naturally occurring infections of paratenic hosts, the infective period is apparently limited. At some point in time these nematodes become encapsulated and eventually die. Inflammation brought about by nematode infection is often associated with eosinophilia, an immunologic phenomenon. The eosinophilia reported in this study suggests massive tissue response by the snake host.

Lichtenfels and Lavies (1976) provided a summary of the time course necessary for the encapsulation of *Eustrongylides* in snakes: about 5 wk after feeding killifish to garter snakes, one snake began violent contortions which continued intermittently for 2 wk until it died. A swelling on the

body wall was found, opened, and a nematode removed. During this 7-wk period, other snakes developed subcutaneous swellings; some died. Nematodes were removed from the lungs and other internal tissues at necropsy. About 12 wk later, encapsulated nematodes were removed. Encapsulation had not been seen earlier. In this study, nematodes were found in four conditions: unencapsulated, presumably migrating forms, newly ingested; encapsulated but alive; encapsulated and dead; encapsulated and sclerotic. These varied conditions are probably the result of repetitive nematode infections occurring over time. Sclerotized nematodes have been found in fish (Cooper et al., 1978a) and resolving lesions have been seen in birds (Wiese et al., 1977); thus scar tissue could be expected in snakes.

Various killifish, *Fundulus* spp., have been identified as a food source of infected vertebrates. Wiese et al. (1977) examined 11 species of fish from 13 different heron feeding areas in Delaware and found larvae of *Eustrongylides* in 41% of the captured *F. heteroclitus*, but only one fish of the other species was infected. Von Brand (1938) examined 62 specimens of *F. heteroclitus* and found 55 infected; a total of 157 eustrongyloid larvae was recovered. Lichtenfels and Lavies (1976) fed wild-caught *F. diaphanus* to captive snakes which subsequently developed eustrongyliasis. In this study, freshly caught water snakes would frequently regurgitate *F. heteroclitus*.

ACKNOWLEDGMENT

I thank Dr. Robin Overstreet, Gulf Coast Research Laboratory, for identification of the nematodes.

LITERATURE CITED

- CANAVAN, W. P. N. 1929. Nematode parasites of vertebrates in the Philadelphia Zoological Garden and vicinity. *Parasitology* 21: 63-102.
- CHITWOOD, M. B. 1969. The systematics and biology of some parasitic nematodes. In *Chemical Zoology*, Vol. III, M. Florin and B. T. Scheer (eds.). Academic Press, New York, pp. 223-244.
- CONE, D. K., AND R. C. ANDERSON. 1977. Parasites of pumpkinseed (*Lepomis gibbosus* L.) from Ryan Lake, Algonquin Park, Ontario. *Can. J. Zool.* 55: 1410-1423.
- COOPER, C. L., J. L. CRITES, AND D. J. SPRINKLE-FASTZKIE. 1978a. Population biology and behavior of larval *Eustrongylides tubifex* (Nematoda: Dioctophymatida) in poikilothermous hosts. *J. Parasitol.* 64: 102-107.
- , ———, AND ———. 1978b. Experimental and natural infections of *Eustrongylides* sp. (Nematoda: Dioctophymatidae) in waterfowl and shore birds. *Avian Dis.* 22: 790-792.
- CULLINAN, R. P. 1945. The larvae of *Eustrongylides ignotus* in *Fundulus heteroclitus*. *J. Parasitol.* 31: 109-112.
- FASTZKIE, J. S., AND J. L. CRITES. 1977. A redescription of *Eustrongylides tubifex* (Nitzsch 1819) Jagerskiold 1909 (Nematoda: Dioctophymatidae) from mallards (*Anas platyrhynchos*). *J. Parasitol.* 63: 707-712.
- HUNTER, G. W. 1937. Parasitism of fishes in the lower Hudson area. N.Y. State Conserv. Dept., 26th Ann. Rpt., Suppl. 11., Biol. Survey Lower Hudson Waters, pp. 264-273.
- JONES, H. I. 1978. Gastrointestinal nematodes from aquatic Australian snakes. *Mem. Queensl. Mus.* 18: 243-263.
- KARMANOVA, E. M. 1968. Dioctophymidea of animals and man and their causation of disease. In *Fundamentals of Nematology*, Vol. 20, K. I. Skrajabin (ed.). Izdatelstvo. Nauk An. SSR, Moscow, 262 pp. [In Russian.]
- LICHTENFELS, J. R., AND B. LAVIES. 1976. Mortality in red-sided garter snakes, *Thamnophis sirtalis parietalis*, due to larval nematode, *Eustrongylides* sp. *Lab. Anim. Sci.* 26: 465-467.
- MODZELEWSKI, E., AND D. D. CULLEY, JR. 1974. Occurrence of the nematode *Eustrongylides wenrichi* in laboratory reared *Rana catesbeiana*. *Copeia* 1974: 1000-1001.
- VON BRAND, T. 1938. Physiological observations on a larval *Eustrongylides* (Nematoda). *J. Parasitol.* 24: 445-451.
- . 1944. Physiological observations upon a larval *Eustrongylides*. VI. Transmission to various coldblooded intermediate hosts. *Proc. Helminthol. Soc. Wash.* 11: 23-27.
- , AND R. P. CULLINAN. 1943. Physiological observations upon a larval *Eustrongylides*. V. The behavior in abnormal warmblooded hosts. *Proc. Helminthol. Soc. Wash.* 10: 29-33.
- WIESE, J. H., W. R. DAVIDSON, AND V. F. NETTLES. 1977. Large scale mortality of nesting ardeids caused by nematode infection. *J. Wildl. Dis.* 13: 376-382.
- WINSOR, H. 1948. Hosts of eustrongyloid worms from Fairmount Park Aquarium and Philadelphia Zoo. *Proc. Pa. Acad. Sci.* 22: 68-72.