



Fusarium oxysporum in Red Sea Bream (*Pagrus* sp.)

Authors: Hatai, Kishio, Kubota, Sabrouh S., Kida, Norihiro, and Udagawa, Shun-ichi

Source: Journal of Wildlife Diseases, 22(4) : 570-571

Published By: Wildlife Disease Association

URL: <https://doi.org/10.7589/0090-3558-22.4.570>

BioOne Complete (complete.BioOne.org) is a full-text database of 200 subscribed and open-access titles in the biological, ecological, and environmental sciences published by nonprofit societies, associations, museums, institutions, and presses.

Your use of this PDF, the BioOne Complete website, and all posted and associated content indicates your acceptance of BioOne's Terms of Use, available at www.bioone.org/terms-of-use.

Usage of BioOne Complete content is strictly limited to personal, educational, and non - commercial use. Commercial inquiries or rights and permissions requests should be directed to the individual publisher as copyright holder.

BioOne sees sustainable scholarly publishing as an inherently collaborative enterprise connecting authors, nonprofit publishers, academic institutions, research libraries, and research funders in the common goal of maximizing access to critical research.

***Fusarium oxysporum* in Red Sea Bream (*Pagrus* sp.)**

Kishio Hatai and Sabrouh S. Kubota, Nippon Veterinary and Zootechnical College, 1-7-1, Kyonan Cho, Musashino, Tokyo 180, Japan; **Norihiro Kida**, Kyowa Yakuhin Co., Ltd., 801, Nishihara, Wakayama 641, Japan; **and Shun-ichi Udagawa**, National Institute of Hygienic Sciences, 1-18-1, Kamiyoga, Setagaya, Tokyo 158, Japan

Red sea bream (*Pagrus major*) are cultured widely throughout the southern coastal waters of Japan, usually in floating net pens. The numbers cultured each year have increased steadily since 1965 and in 1983 reached 25,000 metric tons. The fish grow slowly and reach market sizes of 1 kg or more in weight in 3 yr. Recently, fry closely resembling *P. major* have been imported from Southeast Asian sources. The species has not been correctly identified, other than as a member of the genus *Pagrus*. One characteristic of this introduced fish is that it grows more rapidly than the Japanese red sea bream. Various diseases, however, have occurred among the imported fish, and in Japan some mortality has resulted. The diseases include epitheliocystis, white-spot disease due to *Cryptocaryon irritans*, and bacterial infections, such as edwardsiellosis and vibriosis. This report concerns a case of infection by *Fusarium oxysporum* that occurred on a farm in Mie Prefecture in May 1984 among juvenile "red sea bream" imported from Hong Kong.

Fish dying from the epizootic measured 5.2-6.4 cm in length and 2.7-7.7 g in weight. In almost all cases, no external signs were observed. Detailed examinations were made on five moribund specimens. Microbial examination showed that one of the five was infected with a fungus, whereas four were infected with the bacterium *Edwardsiella tarda*. Kidneys of the fish infected with the fungus were remarkably swollen and discolored. The

other organs, however, appeared to be normal. No internal signs were evident in the fish infected with *E. tarda*. It was not clear how important a factor in the mortality the fungus was because the fish were not treated for the bacterial infection.

The fungus was isolated by incubating a piece of kidney on Sabouraud dextrose agar (SA agar) at 25 C, and a pure culture was obtained. Fungal colonies were subcultured onto SA agar and identified as *Fusarium oxysporum* Schlecht as de-

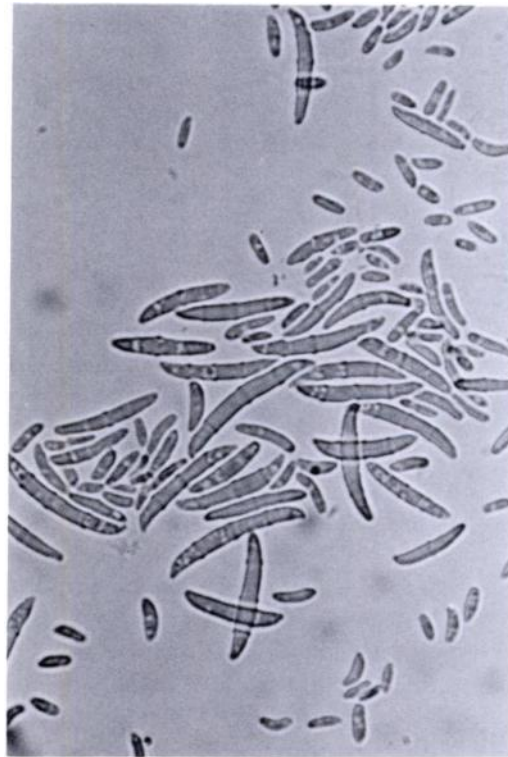

FIGURE 1. Microconidia and macroconidia of *Fusarium oxysporum* NVZC 8401 isolated from the kidney of a red sea bream. $\times 400$.

Received for publication 13 January 1986.

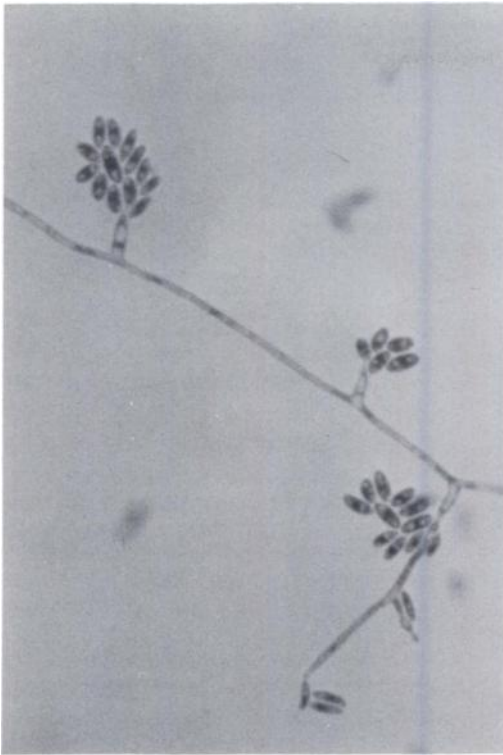


FIGURE 2. Microconidia of *Fusarium oxysporum* NVZC 8401 (from a red sea bream) produced on the tip of short monophialides. Cotton blue stain, $\times 400$.

scribed by Booth (1971, *The Genus Fusarium*, Commonwealth Mycological Institute, Kew, Surrey, England, 237 pp.) (Figs. 1, 2).

The following are the outstanding characters of the fungus. Colonies were fast-growing, floccose, and white or cream with a purple or violet tinge. Microconidia were abundant and borne on short, simple, lateral monophialides or from sparsely branched conidiophores, ellipsoidal or slightly curved, generally one-celled, and produced only in false heads. Macroconidia were slightly sickle-shaped, up to 3(–4)-septate, and with an attenuated apical cell and a pedicellate basal cell. The living culture of the fungus is being kept in the Culture Collection of the Nippon Veterinary and Zootechnical College as NVZC 8401.

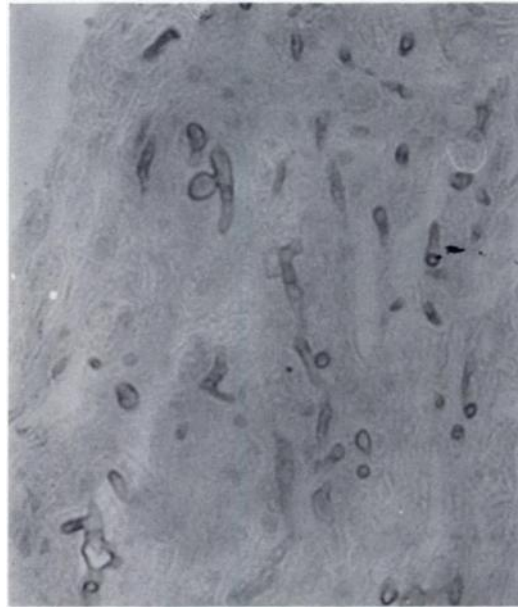


FIGURE 3. Section of kidney of red sea bream with mycotic infection. Note the hyphae. PAS, $\times 400$.

Following the results of mycological examination, we tried to identify the fungus in histologic sections of kidney. Frozen kidney tissue was thawed and fixed in 10% formalin, embedded in paraffin, sectioned at 5 μ m, and stained with hematoxylin and eosin (HE) and periodic acid-Schiff (PAS). Septate hyphae in the kidneys stained well by PAS (Fig. 3).

The distribution of *Fusarium oxysporum* is world-wide. It occurs chiefly as a soil saprophyte. Numerous strains of the fungus, however, have been reported previously as serious wilt pathogens of plants (Booth, 1971, op. cit.) and also as a species involved in superficial and deep infections in man and animals (Austwick, 1984, *In The Applied Mycology of Fusarium*, Moss and Smith (eds.), Cambridge University Press, Cambridge, England, pp. 129–140). The only other known case of *Fusarium* infection in fish is *Fusarium culmorum* found on the skin of a “carp” (Horter, 1960, *Z. Parasitenkd.* 20: 355–358). We believe this is the first reported case of an *F. oxysporum* infection in fish.