

Histomoniasis and Reticuloendotheliosis in a Wild Turkey (*Meleagris gallopavo*) in North Carolina

Authors: Ley, David H., Ficken, Martin D., Cobb, David T., and Witter, Richard L.

Source: Journal of Wildlife Diseases, 25(2) : 262-265

Published By: Wildlife Disease Association

URL: <https://doi.org/10.7589/0090-3558-25.2.262>

BioOne Complete (complete.BioOne.org) is a full-text database of 200 subscribed and open-access titles in the biological, ecological, and environmental sciences published by nonprofit societies, associations, museums, institutions, and presses.

Your use of this PDF, the BioOne Complete website, and all posted and associated content indicates your acceptance of BioOne's Terms of Use, available at www.bioone.org/terms-of-use.

Usage of BioOne Complete content is strictly limited to personal, educational, and non - commercial use. Commercial inquiries or rights and permissions requests should be directed to the individual publisher as copyright holder.

BioOne sees sustainable scholarly publishing as an inherently collaborative enterprise connecting authors, nonprofit publishers, academic institutions, research libraries, and research funders in the common goal of maximizing access to critical research.

Histomoniasis and Reticuloendotheliosis in a Wild Turkey (*Meleagris gallopavo*) in North Carolina

David H. Ley,¹ Martin D. Ficken,¹ David T. Cobb,² and Richard L. Witter,³ ¹Department of Food Animal and Equine Medicine, College of Veterinary Medicine, North Carolina State University, Raleigh, North Carolina 27606, USA; ²Department of Zoology, North Carolina State University, Raleigh, North Carolina 27695, USA; ³U.S. Department of Agriculture, Agricultural Research Service, Regional Poultry Research Laboratory, East Lansing, Michigan 48823, USA

ABSTRACT: A moribund wild turkey (*Meleagris gallopavo*) died shortly after it was discovered in Martin County, North Carolina (USA). The 4.3-kg female turkey appeared in good condition with no visible external lesions or evidence of injury. There were 2- to 5-mm yellow-white plaques on the mucosal surfaces of the oral cavity and mid-esophagus. The liver had large, multifocal, irregular pale areas on cut and uncut surfaces. The spleen contained multifocal, pale, hard, nodules. Microscopic changes in the liver consisted of large multifocal coalescing areas of necrosis. Occasional spherical 10 to 15 μ m in diameter organisms consistent with *Histomonas meleagridis* were present in the necrotic areas. Viable hepatic parenchyma contained multifocal infiltrations of numerous mononuclear cells interpreted as neoplastic cells resembling lymphoblasts and plasma cells. Similar neoplastic cell infiltrates, consistent with the lymphoproliferative disease reticuloendotheliosis, were present in spleen, lung, and esophageal and oral mucosa. Reticuloendotheliosis virus, subtype 2, was isolated from samples of liver and spleen.

Key words: Histomoniasis, *Histomonas meleagridis*, blackhead, reticuloendotheliosis, reticuloendotheliosis virus, lymphoproliferative disease, wild turkey, *Meleagris gallopavo*, case report.

Histomoniasis or "blackhead" is a parasitic disease of many gallinaceous birds caused by the protozoan *Histomonas meleagridis*. The involvement of this parasite in diseases of domestic chickens and turkeys is well described (McDougald, 1984). In wild turkeys (*Meleagris gallopavo*), histomoniasis is thought to be an underreported but important mortality factor (Hurst, 1980; Davidson et al., 1985).

There are few accounts of lymphoproliferative diseases in wild turkeys, and none has identified a proven etiology for the observed lesions (Busch and Williams,

1970; Colwell et al., 1973; Grant et al., 1975; Davidson et al., 1985). Herein, we describe the occurrence of histomoniasis and a lymphoproliferative disease, reticuloendotheliosis, in a wild turkey. This report is the first record of the isolation and identification of reticuloendotheliosis virus from a wild turkey.

On 8 January 1988 a moribund free-ranging wild turkey was discovered in Martin County (1.6 km north of Hamilton, North Carolina, USA; 35°58'N, 77°12'W). The turkey was found at the upland hardwood/mixed alluvial hardwood/cypress backswamp ecotone. The upland hardwood habitat is the transition zone between agricultural lands and the bottomlands along the Roanoke River. This zone is 140 m wide, with a slope of 45%. The site was 140 m from the nearest field and 700 m from the Roanoke River. The average annual turkey population density for the area is estimated at 5.0 individuals/100 ha (North Carolina Wildlife Resources Commission, Raleigh, North Carolina 26711, USA).

The turkey died shortly after discovery, and the entire carcass was wrapped in plastic and stored at 4 C until it was transported to the College of Veterinary Medicine, North Carolina State University (Raleigh, North Carolina 27606, USA) and necropsied on 19 January 1988. The turkey was a 4.3-kg bearded female with no visible external lesions or evidence of injury. There was a slight amount of dry sulfur-colored droppings pasted to the vent feathers. On the oral cavity mucosa, there was a 5-mm in diameter, slightly raised yellow-white plaque; and similar lesions were found on the mucosa of the choanal cleft

and mid-esophagus. The mucosal surface of the crop was normal except for a thickened focal area that appeared to be a healed ulcer or penetrating wound. The uncut surface of the liver had large, multifocal, irregular, pale areas but did not appear enlarged or swollen. The cut surface indicated these lesions throughout. The spleen surface had a mottled appearance and upon palpation hard, irregular nodules were noted. There were no other visible gross lesions. Tissue samples of oral mucosa, esophagus, crop, liver, spleen, lung, kidney and intestines (duodenum, jejunum, ileum, ileocecal junction and colorectum) were fixed in 10% neutral-buffered formalin, processed for histological examination using standard techniques, and sections were stained with hematoxylin and eosin. Representative paraffin-embedded tissues have been deposited in the Registry of Comparative Pathology, Armed Forces Institute of Pathology, Washington, D.C. 20306, USA; accession number 2202885. Samples of spleen and liver were frozen at -70°C pending the results of microscopic examinations.

Tissues examined microscopically had various degrees of autolysis, but were remarkably well preserved considering the time elapsed before fixation. Microscopic changes in the liver consisted of large multifocal coalescing areas of necrosis evidenced by increased cytoplasmic eosinophilia and pyknotic and karyorrhectic nuclei. Numerous thrombi consisting of fibrin and thrombocytes were present in the small and medium-sized hepatic vessels. Occasional spherical 10 to 15 μm in diameter organisms consistent with *Histomonas meleagridis* were present in necrotic areas. Small numbers of heterophils and macrophages were scattered in the cellular debris. The cecal sections examined contained no lesions that could be ascribed to *H. meleagridis*. In the distal small intestine, a focus of necrosis surrounded by zones of heterophils, macrophages and fibroblasts was present in the submucosa which was interpreted to be

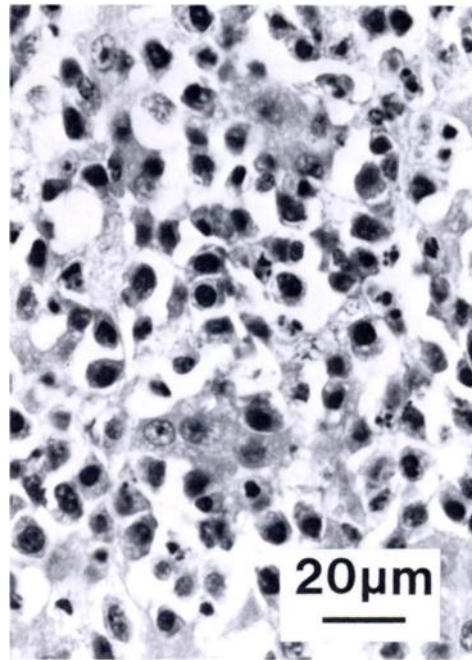


FIGURE 1. Liver from a wild turkey showing neoplastic cell infiltrates within sinusoids causing compression of hepatocytes. H&E.

due to *H. meleagridis*; however, no definitive organisms could be identified.

Also in the liver, adjacent to the necrotic areas, was viable hepatic parenchyma which contained multifocal infiltrations of neoplastic cells which caused compression or obliteration of adjacent hepatic cords (Fig. 1). These cells were large and oval with deeply amphophilic cytoplasm and central or eccentric nuclei. The chromatin of these cells was coarsely clumped and occasional mitotic figures were present.

Lesions within the spleen consisted of multiple foci of neoplastic cell infiltrates which consisted of cells morphologically similar to those cells present in the liver. Similar aggregates of neoplastic cells were present in the parenchyma of the lung. In the esophageal and oral mucosa, there were multifocal areas of necrosis of surface epithelium with associated serocellular debris covering the ulcerated surface. Variable numbers of infiltrating heterophils were present in these areas. Subjacent to

these ulcerations were multifocal collections of neoplastic cells similar to those present elsewhere.

A diagnosis of histomoniasis was supported by the presence of sulfur-colored droppings pasted to the vent feathers, the gross appearance of the liver, and microscopic identification of organisms associated with typical hepatic lesions (Hurst, 1980; McDougald, 1984). However, cecal lesions of histomoniasis were not observed in this case, perhaps due to their mild occurrence, obstruction by postmortem changes, or the lack of representative samples for histologic evaluation.

Gross and microscopic observations indicated the additional diagnosis of a virus-induced avian lymphoproliferative disease. Therefore, previously frozen (-70°C) samples of liver and spleen were homogenized in tissue-culture medium and inoculated onto chicken embryo fibroblast (CEF) cultures for virus assay (Witter et al., 1981; Witter and Johnson, 1985). Chicken embryo fibroblast cultures were examined for reticuloendotheliosis (RE) viral antigens by indirect immunofluorescence (Witter et al., 1970) using RE virus-specific monoclonal antibody (MCA) 11A25 (Cui et al., 1986). Reticuloendotheliosis virus was identified in samples of both spleen and liver. Reticuloendotheliosis virus in CEF culture supernatant fluids was serotyped (Chen et al., 1987) with MCA's (Cui et al., 1986). The RE virus isolate, designated 557, reacted with MCA 11A25 but not with 11C100 or 11C237, which placed the isolate in subtype 2 (Chen et al., 1987).

Reticuloendotheliosis virus is an avian retrovirus capable of inducing runt disease syndrome, and chronic neoplastic disease in susceptible avian hosts (Witter, 1984). Natural hosts for RE virus infection include turkeys, chickens, ducks, geese, and Japanese quail; however, the turkey has most frequently been observed with evidence of disease (Witter, 1984). Reticuloendotheliosis is one of the avian lymphoproliferative diseases that include

Marek's disease (MD) of chickens, caused by a herpesvirus; the leukoses, sarcomas, and related neoplasms of chickens, caused by closely related retroviruses; and lymphoproliferative disease (LPD) of turkeys caused by a retrovirus that is distinct from both the REV and leukosis/sarcoma groups (Calnek, 1984). Few reports exist on the natural occurrence of lymphoproliferative diseases in wild turkeys (Busch and Williams, 1970; Davidson et al., 1985), and none has identified an etiology known to cause tumors in naturally infected hosts. Therefore, while Marek's disease-like lesions have been described (Busch and Williams, 1970), and herpesviruses related to MD viruses have been isolated from wild turkeys (Colwell et al., 1973; Grant et al., 1975), there is no evidence of an etiological relationship between herpesviruses of wild or domestic turkeys and lymphoproliferative lesions (Witter 1972; Colwell et al., 1973; Grant et al., 1975).

The etiology of avian lymphoproliferative diseases cannot be established on gross lesions and histopathology alone. Therefore, a presumptive diagnosis of reticuloendotheliosis should be confirmed by virus isolation or antibody identification. Since RE virus, unlike the avian leukosis/sarcoma viruses and herpesviruses, is not ubiquitous in its natural hosts, its presence normally has diagnostic value (Witter, 1984). The relative importance of RE as a population determinant of wild turkeys can only be ascertained by further research and diagnostic vigilance.

Resources used to support this research were provided in part by the State of North Carolina.

LITERATURE CITED

- BUSCH, R. H., AND L. E. WILLIAMS, JR. 1970. A Marek's disease-like condition in Florida turkeys. *Avian Diseases* 14: 550-554.
- CALNEK, B. W. 1984. Neoplastic diseases. In *Diseases of poultry*, 8th ed., H. J. Barnes, B. W. Calnek, W. M. Reid, and H. W. Yoder, Jr. (eds.). Iowa State University Press, Ames, Iowa, pp. 323-325.
- CHEN, P.-Y., Z. CUI, L. F. LEE, AND R. L. WITTER.

1987. Serologic differences among nondefective reticuloendotheliosis viruses. *Archives of Virology* 93: 233-245.
- COLWELL, W. M., C. F. SIMPSON, L. E. WILLIAMS, JR., AND D. J. FORRESTER. 1973. Isolation of a herpesvirus from wild turkeys in Florida. *Avian Diseases* 17: 1-11.
- CUI, Z., L. F. LEE, R. F. SILVA, AND R. L. WITTER. 1986. Monoclonal antibodies against avian reticuloendotheliosis virus: Identification of strain-specific and strain-common epitopes. *Journal of Immunology* 136: 4233-4242.
- DAVIDSON, W. R., V. F. NETTLES, C. E. COUVILLION, AND E. W. HOWERTH. 1985. Diseases diagnosed in wild turkeys (*Meleagris gallopavo*) of the southeastern United States. *Journal of Wildlife Diseases* 21: 386-390.
- GRANT, H. G., K. D. LEY, AND C. F. SIMPSON. 1975. Isolation and characterization of a herpesvirus from wild turkeys (*Meleagris gallopavo osceola*) in Florida. *Journal of Wildlife Diseases* 11: 562-565.
- HURST, G. A. 1980. Histomoniasis in wild turkeys in Mississippi. *Journal of Wildlife Diseases* 16: 357-358.
- MCDUGALD, L. R. 1984. Other protozoan diseases of the intestinal tract. *In Diseases of poultry*, 8th ed., H. J. Barnes, B. W. Calnek, W. M. Reid, and H. W. Yoder, Jr. (eds.). Iowa State University Press, Ames, Iowa, pp. 717-727.
- WITTER, R. L. 1972. Turkey herpesvirus: Lack of oncogenicity for turkeys. *Avian Diseases* 16: 666-670.
- . 1984. Reticuloendotheliosis. *In Diseases of poultry*, 8th ed., H. J. Barnes, B. W. Calnek, W. M. Reid, and H. W. Yoder, Jr. (eds.). Iowa State University Press, Ames, Iowa, pp. 406-417.
- , AND D. C. JOHNSON. 1985. Epidemiology of reticuloendotheliosis virus in broiler breeder flocks. *Avian Diseases* 29: 1140-1154.
- , AND H. G. PURCHASE, AND G. H. BURGOYNE. 1970. Peripheral nerve lesions similar to those of Marek's disease in chickens inoculated with reticuloendotheliosis virus. *Journal of the National Cancer Institute* 45: 567-577.
- , E. J. SMITH, AND L. B. CRITTENDEN. 1981. Tolerance, virus shedding, and neoplasia in chickens infected with non-defective reticuloendotheliosis viruses. *Avian Diseases* 25: 374-394.

Received for publication 7 September 1988.