



PULMONARY LESIONS IN DISSEMINATED VISCERAL COCCIDIOSIS OF SANDHILL AND WHOOPING CRANES

Authors: Novilla, Meliton N., Carpenter, James W., Jeffers, Thomas K., and White, Sandy L.

Source: Journal of Wildlife Diseases, 25(4) : 527-533

Published By: Wildlife Disease Association

URL: <https://doi.org/10.7589/0090-3558-25.4.527>

BioOne Complete (complete.BioOne.org) is a full-text database of 200 subscribed and open-access titles in the biological, ecological, and environmental sciences published by nonprofit societies, associations, museums, institutions, and presses.

Your use of this PDF, the BioOne Complete website, and all posted and associated content indicates your acceptance of BioOne's Terms of Use, available at www.bioone.org/terms-of-use.

Usage of BioOne Complete content is strictly limited to personal, educational, and non - commercial use. Commercial inquiries or rights and permissions requests should be directed to the individual publisher as copyright holder.

BioOne sees sustainable scholarly publishing as an inherently collaborative enterprise connecting authors, nonprofit publishers, academic institutions, research libraries, and research funders in the common goal of maximizing access to critical research.

PULMONARY LESIONS IN DISSEMINATED VISCERAL COCCIDIOSIS OF SANDHILL AND WHOOPING CRANES

Meliton N. Novilla,¹ James W. Carpenter,² Thomas K. Jeffers,¹ and Sandy L. White¹

¹ Lilly Research Laboratories, A Division of Eli Lilly and Company, Greenfield, Indiana 46140, USA

² Patuxent Wildlife Research Center, U.S. Fish and Wildlife Service, Laurel, Maryland 20708, USA

ABSTRACT: Fifty cranes, consisting of 46 sandhill (*Grus canadensis*) and four whooping cranes (*Grus americana*), were studied. Eighteen sandhill cranes and the four whooping cranes were naturally infected with disseminated visceral coccidiosis (DVC). The remaining sandhill cranes were chicks experimentally infected with oocysts of *Eimeria reichenowi* and/or *E. gruis*; five chicks served as controls. There were no clinical signs attributed to respiratory infection. Necropsy of naturally infected adult birds revealed nodules in many organs, including the lung, air sacs, trachea and nares. Artificially infected sandhill cranes and the whooping crane chicks that died from DVC had congestion and consolidated areas in the lung with frothy fluid in the airways. Grossly visible nodules were observed from 10 days postinoculation. Granulomatous pneumonia and tracheitis were observed with light microscopy. Lesions were associated with merogonic and gametogonic stages of eimerian coccidia. Granulomas and granulomatous foci contained parasitized large mononuclear cells. Merogonic stages were seen in lymphoid cells by ultrastructural examination. Oocysts were observed in the trachea and bronchial mucosa and admixed with exudate in the airways, indicating that crane eimerians can complete their life cycle at these sites. Of the few eimeriid coccidia that have extraintestinal stages of development in birds and mammals, only the species in cranes complete their life cycle in both the digestive and respiratory tracts.

Key words: Coccidia, *Eimeria reichenowi*, *Eimeria gruis*, cranes, extraintestinal lesions, disseminated visceral coccidiosis, pulmonary pathology, pathology.

INTRODUCTION

The coccidians *Eimeria gruis* and *Eimeria reichenowi* are common parasites of whooping cranes (*Grus americana*) and five subspecies of sandhill cranes (*Grus canadensis*) in North America (Courtney et al., 1975; Forrester et al., 1978). Although *Eimeria* spp. infections are generally diseases of the intestinal tract (Pellerdy, 1974), disseminated visceral coccidiosis (DVC) was recognized as a disease entity at the Patuxent Wildlife Research Center (Laurel, Maryland 20708, USA; subsequently referred to as the Center) in 1978-1979 (Carpenter et al., 1979). In DVC, granulomatous nodules may form in many tissues and organs or may result in bronchopneumonia, hepatitis, myocarditis, splenitis, and enteritis; the disease has resulted in death of a number of whooping and sandhill cranes, especially those <2-wk-old (Carpenter et al., 1980, 1984).

Because cranes produced at the Center are released to augment wild populations, studies involving both experimentally induced and natural infections have been

conducted over the last 9 yr to learn more about the life cycle and pathogenicity of these unique coccidian parasites. The purpose of this paper is to describe the clinical signs and the gross and microscopic findings in the respiratory system of cranes affected with DVC.

MATERIALS AND METHODS

Naturally infected cranes

Lungs of sandhill and whooping cranes collected from 1973 were examined retrospectively. These included 14 captive sandhill cranes, and one adult and three whooping crane chicks that were necropsied at the Center, and four other sandhill cranes collected from the Jasper Pulaski Fish and Wildlife Area (Medaryville, Indiana 47957, USA). All birds were known or suspected, in retrospect, to have been infected with *Eimeria* spp.

Experimentally infected birds

Six 5- to 8-day-old chicks were placed in an outdoor pen where deaths from DVC had occurred; four of the six birds had access to contaminated soil at all times while the remaining two chicks were in an uncontaminated, carpeted enclosure within the same pen as described earlier (Novilla et al., 1981). Lungs and trachea from 19 sandhill crane chicks administered *E.*

reichenowi and *E. gruis* (11 birds), or *E. reichenowi* (8 birds) from 1978 to 1983, were studied. In 1978 two sandhill cranes at 2 to 3 wk of age were given 10×10^3 oocysts of a pooled mixture of *E. reichenowi* and *E. gruis* (4 to 1 ratio) of these two species, respectively. In 1979, three sandhill cranes were used as controls and one each were given the above oocyst mixture at a dose rate of 0.5×10^3 , 1×10^3 , 5×10^3 and 10×10^3 oocysts, respectively. Additionally, five sandhill cranes at 4 wk of age were given a dose of 20×10^3 oocysts. Loss of *E. gruis* during prolonged storage of oocyst suspension provided inoculum of *E. reichenowi* for the 1983 study. Oocyst doses of 325×10^3 , 130×10^3 , 65×10^3 and 32.5×10^3 were administered orally via a flexible stomach tube, respectively, to 1, 2, 2 and 3 sandhill cranes at 2 wk of age. The interval between dosing and euthanasia or death was 0.3, 3, 5, 7, 8, 9, 10, 14, 20, 28, and 49 days for 1, 2, 1, 1, 2, 3, 3, 2, 1, 1, and 2 treated birds, respectively. Three control birds were euthanatized for necropsy at 79 days of age.

At the time of necropsy, blood and tissue smears were made of the lung, as well as various other organs. Smears were wet-fixed in Bouin's solution and stained overnight in double-strength Giemsa (pH 7.2). Tissues for light microscopy were collected into 10% buffered neutral formalin, dehydrated, embedded in paraffin and stained with Harris' hematoxylin and eosin. Special stains such as Giemsa, Whipf's polychrome, and the McManus method for glycogen-PAS were used as needed (Luna, 1968).

Samples for transmission electron microscopy were collected in Trump's universal fixative and processed immediately (McDowell, 1978). These were postfixed in 2% osmium tetroxide, dehydrated through a graded series of ethanol solutions, and embedded in Polybed/812* (Polysciences, Inc., Warrington, Pennsylvania 18976, USA). Areas for ultrastructural evaluation were selected from semithin sections ($0.5 \mu\text{m}$) stained with toluidine blue. Ultrathin sections were placed directly on uncoated copper grids, stained with uranyl acetate and lead citrate and examined with a Philips 201 electron microscope (Philips Electronics Inst., Inc., A North American Philips Company, Mahwah, New Jersey 07430, USA).

RESULTS

Clinical signs and parasitology

Clinical signs of DVC were not observed in naturally infected adult sandhill cranes. The single naturally infected adult whooping crane was lethargic and had severe

diarrhea. Two whooping crane chicks were found dead without any prodromal signs, and the other chick was killed in extremis. Artificially infected sandhill crane chicks manifested progressive weakness, emaciation, greenish diarrhea and recumbency before death.

Repeated sampling of feces from naturally infected sandhill cranes for coccidial oocysts yielded *E. reichenowi* and *E. gruis*. A whooping crane sample yielded only *E. reichenowi*-type oocysts. In artificially infected sandhill crane chicks, oocysts were found in fecal samples from the 12th day postinfection (PI). Trophozoites or young schizonts were observed in tissue impression smears from 5 days PI found primarily in the intestines followed by the liver, spleen and lungs. Peripheral blood smears were positive in some birds from 9 days PI with large merozoites observed in the cytoplasm of monocytes and/or lymphocytes.

Gross pathology

Fourteen of the 18 adult sandhill cranes were euthanatized for necropsy at the Center. The remaining birds, from the Jasper Pulaski Fish and Wildlife Area were either found dead, incapacitated, shot or captured. Parasite granulomas were the predominantly observed gross lesion, first seen in the oral cavity as 0.5 to 3.0 mm in diameter grayish-white nodules. Nodules of similar size were disseminated throughout tissues and organs, including the lungs, air sacs, trachea and nares. The only other gross lesion in adult sandhill cranes was congestion of the anterior portion of the intestines.

The adult whooping crane was thin and dehydrated. Postmortem findings were urate deposits on the heart and kidneys, mottling of the liver and distension of the gall bladder. The lungs were unremarkable in the adult and in one whooping crane chick; in two other whooping crane chicks, there was consolidation of the lungs and frothy fluid in the airways. The tra-

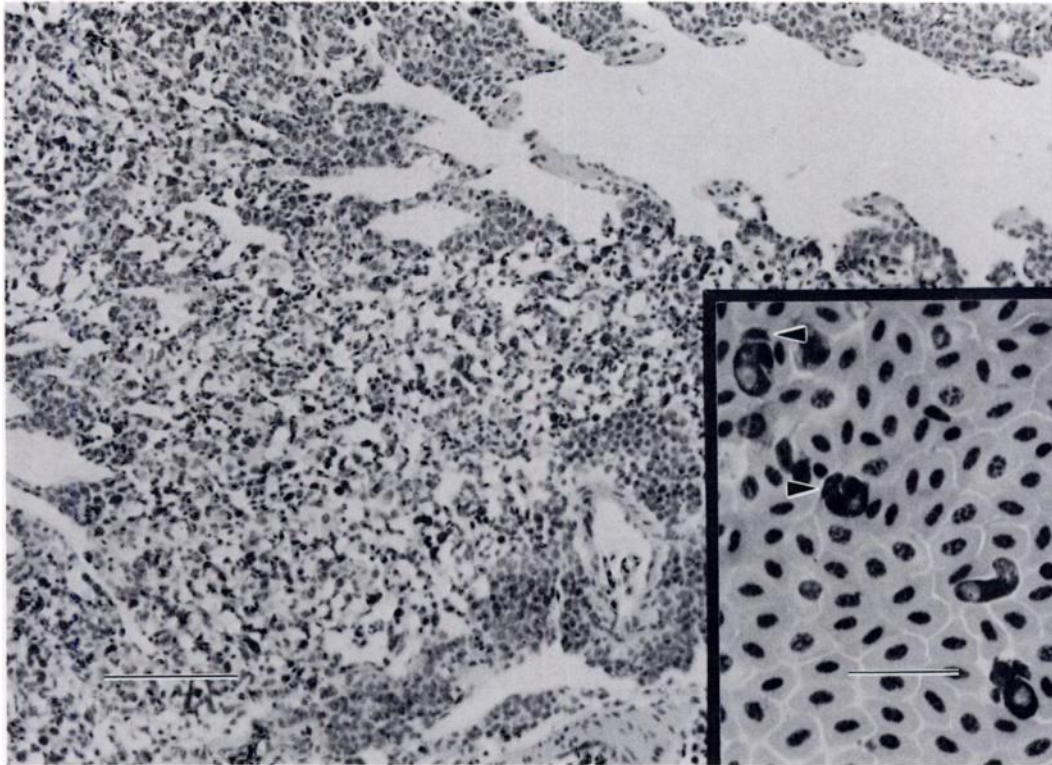


FIGURE 1. Lung section from a sandhill crane chick 10 days after artificial infection with *Eimeria reichenowi* showing interstitial and perivascular infiltration with large mononuclear cells. H&E. Bar = 100 μ m. Inset is a lung impression smear from the same bird with large merozoites displacing host nuclei (arrowheads). Giemsa. Bar = 25 μ m.

chea and bronchi contained several gapeworms (*Cyathostoma coscorobae*).

None of the four sandhill crane chicks exposed to contaminated soil died during the 4 wk observation period. At necropsy, two birds had congested and edematous lungs, and one had gapeworms in the trachea. Three of the 11 birds artificially infected with pooled oocysts died. Lesions typical of DVC including hyperemia of the intestines, mottled liver and spleen, congested lungs and orange-white granulomas were observed in many birds. Of the eight birds inoculated with *E. reichenowi*, all that were alive past 7 days PI were thin; one died 10 days PI and three were moribund and euthanatized at 9 and 10 days PI. At necropsy, there was slight hepatosplenomegaly with multiple white

foci and pulmonary congestion and edema. In both studies, dose and time factors and concurrent gapeworm infection probably influenced the abundance, distribution and severity of lesions.

Histopathology

The basic tissue alteration in DVC was granulomatous inflammation with focal aggregates of lymphocytes and macrophages laden with coccidial stages in many tissues and organs, including those of the respiratory system. In adult sandhill cranes, the most consistent lesions in the lungs were small to large lymphoid aggregates around or near blood vessels and slight infiltration of mononuclear cells in some lobules. The granulomatous infiltrates in the lung and other tissues were composed principally of

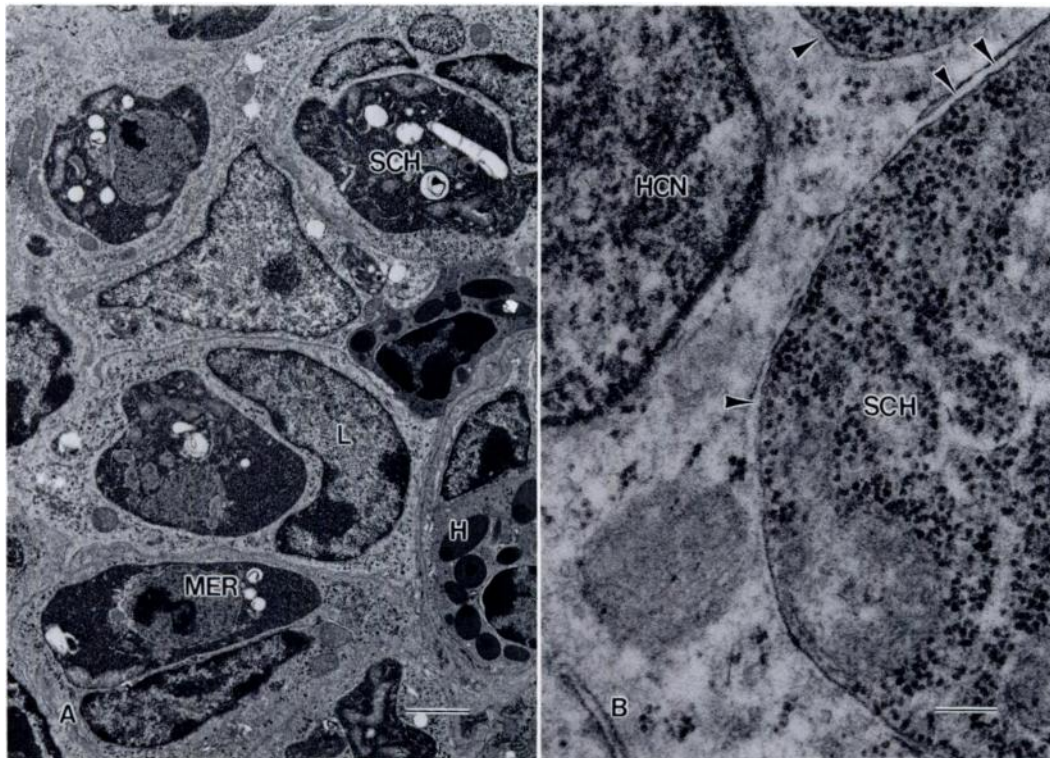


FIGURE 2. Electron micrographs of lung granuloma from a sandhill crane chick artificially infected with *E. reichenowi*. The chick was moribund and killed for necropsy 10 days PI. A. Heterophils (H) and lymphoid cells (L) contain merozoites (MER) and developing schizont (SCH). B. Developing schizont in a parasitophorous vacuole (arrowheads). HCN = host cell nucleus. Uranyl acetate and lead citrate. Bars: A = 1 μ m, B = 0.1 μ m.

epithelioid cells, many of which contained uninucleated and multinucleated meronts. They were highly vascularized, infiltrated by lymphocytes and some heterophils and not surrounded by a fibrous capsule.

In artificially infected sandhill crane chicks, there were no lung lesions until 5 days PI. At this time, small focal aggregates of mononuclear cells were observed in the lung parenchyma. Over the next 5 days, vasculitis developed with transmural and perivascular infiltration of MNC which contained developing meronts (Fig. 1). The cellular aggregates increased in size and number; some mitotic figures were present, and the individual cells were larger and had a blastic appearance. Most of the cells that formed the granulomas contained uninucleated and multinucleated organisms.

Ultrastructural studies showed that the predominant cell type which were parasitized were large mononuclear cells. These cells resembled large lymphocytes or monocytes (Fig. 2A). They had a large electron translucent nucleus, surrounded by a double membrane with irregular outlines often indented by the developing parasite. The intracellular parasites were within a parasitophorous vacuole (Fig. 2B). Nuclear chromatin was clumped with focal peripheral condensation. The relatively abundant cytoplasm was electron translucent and contained mitochondria, rough and smooth endoplasmic reticulum, Golgi apparatus, centrioles, polyribosomes and, occasionally, lysosomes.

There was widespread merogony by 9 days PI. Parasitemia was evident with many infected mononuclear cells in blood

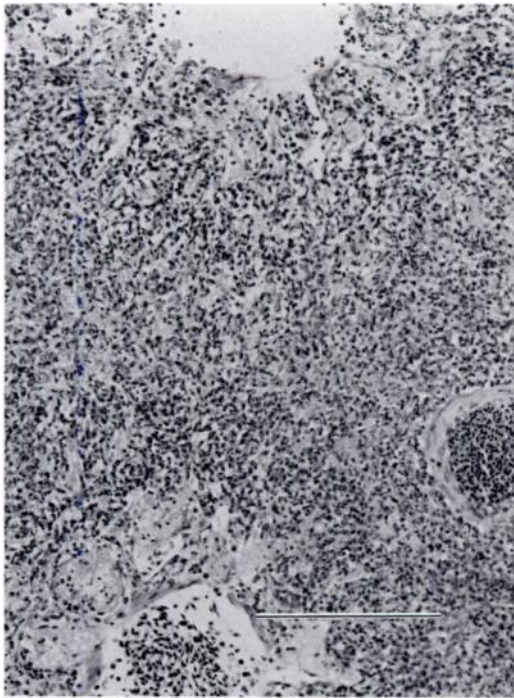


FIGURE 3. Moderate granulomatous pneumonia in a sandhill crane chick 14 days after artificial infection with *E. reichenowi*. H&E. Bar = 200 μ m.

vessels and lymphatics. A focal necrotizing reaction occurred in some lobules of the lung with accumulation of variable proteinaceous exudate in parabronchial lumens, atriae and infundibulae (Fig. 3). All birds that died or were euthanatized in extremis and one bird euthanatized after 21 days of exposure to oocyst-contaminated soil had granulomatous pneumonia and tracheitis. Gamonts and oocysts were found in the respiratory epithelium lining the trachea and primary bronchi from 14 days PI (Fig. 4). There was cellular infiltration by lymphocytes, macrophages, and some heterophils and desquamation of infected cells into the lumen. One of six sandhill crane chicks exposed to contaminated soil had a concurrent infection with gapeworms. This bird had large amounts of mucocellular exudate mixed with oocysts and gamonts in the primary bronchi. Similar changes were found in the lungs of two naturally infected whooping crane

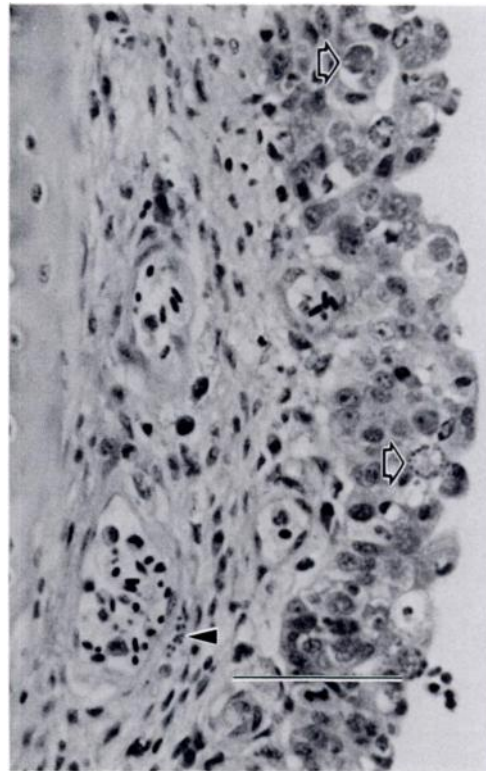


FIGURE 4. Section of primary bronchus from a sandhill crane chick killed for necropsy 24 days after exposure to *Eimeria* spp. infected pen. Note gamonts in bronchial epithelium (open arrows) and merozoites in the submucosa (arrowhead). PAS. Bar = 50 μ m.

chicks which were concurrently infected with gapeworms (Fig. 5).

Parasite granulomas in the lung of birds necropsied before 20 days PI were small and contained only uninucleated organisms. Subsequently, well-developed granulomas were found and were most numerous by 49 days PI (Fig. 6). These granulomas had similar morphology as those found in naturally infected cranes.

DISCUSSION

Extraintestinal development of *E. reichenowi* (and possibly *E. gruis*) has been reported in captive sandhill cranes and whooping cranes and wild sandhill cranes (Novilla et al., 1981). Merogony occurs in many tissues and organs; primarily meronts occur within mononuclear phagocytes where they do not appear to be destroyed

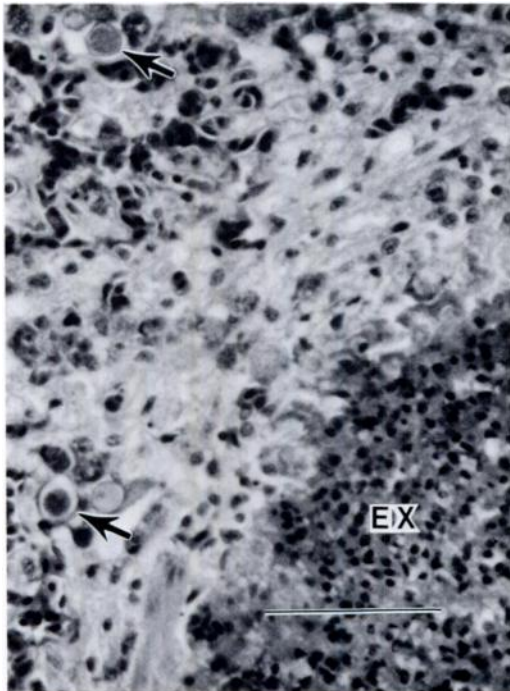


FIGURE 5. Lung section from a whooping crane chick that died from disseminated visceral coccidiosis. Note mucocellular exudate in parabronchial lumen (EX) with gamonts and oocysts (arrows) in parenchyma. H&E. Bar = 100 μ m.

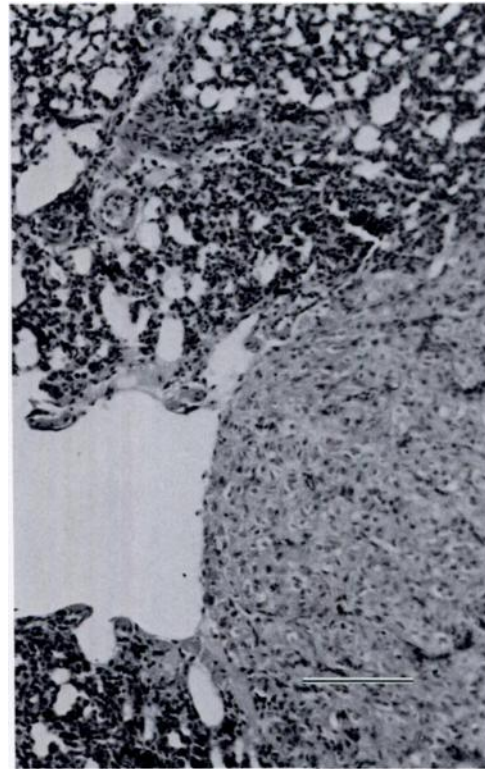


FIGURE 6. Lung granuloma with many intracytoplasmic meronts from a sandhill crane killed for necropsy 49 days after artificial infection with *E. reichenowi*. H&E. Bar = 100 μ m.

by the host cells. Morphologically, these cells resembled large lymphocytes or monocytes, but since their identification was equivocal, the more encompassing term, "lymphoid cell," may be used (Meader and Landers, 1967; Bjerregaard, 1975) until the immunohistologic demonstration of cytoplasmic and cell surface antigens to identify phenotypes are completed.

The basic host response to DVC in young sandhill cranes and whooping cranes is granulomatous inflammation. Changes in the respiratory system are primarily due to infiltration of lymphoid cells laden with developing asexual stages of the crane eimeria. The consequent rupture and death of infected cells initiates a necrotizing and/or granulomatous pneumonia, tracheitis, and air sacculitis. In experimentally infected sandhill crane chicks, morbidity and

death occurred at the peak of merogony (9 to 11 days PI). The widespread merogony is directly responsible for the development of clinical disease and mortality in young cranes of both species in the wild. By 14 days PI, gamonts and oocysts are present in respiratory epithelium, indicating that crane eimerians can complete their life cycle in both respiratory and digestive tracts.

In adult sandhill cranes, focal aggregates of lymphoid cells and granulomatous nodules in many tissues, including the lungs, air sacs, trachea and nares, are the main lesions. Except for the one adult captive whooping crane that died, probably from complications of dehydration, renal impairment and visceral gout, no captive adult cranes died from naturally occurring DVC. Thus, cranes, as they mature, appear

to be able to tolerate the eimerian coccidia, and a chronic infection develops. In a previous survey, juvenile sandhill cranes had a higher prevalence and greater number of granulomas than did adult cranes (Carpenter et al., 1984). The granulomas that are found in many tissues and organs have been proposed as source of merozoites that prolong the infection (Novilla et al., 1981). The inherent ability of the crane eimerians to complete their life cycle in extraintestinal sites and the establishment of a chronic infection tolerated by their migratory hosts reflect the adaptation that may be necessary for their survival in nature.

ACKNOWLEDGMENTS

The authors thank R. A. Bendele, W. L. Current, W. J. Griffing, T. R. Spraker, R. Fayer, and G. F. Gee for their help and encouragement and K. A. Wightman, N. J. Mann, C. E. Sullivan, B. I. Williams, B. Shipley, R. Knopp and M. Weber for their excellent technical assistance.

LITERATURE CITED

- BJERREGAARD, R. S. 1975. Lymphoid cells in chicken intestinal epithelium. *Cell Tissue Research* 161: 485-495.
- CARPENTER, J. W., M. N. NOVILLA, R. FAYER, AND G. C. IVERSON. 1984. Disseminated visceral coccidiosis in sandhill cranes. *Journal of the American Veterinary Medical Association* 185: 1342-1346.
- , T. R. SPRAKER, C. H. GARDINER, AND M. N. NOVILLA. 1979. Disseminated granulomas caused by an unidentified protozoan in sandhill cranes. *Journal of the American Veterinary Medical Association* 175: 948-951.
- , ———, AND M. N. NOVILLA. 1980. Disseminated visceral coccidiosis in whooping cranes. *Journal of the American Veterinary Medical Association* 177: 845-848.
- COURTNEY, C. H., D. J. FORRESTER, J. W. ERNST, AND S. A. NESBITT. 1975. Coccidia of sandhill cranes, *Grus canadensis*. *The Journal of Parasitology* 61: 695-699.
- FORRESTER, D. J., J. W. CARPENTER, AND D. R. BLANKINSHIP. 1978. Coccidia of whooping cranes. *Journal of Wildlife Diseases* 14: 24-27.
- LUNA, L. G. 1968. *Manual of histologic staining methods of the Armed Forces Institute of Pathology*, 3rd ed. McGraw-Hill, New York, New York, 258 pp.
- MCDOWELL, E. M. 1978. Fixation and processing. *In* *Diagnostic electron microscopy*, Vol. 1, B. F. Trump and R. J. Jones (eds.). John Wiley and Sons, New York, New York, pp. 113-140.
- MEADER, R. D., AND D. F. LANDERS. 1967. Electron and light microscopic observations on the relationships between lymphocytes and intestinal epithelium. *American Journal of Anatomy* 121: 763-774.
- NOVILLA, M. N., J. W. CARPENTER, T. R. SPRAKER, AND T. K. JEFFERS. 1981. Parenteral development of eimerian coccidia in sandhill and whooping cranes. *Journal of Protozoology* 28: 248-255.
- PELLERDY, L. 1974. *Coccidia and coccidiosis*, 2nd ed. Paul Parey, Berlin, Federal Republic of Germany, 959 pp.

Received for publication 11 January 1989.