

Thyroid Follicular Carcinoma with Pulmonary Metastases in a Beaver (*Castor canadensis*)

Authors: Anderson, Wayne I., Schlafer, Donald H., and Vesely, Keith R.

Source: Journal of Wildlife Diseases, 25(4) : 599-600

Published By: Wildlife Disease Association

URL: <https://doi.org/10.7589/0090-3558-25.4.599>

BioOne Complete (complete.BioOne.org) is a full-text database of 200 subscribed and open-access titles in the biological, ecological, and environmental sciences published by nonprofit societies, associations, museums, institutions, and presses.

Your use of this PDF, the BioOne Complete website, and all posted and associated content indicates your acceptance of BioOne's Terms of Use, available at www.bioone.org/terms-of-use.

Usage of BioOne Complete content is strictly limited to personal, educational, and non - commercial use. Commercial inquiries or rights and permissions requests should be directed to the individual publisher as copyright holder.

BioOne sees sustainable scholarly publishing as an inherently collaborative enterprise connecting authors, nonprofit publishers, academic institutions, research libraries, and research funders in the common goal of maximizing access to critical research.

Thyroid Follicular Carcinoma with Pulmonary Metastases in a Beaver (*Castor canadensis*)

Wayne I. Anderson, Donald H. Schlafer, and Keith R. Vesely, Department of Pathology, New York State College of Veterinary Medicine, Cornell University, Ithaca, New York 14853, USA

ABSTRACT: An 11-yr-old female beaver (*Castor canadensis*) died after a 3½ mo course of intermittent diarrhea, lethargy and anorexia. A postmortem examination revealed both a necrotizing ulcerative colitis and bilaterally enlarged thyroid glands. Histologically, the necrotizing colitis was similar to that caused by canine or feline parvovirus. Thyroid glands were multilobulated. Lobules were composed of irregularly arranged, variably sized follicles, some of which contained colloid. Follicles were lined by a pleomorphic population of tall cuboidal to columnar epithelial cells. Capsular invasion was present. Similar cells, forming follicles were present within the pulmonary parenchyma. This is the first documented case of a thyroid follicular carcinoma with pulmonary metastases in a beaver.

Key words: Thyroid follicular carcinoma, pulmonary metastases, beaver, *Castor canadensis*, colitis, case history.

Neoplasms of the beaver (*Castor canadensis*) from North America are infrequently documented in the veterinary literature. Previously identified neoplasms include a mandibular periodontal fibroma (Hamerton, 1935), a rhabdomyoma (Dietrich, 1981), and multiple cutaneous papillomas (Carlson and Nielsen, 1983). The present report describes the occurrence of bilateral thyroid follicular carcinoma with pulmonary metastases.

An 11-yr-old female captive-reared beaver died and was presented for postmortem examination following a 3½ mo course of intermittent diarrhea, lethargy and anorexia. Gross examination revealed an emaciated animal with minimal body fat stores. Multiple discrete colonic ulcers (1 mm diameter) were present as was fibrinonecrotic debris adherent to the mucosal surface.

Thyroid glands were bilaterally enlarged. The left and right thyroids measured 6.5 × 4.0 × 3.0 and 5.5 × 4.5 × 3.0 cm, respectively. On cut section, both thy-

roids were roughened, and irregularly lobulated, as was the isthmus. Tracheo-bronchial lymph nodes appeared enlarged and measured 2.0 × 1.0 × 0.7 cm. Gross vascular invasion was not evident, and no other lesions were noted. Tissues were fixed in 10% buffered formalin, routinely processed, sectioned at 4 μm, and stained with haematoxylin and eosin.

Histopathology confirmed the presence of a severe diffuse necrotizing, ulcerative colitis. Dropout of crypts was evident, and the mucosal surface was partially covered by fibrinonecrotic debris. This lesion was

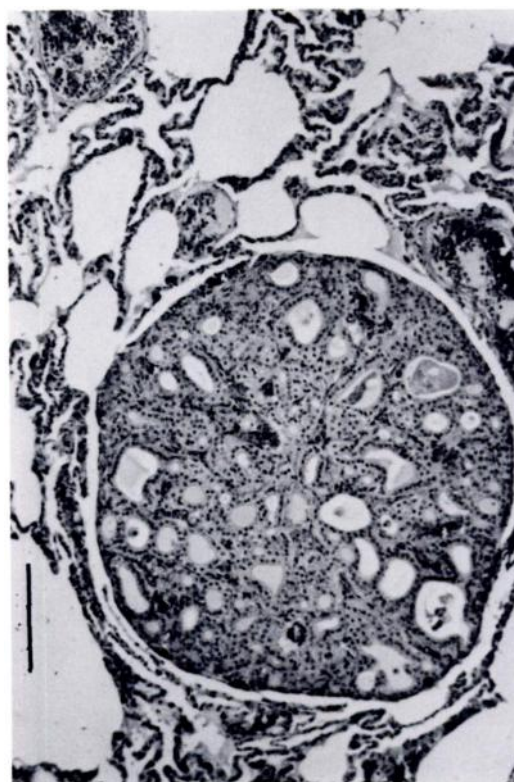


FIGURE 1. Metastatic thyroid follicular carcinoma within the pulmonary parenchyma of a beaver. H&E. Bar = 100 μm.

very similar to that induced by both the feline and canine Parvoviridae. Bacteriology and virology were performed, but a causative agent was not determined.

The thyroid gland parenchyma was composed of multiple discrete lobules separated by thin bands and sheets of a connective tissue stroma. Lobules were composed of randomly arranged, variably sized follicles lined by a pleomorphic population of tall cuboidal to columnar epithelial cells with basally located nuclei. Nuclei were round to slightly ovoid, vesicular and contained one to three nucleoli. Occasional mitotic figures were present. Follicles contained variable amounts of colloid. Follicular epithelial cells were invasive into the overlying capsular wall. Similar cells forming follicles with colloid were present within the pulmonary parenchyma (Fig. 1). Reactive lymphoid hyperplasia was present in lymph nodes, but neoplastic cells were not detected. Representative specimens of tissue blocks from this case are deposited in the Registry of Comparative Pathology (Armed Forces Institute of Pathology, Washington, D.C. 20306, USA; accession number 2185233).

A diagnosis of thyroid follicular carcinoma with pulmonary metastases was made for this case. To our knowledge, the present report represents the first documented case of a thyroid follicular carcinoma with pulmonary metastases in this species. Spontaneous thyroid neoplasm in other rodent species, such as laboratory mice, guinea pigs and hamsters are rare. Generally, such neoplasms are follicular or papillary. In domestic rats, spontaneous thyroid neoplasms are noted more frequently and are primarily parafollicular in origin.

LITERATURE CITED

- CARLSON, B. L., AND S. W. NIELSEN. 1983. Cutaneous papillomatosis in a beaver. *Journal of the American Veterinary Medical Association* 183: 1283-1284.
- DIETRICH, R. 1981. Tumors. *In* Alaskan wildlife diseases, R. Dietrich (ed.). University of Alaska, Fairbanks, Alaska, pp. 236-239.
- HAMERTON, A. E. 1935. Report on the deaths occurring in the society's gardens during 1934. *Proceedings of the Zoological Society of London* 1935: 443.

Received for publication 12 December 1988.