

Toxoplasmosis in Atlantic Bottle-Nosed Dolphins (*Tursiops truncatus*)

Authors: Inskeep, W., Gardiner, C. H., Harris, R. K., Dubey, J. P., and Goldston, R. T.

Source: Journal of Wildlife Diseases, 26(3) : 377-382

Published By: Wildlife Disease Association

URL: <https://doi.org/10.7589/0090-3558-26.3.377>

BioOne Complete (complete.BioOne.org) is a full-text database of 200 subscribed and open-access titles in the biological, ecological, and environmental sciences published by nonprofit societies, associations, museums, institutions, and presses.

Your use of this PDF, the BioOne Complete website, and all posted and associated content indicates your acceptance of BioOne's Terms of Use, available at www.bioone.org/terms-of-use.

Usage of BioOne Complete content is strictly limited to personal, educational, and non-commercial use. Commercial inquiries or rights and permissions requests should be directed to the individual publisher as copyright holder.

BioOne sees sustainable scholarly publishing as an inherently collaborative enterprise connecting authors, nonprofit publishers, academic institutions, research libraries, and research funders in the common goal of maximizing access to critical research.

Toxoplasmosis in Atlantic Bottle-Nosed Dolphins (*Tursiops truncatus*)

W. Inskeep II,¹ C. H. Gardiner,¹ R. K. Harris,¹ J. P. Dubey,² and R. T. Goldston,³ ¹ Department of Veterinary Pathology, Armed Forces Institute of Pathology, Washington, D.C. 20306, USA; ² Zoonotic Diseases Laboratory, Livestock and Poultry Sciences Institute, Agricultural Research Service, U.S. Department of Agriculture, BARC-E, Beltsville, Maryland 20705, USA; ³ Animal Hospital of St. Petersburg, St. Petersburg, Florida 33702, USA

ABSTRACT: A female Atlantic bottle-nosed dolphin (*Tursiops truncatus*) and her calf were found beached on Picnic Island in Tampa Bay, Florida, USA. Despite therapy the animals died. Necropsy revealed severe pneumonia and lymphadenopathy in the mother and the calf, gastric ulcers and infection with the stomach digenean *Braunina cordiformis* in the mother, and a large, pale liver in the calf. *Toxoplasma gondii* was identified by light and electron microscopy and by immunohistochemistry in tissues of both animals. *Toxoplasma gondii* was associated with interstitial pneumonia, necrotizing adrenalitis, and cardiac myonecrosis in the mother and with lymphoid necrosis in both dolphins. The source of infection and the relationship to the recent dolphin beachings along the eastern seacoast of North America are unknown. This is the first report of toxoplasmosis in cetaceans.

Key words: Pneumonia, adrenalitis, cardiac necrosis, *Toxoplasma gondii*, Atlantic bottle-nosed dolphin, *Tursiops truncatus*, case report.

Infection caused by the protozoan parasite *Toxoplasma gondii* is common in many species of homeotherm animals, including humans (Dubey and Beattie, 1988). Members of the carnivore family Felidae are the only known definitive hosts. Although a variety of intermediate hosts are known, marine mammals are rarely included. The prevalence of this ubiquitous protozoan in marine mammals is unknown, but previous reports include toxoplasmosis in a harbor seal (*Phoca vitulina richardii*), a California sea lion (*Zalophus californianus*), a West Indian manatee (*Trichechus manatus*) and a Northern fur seal (*Callorhinus ursinus*) (Van Pelt and Dieterich, 1973; Migaki et al., 1977; Buergetl, 1983; Holshuh et al., 1985). The purpose of this report is to describe the findings in two cases of toxoplasmosis in Atlantic bottle-nosed dolphins (*Tursiops truncatus*).

A female Atlantic bottle-nosed dolphin and her calf were found in December 1987 beached on Picnic Island in Tampa Bay, Florida (27°57'N and 82°27'W). The adult was given squid and fluids orally and was treated with penicillin, dexamethasone and a multivitamin injection; however, she died in approximately 48 hr. The calf was given pyrantel pamoate, penicillin, oral fluids and artificial milk replacer but died within 36 hr. Necropsy revealed severe pneumonia and lymphadenopathy in mother and calf, gastric ulcers and infection with the stomach digenean *Braunina cordiformis* in the mother, and a large, pale liver in the calf. The thymus of the calf was not found at necropsy.

In January 1988, tissues from these two dolphins were submitted to the Department of Veterinary Pathology at the Armed Forces Institute of Pathology (AFIP) (Washington, D.C. 20306, USA) for histopathological evaluation (AFIP Accession Numbers 2153586 and 2153868).

Following fixation in 10% neutral buffered formalin, tissue specimens obtained at necropsy were trimmed and processed by routine paraffin technique and sectioned at 5 μ m. Sections were stained with hematoxylin and eosin for light microscopic examination. For transmission electron microscopy, selected tissues were deparaffinized, hydrated and post fixed in 1% osmium tetroxide; dehydrated, cleared and embedded in epoxy resin. One micron sections were cut and stained in toluidine blue O for preliminary light microscopic examination. Thin sections (80 to 90 nm) were cut and stained with uranyl acetate and lead citrate.

In the adult female there was a diffuse interstitial pneumonia with alveolar ede-

ma and fibrinous exudation (Fig. 1). There were several groups of *T. gondii* tachyzoites in pneumocytes, septal fibrocytes and/or smooth muscle cells, and macrophages within alveolar septa and spaces (Figs. 2, 3, 4). *Toxoplasma gondii* was present within myocardial cells, with associated myonecrosis and degeneration; within the tunica muscularis of the stomach; and within glomeruli (Fig. 5). A mild lymphoid depletion was present in sections of both lymph node and spleen. In one lymph node numerous *T. gondii* tachyzoites were identified within the cytoplasm of a megakaryocyte (Fig. 6). The adrenal glands and lymph nodes had multifocal areas of coagulative necrosis with numerous tachyzoites and a few tissue cysts (Figs. 7, 8, 10, 11, 12). There were areas of fibrosis within the myocardium and areas of hemorrhage and edema within lymph nodes and the spleen.

Additional lesions not related to the *T. gondii* infection were (1) intraluminal gastric adult digeneans identified as *Braunina cordiformis* associated with a superficial necrotizing gastritis; (2) a chronic intramural stomach abscess containing adult digeneans with eggs identified as *Pholeter gastrophilus* (Fig. 9); and (3) within the dermis and subcutis, a multifocal necrotizing vasculitis with associated dermatitis and panniculitis. Numerous ciliated protozoans were found within the skin, with and without associated inflammation (Figs. 13, 14).

In the calf, which was also a female, there was diffuse, mild-to-moderate lymphoid depletion in multiple lymph nodes and the spleen. The lymph nodes had multifocal areas of necrosis with a few *T. gondii* tachyzoites at the interface with viable lymphoid cells. In addition, within lymph node sinuses there were occasional multinucleate giant cells and a mixed population of gram-negative bacilli. There was a diffuse subacute interstitial pneumonia with a multifocal necrogranulomatous bronchitis with gram-negative bacilli

within large foamy macrophages. There was a diffuse fatty change of hepatocytes, which was the cause of the pale liver noted at necropsy, and vacuolar change of renal tubular epithelial cells.

Transmission electron microscopy was performed on the adrenal gland of the adult. Within the cytoplasm of adrenal cortical cells parasitophorous vacuoles contained numerous tachyzoites and a tissue cyst of *T. gondii* (Fig. 10). Endodyogeny was present, and the organisms had a conoid, numerous micronemes, a few rhoptries, a nucleus and a few amylopectin granules (Figs. 11, 12). Sections of adrenal gland from the cow were also evaluated using a peroxidase-antiperoxidase technique and confirmed the diagnosis of toxoplasmosis (Uggla et al., 1987). A pictorial illustration is not included herein because of the lack of contrast with the black and white photograph.

Cats and other Felidae are the only known definitive hosts for *T. gondii*. Intermediate hosts may be infected by (1) ingestion of sporulated oocysts, (2) ingestion of infected tissue or body fluids or (3) congenitally via the placenta. The exact source of the organism in these two dolphins is unknown, but we speculate that the sand and coastal water could easily be contaminated with feline feces containing oocysts of *T. gondii*. In addition, flood water spillage and sewage could also serve as a source of infection for these dolphins. Although the survivability of the organism in the ocean is not known, oocysts survive freezing and drying for several months, and are resistant to numerous disinfectants (Dubey and Beattie, 1988). Considering its durability, survival and transmission of *T. gondii* in an aquatic environment must be considered as a possibility. Moreover, birds, fish, reptiles and amphibians may serve as intermediate/transport hosts; however, only fish are known to be a common dietary component of dolphins (Greene, 1984). Transplacental infections are one of the most common causes of clinical toxo-

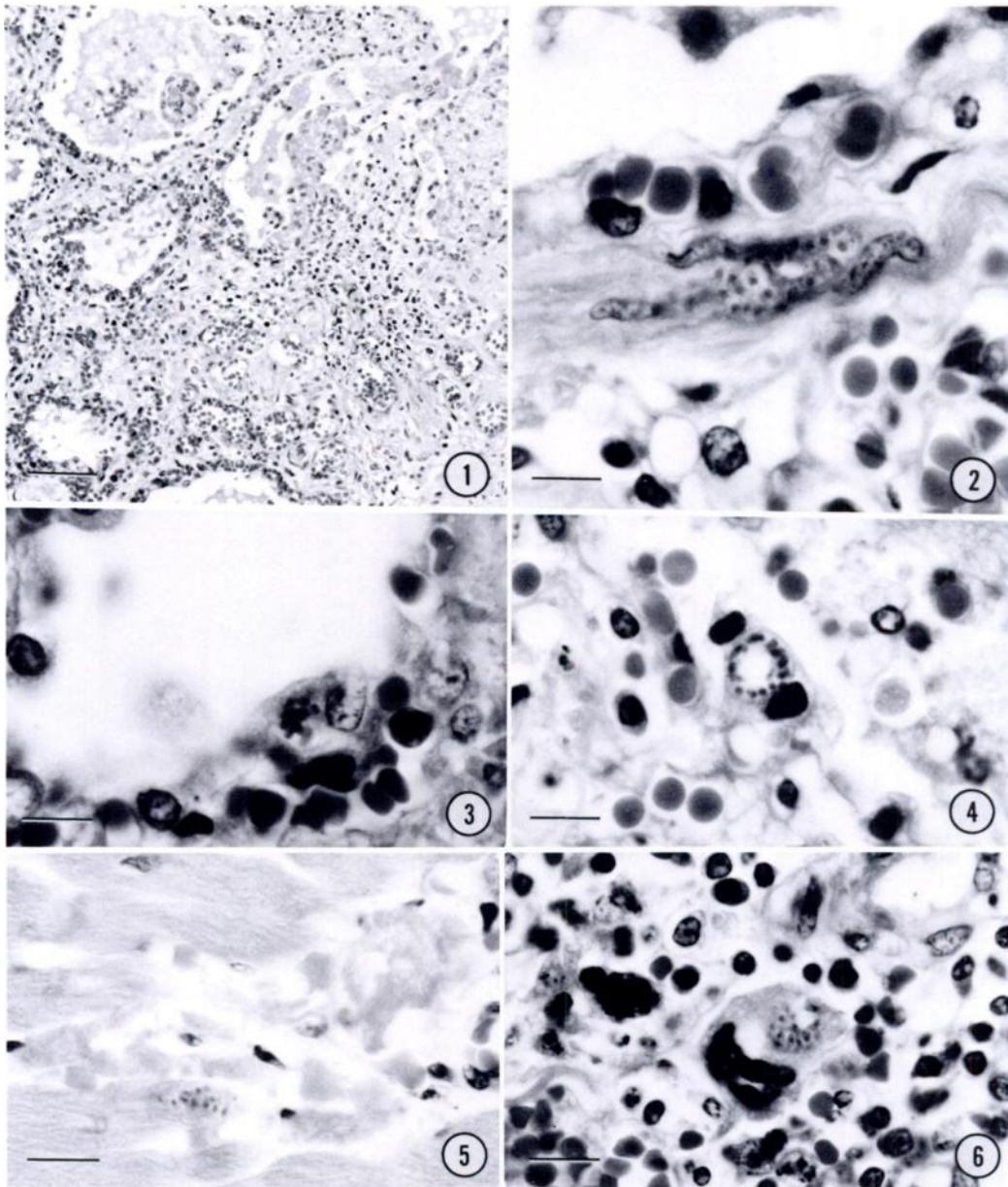


FIGURE 1. Fibrinous interstitial pneumonia in an Atlantic bottle-nosed dolphin. H&E. Bar = 70 μ m.

FIGURE 2. Tachyzoites of *Toxoplasma gondii* in alveolar septal fibrocyte or smooth muscle cell of an Atlantic bottle-nosed dolphin. H&E. Bar = 7 μ m.

FIGURE 3. Tachyzoites of *Toxoplasma gondii* in pneumocyte of an Atlantic bottle-nosed dolphin. H&E. Bar = 10 μ m.

FIGURE 4. Tachyzoites of *Toxoplasma gondii* in pneumocyte of an Atlantic bottle-nosed dolphin. H&E. Bar = 10 μ m.

FIGURE 5. Tachyzoites of *Toxoplasma gondii* in a cardiac myocyte of an Atlantic bottle-nosed dolphin. H&E. Bar = 15 μ m.

FIGURE 6. Tachyzoites of *Toxoplasma gondii* in a megakaryocyte of an Atlantic bottle-nosed dolphin. H&E. Bar = 15 μ m.

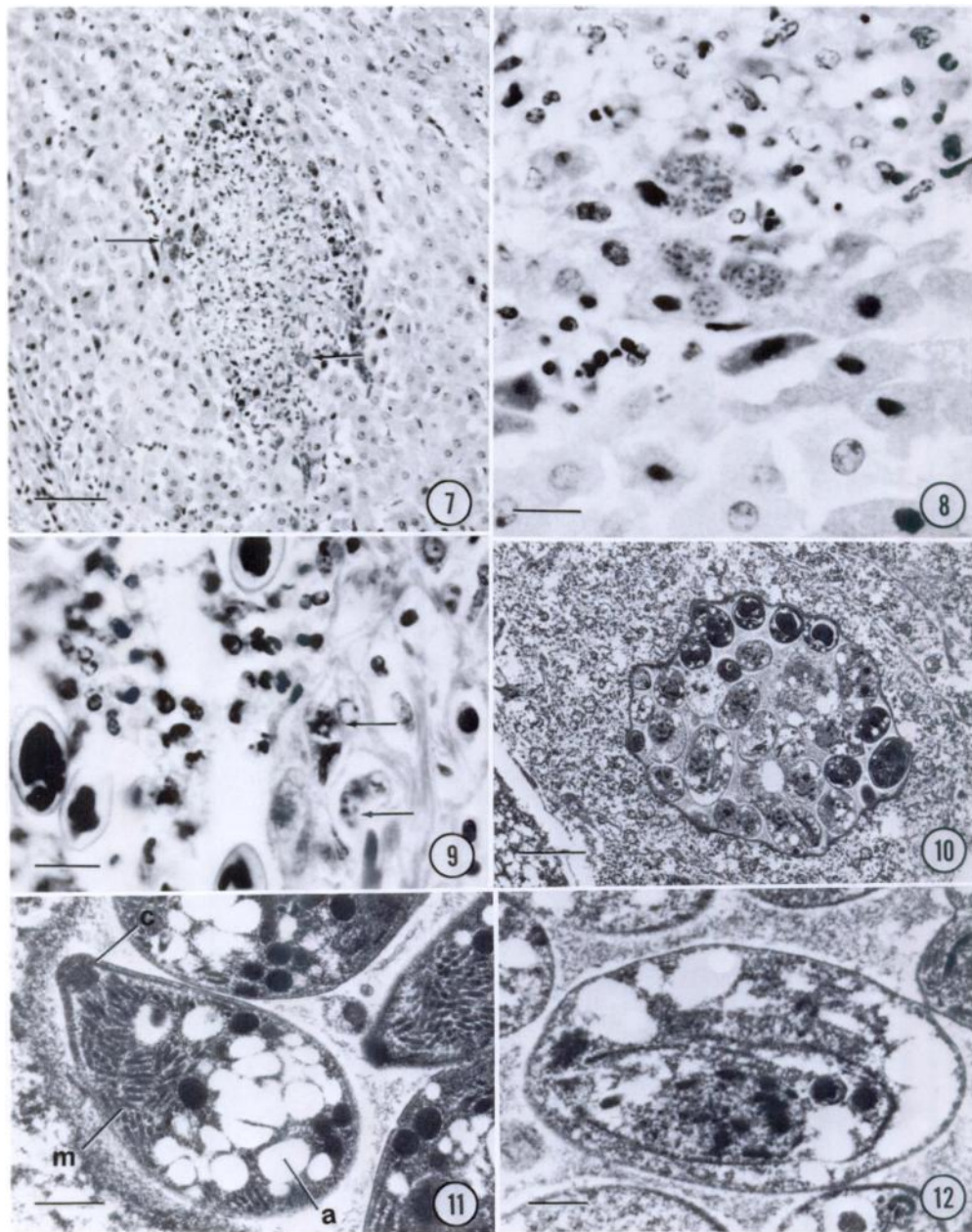


FIGURE 7. Necrotizing adrenalitis in an Atlantic bottle-nosed dolphin. Note tachyzoites and tissue cysts of *Toxoplasma gondii* (arrows). H&E. Bar = 15 μ m.

FIGURE 8. Tachyzoites of *Toxoplasma gondii* in adrenal cortical cells of an Atlantic bottle-nosed dolphin. H&E. Bar = 20 μ m.

FIGURE 9. Trematode eggs within a chronic intramural stomach abscess of an Atlantic bottle-nosed dolphin. Note tachyzoites of *Toxoplasma gondii* within macrophages (arrows). H&E. Bar = 15 μ m.

FIGURE 10. A young *Toxoplasma gondii* tissue cyst in adrenal cortical cell of an Atlantic bottle-nosed dolphin. The bradyzoites in the center of the cyst are dividing and contain relatively fewer organelles. Transmission electron micrograph. Bar = 3.5 μ m.

FIGURE 11. Bradyzoites of *Toxoplasma gondii* in adrenal cortical cell in an Atlantic bottle-nosed dolphin; conoid (c), micronemes (m), amylopectin granules (a). Transmission electron micrograph. Bar = 0.5 μ m.

FIGURE 12. *Toxoplasma gondii* undergoing endodyogeny. *Toxoplasma gondii* within an adrenal cortical cell of an Atlantic bottle-nosed dolphin. Transmission electron micrograph. Bar = 0.7 μ m.

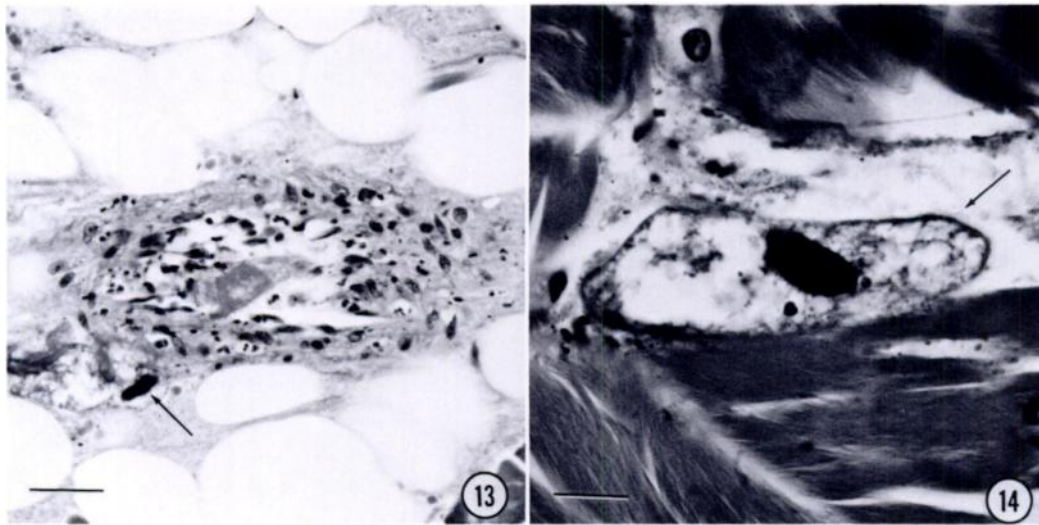


FIGURE 13. Necrotizing vasculitis in panniculus of an Atlantic bottle-nosed dolphin; ciliated protozoan (arrow). H&E.

FIGURE 14. Ciliated protozoan in dermal connective tissue; note large, dark macronucleus and cilia (arrow). H&E. Bar = 15 μ m.

plasmosis in many animals including humans. This may have been the route of infection for the calf.

During the extraintestinal (parenteral) stage of the *T. gondii* life cycle, tachyzoites multiply in nearly any type of host cell resulting in necrosis (Dubey and Beattie, 1988). Previous reports of marine mammal toxoplasmosis document the presence of the parasite in multiple organs including: brain, spinal cord, heart and adrenal in a northern fur seal; brain in a West Indian manatee; heart and stomach in a California sea lion; and liver in a harbor seal (Holshuh et al., 1985; Buergelt, 1983; Migaki et al., 1977; Van Pelt and Dietrich, 1973). In most animals *T. gondii* infection is usually subclinical; however, the organism may cause severe symptoms and lesions in immunodeficient fetuses or in immunocompromised neonates or adults. The thymus of the dolphin calf reported herein was not found at necropsy. This fact, combined with the lesions found in the lymph nodes and spleen, suggests that the calf may have been immunocompromised. In addition, there were less severe lesions of lymphoid depletion in the adult female.

The necrotizing lesions observed in this case are similar to those seen in other species where target organs such as lung, lymphoid tissue and heart are affected. Although the majority of significant histopathological lesions in these two Atlantic bottle-nosed dolphins were clearly caused by *T. gondii*, the relationship, if any, to the recent dolphin beachings along the eastern seacoast of North America is unknown.

We wish to express our appreciation to Martie Collard, Robin-Anne Ferris, and John Jenkins for technical assistance. The opinions or assertions contained herein are the private views of the authors and are not to be construed as official or as reflecting the views of the Department of the Army, Navy, or Air Force or of the Department of Defense.

LITERATURE CITED

- BUERGELT, C. D. 1983. Toxoplasmic meningoencephalitis in a West Indian manatee. *Journal of the American Veterinary Medical Association* 183: 1294-1296.
- DUBEY, J. P., AND C. P. BEATTIE. 1988. *Toxoplasmosis of animals and man*. CRC Press, Inc., Boca Raton, Florida, 220 pp.
- GREENE, C. E., AND A. K. PRESTWOOD. 1984. *Coc-*

- cidial infections. In *Clinical microbiology and infectious diseases of the dog and cat*, C. E. Greene (ed.). W. B. Saunders Company, Philadelphia, Pennsylvania, pp. 826.
- HOLSHUH, H. J., A. E. SHERROD, C. R. TAYLOR, B. F. ANDREWS, AND E. B. HOWARD. 1985. Toxoplasmosis in a feral northern fur seal. *Journal of the American Veterinary Medical Association* 187: 1229-1230.
- MIGAKI, G., J. F. ALLEN, AND H. W. CASEY. 1977. Toxoplasmosis in a California sea lion (*Zalophus californianus*). *American Journal of Veterinary Research* 38: 135-136.
- UGGLA, A., L. S. SJÖLAND, AND J. P. DUBEY. 1987. Immunohistochemical diagnosis of toxoplasmosis in fetuses and fetal membranes of sheep. *American Journal of Veterinary Research* 48: 348-351.
- VAN PELT, R. W., AND R. A. DIETERICH. 1973. Staphylococcal infection and toxoplasmosis in a young harbor seal. *Journal of Wildlife Diseases* 9: 258-261.

Received for publication 17 July 1989.