



Cutaneous Herpesvirus Infection in a Mallard Duck (*Anas platyrhynchos*)

Authors: Wojcinski, Zbigniew W., Wojcinski, Helen S. J., Barker, Ian K., and King, Norval W.

Source: Journal of Wildlife Diseases, 27(1) : 129-134

Published By: Wildlife Disease Association

URL: <https://doi.org/10.7589/0090-3558-27.1.129>

BioOne Complete (complete.BioOne.org) is a full-text database of 200 subscribed and open-access titles in the biological, ecological, and environmental sciences published by nonprofit societies, associations, museums, institutions, and presses.

Your use of this PDF, the BioOne Complete website, and all posted and associated content indicates your acceptance of BioOne's Terms of Use, available at www.bioone.org/terms-of-use.

Usage of BioOne Complete content is strictly limited to personal, educational, and non - commercial use. Commercial inquiries or rights and permissions requests should be directed to the individual publisher as copyright holder.

BioOne sees sustainable scholarly publishing as an inherently collaborative enterprise connecting authors, nonprofit publishers, academic institutions, research libraries, and research funders in the common goal of maximizing access to critical research.

Cutaneous Herpesvirus Infection in a Mallard Duck (*Anas platyrhynchos*)

Zbigniew W. Wojcinski,¹ Helen S. J. Wojcinski,² Ian K. Barker,^{1,4} and Norval W. King, Jr.,³ ¹ Department of Pathology, Ontario Veterinary College, University of Guelph, Guelph, Ontario, Canada N1G 2W1; ² Department of Clinical Studies, Ontario Veterinary College, University of Guelph, Guelph, Ontario, Canada N1G 2W1; ³ New England Regional Primate Research Center, Harvard Medical School, Southborough, Massachusetts 01772, USA; ⁴ Author to whom reprint requests should be directed

ABSTRACT: Investigations of mortalities involving wild mallard ducks (*Anas platyrhynchos*) revealed the presence of a herpesvirus associated with skin lesions on the plantar surface of the foot web of one duck. Ultrastructurally, the paracrystalline arrays of viral core particles and unencapsidated nucleoids in the nucleus, and the enveloped viruses in cytoplasmic vacuoles are compatible with a herpesvirus. This appears to be the first report of cutaneous lesions in a mallard duck attributable to a herpesvirus. Whether this lesion is due to duck virus enteritis (DVE), suggesting that cutaneous shedding is possible, or due to another uncharacterized herpesvirus of ducks is unclear.

Key words: Mallard duck, *Anas platyrhynchos*, herpesvirus, skin, case report.

In October 1984, two live (Birds A, B) and one dead (Bird C) adult female wild mallard ducks (*Anas platyrhynchos*) were submitted to the Department of Pathology at the Ontario Veterinary College (University of Guelph, Guelph, Ontario, Canada N1G 2W1) for necropsy from a site in Southwestern Ontario experiencing increased waterfowl mortality. There was some concern over the possibility of toxicity, since there was a recent history of spraying with a carbamate (Carbofuran®) in the area in the previous month. In addition, some hunting cripples were present. Clinical signs were non-specific, consisting of ill-thrift and lameness. The live birds were euthanatized by CO₂ inhalation.

On gross examination, all three birds had fractured limbs associated with previous gunshot injuries. One of the live submissions (Bird B) had multifocal 5 to 6 mm diameter crateriform erosions on the plantar surface of the right foot web.

Serum was obtained from the live birds for evaluation for botulism by mouse in-

oculation, and liver and spleen from all three birds were cultured aerobically. Selected tissues were fixed in 10% buffered neutral formalin and processed routinely for histology. Tissue blocks were cut at 6 μ m thickness and stained with hematoxylin and eosin. For electron microscopy, formalin-fixed pieces of foot webbing from Bird B were also fixed in universal fixative, washed in phosphate buffer, and post-fixed in 1% osmium tetroxide at room temperature. Blocks were washed in phosphate buffer, dehydrated, cleared and embedded in Epon. Thin sections were stained with uranyl acetate, followed by lead citrate. Grids were examined and photographed on a Philips EM-300 electron microscope at 60 kv.

Significant bacteria were not isolated from the liver or spleen. Serum was negative for botulinum toxin by the mouse inoculation test, in that mice did not show signs of disease or die.

The cause of the mortality among birds at this site could not be determined, but the gross and microscopic findings in the three representative birds submitted suggested that debilitation secondary to gunshot injury may have been a contributing factor.

Microscopically, lesions on the ventral surface of the foot web of Bird B were characterized by foci of hyperkeratosis, acanthosis and erosion. In these areas, epidermal cells of the stratum spinosum were hypertrophied and vacuolated (Fig. 1). Prominent intranuclear inclusions, and occasionally granular amphophilic intracytoplasmic inclusions, were evident in degenerate cells in the middle and upper layers of the epithelium. Many heterophils

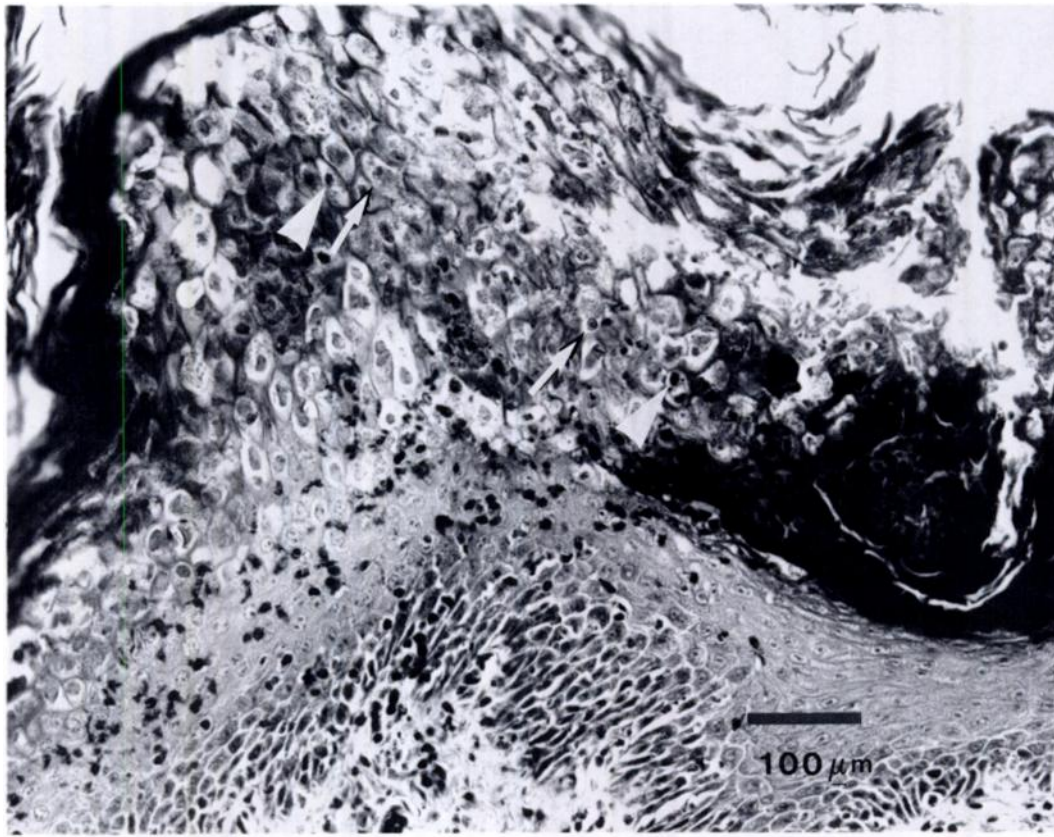


FIGURE 1. Photomicrograph of a cutaneous lesion on the ventral aspect of the foot web from a mallard duck (Bird B) showing acanthosis, hyperkeratosis and degeneration of cells of the stratum spinosum. Note the characteristic intranuclear (arrows) and intracytoplasmic (arrowheads) inclusion bodies in hypertrophied cells of the middle and upper layers of the epidermis. H&E.

were present in the dermis subtending the erosions, and numerous bacteria were evident in the overlying superficial necrotic debris.

Ultrastructural examination of the foot web lesions revealed large numbers of viral particles in the nucleus and cytoplasm of hypertrophied epidermal cells. Within the nuclei of affected cells, there was margination and clumping of chromatin, diffuse fine granular material filling the bulk of the nucleus, and focal paracrystalline arrays of viral core particles, with empty nucleocapsids and nucleocapsids containing cores arranged around the periphery of these aggregates (Fig. 2). Unenveloped virions were present lining the inner nuclear membrane, between the inner and outer lamellae of the nuclear envelope, or

occasionally randomly scattered throughout the nucleoplasm (Fig. 3). Virions were also observed budding through the nuclear membrane into irregularly dilated perinuclear cisternae or cytoplasmic vacuoles, often forming large aggregates of membrane-bound cytoplasmic inclusions.

In addition, paracrystalline arrays of viral cores, as well as unenveloped nucleocapsids and enveloped viruses, were evident in the cytoplasm. Unenveloped virions were observed aggregating at the membrane of cytoplasmic vacuoles which contained enveloped viruses (Fig. 4). Occasionally, more than one nucleocapsid was present within an irregular envelope. The viral particles varied in size from approximately 37.4 nm for intranuclear core particles, to 93.5 nm for intranuclear nucleo-

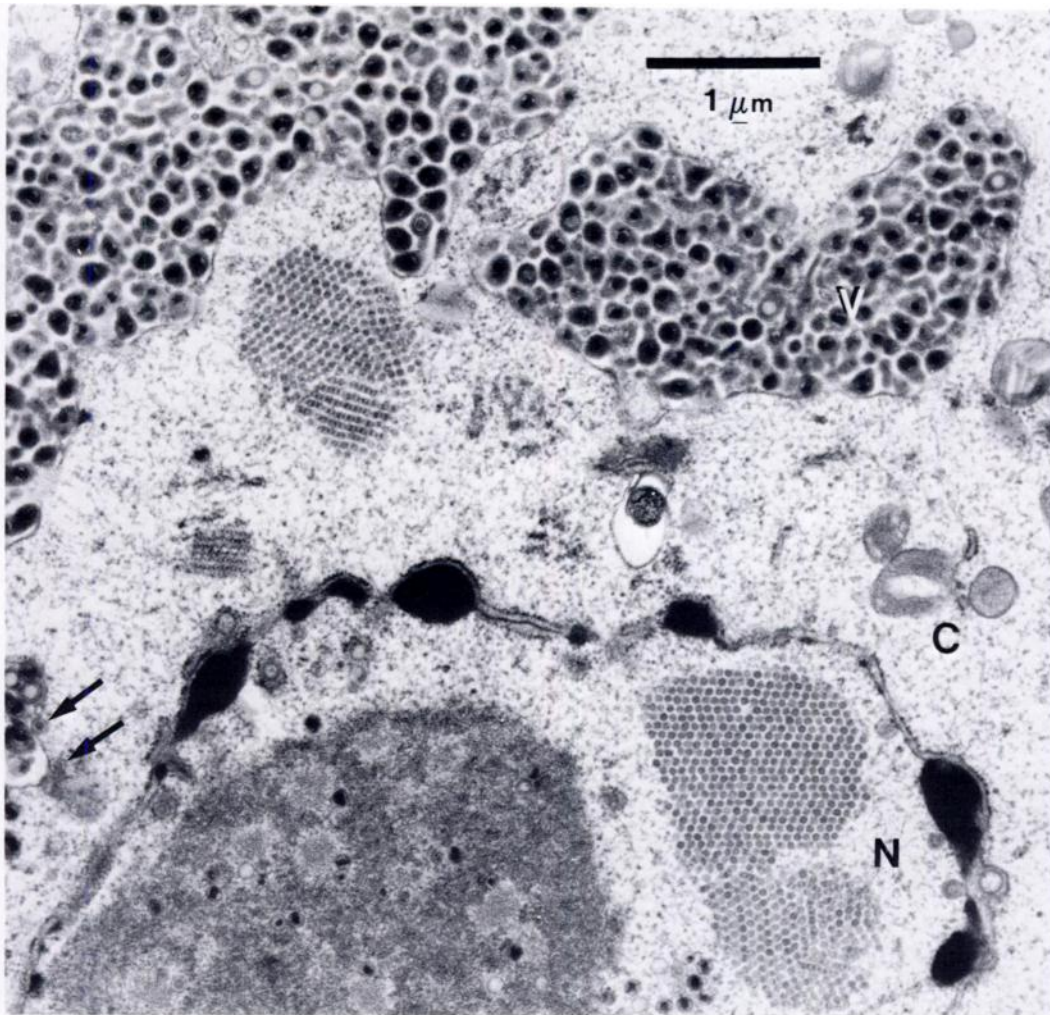


FIGURE 2. Electron photomicrograph showing paracrystalline arrays of naked viral core particles in the nucleus (N) and cytoplasm (C) of an infected cell of the stratum spinosum. Unenveloped nucleocapsids are scattered throughout the nucleus and occasionally are present in the cytoplasm (arrows). Large vacuoles (V) in the cytoplasm contain enveloped virions.

capsids, and 93.5 to 186.9 nm for enveloped cytoplasmic particles containing densely stained (mature) cores. The cytoplasm of the infected cells contained few organelles, including swollen mitochondria, peripheralized tonofilaments and cytoplasmic vacuoles.

The morphological appearance and mode of assembly of the viral particles observed in the lesions on the foot web are compatible with a herpesvirus, similar to the description of DVE by Breese and Dardiri (1968) and Dardiri (1975). However,

there are several noteworthy features. The large number of unencapsidated nucleoids present in the nucleus and in some cells in the cytoplasm resembles *Herpesvirus simplex* (Morgan et al., 1968), but is more extensive. The presence of the naked nucleoids in the cytoplasm is interpreted to result from disruption of the nuclear membrane with escape of naked nucleoids from the nucleus into the cytoplasm. The other striking feature is the tendency for the enveloped virions to remain within large cytoplasmic vacuoles, which appear as inclu-

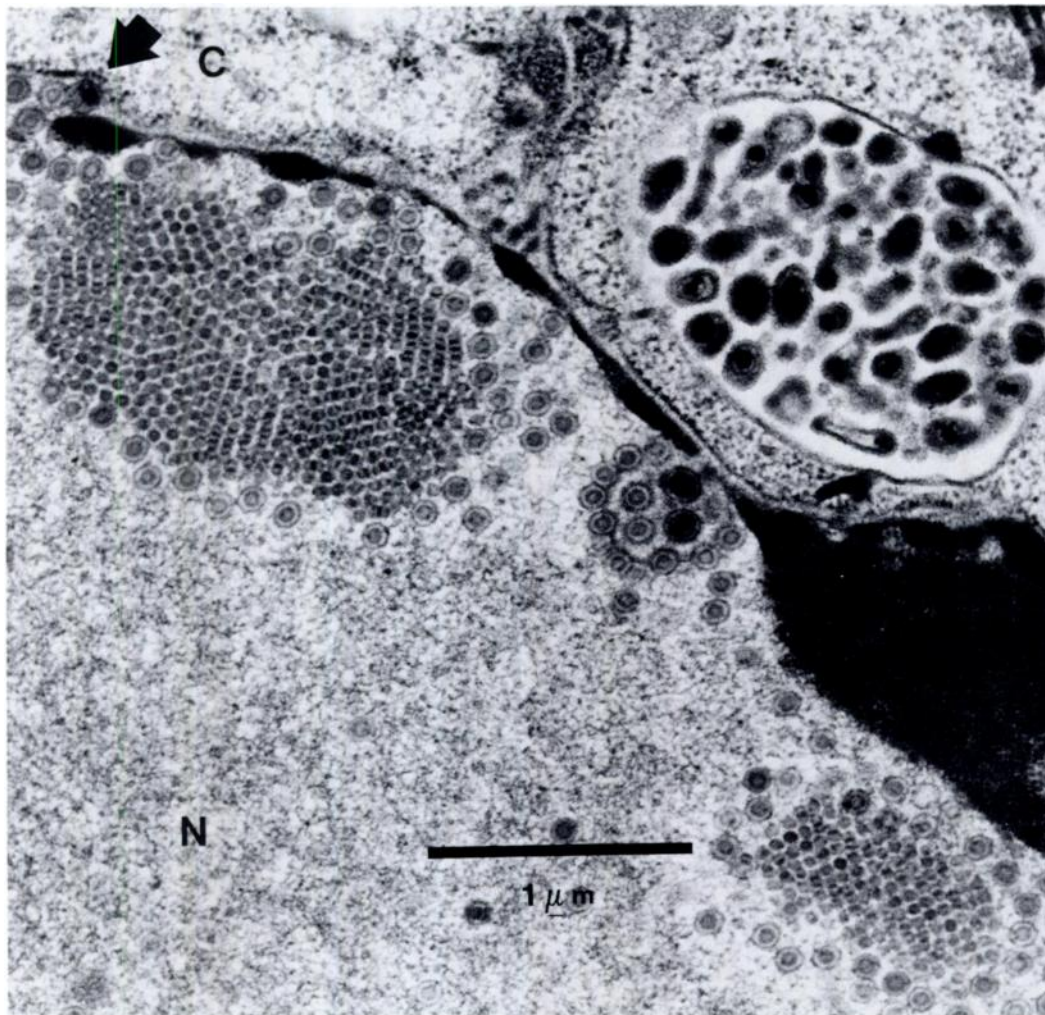


FIGURE 3. Higher magnification of an infected cell of the stratum spinosum showing paracrystalline arrays of naked viral core particles in the nucleus (N), surrounded by nucleocapsids. Nucleocapsids with central core particles are also present in a dilated perinuclear cisterna (arrow). A vacuole containing enveloped virions is evident in the cytoplasm (C).

sions at the light microscopic level. This is unusual also and more often a feature found with cell-associated herpesviruses, most notably the cytomegaloviruses. However, the light microscopic appearance (no cytomegaly or karyomegaly) does not support the conclusion that this is a cytomegalovirus (Doane and Anderson, 1987).

Although confirmation of the diagnosis depends on the identification of the virus by serological methods or viral isolation, intranuclear type A inclusion bodies are compatible with DVE infection in water-

fowl (Dardiri, 1975). However, as DVE virus has an affinity for a variety of epithelial and reticuloendothelial tissues (Leibovitz and Hwang, 1968; Leibovitz, 1971; Proctor, 1975, 1976; Montali et al., 1976), it is unusual that only the epidermis of the foot web was affected in this case, if it is due to DVE. A possible explanation may be that differences in virulence exist among different strains of DVE (Jansen, 1968). Furthermore, the response to the virus does appear to be extremely variable (Leibovitz, 1969; Dardiri, 1975), which has been

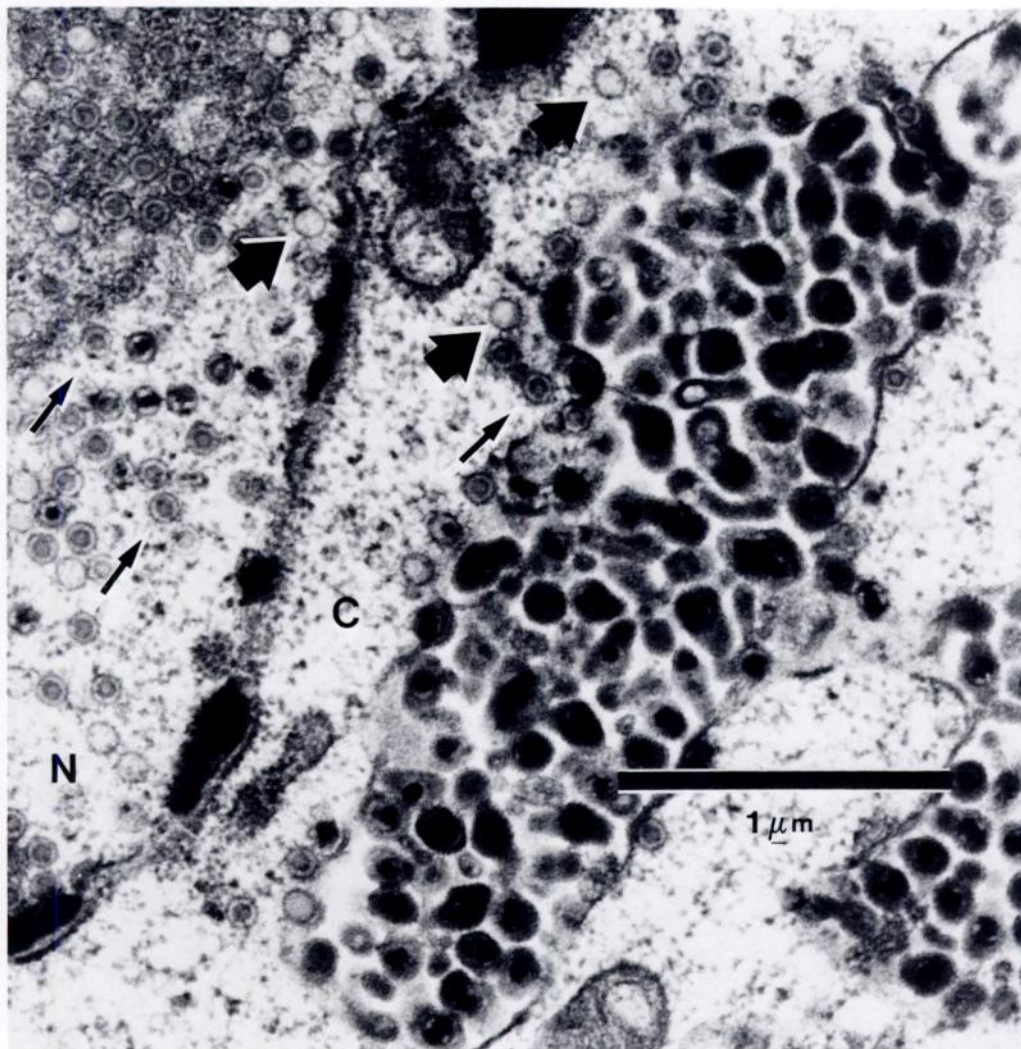


FIGURE 4. Electron photomicrograph of an infected cell of the stratum spinosum demonstrating nucleocapsids with cores (arrows) and without cores (arrowheads) in the nucleus (N) and adjacent to a vacuole containing enveloped virions in the cytoplasm (C).

confirmed experimentally (Burgess and Yuill, 1983; Wobeser, 1987), although the mechanisms of resistance or latency are not yet completely understood (Burgess et al., 1979).

Cutaneous lesions have not been described in any reports of DVE. If the lesion reported here is due to DVE, it suggests the possibility of cutaneous shedding of virus into the environment. In that circumstance, cutaneous erosions also may provide another indicator of persistent DVE infection or of viral shedding and

should be sought, although they are likely an inconsistent and unreliable method of detecting DVE infections in waterfowl. If this lesion is not due to DVE, it indicates that a second herpesvirus of anatids awaits further characterization.

This study was supported in part by the Ontario Ministry of Natural Resources and the Ontario Ministry of Health. The authors wish to thank Carol Winter, Gail Deutsch and Ken Baker for their technical assistance and Norm North of the Canadian Wildlife Service (London, Ontario,

Canada) for submission of the mallard ducks.

LITERATURE CITED

- BREESE, S. S., JR., AND A. H. DARDIRI. 1968. Electron microscopic characterization of duck plague virus. *Virology* 34: 160-169.
- BURGESS, E. C., J. OSSA, AND T. M. YUILL. 1979. Duck plague: A carrier state in waterfowl. *Avian Diseases* 24: 940-949.
- , AND T. M. YUILL. 1983. The influence of seven environmental and physiological factors on duck plague virus shedding by carrier mallards. *Journal of Wildlife Diseases* 19: 77-81.
- DARDIRI, A. H. 1975. Duck viral enteritis (duck plague) characteristics and immune response of the host. *American Journal of Veterinary Research* 36: 535-538.
- DOANE, F. W., AND N. ANDERSON. 1987. Herpesviridae. In *Electron microscopy in diagnostic virology. A practical guide and atlas*. Cambridge University Press, New York, New York, pp. 75-83.
- JANSEN, J. 1968. Duck plague. *Journal of the American Veterinary Medical Association* 152: 1009-1016.
- LEIBOVITZ, L. 1969. The comparative pathology of duck plague in wild Anseriformes. *The Journal of Wildlife Management* 33: 294-303.
- . 1971. Gross and histopathological changes of duck plague (duck virus enteritis). *American Journal of Veterinary Research* 32: 275-290.
- , AND J. HWANG. 1968. Duck plague on the American continent. *Avian Diseases* 12: 361-378.
- MONTALI, R. J., M. BUSH, AND G. A. GREENWELL. 1976. An epizootic of duck viral enteritis in a zoological park. *Journal of the American Veterinary Medical Association* 169: 954-958.
- MORGAN, C., H. M. ROSE, AND B. MEDNIS. 1968. Electron microscopy of *Herpes simplex* virus. *Journal of Virology* 2: 507-536.
- PROCTOR, S. J. 1975. Pathogenesis of digestive tract lesions in duck plague. *Veterinary Pathology* 12: 349-361.
- . 1976. Pathogenesis of duck plague in the bursa of Fabricius, thymus and spleen. *American Journal of Veterinary Research* 37: 427-431.
- WOBESER, G. 1987. Experimental duck plague in Blue-winged teal and Canada geese. *Journal of Wildlife Diseases* 23: 368-375.

Received for publication 22 December 1989.