



## **Unilateral Hydrocephalus in a Wild European Brown Hare (*Lepus europaeus*)**

Authors: Abramo, F., and Poli, A.

Source: Journal of Wildlife Diseases, 27(2) : 331-333

Published By: Wildlife Disease Association

URL: <https://doi.org/10.7589/0090-3558-27.2.331>

---

BioOne Complete ([complete.BioOne.org](https://complete.BioOne.org)) is a full-text database of 200 subscribed and open-access titles in the biological, ecological, and environmental sciences published by nonprofit societies, associations, museums, institutions, and presses.

Your use of this PDF, the BioOne Complete website, and all posted and associated content indicates your acceptance of BioOne's Terms of Use, available at [www.bioone.org/terms-of-use](https://www.bioone.org/terms-of-use).

Usage of BioOne Complete content is strictly limited to personal, educational, and non - commercial use. Commercial inquiries or rights and permissions requests should be directed to the individual publisher as copyright holder.

---

BioOne sees sustainable scholarly publishing as an inherently collaborative enterprise connecting authors, nonprofit publishers, academic institutions, research libraries, and research funders in the common goal of maximizing access to critical research.

## Unilateral Hydrocephalus in a Wild European Brown Hare (*Lepus europaeus*)

F. Abramo and A. Poli, Department of Animal Pathology, School of Veterinary Medicine, University of Pisa, viale delle Piagge 2, 56100 Pisa, Italy

**ABSTRACT:** Macroscopic and histological study of a case of unilateral hydrocephalus in a young wild European brown hare (*Lepus europaeus*) is reported here. Morphological changes were mostly massive dilatation of the left lateral ventricle, atrophy of the cortex and a striking reduction of the corresponding white matter. Lymphocytic cell infiltrates and hemosiderin-laden macrophages in the choroid plexus and meninges also were observed. Although the exact cause of the lesions was not found all findings suggested a hydrocephalus of possible traumatic, infectious or congenital hypoplasia origin.

**Key words:** Hydrocephalus, European brown hare, cortex, atrophy, *Lepus europaeus*, case report.

Hydrocephalus is defined as an abnormal accumulation of cerebrospinal fluid in the cerebral cavity (Sullivan, 1985). The pathogenetic mechanism inducing the lesion is the result of an imbalance production and absorption of cerebrospinal fluid in the brain (James et al., 1975).

Two variants of hydrocephalus have been identified: the communicating and non-communicating forms. The communicating type refers to massive dilation of both ventricular system and arachnoid space while in the non-communicating type also known as internal hydrocephalus, cerebrospinal fluid accumulates only within the ventricular system, proximal to a point of obstruction (Heavner, 1978). The most common sites of obstruction are the foramina of Luschka in the fourth ventricle and the aqueduct of Sylvius (Jones and Hunt, 1983). The occurrence of hydrocephalus has been previously reported in many animal species such as rabbits, cows, horses, dogs, cats and laboratory animals (Higgins et al., 1977). There is little documentation of their condition in wild animals in general but there are reports in mink and bear (Halstead and Kiel, 1962).

In this paper we present a morphological description of a hydrocephalus in one young, male, wild European brown hare (*Lepus europaeus*) found circling in a field. The hare was presented to the pathology institute (School of Veterinary Medicine, University of Pisa, Pisa, Italy) and euthanized. The brain was removed, sectioned transversely once through the cerebrum and fixed in 10% buffered formalin. Transverse brain sections were obtained, dehydrated and embedded in paraffin. Histological examination was performed on hematoxylin and eosin (HE) stained, 4  $\mu$ m thick sections.

The only macroscopic lesion observed was marked dilation of the left lateral ventricle with atrophy of the cortex and reduction of the left Ammon's Horn (Fig. 1). No changes were observed at the level of the cerebral aqueduct, third and fourth ventricle. The cortex was extensively atrophic around the dilated ventricle.

Microscopic study showed that the gray matter was reduced to less than half of its normal thickness and the white matter had almost disappeared (Fig. 2). The latter had a relative increased number of glial cells. Spongiform degeneration was observed in a limited area of the affected cortex. The Ammon's horn was atrophic, and no degenerative lesions were evident. Slight loss of the ependymal lining was noticed in some parts of the affected ventricle while in other areas of the affected ventricle flattened ependymal cells were present. Few erythrocytes were present in the ventricle lumina. The choroid plexus contained nodules of lymphoid cells (Fig. 3) and a few macrophages containing hemosiderin. A few scattered blood vessels in the sub-arachnoid space were surrounded by a mild perivascular lymphoid cell infiltration.

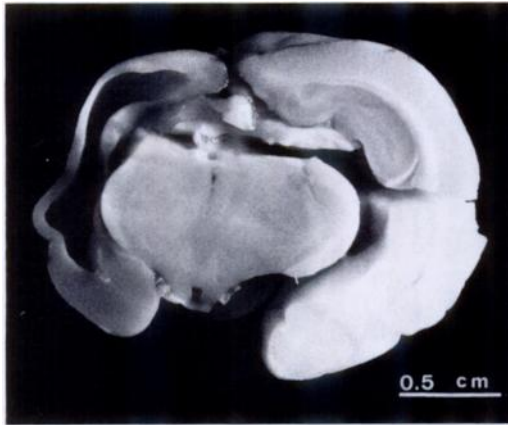


FIGURE 1. Severe enlargement of the left lateral ventricle in a wild European brown hare with hydrocephalus.

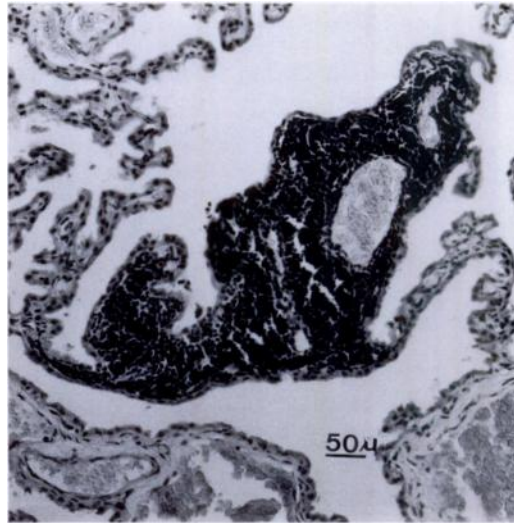


FIGURE 3. Brain of a European brown hare showing nodular lymphoid cell infiltrate in the choroid plexus of the affected dilated ventricle (H&E stained section; 40×).




FIGURE 2. Brain of a European brown hare showing reduction in cortical thickness overlying the affected ventricle (a) compared to the normal one, same magnification (b). Partial disappearance and compression of the white matter (a) (H&E stained section; 10×).

In spite of the occasional development of hydrocephalus in connection with well known acquired circumstances, hydrocephalus usually occurs as a disease of the new-born and the cause can be attributed to maldevelopment of the brain or cranium (Jones and Hunt, 1983). Many cases of hydrocephalus in domestic and laboratory animals have been attributable to hereditary developmental defects (Gilman, 1956; Bruni et al., 1988). Congenital hydrocephalus also has been experimentally induced in laboratory animals following (1) maternal treatment with chemicals, (2) exposure to viruses, (3) X-irradiation and (4) vitamin deficient diets (Bruni et al., 1988; Lindsey and Fox, 1974). All pathological changes observed in our case seemed to be a direct response to an excessive accumulation of cerebrospinal fluid causing the pressure atrophy of the cerebral tissue. The effect of the pressure exerted by the fluid was particularly evident on the white matter which atrophied more than the gray matter. The white matter is known to rapidly degenerate when subjected to increased fluid pressure (Sullivan, 1985). No lesions of infection nor any obstructive cause was de-

tected. Infectious agents and other environmental factors have been reported to damage the central nervous system of the foetus (1) indirectly by damaging the uterus, placenta or both, (2) by transplacental passage of preformed microbial toxins originating either in the dam or in her feed and (3) by direct invasion of the foetus itself (Heavner, 1978). The absence of a clear history allows us to present a hypothesis. The unilateral nature of the hydrocephalus, the lymphocytic cell infiltrates in the choroid plexus and meninges, and the hemosiderin-laden macrophages suggest that perinatal trauma or an infectious agent was the initiating cause. However, an hereditary or congenital condition also is a possibility.

#### ACKNOWLEDGMENTS

The authors thank D. K. Tontis for his assistance in the preparation of the manuscript.

#### LITERATURE CITED

- BRUNI, J. E., M. R. DEL BIGIO, E. R. CARDOSO, AND T. V. N. PERSAUD. 1988. Hereditary hydrocephalus in laboratory animals and humans. *Experimental Pathology* 35: 239-246.
- GILMAN, J. P. W. 1956. Congenital hydrocephalus in domestic animals. *Cornell Veterinarian* 46: 487-499.
- HALSTEAD, J. R., AND W. KIEL. 1962. Hydrocephalus in a bear. *Journal of the American Veterinary Medical Association* 141: 367-368.
- HEAVNER, J. E. 1978. Congenital hydrocephalus secondary to in utero infection. *Veterinary Medicine/Small Animal Clinician* 73: 157-160.
- HIGGINS, R. J., M. VANDEVELDE, AND K. B. BRAUND. 1977. Internal hydrocephalus and associated periventricular encephalitis in young dogs. *Veterinary Pathology* 14: 236-246.
- JAMES, A. E., B. BURNS, W. F. FLOR, E. P. STRECKER, T. MERZ, M. BUSH, AND D. L. PRICE. 1975. Pathophysiology of chronic communicating hydrocephalus in dogs (*Canis familiaris*). *Journal of the Neurological Sciences* 24: 151-178.
- JONES, T. C., AND R. D. HUNT. 1983. *Veterinary pathology*, 5th ed. Lea & Febiger, Philadelphia, Pennsylvania, 1,656 pp.
- LINDSEY, J. R., AND R. R. FOX. 1974. Inherited diseases and variations. *In* The biology of the laboratory rabbit, S. H. Weisbroth, R. E. Flatt, and A. L. Kraus (eds.). Academic Press, New York, New York, pp. 377-381.
- SULLIVAN, N. D. 1985. The nervous system. *In* Pathology of domestic animals, 3rd ed., K. V. F. Jubb, P. C. Kennedy and N. Palmer (eds.). Academic Press, New York, New York, pp. 209-211.

*Received for publication 2 January 1990.*