



Pancreatic Duct Hyperplasia in a Raccoon (*Procyon lotor*) Caused by *Atriotaeia procyonis*

Authors: Snyder, Daniel E., Hamir, Amir N., Hanlon, Cathleen A., and Rupprecht, Charles E.

Source: Journal of Wildlife Diseases, 27(2) : 334-336

Published By: Wildlife Disease Association

URL: <https://doi.org/10.7589/0090-3558-27.2.334>

BioOne Complete (complete.BioOne.org) is a full-text database of 200 subscribed and open-access titles in the biological, ecological, and environmental sciences published by nonprofit societies, associations, museums, institutions, and presses.

Your use of this PDF, the BioOne Complete website, and all posted and associated content indicates your acceptance of BioOne's Terms of Use, available at www.bioone.org/terms-of-use.

Usage of BioOne Complete content is strictly limited to personal, educational, and non - commercial use. Commercial inquiries or rights and permissions requests should be directed to the individual publisher as copyright holder.

BioOne sees sustainable scholarly publishing as an inherently collaborative enterprise connecting authors, nonprofit publishers, academic institutions, research libraries, and research funders in the common goal of maximizing access to critical research.

Pancreatic Duct Hyperplasia in a Raccoon (*Procyon lotor*) Caused by *Atriotaeia procyonis*

Daniel E. Snyder,¹ Amir N. Hamir,² Cathleen A. Hanlon,³ and Charles E. Rupprecht,³ ¹U.S. Department of Agriculture, Agricultural Research Service, Animal Parasite Research Laboratory, POB 952, Auburn, Alabama 36831, USA; ²University of Pennsylvania, School of Veterinary Medicine, New Bolton Center, 382 West Street Road, Kennett Square, Pennsylvania 19348-1692, USA; ³The Wistar Institute of Anatomy and Biology, 3601 Spruce St., Philadelphia, Pennsylvania 19104, USA

ABSTRACT: A raccoon (*Procyon lotor*) live-trapped in Philadelphia, Pennsylvania was heavily infected with the tapeworm *Atriotaeia procyonis*. Histopathologic examination of the duodenum revealed this tapeworm attached to the mucosa; the mucosa was mildly hyperplastic without a significant inflammatory infiltrate. This tapeworm was seen also within the proximal pancreatic duct and histopathologic lesions associated with its presence consisted of marked hyperplasia of mucosal cells, causing the formation of an extensive papillary projection into the duct lumen. Inflammatory cellular reaction was minimal, consisting primarily of lymphocytes, and was seen in the mucosa and submucosa of the duct. The presence of *A. procyonis* in the pancreas of this raccoon is considered to be an aberrant location for this parasite and has not been reported previously.

Key words: *Atriotaeia procyonis*, Cestoda, raccoon, *Procyon lotor*, pancreatic duct, pathology, case report.

Atriotaeia procyonis is a common tapeworm of the small intestine of the raccoon (*Procyon lotor*) (Snyder and Fitzgerald, 1985). Like other adult tapeworms, little or no damage to the host has been described as these parasites attach to and reside in the intestinal tract. The purpose of this report is to describe gross and histopathologic changes in the duodenal mucosa and pancreatic duct of a raccoon naturally infected with *A. procyonis*.

An adult female raccoon was live-trapped in Andorra Park, Philadelphia, Pennsylvania (USA: 39°57'N; 75°07'W) in August 1989 as part of surveillance for rabies infection and for baseline data collection for raccoons in the park. The animal was euthanized by an intravenous barbiturate overdose and a complete necropsy performed. At necropsy, the mucosa of the proximal duodenum was covered diffusely

with white, fibrin-like material (Fig. 1). Closer examination of the area revealed a moderately thickened mucosa. The fibrin-like material consisted of small tapeworms (<2 cm in length), some of which were attached to the mucosal surface. The tapeworms were present in approximately the first 45 cm of the proximal duodenum; an attempt was not made to enumerate them. No other gross lesions were seen in the carcass. Representative tissue sections of all major organs were fixed in 10% neutral buffered formalin, embedded in paraffin, sectioned at 5 μ m and stained with hematoxylin and eosin for examination by light microscopy. Histopathologic examination revealed numerous tapeworms embedded and attached to the duodenal mucosa (Fig. 2) and within the proximal pancreatic duct (Fig. 3). There was mild hyperplasia of the duodenal mucosa. The mucosa of the proximal pancreatic duct was markedly hyperplastic with the formation of a papillary projection into the duct lumen. The supporting stroma of the papillary projection contained a mild, focal nodular accumulation of lymphocytes (Fig. 3).

The tapeworms were identified as immature specimens of *Atriotaeia procyonis* based on a previous description (Galati, 1959). Representative specimens of *A. procyonis* are deposited in the U.S. National Parasite Collection (Beltsville, Maryland 20705, USA; accession number 81412). Specimens seen in histologic section and whole mount preparations were 1 to 2 cm in length, did not have well defined segmentation or reproductive organs and had large numbers of calcareous

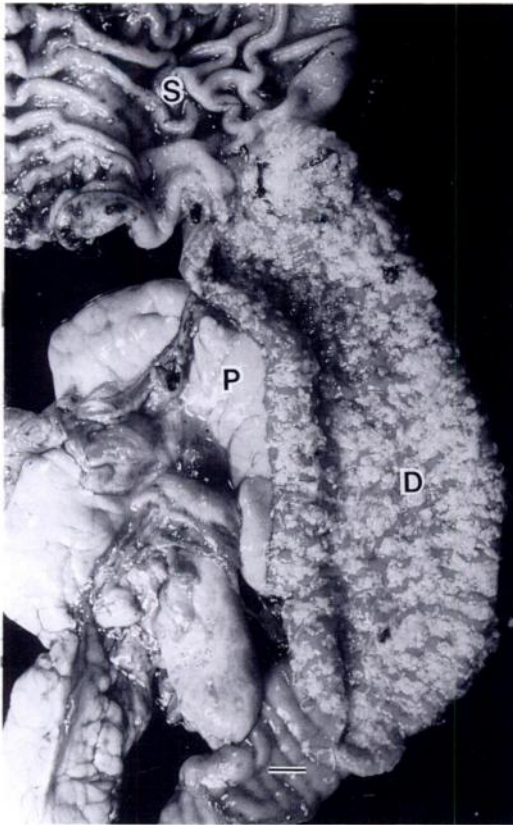


FIGURE 1. Gross photograph of proximal duodenum (D), stomach (S), and pancreas (P) of a raccoon at necropsy. The mucosal surface of the duodenum had a confluent layer of white, fibrin-like material that upon closer examination was found to consist of small immature tapeworms, identified as *Atriotaeia procyonis*. Bar = 1 cm.

corpuscles. Gallati (1959) described the life history of this parasite and his drawings of immature *A. procyonis*, 6 days post-infection with laboratory reared cysticeroids, are similar to the specimens found in the raccoon described above. Apparently this raccoon had recently ingested an insect intermediate host infected with cysticeroids of this tapeworm. Gallati (1959) did not describe histologic lesions in the duodenum or the pancreas of naturally or experimentally infected raccoons. This report appears to be the first to describe histologic lesions in the pancreatic duct of a raccoon naturally infected with this tapeworm. *Atriotaeia procyonis* has been re-

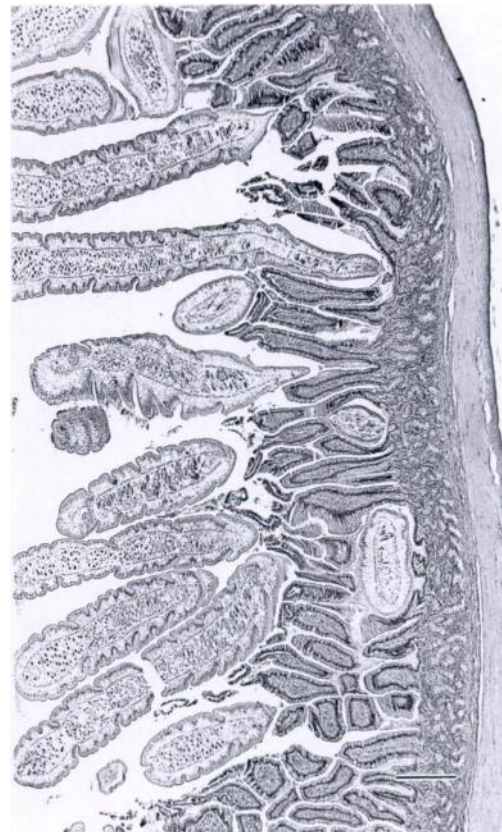


FIGURE 2. Low magnification photomicrograph showing attachment of *Atriotaeia procyonis* to duodenal mucosa. Bar = 100 μ m.

ported commonly from the small intestine of raccoons with the mean intensity generally less than 100. Schaffer et al. (1981) reported one raccoon with 818 specimens of this tapeworm. Parasite induced host damage is often difficult to assess under natural conditions in wildlife. Heavy parasite infections in certain animals, as described above, may cause tissue damage to the host. The importance of these lesions on the overall health of the infected host is often difficult to assess. The presence of *A. procyonis* in the pancreatic duct of this raccoon is considered to be an aberrant location for this parasite and has not been reported previously. The high intensity of infection might account for the aberrant location of this tapeworm. The aberrant migration or location of nematode para-

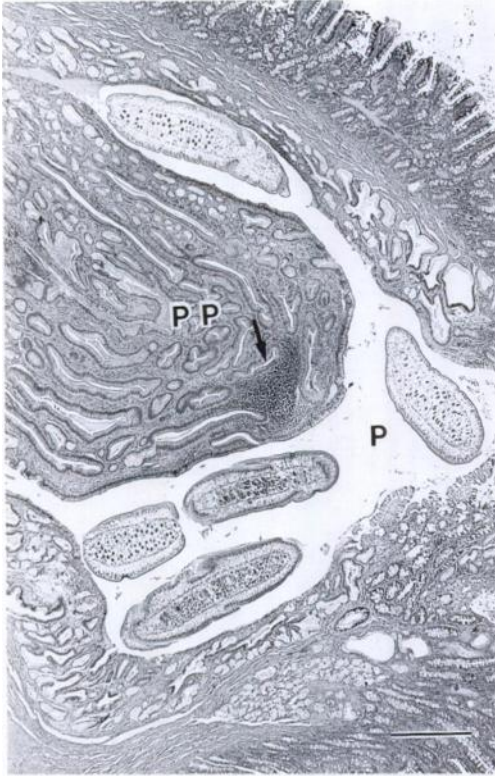

FIGURE 3. *Atriotaenia procyonis* within proximal pancreatic duct (P) and hyperplasia of mucosal cells, causing the formation of an extensive papillary projection (PP) into the duct lumen. A focal area of inflammatory cells (arrow) is seen in the submucosa and mucosa of the duct. Bar = 100 μ m.

sites in the pancreatic duct of other animals (pig, dog, horse) has been reported (Hamir, 1987).

This work was supported in part by the Pennsylvania Department of Agriculture.

LITERATURE CITED

- GALLATI, W. W. 1959. Life history, morphology and taxonomy of *Atriotaenia (Ershovia) procyonis* (Cestoda: Linstowiidae), a parasite of the raccoon. *The Journal of Parasitology* 45: 363-377.
- HAMIR, A. N. 1987. Verminous pancreatitis in a horse. *The Veterinary Record* 121: 301-302.
- SCHAFFER, G. D., W. R. DAVIDSON, V. F. NETTLES, AND E. A. ROLLER, III. 1981. Helminth parasites of translocated raccoons (*Procyon lotor*) in the southeastern United States. *Journal of Wildlife Diseases* 17: 217-227.
- SNYDER, D. E., AND P. R. FITZGERALD. 1985. Helminth parasites from Illinois raccoons (*Procyon lotor*). *The Journal of Parasitology* 71: 274-278.

Received for publication 21 June 1990.