

## **YERSINIOSIS IN FREE-RANGING MUSKOXEN ON BANKS ISLAND, NORTHWEST TERRITORIES, CANADA**

Authors: Blake, John E., McLean, Bruce D., and Gunn, Anne

Source: Journal of Wildlife Diseases, 27(4) : 527-533

Published By: Wildlife Disease Association

URL: <https://doi.org/10.7589/0090-3558-27.4.527>

---

BioOne Complete ([complete.BioOne.org](https://complete.BioOne.org)) is a full-text database of 200 subscribed and open-access titles in the biological, ecological, and environmental sciences published by nonprofit societies, associations, museums, institutions, and presses.

Your use of this PDF, the BioOne Complete website, and all posted and associated content indicates your acceptance of BioOne's Terms of Use, available at [www.bioone.org/terms-of-use](https://www.bioone.org/terms-of-use).

Usage of BioOne Complete content is strictly limited to personal, educational, and non - commercial use. Commercial inquiries or rights and permissions requests should be directed to the individual publisher as copyright holder.

---

BioOne sees sustainable scholarly publishing as an inherently collaborative enterprise connecting authors, nonprofit publishers, academic institutions, research libraries, and research funders in the common goal of maximizing access to critical research.

## YERSINIOSIS IN FREE-RANGING MUSKOXEN ON BANKS ISLAND, NORTHWEST TERRITORIES, CANADA

John E. Blake,<sup>1,4</sup> Bruce D. McLean,<sup>2</sup> and Anne Gunn<sup>3</sup>

<sup>1</sup> Department of Veterinary Pathology, Western College of Veterinary Medicine, University of Saskatchewan, Saskatoon, Saskatchewan S7N 0W0, Canada

<sup>2</sup> Department of Renewable Resources, Government of the Northwest Territories, Inuvik, Northwest Territories X0E 0T0, Canada

<sup>3</sup> Department of Renewable Resources, Government of the Northwest Territories, Coppermine, Northwest Territories X0E 0E0, Canada

<sup>4</sup> Present address: Institute of Arctic Biology, University of Alaska Fairbanks, Fairbanks, Alaska 99775, USA

**ABSTRACT:** Sixty-seven muskox (*Ovibos moschatus*) carcasses, 53 skeletal remains and two sick muskoxen were seen during an aerial survey of the Thomsen River region, northern Banks Island, Northwest Territories, Canada in late July 1986. Complete necropsies were performed on 29 muskoxen estimated to have died within the previous 3 to 5 days. Twenty were diagnosed with acute yersiniosis due to *Yersinia pseudotuberculosis* serotype 1B and were in excellent body condition. A diagnosis could not be made on seven animals due to marked autolysis; however, these muskoxen also were in excellent body condition. The remaining two were aged, emaciated muskoxen. This report describes the first occurrence of yersiniosis in free-ranging muskoxen and the first documentation of large scale mortality due to this disease in a free-ranging population of wild ungulates.

**Key words:** *Yersinia pseudotuberculosis*, yersiniosis, muskox, *Ovibos moschatus*, pathology, bacteriology, epidemiology, population biology, Canadian Arctic.

### INTRODUCTION

Although previously unreported in muskoxen (*Ovibos moschatus*), *Yersinia pseudotuberculosis* is known to cause a variety of diseases in many species and is a major cause of mortality in domestic and captive wild ungulates (Hubbert, 1972; Hacking and Sileo, 1974; Obwolo, 1976; Baskin et al., 1977; Stovell, 1980; Karbe and Erickson, 1984; Mackintosh and Henderson, 1984a). It is a zoonosis and its occurrence as a human pathogen is well described (Stovell, 1980; Toma, 1987). The bacterium is transmitted by the fecal-oral route but the organism is ubiquitous and exposure alone, unless to a particularly virulent strain or in high numbers, does not cause disease (Obwolo, 1976; Stovell, 1980). Sudden climatic changes, poor nutrition, and overcrowding are stressors frequently implicated as precipitating factors in the pathogenesis of this disease (Obwolo, 1976; Stovell, 1980; Mackintosh and Henderson, 1984a).

The muskox is a member of the family Bovidae and subfamily Caprinae. It is a

circumpolar ungulate well adapted to life in the high arctic. Archeological and historical reports indicate that a substantial muskox population of undetermined size existed in the Thomsen River region of northern Banks Island, Northwest Territories, Canada in the latter half of the nineteenth century (Hone, 1934; Manning and Macpherson, 1958; Zoltai et al., 1980; Will, 1984). Muskoxen were considered extinct on this island by the turn of the century (Stefansson, 1921; Manning and Macpherson, 1958) but the population has gradually recovered with most of the increase occurring in the last 20 yr (Urquhart, 1973; Zoltai et al., 1980; Vincent and Gunn, 1981; McLean et al., 1986). Recolonization of Banks Island may have occurred by expansion of a small unrecognized remnant population, by immigration from neighboring Victoria or Melville Island, or a combination of both. A whole island aerial survey in 1985 estimated the Banks Island population to be 25,000 ± 2070 (SE) animals with the highest density in the Thomsen River region (McLean et al., 1986).



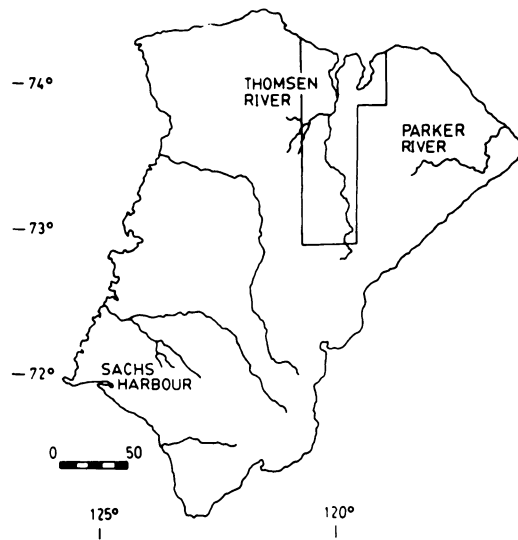


FIGURE 1. The study area on Banks Island, Northwest Territories, Canada is outlined around the Thomsen River drainage. Scale is in km.

During whole island aerial surveys on Banks Island in 1982 and 1985 over 30 skeletal remains and carcasses were observed each time while flying transect lines in the region of the Thomsen River drainage (Latour, 1985; McLean et al., 1986). In July and August of 1986, this study was initiated to investigate the cause of mortality.

## MATERIALS AND METHODS

### Study area

The study area was a 6,400 km<sup>2</sup> section (from 73°00' to 74°20'N and 118°00' to 121°00'W) of the Thomsen River region on northern Banks Island, Northwest Territories, Canada (Fig. 1). Unlike most of Banks Island which is dominated by polar semi-desert and desert communities, the study area has an abundance of well developed sedge meadows (Zoltai et al., 1980) and supports a large proportion of the Banks Island muskox population (Latour, 1985; McLean et al., 1986). This local population is not hunted. Sachs Harbour (population 165), the only community on Banks Island, is 250 km southwest of the study area and Inuvialuit rarely visit the north end of the island. The climate of the area is arctic maritime with long cold winters, short cool summers, and low precipitation (Maxwell, 1981).

From 25 July through 1 August 1986, we used a Bell Jet Ranger 206B helicopter to survey the

Thomsen River drainage and adjacent valleys. Single survey flights were also flown in two areas outside the study area: (1) the Parker River region and (2) between the Thomsen River base camp and Sachs Harbour (Fig. 1).

The age, sex, and location of sick muskoxen, carcasses, and skeletal remains observed from the helicopter were recorded on topographical maps (1:250,000). Muskoxen were aged by horn size and shape and by tooth eruption pattern (Henrichsen and Grue, 1980). Animals  $\geq 4$ -yr-old were classified as adults. Moribund muskoxen that were unable to stand when approached were shot at the base of the skull with a 12 ga shotgun slug. Complete necropsies were done on muskoxen that were shot or were estimated to have died within the previous 5 days. Badly decomposed carcasses and skeletal remains were examined for the presence or absence of femur or humerus marrow fat, however, as increasing numbers of recently dead muskoxen were found, time did not allow landing the helicopter to examine all of them. Their locations continued to be recorded on topographic maps.

Standard necropsy protocol was followed and tissues collected for histopathology were placed in 10% neutral buffered formalin. Tissues collected for bacteriologic, virologic, and parasitologic examination were chilled at the field camp using snow and ice for a maximum of 3 days prior to being frozen in Inuvik, Northwest Territories. All formalin fixed and frozen samples were subsequently examined at the Western College of Veterinary Medicine (Saskatoon, Saskatchewan S7N 0W0, Canada).

Formalin fixed tissue were trimmed and processed by routine paraffin technique and sectioned at 6  $\mu$ m. Sections were stained with hematoxylin and eosin for light microscopic examination. If bacterial colonies were present sections were stained using the Brown and Brenn method (Luna, 1968).

Intestinal contents, mesenteric lymph nodes, and liver were cultivated under aerobic and anaerobic conditions on blood agar plates (containing 5% sheep blood) and MacConkey's agar plates (Difco Laboratories, Detroit, Michigan 48232, USA). To detect *Salmonella* spp., intestinal contents were incubated for 24 hr in Selenite-F broth (BBL, Division of Becton Dickinson and Co., Cockeysville, Maryland 21030, USA) prior to cultivation on Hektoen (Difco) and Brilliant Green agar plates (Difco). Isolates were identified to genus and species according to established criteria (Carter, 1984). Identification of urease positive Enterobacteriaceae was checked using API® strips (Analytab Products, Division of Sherwood Medical, Plainview, New York 11803, USA). Cultures identified as *Y. pseudotuberculosis* were sent to the Yersinia

Reference Laboratory in Rexdale, Ontario for additional confirmation and serotyping.

Intestinal contents were examined for virus particles using negative staining electron microscopy (England and Reed, 1980). Frozen sections of intestine were examined for bovine virus diarrhea (BVD) virus, rotavirus and coronavirus using an indirect immunofluorescence test (Clark et al., 1985). Attempts were made to cultivate BVD virus from ileum and mesenteric lymph node (Clark et al., 1985).

Smears of intestinal mucosal scrapings were examined microscopically for internal parasites and tissue sections were examined closely for parasites by light microscopy.

### RESULTS

Sixty-seven muskox carcasses, 53 skeletal remains, and two sick muskoxen were counted in the Thomsen River study area. The dead and sick animals were found primarily in drainages supporting the most concentrated groups of muskoxen. Most, 109 of 122 (90%), were found within 1,000 km<sup>2</sup> inside the study area. Twelve carcasses and skeletal remains were counted but not examined in the Parker River drainage 50 km west of the Thomsen River and two skeletal remains were seen on a supply flight between the Thomsen River base camp and Sachs Harbour on the south-east corner of Banks Island. Twenty of 29 (69%) muskoxen necropsied died from acute yersiniosis. Of these, 12 were adult males, three were adult females, three were 3-yr-old males, one was a 3-yr-old female and one was a 2-yr-old female.

All 20 animals found dead with yersiniosis were in excellent body condition with ample subcutaneous and internal fat stores. The animals showed marked subcutaneous bruising and hemorrhage usually along the back, brisket and over the thorax on the dependent side. Blood tinged fluid or froth was frequently seen in the nares. The cause of death in each animal was attributed to an acute, severe, hemorrhagic, necrotizing, ulcerative enteritis. Ten of the 20 muskoxen had an associated typhlocolitis. Excessive blood tinged or straw colored fluid was always present in the abdominal cavity. Affected intestines had a diffusely




FIGURE 2. Mucosal surface of the jejunum from a muskoxen with multifocal 1 mm to 3 mm ulcers. Bar = 1 cm.

red serosal surface with a few fibrin strands and dilated lymphatics. The intestinal wall was thickened and the mucosal surface had multifocal to coalescing 1 mm to 3 mm ulcers (Fig. 2) or was diffusely red and rough so discrete ulcers could not be identified. Intestinal contents varied from thin, blood tinged fluid (Fig. 3) to frank blood mixed with necrotic debris, mucous, and fibrin. In four animals large areas of jejunal mucosa had sloughed producing long tubular casts. The most extensive intestinal lesion seen in one muskox involved most of the small intestine (excluding the first 50 cm), the cecum, and the entire proximal loop of the ascending colon. Gross lesions were not always present in the cecum or colon. The minimal intestinal lesion observed in any one animal involved the last 100 cm of small intestine. Regardless of the extent of the intestinal lesion, the terminal small intestine was always the most severely affected. Mesenteric lymph nodes in all animals were enlarged three to seven times normal size, some measuring up to 7 cm in length. On cut surface, focal areas of necrosis and hemorrhage were often present (Fig. 4). A sick, 3-yr-old bull necropsied immediately after being shot had a moderately enlarged spleen and a swollen liver with pinpoint areas of pallor scattered throughout the parenchyma. In all other animals the liver and spleen were too autolyzed for adequate examination.

Tissues collected from the 3-yr-old, sick

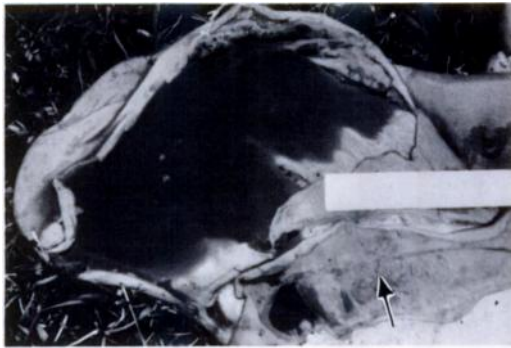

FIGURE 3. Opened cecum from a muskoxen filled with watery, blood tinged fluid. The ileum (arrow) has a rough, thickened mucosal surface. Bar = 12.5 cm.

bull were the best suited for histopathologic examination. Intestinal sections had multifocal to coalescing areas of mucosal ulceration and necrosis with large numbers of neutrophils. This was often seen overlying areas of gut-associated-lymphoid tissue (Fig. 5). Multifocal areas of necrosis and inflammation with central colonies of Gram-negative bacteria were also seen in sections of lung and liver (Fig. 6). Mesenteric lymph nodes were extremely reactive and sinusoids were filled with neutrophils. Most mesenteric lymph nodes had microscopic foci of necrosis containing

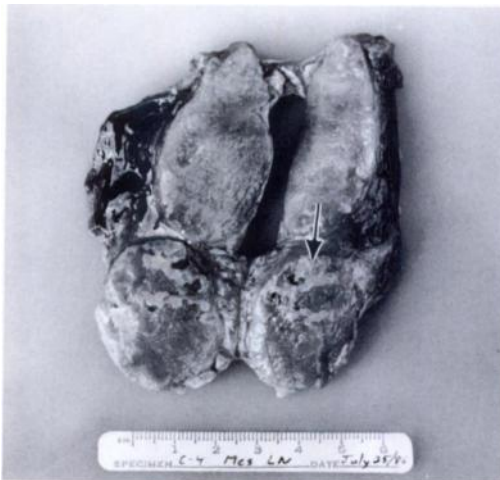

FIGURE 4. The cut surface of an enlarged mesenteric lymph node from a muskoxen permits visualization of multifocal to coalescing areas of necrosis (arrow).

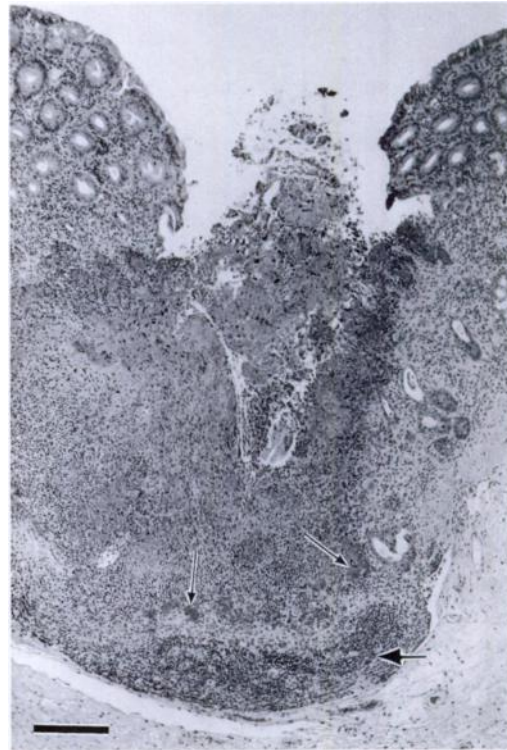


FIGURE 5. Histological section of cecum from a muskoxen with a focal, discrete ulcer over gut-associated lymphoid tissue (large arrow). There is prominent necrosis with a marked inflammatory response consisting primarily of neutrophils. Numerous bacterial colonies can be seen in the lesion (small arrows). H&E. Bar = 700  $\mu$ m.

central bacterial colonies but some had locally extensive areas of necrosis with a marked pyogenic inflammatory response.

Bacteria identified as *Y. pseudotuberculosis* serogroup 1B were isolated in large numbers from the intestines, and in pure culture from the mesenteric lymph nodes and from one liver. No other pathogens were identified despite extensive bacteriologic, virologic, and parasitologic examination. Other bacteria isolated in variable quantity from the intestines but considered relatively insignificant included *Clostridium perfringens*, *Escherichia coli*, and a variety of *Streptococcus* spp.

Of the remaining nine muskoxen necropsied, seven were too autolyzed to make a definitive diagnosis but they had abundant fat stores. These seven animals con-

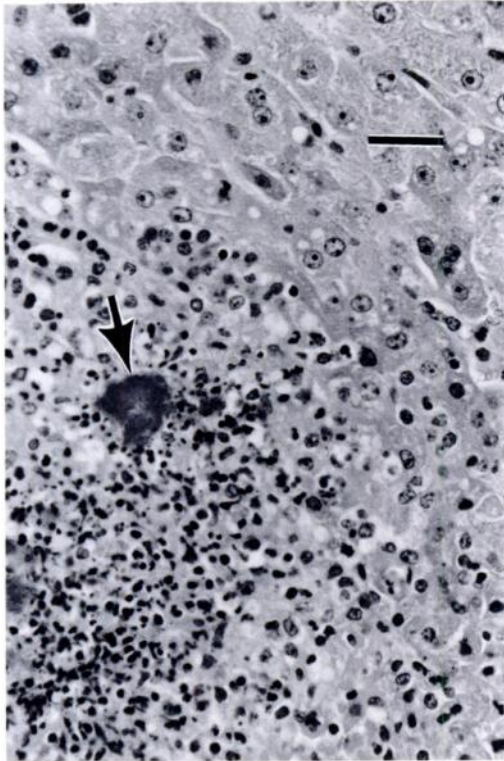


FIGURE 6. Histological section of liver from a muskoxen with a focal area of hepatic necrosis. Note the large bacterial colony (arrow) within the lesion. H&E. Bar = 106  $\mu$ m.

sisted of six adult males and one adult female. The remaining two cases included an emaciated, heavily parasitized adult female found alive and an adult bull which had serous atrophy of all fat stores. Twenty-one skeletal remains were examined of which 14 had solid, fat femur or humerus marrow cores indicating that these animals died in good body condition.

#### DISCUSSION

During the summer of 1986, infection with *Y. pseudotuberculosis* caused an acute, fatal, enterocolitis in muskoxen on northern Banks Island. All animals with yersiniosis were in excellent body condition with ample fat stores. A stressor is often implicated in the pathogenesis of yersiniosis (Obwolo, 1976; Stovell, 1980; Mackintosh and Henderson, 1984a); how-

ever, we propose that nutritional stress is not important in these muskoxen but other as yet unidentified factors are involved. Population density must be considered since the Thomsen River region has the highest density of muskoxen on Banks Island. The entire area has an average of 1.5 muskoxen/km<sup>2</sup> with localized densities as high as 4.0 per km<sup>2</sup> (McLean et al., 1986). This is generally much higher than the 0.6 to 1.5 muskoxen/km<sup>2</sup> reported from other prime muskox habitats (Thomas et al., 1981; Smith, 1984; Pattie, 1986; Thing et al., 1987). Other possible factors that should be considered include the behavioral stress involved with the onset of rut or adverse climatic conditions, particularly unusually hot weather during an arctic summer. Climatic conditions and possible reservoir-carrier hosts may also be important in the maintenance of *Yersinia* spp. in the environment. Many reports of yersiniosis have suggested that wild rodents and birds can act as carriers of *Y. pseudotuberculosis* (Hubbert, 1972; Hacking and Sileo, 1974; Baskin et al., 1977; Stovell, 1980; Mackintosh and Henderson, 1984b). Muskox feeding behavior and habitat selection could be important with respect to exposure to the infectious agent. Muskox on Banks Island, especially the bulls, have been observed to feed predominantly in wet sedge meadows and in drainages. If the infection is water borne such animals are more likely to be exposed. The Banks Island muskox population may have originated from a relatively small number of animals, therefore, it is conceivable that low genetic variability may be related to their susceptibility to infection with *Y. pseudotuberculosis*. The limited data available suggest that muskoxen have less genetic variability than many other ungulates that have been studied (Rowell, 1990).

Muskoxen inhabit a harsh environment of seasonal temperature extremes. Population growth is believed to be limited by density-independent factors, primarily climate. Icing and snow conditions reducing

access to forage have caused large winter die-offs in Greenland and the Canadian arctic (Tener, 1965; Vibe, 1967; Parker et al., 1975; Gray, 1987). Because of Banks Island's remote location and large size, aerial surveys only became possible in the 1970's and 1980's. Most of these were done by fixed wing aircraft which precluded any opportunity to examine dead animals. Therefore, any previously observed mortality was usually assumed to be caused by winter starvation. Wilkinson and Shank (1976) related muskox mortality, seen in the same study area in 1973, to rutting fight injuries. In our opinion, this was not properly documented with detailed necropsies and the authors may have mistaken the bleeding from the nose, excessive blood tinged abdominal fluid and the subcutaneous bruising and hemorrhages seen in cases of yersiniosis for fighting injuries.

The 1973 deaths reported by Wilkinson and Shank (1976), the previous aerial sightings of carcasses and skeletal remains, and the autolyzed carcasses and skeletal remains with fat marrow cores seen in this study suggest that yersiniosis has been occurring for at least 13 yr and may be endemic in the Thomsen River region. The paucity of carcasses and skeletal remains in other areas of Banks Island suggest that this may be a problem that is unique to the Thomsen River drainage. However, since *Y. pseudotuberculosis* is considered ubiquitous, there is potential for this disease to occur in similar muskox habitat in other regions.

Factors such as range conditions, climate, particularly snow and ice conditions, and predation are obviously important population regulators but the influence of disease on the population dynamics of free-ranging muskoxen has not been previously considered. Further investigations are necessary to define the epidemiology and to assess the impact that yersiniosis has on muskoxen population dynamics and what potential role this disease may have on other rapidly expanding muskox populations.

#### ACKNOWLEDGMENTS

This work was funded in part by the Northern Oil and Gas Action Program (Indian and Northern Affairs Canada). The authors wish to thank the Polar Continental Shelf Project, Department of Energy Mines and Resources for logistical support, and Dr. S. Toma of the National Yersinia Reference Centre for serotyping the *Yersinia pseudotuberculosis* isolates.

#### LITERATURE CITED

- BASKIN, G. B., R. J. MONTALI, M. BUSH, T. J. QUAN, AND E. SMITH. 1977. Yersiniosis in captive exotic mammals. *Journal of the American Veterinary Medical Association* 171: 908-912.
- CARTER, G. R. 1984. Diagnostic procedures in veterinary bacteriology and mycology. Charles C Thomas, Springfield, Illinois, 515 pp.
- CLARK, E. G., G. R. NORMAN, AND E. D. JANZEN. 1985. Pathologic and virologic findings associated with bovine virus diarrhea—mucosal disease virus infection in neonatal beef calves in Saskatchewan. *Proceedings of the American Association of Veterinary Laboratory Diagnosticians* 28: 321-330.
- ENGLAND, J. J., AND D. E. R. REED. 1980. Negative contrast electron microscopic techniques for diagnosis of viruses of veterinary importance. *Cornell Veterinarian* 70: 125-136.
- GRAY, D. R. 1987. The muskoxen of Polar Bear Pass. Fitzhenry and Whiteside, Markham, Ontario, Canada, 191 pp.
- HACKING, M. A., AND L. SILEO. 1974. *Yersinia enterocolitica* and *Yersinia pseudotuberculosis* from wildlife in Ontario. *Journal of Wildlife Diseases* 10: 452-457.
- HENRICHSEN, P., AND H. GRUE. 1980. Age criteria in the muskox (*Ovibos moschatus*) from Greenland. *Danish Review of Game Biology* 11: 1-18.
- HONE, E. 1934. The present status of the muskox in arctic North America and Greenland. Special Publication of the American Committee for International Wildlife Protection, Number 5, Philadelphia, Pennsylvania, 87 pp.
- HUBBERT, W. T. 1972. Yersiniosis in mammals and birds in the United States: Case reports and review. *American Journal of Tropical Medicine and Hygiene* 21: 458-463.
- KARBE, E., AND E. D. ERICKSON. 1984. Ovine abortion and stillbirth due to purulent placentitis caused by *Yersinia pseudotuberculosis*. *Veterinary Pathology* 21: 601-606.
- LATOUR, P. 1985. Population estimates for Peary caribou and muskoxen on Banks Island in 1982. Renewable Resources, Government of the Northwest Territories, File Report No. 49, Yellowknife, Northwest Territories, Canada, 21 pp.

- LUNA, L. G. (editor). 1968. Manual of histologic staining methods of the Armed Forces Institute of Pathology. McGraw Hill Company, New York, 258 pp.
- MACKINTOSH, C. G., AND T. G. HENDERSON. 1984a. The epidemiology of yersiniosis in deer. In Proceedings of a deer course for veterinarians, deer branch course no. 1, P. R. Wilson (ed.). New Zealand Veterinary Association, Palmerston North, New Zealand, pp. 34–42.
- , AND ———. 1984b. Potential wildlife sources of *Yersinia pseudotuberculosis* for farmed red deer (*Cervus elaphus*). New Zealand Veterinary Journal 32: 208–210.
- MANNING, T. H., AND A. H. MACPHERSON. 1958. The mammals of Banks Island. Arctic Institute of North America Technical Paper No. 2, The University of Calgary, Calgary, Alberta, Canada, 74 pp.
- MAXWELL, B. 1981. Climatic regions of the Canadian Arctic Islands. Arctic 34: 225–240.
- MCLEAN, B. D., K. JINGFORS, AND R. CASE. 1986. Abundance and distribution of muskoxen and caribou on Banks Island, July 1985. Renewable Resources, Government of the Northwest Territories, File Report No. 64, Yellowknife, Northwest Territories, Canada, 45 pp.
- OBWOLO, M. J. 1976. A review of yersiniosis (*Yersinia pseudotuberculosis* infection). The Veterinary Bulletin 46: 167–171.
- PARKER, G. R., D. C. THOMAS, E. BROUGHTON, AND D. R. GRAY. 1975. Crashes of muskox and Peary caribou populations in 1973–1974 on the Parry Islands, Arctic Canada. Canadian Wildlife Service Progress Note 56: 1–10.
- PATTIE, D. L. 1986. Musk ox density and calf numbers on Devon Island's north coast. Journal of Mammalogy 67: 190–191.
- ROWELL, J. E. 1990. The muskox. In International studbook for muskox (*Ovibos moschatus*), B. Holst (ed.). Copenhagen Zoo, Copenhagen, Denmark, pp. 2–22.
- SMITH, T. E. 1984. Status of muskoxen in Alaska. In Proceedings of the first international muskox symposium, D. R. Klein, R. G. White, and S. Keller (eds.). Biological Papers of the University of Alaska, Special Report No. 4, Fairbanks, Alaska, pp. 15–18.
- STEFANSSON, V. 1921. The friendly Arctic. MacMillan Co., New York, New York, 784 pp.
- STOVELL, P. L. 1980. Pseudotubercular yersiniosis. In CRC Handbook Series in Zoonoses, Section A, vol. II, J. H. Steele (ed.). CRC Press, Boca Raton, Florida, pp. 209–256.
- TENER, J. S. 1965. Muskoxen in Canada: A biological and taxonomic review. Canadian Wildlife Service, Monograph Series, Number 2, Ottawa, Ontario, Canada, 166 pp.
- THING, H., D. R. KLEIN, K. JINGFORS, AND S. HOLT. 1987. Ecology of muskoxen in Jameson Land, northeast Greenland. Holarctic Ecology 10: 95–103.
- THOMAS, D. C., F. L. MILLER, R. H. RUSSELL, AND G. R. PARKER. 1981. The Bailey Point Region and other muskox refugia in the Canadian Arctic: A short review. Arctic 34: 34–36.
- TOMA, S. 1987. Human and nonhuman infections caused by *Yersinia pseudotuberculosis* in Canada from 1962 to 1985. Journal of Clinical Microbiology 24: 465–466.
- URQUHART, D. R. 1973. Oil exploration and Banks Island wildlife. A guideline for the preservation of caribou, muskox and arctic fox populations on Banks Island, Northwest Territories, Canada. Government of the Northwest Territories, Game Management Division, Yellowknife, Northwest Territories, Canada, pp. 105.
- VIBE, C. 1967. Arctic animals in relation to climatic fluctuations. Meddelelser Om Gronland 170: 153–162, 181–192.
- VINCENT, D., AND A. GUNN. 1981. Population increase of muskoxen on Banks Island and implications for competition with Peary caribou. Arctic 34: 175–179.
- WILKINSON, P. F., AND C. C. SHANK. 1976. Rutting fight mortality among muskoxen on Banks Island, Northwest Territories, Canada. Animal Behavior 24: 756–758.
- WILL, R. T. 1984. Muskox procurement and use on Banks Island by nineteenth century Copper Inuit. In Proceedings of the First International Muskox Symposium, D. R. Klein, R. G. White, and S. Keller (eds.). Biological Papers of the University of Alaska, Special Report No. 4, Fairbanks, Alaska, pp. 153–161.
- ZOLTAI, S. C., D. J. KARASIUK, AND G. W. SCOTTER. 1980. A natural resource survey of the Thomsen River area, Banks Island, Northwest Territories. Prepared for Parks Canada, Environment Canada, Ottawa, Ontario, Canada, 153 pp.

Received for publication 8 November 1990.