



ACUTE HEPATOSIS IN THE EUROPEAN BROWN HARE (LEPUS EUROPAEUS) IN ITALY

Authors: Poli, A., Nigro, M., Gallazzi, D., Sironi, G., Lavazza, A., et al.

Source: Journal of Wildlife Diseases, 27(4) : 621-629

Published By: Wildlife Disease Association

URL: <https://doi.org/10.7589/0090-3558-27.4.621>

BioOne Complete (complete.BioOne.org) is a full-text database of 200 subscribed and open-access titles in the biological, ecological, and environmental sciences published by nonprofit societies, associations, museums, institutions, and presses.

Your use of this PDF, the BioOne Complete website, and all posted and associated content indicates your acceptance of BioOne's Terms of Use, available at www.bioone.org/terms-of-use.

Usage of BioOne Complete content is strictly limited to personal, educational, and non - commercial use. Commercial inquiries or rights and permissions requests should be directed to the individual publisher as copyright holder.

BioOne sees sustainable scholarly publishing as an inherently collaborative enterprise connecting authors, nonprofit publishers, academic institutions, research libraries, and research funders in the common goal of maximizing access to critical research.

ACUTE HEPATOSIS IN THE EUROPEAN BROWN HARE (*LEPUS EUROPAEUS*) IN ITALY

A. Poli,¹ M. Nigro,² D. Gallazzi,³ G. Sironi,³
A. Lavazza,⁴ and D. Gelmetti⁴

¹ Dipartimento di Patologia Animale, Profilassi ed Igiene degli Alimenti,
Università di Pisa, 56124 PISA, ITALY.

² Dipartimento di Biomedicina Sperimentale, Infettiva e Pubblica, Sezione di Biologia e genetica,
Università di Pisa, 56124 PISA, ITALY.

³ Istituto di Anatomia Patologica Veterinaria e Patologia Aviare, Facoltà di Medicina Veterinaria
Università di Milano, 20133 MILANO, ITALY

⁴ Istituto Zooprofilattico Sperimentale della Lombardia e dell'Emilia, 25100 BRESCIA, ITALY

ABSTRACT: Since October 1986 an unusually high mortality has been observed both in wild European brown hares (*Lepus europaeus*) and in hare farms in Italy. Pathological alterations, including severe hepatitis, nephrosis, congestion and hemorrhages of tracheal mucosa and lungs, and splenic vascular congestion, were observed in 179 of 381 hares necropsied from 1986 to 1988. Jaundice also was seen in 30% of these hares. Histologically, the liver damage was characterized by coagulative necrosis, mainly located around the portal areas, or by degenerative changes. Hyperemia, focal hemorrhages and periportal mononuclear cell infiltration were also present. The epithelium of renal tubules showed the presence of various degrees of vacuolar degeneration and necrosis, and eosinophilic granular hyaline casts or homogenous proteinaceous material were found within the lumen of tubules. Only the adult hares were affected. In wild hare populations night counts revealed a reduction of the number of observed wild hares during the winter period which ranged from 27 to 40%, whereas in hare farms the mortality ranged from 30 to 90%. Bacteriological, parasitological, and toxicological investigations were unable to confirm the primary cause of these deaths. Negative stain electron microscopy and immunoelectronmicroscopy conducted since October 1988 on liver and spleen homogenates from hares with acute hepatitis revealed the presence of viral particles with morphological aspects resembling those of calicivirus, antigenically related to the etiologic agent of viral haemorrhagic disease of rabbits.

Key words: Acute hepatitis, nephrosis, viral infection, European brown hare, *Lepus europaeus*, mortality.

INTRODUCTION

Since 1986, an unusually high frequency of deaths of European brown hares (*Lepus europaeus*) has been observed in Italy as well as in other countries in Europe. This increased mortality of hares has occurred both in wild hares and on hare farms. Acute hepatitis, enteritis, nephrosis, general jaundice and congestion and hemorrhages of internal organs were the main pathological findings in most of the affected animals. These lesions resembled those alterations observed in hares found dead in other European countries (U. Eskens, pers. comm.; Louzis, 1988; Gavier and Mörner, 1989). The disease has been tentatively named European Brown Hare Syndrome (Gavier and Mörner, 1989) and recently a viral aetiology for this disease was suggested (Lavazza and Vecchi, 1989).

This work was conducted to further study the occurrence of this characteristic syndrome of hares in Italy from 1986 to 1988, and to describe the macroscopic and histological changes in 179 cases that occurred in this period. Furthermore, negative staining electronmicroscopy and immuno-electronmicroscopy methods were conducted in order to confirm the viral aetiology of the disease and to determine if morphological aspects and antigenic properties of the virus may be correlated to the agent of viral haemorrhagic disease (VHD) of rabbits.

MATERIALS AND METHODS

During the period from October 1986 through December 1988, 119 wild European brown hares were found dead in nine protected areas from different parts of North and Central Italy (46°16' to 44°40'N, 7°15' to 13°10'W). In the same period 262 hares coming from 43 hare farms also were

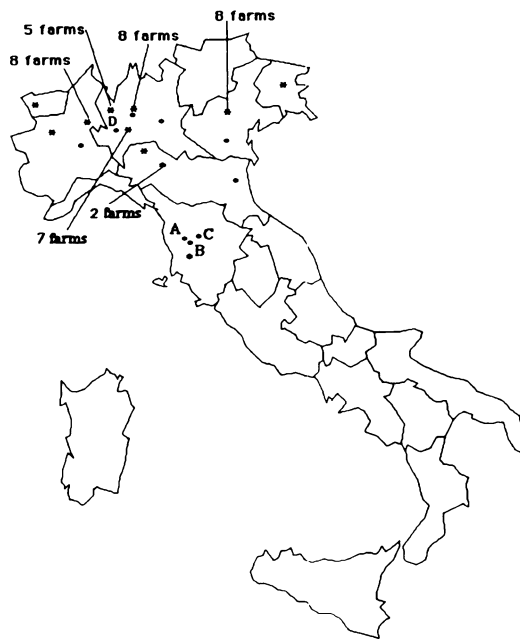


FIGURE 1. Map of the northern and central Italy showing protected areas and hare farms where brown hares were found dead, 1986 to 1988. O, protected areas; *, hare-farms.

examined. In Figure 1 the location of sampled protected areas and of the hare-farms are presented; these consisted of 60 to 450 animals maintained in captivity.

Specimens of liver, intestine, stomach, spleen, kidney, lymph-nodes, lung, trachea, and central nervous system were fixed in 10% buffered formalin solution (pH 7.4). The tissues were then embedded in paraffin and cut at 3 to 5 μ m. Histological examination was performed on Hematoxylin-Eosin (H&E), Masson's trichrome, Periodic acid-Schiff (PAS), von Kossa, and benzidine stained sections. Frozen sections were used for Sudan III staining.

One mm³ pieces of liver from six hares with hepatitis (three wild hares from protected areas and three animals from hare farms) were fixed in Karnovsky's fixative, rinsed overnight in 0.1 M phosphate buffer solution 0.15 M NaCl (PBSS) pH 7.3 and postfixed in 1% osmium tetroxide solution in the same buffer for 2 hr. After dehydration the specimens were embedded in an epon-araldite mixture and cut using LKB Ultratome III (LKB, Bromma, Sweden) by glass or diamond knives. Semithin sections were stained by toluidine blue. Ultrathin sections were stained for contrast by uranyl acetate and lead citrate and examined with an Elmiskope 101 (Siemens, Berlin, Federal Republic of Germany) electron microscope.

Since October 1988 liver and spleen specimens collected from 51 hares (37 wild hares and 14 subjects from hare-farms) were immediately frozen at -20 C and submitted to electron microscopy examination by negative staining technique and immuno-electronmicroscopy (Misciattelli et al., 1981). Homogenates diluted 1:5 in distilled water were twice frozen and thawed and centrifuged at 3,000 g for 15 min to eliminate gross debris. Two milliliters of supernatant were thereafter centrifuged at 10,000 g for 15 min. Seventy-five μ l of the supernatant were transferred into a microtube with specific adapter for 200 mesh copper grid covered with formvar film and centrifuged in a Airfuge Beckman (Beckman Instruments Inc., Palo Alto, California 94304, USA) at 20 psi for 15 min. Afterwards the grids were negatively stained with sodium phosphotungstate 2% pH 7.2 for two min and finally observed by a TEM CM10 Philips (Philips, Eindhoven, The Netherlands) operating at 80 Kv at 25,000 to 52,000 magnifications.

For immuno-electronmicroscopy a rabbit hyperimmune serum anti-VHD virus was used. An optimal dilution (1:20) of this serum was incubated with an equal volume of the double centrifuged liver and spleen homogenates of hares for 1 hr at 37 C, before ultracentrifugation with Airfuge Beckman. The grids were negatively stained as previously described and examined by TEM CM10 Philips electron microscope.

Various tissue specimens from 72 hares (48 wild hares and 24 hares from hare farms) were routinely submitted to bacteriological examinations using blood Agar (containing 5% sheep erythrocytes). After enrichment in Selenite broth (Difco Laboratories, Detroit, Michigan 48232, USA), cultivation was performed on SS Agar (Difco), Brilliant Green Agar (Difco), Desoxychocolate Agar (Difco) and Yersinia Selective Agar (Oxoid Italiana S.p.A., Milano, Italy).

The gastrointestinal contents were examined and an attempt was made to recover all visceral helminths. Visual examination was supplemented by washing and sedimentation of gastrointestinal contents in conical glasses and sediment analysis by stereomicroscopy. All bronchi and bronchioli were also opened and examined to recover visceral helminths (Euzeby, 1982). Fecal samples were both examined after flotation and placed in a Bermann apparatus overnight at 37 C (Golvan and Ambroise-Thomas, 1984).

Three of the protected areas sampled, located in the central part of Italy, were submitted to night counts by hand-held "spotlight" to estimate the size of hare population (Pfister and Rimathe, 1973; Frylestam, 1981). These study areas consisted of 560 ha (area A), 970 ha (area B) and 790 ha (area C) of plains as previously described (Poli et al., 1988).

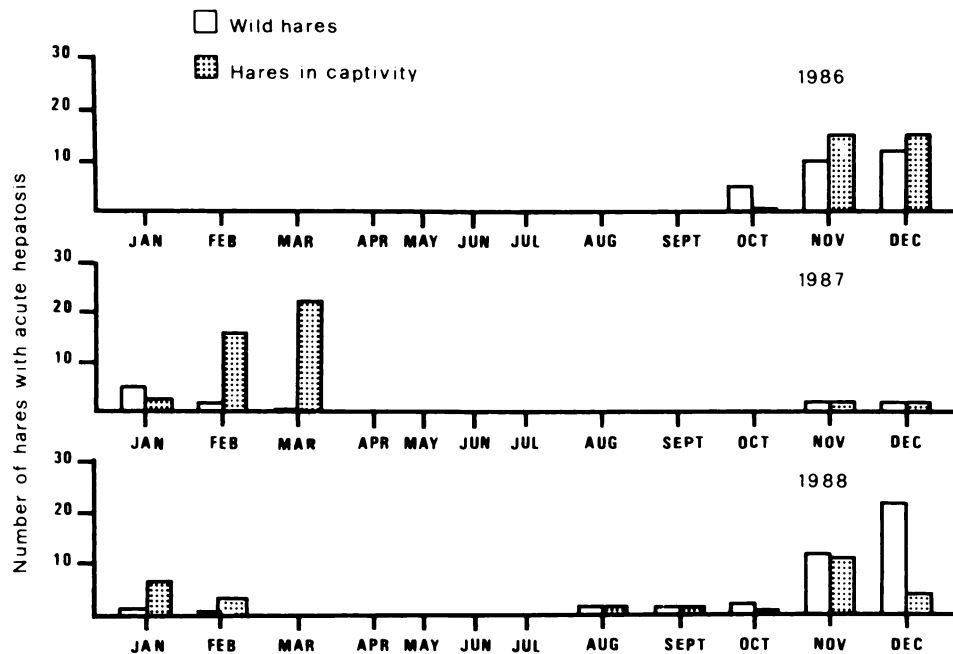


FIGURE 2. Seasonal variations of incidence of acute hepatitis in wild and captive brown hares.

The hares were counted from a car along field roads in autumn (October to November) before the beginning of outbreaks of deaths and in late winter (February to March), usually on four occasions during each season. Counts were made in clear weather between 8:00 P.M. and 11:00 P.M. local time within 1 wk. On the basis of different crop and field types, sampling plots of about 25% of total areas were examined.

During the study period 245 hares were live trapped, in the areas where night counts were conducted, and serum samples were collected to make serological examination for *Leptospira interrogans* serovar *grippotyphosa* by the microagglutination test (MAT).

Samples of liver from five wild hares with hepatitis, found dead in A and B areas, were homogenized in PBSS pH 7.4, the supernatant was centrifuged at $1,500 \times g$ for 15 min and 0.1 ml was inoculated in Rabbit Kidney cells (RK 13); the maintenance medium was Eagle MEM with 5% of Fetal Calf serum. The inoculated cultures were examined daily and subjected to three blind passages.

Liver specimens from 6 wild hares with acute hepatitis, found dead in area D in northern Italy, were submitted to toxicological examinations for chlorinated hydrocarbon insecticides and organophosphorus insecticides by gas chromatography.

RESULTS

Three hundred eighty-one hares (119 wild hares and 262 from hare farms) were

observed during the study period (1986 to 1988). The seasonal occurrence of this syndrome is reported in Figure 2. An altered behaviour characterized by diminished escape distance, loss of balance and sometime incapacity to move, was observed in wild hares; epistaxis was a clinical finding in some of these animals. Behavioural alterations were also observed in hares maintained in captivity. These animals had listlessness, muscle tremors, and sometime epistaxis. Animals >8-mo-old were usually infected while this syndrome was less severe in young hares. On the hare farms the morbidity ranged from 30 to 90% and affected animals mainly died within 1 to 2 days. The farm size did not influence the mortality rate. In wild hare populations, the night counts ranged from 27 to 40%, a reduction in the number of wild hares observed during the winter period.

Generally, postmortem findings in wild and captive hares were similar. Characteristic lesions of acute hepatitis were observed in 77 of 119 wild hares found dead. In the same period outbreaks of this syndrome were observed on 43 hare farms and 102 of 262 hares necropsied from these

farms also showed acute hepatitis. No cases of chronic hepatitis were observed in wild hares or in herded hares. Eighty percent of hares with characteristic clinical signs of acute hepatitis were in very good nutritional condition, as indicated by the presence of well developed perirenal and coronary fat deposits. Only a few animals presented with weight loss. Jaundice was observed in approximately 30% of animals necropsied, and was characterized by marked yellow coloring of sclera and of subcutaneous connective tissue; frequently these animals were in poor nutritional condition. Scattered hemorrhages were observed in conjunctiva, skeletal muscles and mammary glands.

In all hares the stomach was well filled with dry food material and hemorrhages were seldom present on the gastric mucosa. Catarrhal to hemorrhagic enteritis was often observed, more evident in the small intestine. In the lumen of the terminal colon and in the rectum a thick mucus was sometimes found.

The liver was usually of normal size, pale or orange-yellow in color with marked lobuli. In some hares there was a slight hepatomegaly and the liver was dark-red in color. The gall-bladder was always enlarged and full. A moderate enlargement of the spleen, dark-red in color and with increased consistency was observed. Lymph-nodes were enlarged, with dark red hemorrhagic cortical areas.

The kidney was slightly yellow with a marked dark cortico-medullary junction. In most cases the content of urinary bladder was dark colored, and urine analysis revealed proteinuria and presence of hemoglobin. Marked hyperemia and hemorrhages were present on the tracheal mucosa, and the lungs were edematous with focal hemorrhages.

Focal pale areas were rarely found on myocardium. There was congestion of meningeal vessels.

The most important microscopical findings were in the liver and kidneys. In the liver, widespread areas of coagulative ne-

crolosis, particularly in the periportal regions were seen (Fig. 3) and sometime, especially in the animals with jaundice, lobules were entirely necrotic. Congestion of sinusoids and scattered hemorrhages in the liver parenchyma also were present. At the border of the necrotic areas the hepatocytes showed a swollen homogeneous and marked eosinophilic cytoplasm with picnotic and cariorectic nuclei. Cytoplasmic vacuoles, due to fatty degeneration, and intracytoplasmic basophilic granules, positive for the von Kossa staining were also present around the necrotic areas (Fig. 4). Small amounts of mononuclear cell infiltrates, consisting of a few lymphocytes and rare granulocytes, were present in periportal areas.

Tubular nephrosis, characterized by vacuolar degeneration of tubular cells, was observed in 30% of hares. Some of these cells had a strongly eosinophilic cytoplasm and picnotic nuclei, while other cells showed a brown granular pigment (Fig. 5). The tubular lumens were narrowed by the presence of granular eosinophilic hyaline casts of hemoglobin or myoglobin origin, identified by histochemical test. Homogeneous proteinaceous casts also were present in the tubular lumens.

A marked congestion and a slight reduction of lymphatic follicles were present in the spleen. Congestion and hemorrhages of the cortical portion of lymph nodes and a severe reduction of lymphatic follicles were observed.

A marked hyperemia and sometimes submucosal hemorrhages were seen in the tracheal mucosa. In the lungs blood vessel congestion, oedema and scattered hemorrhages were seen, with the latter more rarely observed.

By electron microscopy, widespread calcium deposits were constantly observed in the liver. These consisted of aggregates of osmiophilic material in the shape of dark granules and rings of 60 to 65 nm in size and were delimited by a membrane. Using transmission electron microscopy viral

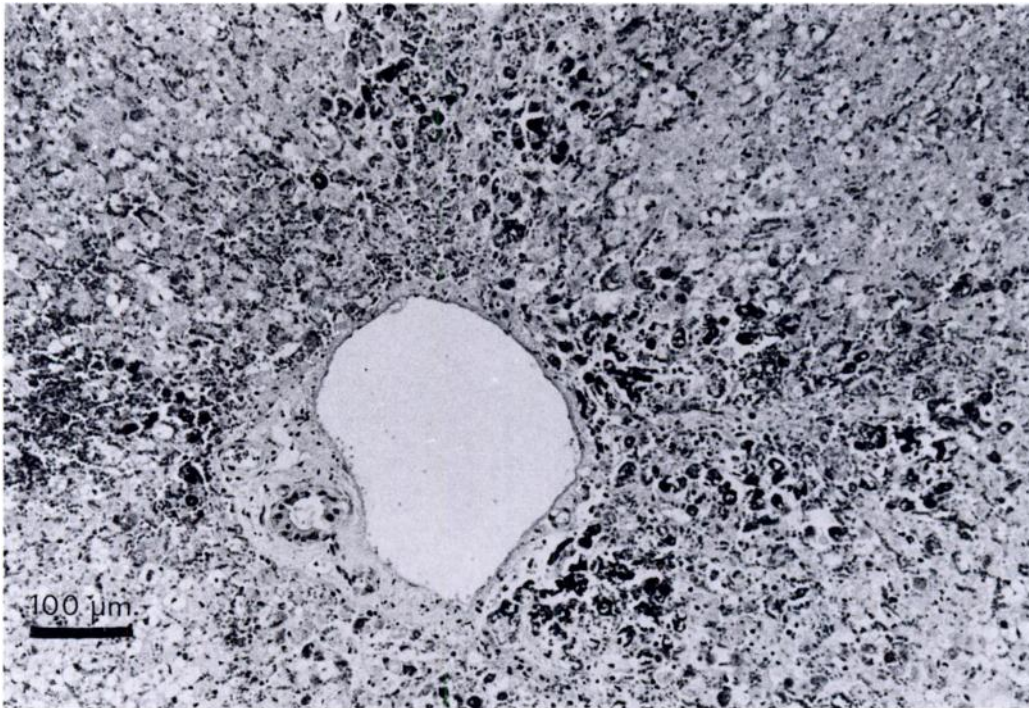


FIGURE 3. Liver of hares with acute hepatitis. Note the large areas of periportal necrosis and marked congestion of sinusoid. Vacuoles and intracytoplasmic basophilic granules are present within hepatocytes. H&E.

particles were never observed in nuclear or cytoplasmic areas.

No specific bacterial infections were cultured from the livers of 46 animals, but *Escherichia coli* was isolated in 15 hares, *Pasteurella* sp. in seven hares, *Klebsiella* sp. in one hare, *Staphylococcus* sp. coagulase positive in one hare and in two subjects no growth of bacteria was observed. All the hares captured were serologically negative to *Leptospira interrogans* serovar *grippityphosa*. The results of parasitological examinations are summarized in Table 1.

Negative staining electron-microscopy of liver and spleen homogenates showed the presence of viral particles in 23 of 51 hares examined. Such icosahedral particles, were 32 to 35 nm in size (Fig. 6), slightly larger than a picornavirus, and distinctive cup-like depressions, frequently set in a six-fold "Star of David" array, were frequently observed in their surface. Emp-

ty viral particles preserved a core 27 nm in size outlined by a rim from which 10 short and evenly spaced tiny projections radiate. By means of immuno-electron-microscopy a specific aggregation of the virus was observed. The clumping in compact groups of a variable number of viral units, surrounded by a dense halo of antibodies was observed in all 23 of the samples which were positive in negative staining electronmicroscopy.

No cytopathic effect was observed in RK 13 tissue cultures from hare organs after three blind passages. Electron microscopic negative staining of cell supernatant and cryolysate also was negative. All the specimens from six hares submitted for toxicological investigations were negative for the presence of organophosphoric and chlorinated hydrocarbon insecticides.

DISCUSSION

Lesions characterized by acute hepatitis, nephrosis and hemorrhagic alterations

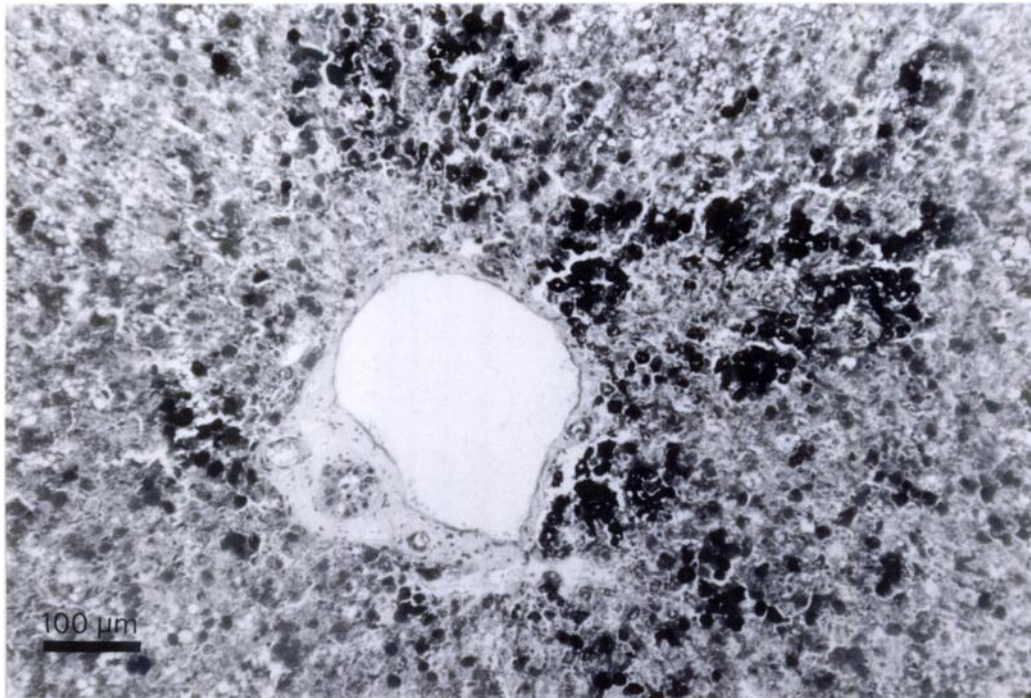


FIGURE 4. Liver of hares with acute hepatitis. Granules within hepatocytes are positively stained. Von Kossa stain.

of internal organs, were revealed in 79 of 119 wild hares found dead. Similar pathological changes also were observed in 102 hares from 43 outbreaks on hare farms.

Hares with similar lesions have been found dead since 1980 in Sweden (Gavier and Mörner, 1989), and 1986 in Middelhessen in the Federal Republic of Germany (Eskens et al., 1987; U. Eskens, pers. comm.). Recently, acute hepatitis was observed in several hare carcasses found in central, northern and east-central France (Louzis, 1988).

In Italy the occurrence of this syndrome in wild and captive hares was observed mainly from the second half of October to March, while in northern Europe the disease appeared from mid-September to December (U. Eskens, pers. comm.; Gavier and Mörner, 1989).

In our study the mortality was higher in captive hare (from 30 to 90%) than in wild hare populations; in the latter there was a reduction of the number of observed

hares in the winter period only ranging from 27 to 40%.

In captive hare the disease appeared suddenly and frequently showed a peracute or acute evolution. Also, in wild hares the illness had a similar rapid evolution as indicated by the very good nutritional condition of a high number of animals (70%). By means of bacteriological, parasitological and toxicological investigations it was not possible to explain the occurrence of the disease.

The liver lesions, were similar to those seen in hares when they are on a diet of plants containing a high level of nitrates. Eskens et al. (1987) supposed that a newly generated OO-kind of rape, whose cultivation has been intensified since 1986, could be responsible for the increased frequency of deaths in hares. This kind of rape is uncommon in Italy, and also the outbreaks of acute hepatitis in hares fed dry commercial food would seem to exclude liver changes being related only to

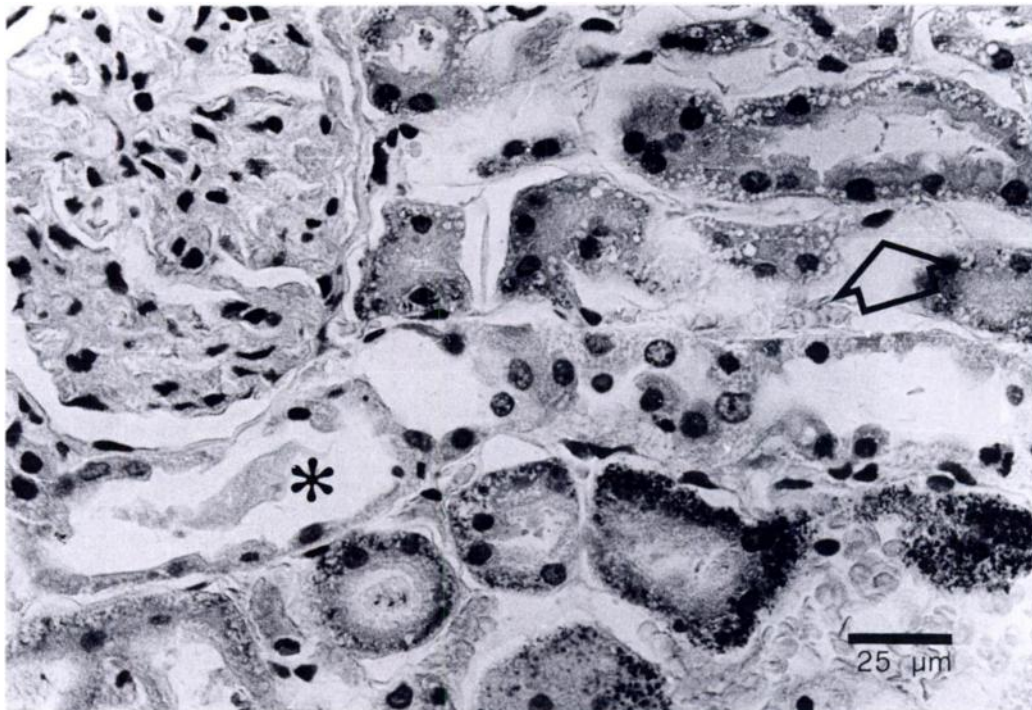


FIGURE 5. Kidney of hares with acute hepatitis. Note the presence of vacuoles (arrow) and granular pigment within the cytoplasm of tubular cells. Homogeneous protineaceous casts also were present within the tubular lumen (*). H&E.

a plant poisoning. Several poisons used in agriculture may cause this type of liver damage but in our study the mortality occurred in a period of the year with reduced use of poisons in farming.

The morphological hepatic alterations, the presence of jaundice, and hemoglobin pigment in kidneys have been proposed to result from enteric infections of toxin-producing bacteria (Louzis, 1988). Investigations carried out to determine the presence of heat-labile and heat-stable toxins in hares with acute hepatitis did not reveal any toxins in the gastrointestinal contents

(Eskens et al., 1987). In our study, bacteriological investigations did not reveal any correlation between this syndrome and pathogenic bacteria, only *E. coli* was occasionally isolated from hares with hepatitis.

By means of negative staining electron microscopy, it was possible to observe the presence of viral particles in 23 of 51 hares examined. Even if attempts to isolate a viral agent did not succeed, the morphological aspect of the viral particles was indicative of the family Caliciviridae. Further investigations are required to evaluate

TABLE 1. Parasites from brown hares with and without acute hepatitis from Italy.

	Hares positive for				
	<i>Etmeria</i> spp.	<i>Tricho-</i> <i>strongylus</i> <i>retortae-</i> <i>formis</i>	<i>Proto-</i> <i>strongylus</i> sp.	<i>Dicrocoe-</i> <i>litum den-</i> <i>driticum</i>	<i>Fasciola</i> <i>hepatica</i>
Hares with acute hepatitis <i>n</i> = 45	41	33	0	0	0
Hares without acute hepatitis <i>n</i> = 27	24	21	2	1	2

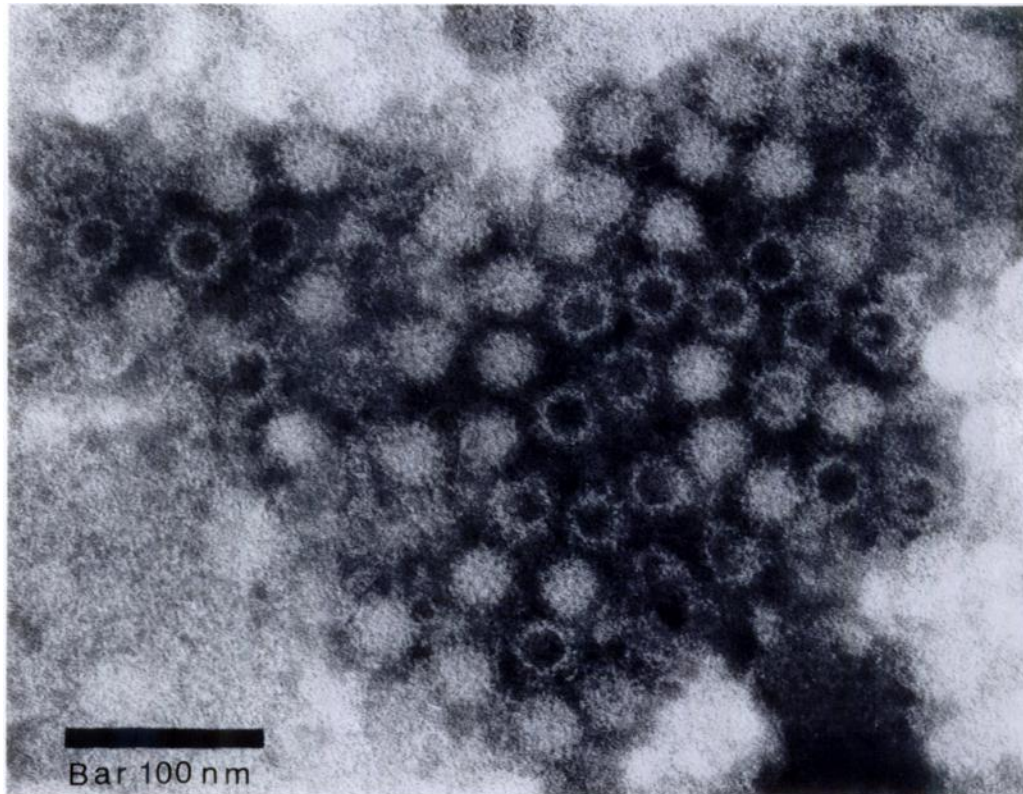


FIGURE 6. Negatively stained transmission electron micrograph of a group of round 32 to 35 nm viral particles in the liver of an hare with acute hepatitis. Both complete and empty virions can be seen.

the role of this agent in the pathogenesis of this syndrome. However, these viral particles resembled morphologically those observed in the liver of rabbits affected by VHD (Liu et al., 1984; Lee and Park, 1987; Buonavoglia et al., 1988). This new disease of rabbits recently appeared in the same areas in which acute hepatitis of hares was recognized (Cancellotti et al., 1990; Morisse, 1988; Loliger et al., 1989). Presently, on the basis of morphological characteristics Xu et al. (1988) maintain that the aetiological agent of the VHD is a single stranded DNA virus, similar to a Parvovirus. However, opposite results, concerning the biochemical and molecular characterisation of the virus, demonstrated that the VHD virus is a calicivirus, made up of a single protein with a molecular weight of 60 Kd and with a genome constituted

by a positive stranded RNA (Ohlinger et al., 1989; Capucci et al., 1990).

In the light of present knowledge and on the basis of the results reported, it is possible to maintain that the virus identified by electronmicroscopy in liver and spleen of hares with acute hepatitis could be the aetiological agent of this syndrome of the European brown hare. Nevertheless, the importance of seasonal factors in the onset of the illness cannot be dismissed. The morphological characteristics of the virus were suggestive of a Calicivirus and the existence of an antigenic cross-relation with VHD virus is proved by the clumping of virions after incubation with an hyperimmune serum. Presently, it seems very important to obtain more information on biochemical and antigenic nature of the virus from hare in order to evaluate wheth-

er these two different diseases of rabbit and hares, characterized similar pathological alterations, are related to the same causative agent or to different, but antigenically related viruses.

LITERATURE CITED

- BUONAVOGLIA, C., L. DI TRANI, R. DI PASQUALE, A. TINARI, F. M. RUGGERI, AND D. GALASSI. 1988. Sui recenti episodi di mortalità nei conigli in Italia. Nota preliminare. *Selezione Veterinaria* 29: 1509-1510.
- CANCELOTTI, F. M., C. VILLERI, M. RENZI, AND R. MONFREDINI. 1988. Le insidie della malattia X del coniglio. *Rivista di Coniglicoltura* 9: 41-46.
- CAPUCCI, L., M. T. SCICLUNA, A. LAVAZZA, AND E. BROCCHI. 1990. Purification and characterization of the causative agent of Viral Haemorrhagic Disease of Rabbit. *Selezione Veterinaria* 31: 301-312.
- ESKENS, U., H. KLIMA, J. NILZ, AND D. WIEGAND. 1987. Leberdystrophie bei hasen. Pathologie und epidemiologische Untersuchungen eines Feldhasensterbens in Mittelhessen. *Tierärztliche Praxis* 15: 229-235.
- EUZEBY, J. 1982. Diagnostic experimental des helminthoses animales. *Informes Tecnicos del Services Veterinaria* 1: 1-349.
- FRYLESTAM, B. 1981. Estimating by spotlight the population density of the European hare. *Acta Theriologica* 26: 419-427.
- GAVIER, D., AND T. MÖRNER. 1989. The European brown hare syndrome in Sweden. *Internationalen Symposium über die Erkrankungen der Zoo und Wildtiere* 31: 261-264.
- GOLVAN, Y. J., AND P. AMBROISE-THOMAS. 1984. Les nouvelles techniques en parasitologie. Flammarion Médecine-Sciences, Paris, France, 37 pp.
- LAVAZZA, A., AND G. VECCHI. 1989. Osservazioni su alcuni episodi di mortalità nelle lepri. Evidenziazione al microscopio elettronico di una particella virale. Nota preliminare. *Selezione Veterinaria* 30: 461-467.
- LEE, C. S., AND C. K. PARK. 1987. Aethiological studies on an acute fatal disease of Angora rabbits: So-called rabbit viral sudden death. *Korean Journal of Veterinary Research* 27: 277-290.
- LIU, S. J., H. P. XUE, B. Q. PU, AND N. H. QUIAN. 1984. A new viral disease in rabbits. *Animal Husbandry and Veterinary Medicine* 16: 253-255.
- LOLIGER, H. C. H., S. MATTHES, AND E. B. LIESS. 1989. Über das Austeten einer infectioner hemorrhagischen Erkrankungen bei Hauscaninken in der Bunderrepublik Deutschland. *Tierärztliche Umschau* 44: 22-25.
- LOUZIS, C. 1988. Hemorrhagic Septicemia Syndrome in the European hare in France. Meeting "Diseases of hares and the European brown hare syndrome," Uppsala, Sweden, October 27th-30th.
- MISCIATTELLI, M. E., G. BIANCARDI, G. L. BELLETTI, AND F. GUARDA. 1981. Problemi diagnostici delle malattie neonatali: contributo della Microscopia Elettronica e della Immuno-Microscopia Elettronica. *Atti Società Italiana delle Scienze Veterinarie* 35: 109-124.
- MORISSE, J. P. 1988. Haemorrhagic septicemic syndrome in rabbit. First observation in France. *Le Point Veterinaire* 20: 835-839.
- OHLINGER, V. F., B. HAAS, R. AHL, AND F. WEILAND. 1989. Die infektiöse hämorrhagische Krankheit der Kaninchen—eine durch ein Calicivirus verursachte Tierseuche. *Tierärztliche Umschau* 44: 284-294.
- PFISTER, H. P., AND R. RIMATHE. 1973. Die Schutzzung des Feldhasenbestandes in einem Solothurner Revier mit Hilfe von Jagdscheinwerfern. *Schweizer Jagdzeitung* 1: 18-20.
- POLI, A., F. FANCIANTI, V. TROCCHI, F. VUJONE, AND G. TENACCIANO. 1988. Influence of population density on seasonal variations of parasitic infections in European hare (*Lepus europaeus*, Pallos). *Internationalen Symposium über die Erkrankungen der Zoo und Wildtiere* 30: 33-319.
- XU, W. Y., N. X. DU, AND S. J. LIU. 1988. A new virus isolated from haemorrhagic disease in rabbits. *In Proceedings of the 4th Congress of the World Rabbit Science Association, Budapest, Hungary*, pp. 456-461.

Received for publication 21 August 1989.