



Occurrence of a *Syngamus* sp. in tundra voles (*Microtus oeconomus*) collected on St. Lawrence Island, Bering Sea

Authors: Sato, Hiroshi, and Kamiya, Masao

Source: Journal of Wildlife Diseases, 28(1) : 134-137

Published By: Wildlife Disease Association

URL: <https://doi.org/10.7589/0090-3558-28.1.134>

BioOne Complete (complete.BioOne.org) is a full-text database of 200 subscribed and open-access titles in the biological, ecological, and environmental sciences published by nonprofit societies, associations, museums, institutions, and presses.

Your use of this PDF, the BioOne Complete website, and all posted and associated content indicates your acceptance of BioOne's Terms of Use, available at www.bioone.org/terms-of-use.

Usage of BioOne Complete content is strictly limited to personal, educational, and non - commercial use. Commercial inquiries or rights and permissions requests should be directed to the individual publisher as copyright holder.

BioOne sees sustainable scholarly publishing as an inherently collaborative enterprise connecting authors, nonprofit publishers, academic institutions, research libraries, and research funders in the common goal of maximizing access to critical research.

Occurrence of a *Syngamus* sp. in tundra voles (*Microtus oeconomus*) collected on St. Lawrence Island, Bering Sea

Hiroshi Sato,¹ and Masao Kamiya,² ¹ Department of Parasitology, Hirosaki University School of Medicine, Hirosaki 036, Japan; ² Department of Parasitology, Faculty of Veterinary Medicine, Hokkaido University, Sapporo 060, Japan

ABSTRACT: A species of syngamid nematode belonging to the genus *Syngamus* was found in the respiratory tract (terminal trachea to bronchi) of tundra voles (*Microtus oeconomus*) collected on St. Lawrence Island, Alaska (USA). Its prevalence in June 1989 was >29% (12 of 41 male voles and seven of 24 females) in the village of Savoonga, while no nematodes were found from 41 voles collected in the village of Gambell. Lesions included dilatation of parasitized respiratory ducts and peribronchial and perivascular cuffing by lymphoid cells, mainly plasma cells, in parasitized lobes. Morphologically, this syngamid species differed from *S. microtinae* reported previously from the same host species as well as from other syngamids known from avian hosts.

Key words: *Syngamus* sp., *Microtus oeconomus*, Nematoda, prevalence, morphology.

Nematodes of the genus *Syngamus* occur usually in the respiratory tract of various species of domestic and wild birds (Ryzhikov, 1949; Skrjabin et al., 1952; Barus and Tenora, 1972a). Other syngamid genera, *Mammomonogamus* and *Rodentogamus* are known to occur in the respiratory tracts of mammals in the tropical region or rodents in the eastern part of Palearctic region, respectively (Baruš and Tenora, 1972a; Lichtenfels, 1980). The latter includes *R. ryjkovi* from *Apodemus agrarius* and *A. speciosus* (Sadovskaja, 1950) and *R. citelli* from *Citellus undulatus* (Ryzhikov, 1956). Recently, however, Fedorov and Chechulin (1980) reported *S. microtinae* from *Clethrionomys rufocanus*, *C. rutilus* and *Microtus oeconomus* and an unidentified *Syngamus* sp. from *C. rufocanus*. Records of occurrence for syngamids from rodents are limited to these three descriptions, each of which referred to only a few cases of infection. There are no reports on prevalence and

pathology of syngamid infection in rodent hosts. In the present work, we report a high prevalence of *Syngamus* sp. in *M. oeconomus* collected at a locality on St. Lawrence Island (Bering Sea, Alaska, USA).

Formalin-fixed lungs of 106 voles collected in two villages on St. Lawrence Island during 10 to 15 June 1989 were processed by routine methods for microscopic examination: 65 voles from Savoonga (63°42'N, 170°29'W) and 41 voles from Gambell (63°47'N, 171°45'W).

Paired nematodes existed in dilated lumina of the terminal trachea and bronchi (Fig. 1). The nematodes were found in 29% of *M. oeconomus* (12 of 41 males and seven of 24 females) from Savoonga. The main lesions due to the adult nematodes were marked dilatation of the respiratory ducts in the parasitized lobe, with peribronchial, peribronchiolar and perivascular cuffing by lymphoid cells, mainly plasma cells. Restricted infiltration of neutrophils and eosinophils was seen where the bronchial mucosa was injured by attachment of adult worms. Some bronchial and bronchiolar epithelium showed mild hypertrophy and/or hyperplasia with increase in number of goblet cells, or rarely focal squamous metaplasia. Occasionally, several or numerous developing to embryonated eggs were scattered in the alveolar spaces, and surrounded by a small number of inflammatory cells including multinucleated giant cells, macrophages and granulocytes. There was one case in which several migrating nematode larvae existed in the pulmonary arterioles (Fig. 2), interstitial tissues and alveolar spaces, besides juvenile worms within the bronchioli. These migrating larvae provoked

acute inflammatory reactions, including arteriolitis and hemorrhages in the interstitium with peribronchiolar and perivascular cuffing by lymphoid cells and granulocytes (Fig. 3).

Other voles had no direct evidence of parasitism, although some from Savoonga (four male voles and five females) had marked lymphoid cuffing around the respiratory ducts and vasculature in the lungs. No voles collected in Gambell showed evidence of the parasites.

We failed to remove complete nematodes from formalin-fixed lungs, but collected some fragments of both female and male parasites. Males were small, measuring 4.0 to 4.9 mm in length and 0.34 to 0.48 mm in maximum width (from three specimens). They attached firmly to the females by means of the copulatory bursa. Females were suspected to be twice or more larger in length and width than male worms. The parasites possessed well developed buccal capsules, of which the internal surface was smooth without longitudinal ribs (Fig. 4). Cuticular corona existed at the oral opening. All six cephalic papillae were sessile. The copulatory bursa was supported by stumpy rays reaching the edge (Fig. 5). Among three male nematodes, differences in number and configuration of the group of dorsal rays were noted. Spicules, equal and straight, were fine, about 0.070 mm in length. Tails of female worms were pointed. The elliptical eggs possessed operculum-like protrusions at each pole and measured 0.092 to 0.100 mm by 0.044 to 0.049 mm (Fig. 6).

The morphological features mentioned above do not correspond to those of members of the genus *Rodentogamus*, but agree with the diagnosis for *Syngamus* (Baruš and Tenora, 1972a; Lichtenfels, 1980). From the same species of host collected in Amur region of USSR, Fedorov and Chechulin (1980) described *S. microtinae*. The parasite examined here, however, differs from this species in having a distinct cuticular corona at the oral opening, pointed tail of female worms and a different con-

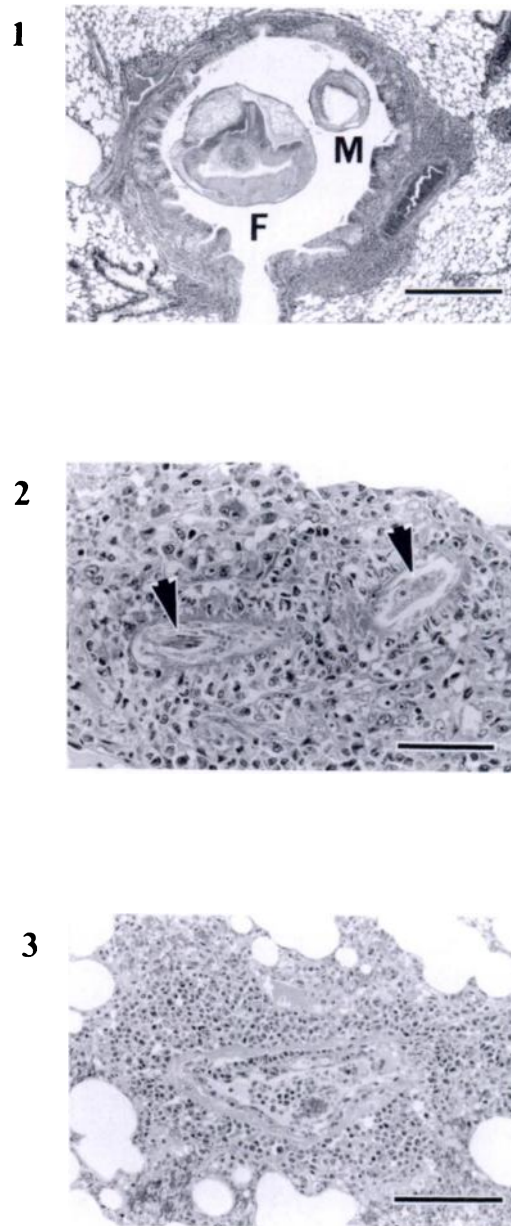


FIGURE 1. Female (F) and male (M) specimens of *Syngamus* sp. located within the bronchial lumen of the tundra vole. Bar = 0.50 mm.

FIGURE 2. A migrating larva of *Syngamus* sp. within the pulmonary arteriole (arrowheads) of a tundra vole. Acute inflammatory reactions of macrophages, neutrophils and eosinophils are marked in the surrounding interstitial tissue. Bar = 0.050 mm.

FIGURE 3. Arteriolitis with perivascular cuffing of lymphoid cells and some granulocytes in lung of a tundra vole infected with *Syngamus* sp. The same case as in Fig. 2. Bar = 0.100 mm.

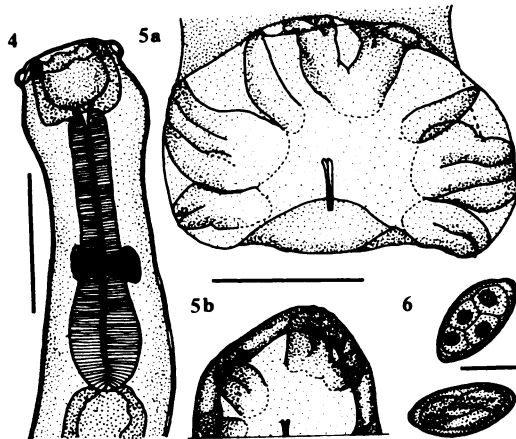


FIGURE 4. Lateral view of anterior end of male *Syngamus* sp. Bar = 0.300 mm. Drawings of Figs. 4–6 were made with the aid of a camera lucida.

FIGURE 5a, b. Posterior end of male *Syngamus* sp. with different numbers and configuration of the dorsal group of rays. The bursa drawn in (b) is not fully extended and the drawing is cut off at level of posterolateral ray. Bar = 0.200 mm.

FIGURE 6. Eggs located in the uterus of *Syngamus* sp. Bar = 0.050 mm.

figuration of bursal rays. This parasite is also different from any syngamid species parasitizing avian hosts. Thus, it is possible that the parasite mentioned here is an undescribed species of the genus *Syngamus*, although better preserved material is needed for more complete description. Variation in the number and configuration of dorsal groups of bursal rays is well documented in many members of syngamids belonging to the subfamily Syngaminae (Ryzhikov, 1949; Skrjabin et al., 1952). Similarly in this case, we actually observed different types of bursal dorsal rays.

Presently, there are only three other reports on syngamids in rodent hosts, each of which documented a lower prevalence of infection (Sadovskaja, 1950; Ryzhikov, 1956; Fedorov and Chechulin, 1980). Consequently, syngamid infection in rodents has been considered to be highly restricted (Sergeeva, 1984). Sergeeva (1984), contrary to Baruš and Tenora (1972a), suggested that all recorded syngamids from rodent hosts represented accidental infec-

tions by parasites of avian hosts, and synonymized *R. ryjikovi* and *R. citelli* with *S. trachea* and *S. microtinae* with *S. merulae* as variants. The present data on occurrence with high prevalence and normal development of parasites accompanied by weak host responses, however, circumstantially supports the existence of syngamid species specifically parasitic to rodent hosts. Further, the fact that there exist at least two species of *Syngamus* (Fedorov and Chechulin, 1980; the present work) in addition to two species of *Rodentogamus* (Sadovskaja, 1950; Ryzhikov, 1956), which parasitize rodent hosts, is of interest in considering the phylogeny of the syngamids (Baruš and Tenora, 1972b).

Parasite materials and histological slides have been deposited in the Department of Parasitology, Faculty of Veterinary Medicine, Hokkaido University (Accession numbers 2899 and 704, respectively).

We wish to express our thanks to R. L. Rausch, University of Washington, for providing us opportunities to participate in his project on St. Lawrence Island in 1988 and 1989; H. Kamiya, Hiroasaki University School of Medicine, for encouragement and valuable suggestions; and S. Kamagai, Meguro Parasitological Museum, for lending us literature. The present study was supported in part by the Ministry of Education, Science and Culture, Japan (Grant Nos. 63044005 and 03044016).

LITERATURE CITED

- BARUŠ, V., AND F. TENORA. 1972a. Notes on the systematics and taxonomy of the nematodes belonging to the family Syngamidae Leiper, 1912. *Acta Universitatis Agriculturae, Facultas Agronomica, Brno* 20: 275–286.
- , AND ———. 1972b. Notes on the evolution of the nematodes belonging to the family Syngamidae Leiper, 1912. *Acta Universitatis Agriculturae, Facultas Agronomica, Brno* 20: 287–295.
- FEDOROV, K. P., AND A. I. CHECHULIN. 1980. [New species of nematodes from the family Syngamidae from rodents]. [In Russian.] *Materialy Nauchnoi Konferentsii Vsesoyuznogo Obshchestva Gel'mintologov (Nematody i nematodozy)* No. 32: 124–128.

- LICHTENFELS, J. R. 1980. Keys to genera of the superfamily Strongyloidea. In CIH keys to the nematode parasites of vertebrates, No. 7, R. C. Anderson, A. G. Chabaud, and S. Willmott (eds.). Commonwealth Agricultural Bureaux, Bucks, England, pp. 1-41.
- RYZHIKOV, K. M. 1949. [Syngamidae of domestic and wild animals.] [In Russian.] In Essentials of nematology, Vol 1, K. I. Skrjabin (ed.). Izdatl'stvo Akademii Nauk SSSR, Moscow, U.S.S.R. pp. 1-164.
- . 1956. [*Syngamus citelli* nov. sp. from a ground squirrel in Iakutiia.] [In Russian.] Trudy Gel'mintologicheskoi Laboratorii Akademii Nauk SSSR 8: 140-143.
- SADOVSKAJA, N. P. 1950. [*Syngamus (Rodentogamus) ryjikovi* nov. subgen. nov. sp. parasite of rodents in Primorskiy kray.] [In Russian.] Trudy Gel'mintologicheskoi Laboratorii Akademii Nauk SSSR. 3: 206-209.
- SERGEVA, T. P. 1984. [Taxonomy of syngamid species from rodents.] [In Russian.] Materialy Nauchnoi Konferentsii Vsesoyuznogo Obshchestva Gel'mintologov (Biologiya i taksonomiya gel'mintov zhivotnykh i cheloveka) No. 34: 67-73.
- SKRJABIN, K. I., N. P. SHIKHOBALOVA, R. S. SCHULZ, T. I. POPOVA, S. N. BOEV, AND S. L. DELYAMURE. 1952. Strongylata. In Key to parasitic nematodes, Vol. 3, Skrjabin, K. I. (ed.). Izdatl'stvo Akademii Nauk SSSR, Moscow (originally in Russian and translated in English by A. Birron and Z. S. Cole, Israel Program for Scientific Translations, Jerusalem, 1961, pp. 177-193).

Received for publication 27 March 1991.