



## **Reticuloendotheliosis in a Wild Turkey (*Meleagris gallopavo*) from Coastal Georgia**

Authors: Hayes, L. E., Langheinrich, K. A., and Witter, R. L.

Source: Journal of Wildlife Diseases, 28(1) : 154-158

Published By: Wildlife Disease Association

URL: <https://doi.org/10.7589/0090-3558-28.1.154>

---

BioOne Complete ([complete.BioOne.org](https://complete.BioOne.org)) is a full-text database of 200 subscribed and open-access titles in the biological, ecological, and environmental sciences published by nonprofit societies, associations, museums, institutions, and presses.

Your use of this PDF, the BioOne Complete website, and all posted and associated content indicates your acceptance of BioOne's Terms of Use, available at [www.bioone.org/terms-of-use](https://www.bioone.org/terms-of-use).

Usage of BioOne Complete content is strictly limited to personal, educational, and non - commercial use. Commercial inquiries or rights and permissions requests should be directed to the individual publisher as copyright holder.

---

BioOne sees sustainable scholarly publishing as an inherently collaborative enterprise connecting authors, nonprofit publishers, academic institutions, research libraries, and research funders in the common goal of maximizing access to critical research.

## Reticuloendotheliosis in a Wild Turkey (*Meleagris gallopavo*) from Coastal Georgia

L. E. Hayes,<sup>1</sup> K. A. Langheinrich,<sup>2</sup> and R. L. Witter,<sup>3</sup> <sup>1</sup> Southeastern Cooperative Wildlife Disease Study, Department of Parasitology, College of Veterinary Medicine, The University of Georgia, Athens, Georgia 30602, USA; <sup>2</sup> United States Department of Agriculture, Food Safety Inspection Service, Russell Research Center, Athens, Georgia 30602, USA; <sup>3</sup> United States Department of Agriculture, Agricultural Research Service, Avian Disease and Oncology Laboratory, 3606 East Mount Hope Road, East Lansing, Michigan 48823, USA

**ABSTRACT:** An emaciated wild turkey (*Meleagris gallopavo*) exhibiting neurologic signs was found on Ossabaw Island, Chatham County, Georgia (USA) on 11 April 1989. The neurologic abnormalities observed included ataxia, drooping wings, head tremors, torticollis, and circling. At necropsy, discrete yellowish-white nodules, varying in size from 2 to 5 mm, were present in the spleen. White nodular lesions approximately 2 mm in diameter were observed beneath the mucosal surface of the distal esophagus. Histopathologic examination of the splenic nodules disclosed large numbers of primitive lymphoreticular cells with leptochromatic nuclei and abundant, slightly basophilic cytoplasm. The mitotic index in these cells was moderate to high. Similar neoplastic cells composed the masses observed in the esophagus. Multifocal, mild perivascular cuffing with mononuclear cells was found in the lumbar spinal cord, brain, and brain stem. Reticuloendotheliosis virus, subtype 3, was isolated from samples of the spleen and liver.

**Key words:** Wild turkey, *Meleagris gallopavo*, reticuloendotheliosis, reticuloendotheliosis virus, avian retrovirus, avian lymphoproliferative disease

Lymphoproliferative and Marek's-like diseases rarely have been reported in free-ranging wild turkeys (*Meleagris gallopavo*) in the southeastern United States (Davidson et al., 1985; Busch and Williams, 1970). In these reports, a causative virus was not identified. Herpesviruses have been isolated from wild turkeys in Florida, but no definitive link between these viruses and lymphoproliferative disease in turkeys has been established (Colwell et al., 1973; Grant et al., 1975). Recently, reticuloendotheliosis virus (REV), subtype 2, was isolated from a wild turkey in North Carolina (Ley et al., 1989). Infiltrates of neoplastic cells consistent with those seen in lymphoproliferative disease/reticuloendotheliosis

were observed in the spleen, liver, lung, and oral and esophageal mucosa in this bird (Ley et al., 1989).

On 11 April 1989, a wild turkey that was weak and could not fly more than a few feet was found by the Georgia Department of Natural Resources' Area Manager on Ossabaw Island, Georgia (31°47'N, 81°07'W). Ossabaw Island is a 10,117 hectare barrier island off the coast of Georgia. Upland habitats cover approximately 4,775 ha, while the remainder of the island consists of fresh and saltwater marshes. A variety of introduced domestic and exotic species inhabit the island in addition to native wildlife characteristic of the southeastern coastal USA (Johnson et al., 1974).

The sick turkey routinely had been observed feeding with several domestic fowl, including domestic chickens, Japanese chickens, guinea fowl, peafowl, and several types of geese, kept by a private individual on the island. Although the turkey was wild, it was habituated to being fed.

The wild turkey was captured and transported to the Southeastern Cooperative Wildlife Disease Study (SCWDS) diagnostic laboratory. Physical examination disclosed a thin female bird with a prominent keel. No ocular or nasal discharges were observed, and the infraorbital sinuses were not swollen. When allowed to stand unrestrained, the bird either held its head low and experienced intention tremor-like movements or exhibited torticollis. The turkey's wings drooped slightly, and it tended to circle to the left. The bird's movements were ataxic, and it often fell. Blood samples were collected in sterile tubes with and without EDTA. The bird

was then euthanatized with T-61 Euthanasia Solution (Taylor Pharmacal Company, Decatur, Illinois 62525).

At necropsy, multifocal white 2 mm nodules were observed within the mucosa of the distal portion of esophagus. These lesions were numerous and easily visible from the mucosal surface. Multifocal yellowish-white nodules which varied in size from 2 to 5 mm were scattered throughout the splenic parenchyma. The spleen did not appear grossly enlarged. The following tissues were collected and preserved in 10% buffered neutral formalin for histopathologic examination: lung, trachea, heart, esophagus, crop, liver, proventriculus, gizzard, small and large intestine, spleen, air sac, ovary, sciatic and brachial plexus nerves, cervical, thoracic and lumbar spinal cord, cerebrum, and cerebellum. All of the listed tissues were evaluated microscopically. Formalin-fixed tissues were deposited with the Armed Forces Institute of Pathology (Accession No. 2325076). Portions of the brain, lung, liver and spleen also were frozen at  $-70^{\circ}\text{C}$  and later used in an attempt to isolate viruses. Tracheal and cloacal swabs were taken for *Mycoplasma* sp. culture attempts, and serum was obtained for *Mycoplasma* sp., avian influenza virus and Newcastle disease virus serology from the blood collected prior to death.

Histopathologic examination of tissues disclosed neoplastic lesions in the esophagus and spleen. In the spleen, multiple foci of neoplastic infiltrates consisted of primitive lymphoreticular cells with leptochromatic nuclei and abundant slightly basophilic cytoplasm with a moderate to high mitotic index. These cells were compatible in appearance with those described as being typical of REV tumor cells (Riddell, 1987). The nuclei of these cells were round to ovoid and centrally or eccentrically placed. Many mononuclear cells contained hyaline, eosinophilic, globular material in the cytoplasm. Identifiable plasma cells, heterophils, and spindle-shaped cells associated with a fine connective tissue stro-

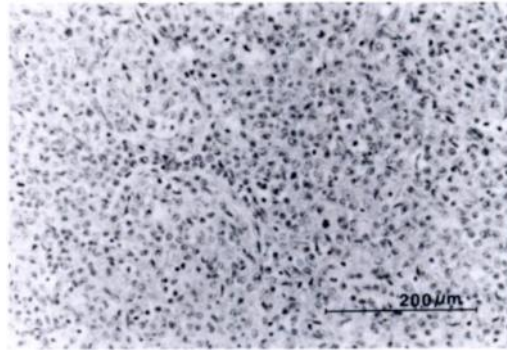


FIGURE 1. Splenic neoplastic infiltrate composed of primitive lymphoreticular cells with leptochromatic nuclei, abundant cytoplasm, and numerous mitotic figures. Plasma cells, heterophils, and spindle-shaped cells associated with fine connective tissue stroma are also present. H&E.

ma also were components of the masses (Fig. 1).

The esophageal nodules were composed of neoplastic cells similar to those observed in the splenic lesions. These groups of cells were observed adjacent to and sometimes obliterating esophageal glands and normal bursal-derived lymphoid tissue. In some cases the lymphoreticular cells appeared to be invading or impinging on the stratified squamous mucosa. Mitotic figures were common (Fig. 2). Multifocal, mild perivascular cuffing with mononuclear inflammatory cells was observed in the lumbar spinal cord, brain, and brain stem (Fig. 3). Lesions associated with peripheral or visceral nerves were not seen.

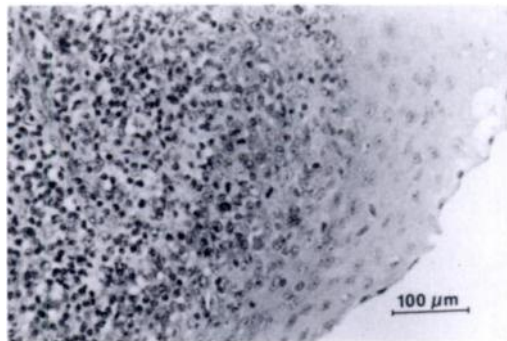


FIGURE 2. Stratified squamous epithelium of esophagus with invasion by lymphoreticular cells. Note several mitotic figures. H&E.

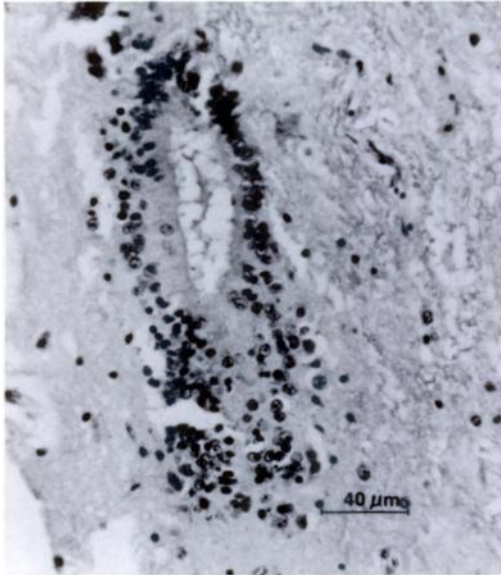


FIGURE 3. Perivascular cuff of lymphocytes and plasma cells adjacent to central canal in lumbar spinal cord. H&E.

An attempt was made to isolate Newcastle disease and avian influenza viruses from frozen cerebral and cerebellar brain tissue and lung tissue. Ten percent tissue suspensions were made in brain heart infusion broth and inoculated into nine to ten day old chicken embryos. No embryo mortality or hemagglutinating activity of allantoic fluids was observed on either of two passages. The bird was serologically negative for antibody to Newcastle disease by the hemagglutination inhibition test and serologically negative for avian influenza by a standard agar gel precipitin test. *Mycoplasma gallopavonis* was isolated from tracheal, cloacal, and air sac swabs. *Mycoplasma gallopavonis* isolates from turkeys have been shown to be pathogenic to chicken and turkey embryos (Rocke and Yuill, 1987), but there have been no reports of naturally occurring disease caused by this agent in wild turkey populations. The turkey was serologically negative for antibody to *M. gallisepticum* by the rapid plate agglutination test using Salsbury plate antigens according to the manufacturer's

procedures (Salsbury Laboratories, Inc., Charles City, Iowa 50616, USA). Reticuloendotheliosis virus was isolated from frozen samples of liver and spleen. Test samples consisted of 1:10 dilutions of crude homogenates of liver and spleen in cell culture medium. Virus was isolated by inoculation of 0.1 ml of test sample into 24-hour chicken embryo fibroblast monolayers in 35-mm dishes. Following a 7-day culture period, supernatant fluids were transferred to chicken embryo fibroblast monolayers containing coverslips. After an additional 3-day culture period, the coverslips were removed, fixed, and evaluated for viral antigen by an indirect immunofluorescent assay (Chen et al., 1987) using a 1:200 dilution of monoclonal antibody 11A25 specific for REV (Cui et al., 1986). Supernatant fluid from cultures positive by immunofluorescent staining were saved at  $-196^{\circ}\text{C}$  and used as a virus stock. The REV isolates from both the liver and spleen were categorized as subtype 3 based on immunofluorescent staining with a battery of monoclonal antibodies (Chen et al., 1987). Isolation of REV coupled with the presence of neoplastic lymphoreticular lesions supports the diagnosis of reticuloendotheliosis in this bird.

Reticuloendotheliosis viruses are classified as retroviruses. They have been associated with multiple syndromes in domestic birds including runting, acute reticulum cell neoplasia, and chronic neoplasia manifested by lymphoid tumors (Witter, 1991). The runting syndrome is characterized by retardation in physical development, atrophy of lymphoid tissues, anemia, proventriculitis, enteritis, abnormal feather development, enlarged peripheral nerves, and immunodepression (Witter, 1991).

Reticuloendotheliosis viruses are similar to but distinct from the leukosis/sarcoma group of avian retroviruses (Witter, 1991). Natural hosts for REV include turkeys, chickens, ducks, geese and Japanese quail. Experimental infections have been produced in pheasants and guinea fowl in ad-

dition to these natural hosts (Witter, 1991; Riddell, 1987).

Serologic evidence indicates that REV is widely distributed in domestic and some wild avian species, particularly in the southeastern United States, and is not always associated with clinical disease (Witter, 1991). There are three antigenic subtypes of the virus which can be identified using monoclonal antibodies (Chen et al., 1987). All three subtypes have been isolated from turkeys (Chen et al., 1987). Although the different subtypes possess similar biological properties, differences in pathogenicity exist (Purchase et al., 1973; Kang et al., 1975; Bauer and Temin, 1980). At the present time there is little or no information on differences in epizootiology for these subtypes (Witter, 1991). The viruses have been shown to be transmissible by several different routes. Direct contact with infected birds is considered the primary mode of transmission (Paul et al., 1977; Witter and Johnson, 1985). Virus has been isolated from feces, ocular and oral secretions, cloacal swabs, and litter (Peterson and Levine, 1971; Witter and Johnson, 1985; Bagust et al., 1981). Vertical transmission has been reported in immunotolerantly infected turkeys (McDougall et al., 1980; Bagust et al., 1981; Witter and Salter, 1989). The relative role of these modes of transmission in the natural epizootiology of the disease is unknown (Witter, 1991). The possibility of mechanical transmission by insects has been considered, but its importance is as yet not proven (Witter, 1991; Witter and Johnson, 1985; Motha et al., 1983). Artificial transmission by inoculation with REV-contaminated vaccines has occurred in domestic flocks (Witter, 1991).

It is nearly impossible to definitively differentiate the etiological agents which give rise to avian lymphoproliferative diseases using histopathology alone. The lesions produced vary greatly, and none appear to be pathognomonic. Therefore, serology or virus isolation must be used to aid in arriving at a definitive diagnosis.

This is the second report of reticuloendotheliosis in a wild turkey in the southeastern United States. This turkey was observed in close association with domestic birds, and it is probable that this was the source of the infection. The existence and possible importance of this virus in truly wild populations is unknown. However, this case, coupled with the report from North Carolina (Ley et al., 1989) indicates that this virus should be considered when a lymphoproliferative disease is encountered in a wild turkey. Further work on the epizootiology of these viruses in wild populations may be warranted in the future.

This study was supported by an appropriation from the Congress of the United States to the Southeastern Cooperative Wildlife Disease Study, Department of Parasitology, College of Veterinary Medicine, The University of Georgia. Funds were administered and research coordinated under the Federal Aid in Wildlife Restoration Act (50 Stat. 917) and through Contract Number 14-16-0004-89-912, Fish and Wildlife Service, U.S. Department of the Interior.

Special thanks to W. O. Fletcher, Georgia Department of Natural Resources, for submission of the case, and to V. F. Nettles, W. R. Davidson, and M. P. Luttrell for editorial advice.

#### LITERATURE CITED

- BAGUST, T. J., T. M. GRIMES, AND N. RATNAMOHAN. 1981. Experimental infection of chickens with an Australian strain of reticuloendotheliosis virus 3. Persistent infection and transmission by the adult hen. *Avian Pathology* 10: 375-385.
- BAUER, G., AND H. M. TEMIN. 1980. Specific antigenic relationships between the RNA-dependent DNA polymerases of avian reticuloendotheliosis viruses and mammalian type C retroviruses. *Journal of Virology* 34: 168-177.
- BUSCH, R. H., AND L. E. WILLIAMS, JR. 1970. A Marek's disease-like condition in Florida turkeys. *Avian Diseases* 14: 550-554.
- CHEN, P. Y., Z. Z. CUI, L. F. LEE, AND R. L. WITTER. 1987. Serologic differences among nondefective reticuloendotheliosis viruses. *Archives of Virology* 93: 233-246.
- COLWELL, W. M., C. F. SIMPSON, L. E. WILLIAMS,

- JR., AND D. J. FORRESTER. 1973. Isolation of herpesvirus from wild turkeys in Florida. *Avian Diseases* 17: 1-11.
- CUI, Z., L. F. LEE, R. F. SILVA, AND R. L. WITTER. 1986. Monoclonal antibodies against avian reticuloendotheliosis virus: Identification of strain-specific and strain-common epitopes. *The Journal of Immunology* 136: 4237-4242.
- DAVIDSON, W. R., V. F. NETTLES, C. E. COUVILLION, AND E. W. HOWERTH. 1985. Diseases diagnosed in wild turkeys (*Meleagris gallopavo*) of the southeastern United States. *Journal of Wildlife Diseases* 21: 386-390.
- GRANT, H. G., K. D. LEY, AND C. F. SIMPSON. 1975. Isolation and characterization of a herpesvirus from wild turkeys (*Meleagris gallopavo osceola*) in Florida. *Journal of Wildlife Diseases* 11: 562-565.
- JOHNSON, A. S., H. O. HILLESTAD, S. F. SHANHOLTZER, AND G. F. SHANHOLTZER. 1974. An ecological survey of the coastal region of Georgia. National Park Service, Science Monograph Series Number 3, United States Government Publishing Office, 232 pp.
- KANG, C.-Y., T. C. WONG, AND K. V. HOLMES. 1975. Comparative ultrastructural study of four reticuloendotheliosis viruses. *Journal of Virology* 16: 1027-1038.
- LEY, D. H., M. D. FICKEN, D. T. COBB, AND R. L. WITTER. 1989. Histomoniasis and reticuloendotheliosis in a wild turkey (*Meleagris gallopavo*) in North Carolina. *Journal of Wildlife Diseases* 25: 262-265.
- MCDUGALL, J. S., R. W. SHILLETTO, AND P. M. BIGGS. 1980. Experimental infection and vertical transmission of reticuloendotheliosis virus in the turkey. *Avian Pathology* 9: 445-454.
- MOTHA, M. X. J., J. R. EGERTON, AND A. W. SWEENEY. 1983. Some evidence of mechanical transmission of reticuloendotheliosis virus by mosquitoes. *Avian Disease* 28: 858-867.
- PAUL, P. S., K. H. JOHNSON, K. A. POMEROY, B. S. POMEROY, AND P. S. SARMA. 1977. Experimental transmission of reticuloendotheliosis in turkeys with the cell-culture-propagated reticuloendotheliosis viruses of turkey origin. *Journal of the National Cancer Institute* 58: 1819-1824.
- PETERSON, D. A., AND A. S. LEVINE. 1971. Avian reticuloendotheliosis virus (strain T) IV. Infectivity in day-old cockerals. *Avian Diseases* 15: 874-883.
- PURCHASE, H. G., C. LUDFORD, K. NAZERIAN, AND H. W. COX. 1973. A new group of oncogenic viruses: Reticuloendotheliosis, chick syncytial, duck infectious anemia, and spleen necrosis viruses. *Journal of the National Cancer Institute* 51: 489-499.
- RIDDELL, C. 1987. Lymphoid System. In *Avian histopathology*, 1st ed., C. Riddell (ed.). American Association of Avian Pathologists, Allen Press, Lawrence, Kansas, pp. 7-17.
- ROCKE, T. E., AND T. M. YUILL. 1987. Microbial infections in a declining wild turkey population in Texas. *Journal of Wildlife Management* 51: 778-782.
- WITTER, R. L. 1991. Reticuloendotheliosis. In *Diseases of poultry*, 9th ed., B. W. Calnek, H. J. Barnes, C. W. Beard, W. M. Reid, and H. W. Yoder, Jr. (eds.). Iowa State University Press, Ames, Iowa, pp. 406-417.
- , AND D. C. JOHNSON. 1985. Epidemiology of reticuloendotheliosis virus in broiler breeder flocks. *Avian Diseases* 29: 1140-1154.
- , AND D. W. SALTER. 1989. Vertical transmission of reticuloendotheliosis virus in breeder turkeys. *Avian Diseases* 33: 226-235.

*Received for publication 21 January 1991.*