



MORTALITY OF FALLOW DEER (DAMA DAMA) EXPERIMENTALLY-INFECTED WITH MENINGEAL WORM, PARELAPHOSTRONGYLUS TENUIS

Authors: Pybus, M. J., Samuel, W. M., Welch, D. A., Smits, J., and Haigh, J. C.

Source: Journal of Wildlife Diseases, 28(1) : 95-101

Published By: Wildlife Disease Association

URL: <https://doi.org/10.7589/0090-3558-28.1.95>

BioOne Complete (complete.BioOne.org) is a full-text database of 200 subscribed and open-access titles in the biological, ecological, and environmental sciences published by nonprofit societies, associations, museums, institutions, and presses.

Your use of this PDF, the BioOne Complete website, and all posted and associated content indicates your acceptance of BioOne's Terms of Use, available at www.bioone.org/terms-of-use.

Usage of BioOne Complete content is strictly limited to personal, educational, and non - commercial use. Commercial inquiries or rights and permissions requests should be directed to the individual publisher as copyright holder.

BioOne sees sustainable scholarly publishing as an inherently collaborative enterprise connecting authors, nonprofit publishers, academic institutions, research libraries, and research funders in the common goal of maximizing access to critical research.

MORTALITY OF FALLOW DEER (*DAMA DAMA*) EXPERIMENTALLY-INFECTED WITH MENINGEAL WORM, *PARELAPHOSTRONGYLUS TENUIS*

M. J. Pybus,¹ W. M. Samuel,² D. A. Welch,² J. Smits,³ and J. C. Haigh³

¹ Alberta Fish and Wildlife Division, O. S. Longman Building, 6909-116 Street,
Edmonton, Alberta, Canada T6H 4P2

² Department of Zoology, University of Alberta, Edmonton, Alberta, Canada T6G 2E9

³ Western College of Veterinary Medicine, University of Saskatchewan,
Saskatoon, Saskatchewan, Canada S7N 0W0

ABSTRACT: Six fallow deer (*Dama dama*) fawns died after receiving 25 to 150 infective larvae of *Parelaphostrongylus tenuis*. Fawns given higher doses usually died sooner (6 to 23 days) than those given lower doses (54 to 67 days). Early deaths were associated with severe acute peritonitis resulting from perforation of the intestinal wall; later deaths were associated with paralysis and inability to rise. Numerous adult *P. tenuis* were found within neural tissues of the brain and spinal cord in the three fawns with paralysis. One white-tailed deer (*Odocoileus virginianus*) exposed to infective larvae from the same source survived infection without exhibiting clinical signs and began passing larvae in feces 88 days post-exposure. At the doses used in this study, meningeal worm caused fatal infections in fallow deer. Results are compared to published observations of fallow deer naturally-infected with *P. tenuis*.

Key words: Fallow deer, *Dama dama*, mortality, meningeal worm, *Parelaphostrongylus tenuis*, experimental study, pathology, transmission.

INTRODUCTION

Meningeal worm (*Parelaphostrongylus tenuis*) has received much attention as an important nematode parasite of ungulates of North America. It establishes benign infections in white-tailed deer (*Odocoileus virginianus*) but can cause fatal neurologic disease in individuals of many other species of ungulates in free-ranging, captive or experimental situations (see review by Anderson and Prestwood, 1981). Meningeal worm in white-tailed deer currently extends throughout broad areas of eastern North America and poses a serious concern in the management of cervids, particularly moose (*Alces alces*) and wapiti (*Cervus elaphus*). Some attempts to establish populations of these and other ungulate species in southeastern Canada and eastern United States have met with failure, in part, as a result of the effects of meningeal worm (Severinghaus and Jackson, 1970; Anderson, 1971; Trainer, 1973; Severinghaus and Darrow, 1976; Nettles et al., 1977a; Bergerud and Mercer, 1989).

The effects of meningeal worm in fallow deer (*Dama dama*) are not clearly understood. In Kentucky (USA) a free-ranging

population of fallow deer has existed sympatric with white-tailed deer and *P. tenuis* since the 1920's. Clinical neurologic disease and death of fallow deer infected with meningeal worm have been reported (Kistner et al., 1977; Nettles et al., 1977b); however, some fallow deer apparently survive infection and may become resistant to reinfection (Davidson et al., 1985).

In recent years, fallow deer have increased in popularity as a game farm species in North America. Expansion of this industry will undoubtedly result in increased demand to translocate fallow deer to or from areas where they may be exposed to *P. tenuis*. Such translocations raise the two important questions of (1) can meningeal worm affect the success of translocated fallow deer, and (2) can *P. tenuis* mature in fallow deer and pose subsequent risk of translocating the parasite?

To address these questions, we exposed fallow deer fawns to 25 to 150 third-stage larvae of *P. tenuis*. Infection was fatal in all cases. Natural exposure and transmission of meningeal worm to free-ranging fallow deer in Kentucky are assessed in light of these results.

MATERIALS AND METHODS

In August 1989, 12 fallow deer fawns were acquired from a game farm in southeastern Saskatchewan (Canada) and transported to the Ellerslie Research Station (University of Alberta, Edmonton, Alberta, Canada T6G 2E9). In addition, we received one wild orphaned white-tailed deer fawn collected in Alberta. All fawns were housed inside, on cement, and bottle-fed a 2:1 mixture of whole milk and evaporated milk until weaned onto a pelleted alfalfa-based ration approximately 5 wk after arrival at Ellerslie (Pybus, 1983).

Six 5-wk-old fallow deer were exposed to 25 to 150 infective third-stage larvae of *P. tenuis* (Table 1). The identity of these larvae as meningeal worm was verified previously (Pybus et al., 1990). The source of larvae used in the current study was as follows: first-stage larvae collected from feces of white-tailed deer in western Pennsylvania were passaged through laboratory-reared snails (*Triodopsis multilineata*), a hand-reared white-tailed deer fawn, and through snails once again (following techniques outlined in Platt and Samuel, 1978; Pybus and Samuel, 1981). Larvae from the latter snails were used to expose the fallow deer. Six unexposed fallow deer fawns, for use in another experiment, served as controls on clinical signs.

All fawns were observed daily for behavioral changes. Fecal samples collected weekly for up to 60 days following exposure and daily thereafter were examined for nematode larvae using a modified Baermann technique (Welch et al., 1991). Fallow deer that exhibited severe neurologic signs were killed with an intracardiac injection of sodium pentobarbital (Euthanyl®, M.T.C. Pharmaceuticals, Mississauga, Ontario, Canada L4W 2S5). Current guidelines provided by the Canadian Council on Animal Care (1984) were followed throughout the study.

The first two fawns were frozen and examined 2 to 3 wk later; all others were examined

fresh. At necropsy, body cavities were flushed and the fluids recovered were examined at 12× magnification for nematode larvae. The abomasum, greater omentum, and tissues in the dorsal peritoneal region were scanned for haemorrhages and larvae at 12× magnification. The abomasum and duodenum of three fallow deer were flushed and contents examined at 12× magnification. The brain and spinal cord of all fawns were examined grossly at 6× magnification and histologically for evidence of meningeal worm. Blood from the jugular vein was taken immediately before death of the fawns with neurologic signs. After death, cerebrospinal fluid was taken from the atlanto-occipital joint prior to disarticulation of the head.

To verify the identity and viability of larvae used to expose fallow deer, the white-tailed deer fawn was exposed to larvae from the same source. Clinical signs were not observed in the white-tailed deer, although postmortem cerebrospinal fluid had marked xanthochromia and leucocytosis (>10,000 WBC/μl) with 90% eosinophils. Dorsal-spined larvae were first detected in fecal samples collected 88 days post-exposure (dpe). The fawn was killed 90 dpe and 62 adult *P. tenuis* were recovered from the cranial cavity (89%) and spinal cord (11%). Other nematodes were not found.

RESULTS

Early mortality

Three fallow deer fawns died 6, 8, and 23 dpe, respectively, with similar clinical signs and postmortem lesions. Each fawn became depressed, anorexic, and stood with its head down and back arched for 2 to 5 days prior to death.

At necropsy, the fawns were in good body condition with adequate fat deposits.

TABLE 1. Meningeal worm (*Parelaphostrongylus tenuis*) in experimentally-infected fallow deer (FD).

Fawn number	Dose ^a	Death (dpe) ^b	Worm recovery (%)	Number of worms		Comments
				Brain	Cord	
FD 13	150	6	0	0	0	Peritonitis
FD 01	125	8	0	0	0	Peritonitis
FD 10	75	54	33	4	21	Paralysis
FD 03	55	23	0	0	0	Peritonitis
FD 05	35	57	69	8	16	Paralysis
FD 02	25	67	52	4	9	Paralysis

^a Number of third-stage larvae.

^b Number of days post-exposure when fawn died.

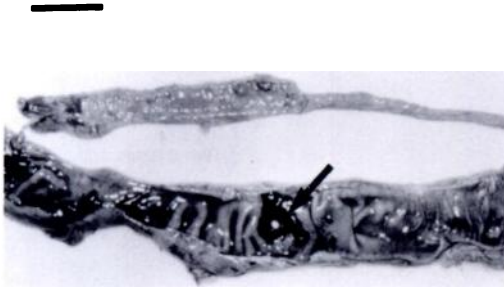


FIGURE 1. Inflammation of the distal duodenum in a fallow deer fawn given 55 larvae of *Parelaphostrongylus tenuis*. Note intense haemorrhage in the mucosa and complete perforation of the intestinal wall (!). Bar = 3 cm.

In each animal, the mucosa of the greater curvature of the abomasum was hyperaemic with a few scattered focal haemorrhages. The small intestine was filled with black-red fluid. The intestinal wall was slightly thickened; the mucosa was rugose and congested.

Extensive fibrinous adhesions were present throughout the peritoneal cavity. The omentum was firmly adhered to the greater curvature of the abomasum and to the serosa of the posterior duodenum, jejunum, colon, and caecum. Adhesions were more pronounced adjacent to the jejunum, spiral colon, and duodenum, respectively, in the fawns that died at 6, 8, and 23 dpe. One large (10 mm) and two small (2 to 3 mm) circular perforations were found in the wall of the posterior duodenum in the fawn that died 23 dpe (Fig. 1). No *P. tenuis* larvae were recovered from these deer.

The fawn that died 6 dpe had a discrete indurated, pale granular area (30 × 40 mm) in the hepatic parenchyma. Approximately 200 ml of serosanguinous fluid were present in the right thoracic cavity and a 2 to 4 mm thick fibrinous layer covered the entire right lung. This layer easily peeled back to reveal a congested, oedematous diaphragmatic lobe of the lung. Based on the postmortem findings, *Fusobacterium necrophorus* was suspected but could not be verified.

Late mortality

Three fallow deer killed 54, 57, or 67 dpe, respectively, also exhibited similar clinical signs and postmortem lesions. In one fawn, depression, mild paresis in the right hind leg, and lumbar weakness persisted for 14 days before advancing to complete posterior paralysis 54 dpe. In the two remaining fawns, ataxia, paresis, and posterior weakness rapidly (within 48 hr) progressed to complete posterior paralysis and disorientation. Infections in these fawns were considered terminal and consequently the fawns were killed. Clinical signs were not noted in any of the six control fawns.

Gross lesions in the spinal cord of all three fawns were characterized by extensive damage to grey matter and inflammation of nerve roots in the lumbar region. Spinal grey matter was congested, with tracks of haemorrhage and malacia adjacent to adult *P. tenuis*. A few haemorrhagic tracks also were seen in spinal and cerebral white matter adjacent to adult meningeal worms.

Moderate to severe inflammation was present throughout the lumbar region. Many nerve roots were soft, swollen, engorged with blood, and surrounded by a thick inflammatory accumulation. Small pink, fleshy nodules (accumulations of lymphocytes) were present in epidural areas adjacent to some roots. Similar accumulations were seen in the thoracic region of the spine of two fawns. Inflammatory reactions were most pronounced in the fawn killed 67 dpe.

Histologic lesions were characterized by widespread multifocal meningitis and myelitis in the CNS. Lesions often were associated with the presence of adult nematodes within neural tissue; however, they did not focus directly around the worms. Generalized infiltration of the meninges and perivascular cuffing within neural tissues involved primarily lymphocytes with some eosinophils. Haemorrhage and malacic tracks were present in the lumbar spinal cord, cerebral cortex, and pons. The right sciatic nerve of the fawn killed 54

dpe had severe local haemorrhage, inflammation, and degeneration of nerve sheaths and axons in the proximal third.

Sixty-two non-gravid adult *P. tenuis* were collected from the brain (26%) and spinal cord (74%) of the three deer with paralysis (Table 1). The sex ratio of adults was approximately one:one. Representative specimens were deposited in the National Museum of Natural Sciences (Division of Invertebrate Zoology, Ottawa, Ontario, Canada K1A 0M8; accession numbers CMNP1991-0022).

Within the cranial cavity, meningeal worms were located on or in the cerebrum (50%), medulla (31%), and cerebellum (19%). These nematodes were distributed equally in neural tissue (50%) and subdural spaces (50%). Nematodes were not found in cranial venous sinuses or olfactory lobes. Within the vertebral canal, *P. tenuis* were distributed along the full length of the spinal cord; however, they were more commonly found in cervical (43%) and lumbar regions (41%). Although most nematodes along the spinal cord were in the subdural space, 14 of 46 (30%) were in neural tissue, primarily within grey matter of the lumbar region. These latter nematodes lay in an extended coil affecting a considerable amount of tissue. Meningeal worms were not found in the epidural region of the cord.

Mild xanthochromia and leucocytosis (1,292 to 15,975 WBC/ μ l) were present in cerebrospinal fluids from the fawns with paralysis. WBC populations consisted of eosinophils (70 to 86%) and lymphocytes (14 to 25%). Peripheral blood values were normal.

DISCUSSION

Meningeal worm caused fatal infections in young fallow deer at all doses used in this study; three of six deer died as a direct result of infection, the remaining three deer were incapacitated beyond recovery and were killed. At the higher doses, infections rapidly produced fatal peritonitis and co-

litis identical to those in young domestic goats given 200 to 1,000 larvae of *P. tenuis* (Anderson and Strelive, 1969). In both species, the clinical course was short and the animals died quickly. Peritonitis has not been observed in young animals of other species given similar doses of *P. tenuis* (Anderson, 1963, 1964; Anderson et al., 1966; Anderson and Strelive, 1968; Tyler et al., 1980). The severe damage to the gastrointestinal tract of fallow deer fawns receiving high doses of infective larvae is most likely associated with the large number of larvae which penetrated the gut wall. Young fallow deer and domestic goats apparently are unable to limit this phase of the migration of meningeal worm.

At the lower doses, a high proportion of larvae reached the CNS in fallow deer. The clinical, gross, and histologic changes were similar to those seen in moose (*Alces alces*), mule deer (*Odocoileus hemionus*), wapiti (*Cervus elaphus canadensis*), caribou (*Rangifer tarandus caribou*), and domestic goats experimentally-infected with *P. tenuis* (Anderson, 1964; Anderson et al., 1966; Anderson and Strelive, 1968, 1972; Tyler et al., 1980). In all cases, meningeal worms developing within the CNS caused extensive damage to neural tissues, particularly in the lumbar and posterior cervical regions. Mule deer and domestic goats developed neurologic disease when exposed to 50 to 75 infective larvae and, like fallow deer in the present study, may be particularly susceptible to *P. tenuis* developing in the CNS. Field evidence suggests that caribou also develop neurologic disease at low doses of meningeal worm (Anderson, 1971).

The pathogenesis of infection in fallow deer was consistent with the proposed migration and development of *P. tenuis* in white-tailed deer. In white-tailed deer, larvae penetrate the abomasal wall (Anderson and Strelive, 1967) and reach the spinal cord in approximately 10 days (Anderson, 1965). In the current study, there is ample evidence that infective larvae penetrated

the gastrointestinal tract; however, few appeared to penetrate the abomasal wall. Large numbers of larvae appeared to be swept more posteriorly and were associated with a strong reaction in the lower gut. This may increase the chances of fatal peritonitis in this abnormal host. A similar situation may occur in domestic goats (Anderson and Strelive, 1969).

The onset of clinical neurologic signs in fallow deer fawns that survived initial migration of larvae indicates development of adult *P. tenuis* within the spinal neural tissue. In white-tailed deer, adult meningeal worms develop in the nerve cord and, by 40 dpe, move into spinal subdural spaces prior to migration towards the brain (Anderson, 1963, 1965). In fallow deer, many adult meningeal worms stayed within the spinal grey matter well after 40 days or migrated anteriorly and entered cerebral white matter. Subsequent damage to the CNS resulted in terminal paralysis. The same general pattern of migration and development has been seen in a variety of hosts other than white-tailed deer (Anderson and Prestwood, 1981).

Current experimental results suggest that fallow deer do not survive infection with *P. tenuis*. But, field evidence from Kentucky indicates that some fallow deer do (Davidson et al., 1985). These results appear to be contradictory; however, on closer inspection, this is not the case.

A high proportion (if not all) of fallow deer in Kentucky are sympatric with infected white-tailed deer and apparently are exposed to meningeal worm. Results of examining naturally-infected fallow deer from this population are as follows: seven deer that died with fatal neurologic disease had adult *P. tenuis* in the CNS (Nettles et al., 1977b); five deer randomly-selected from the population exhibited no clinical signs and had no nematodes in the CNS but each had lesions indicative of previous meningeal worm infections (Davidson et al., 1985). The latter authors suggested that survival of fallow deer with *P.*

tenuis may directly reflect natural exposure in Kentucky to very few larvae. Our results suggest that the maximum number tolerated is less than 25 larvae but the actual number is unknown and probably differs in different situations and in different individuals. Survival probably depends on several factors including the number of infective larvae ingested at one time, the time interval between exposures, and, perhaps, the age of deer when exposure occurs.

There is evidence of substantial immune response against *P. tenuis* in the CNS of fallow deer (Nettles et al., 1977b; Davidson et al., 1985; present study). However, the mechanisms of this resistance are not known. The presence of a response in deer exposed to a single dose of larvae (present study) suggests an innate immunity in fallow deer. The extent of protection appears to differ with different doses. At 25 to 75 larvae, the immune response was activated but was unsuccessful at preventing the development of meningeal worms in the CNS. Similar fatal infections have been observed in naturally-infected fallow deer (Kistner et al., 1977; Nettles et al., 1977b; Woolf et al., 1977). At lower doses, as may be expected in some field situations (Lankester and Anderson, 1968; Anderson and Prestwood, 1981; Davidson et al., 1985), protection appears to be more successful (Davidson et al., 1985). In field situations there also may be a component of acquired immunity resulting from prior exposure. Such a response is likely to be triggered by exposure to a few larvae which primes a secondary immune response, perhaps similar to the protective immunity observed in white-tailed deer exposed to repeated low-levels of *Parelaphostrongylus andersoni* (Prestwood and Nettles, 1977).

Fallow deer also appear at least partially resistant to *Elaphostrongylus cervi*, a parasite closely-related to meningeal worm (Lankester et al., 1990). In this case, however, few larvae appeared to reach the CNS. Other larvae may have been killed

or not activated in the gut (Rogers, 1963, 1966) and thus failed to make the subsequent migration to the CNS. Such a situation would imply an innate resistance to the parasite.

In a situation of natural transmission, the opportunity exists for an individual deer to encounter a range of doses, either in single or multiple exposures. Thus, wildlife managers can expect a range of responses, including some losses, whenever fallow deer use range contaminated with *P. tenuis*. Mortality of some fallow deer held on game farms in areas where meningeal worm is enzootic also can be expected. Presently, it is not possible to determine how severe such losses would be; however, they probably would increase in areas with high levels of *P. tenuis* in local white-tailed deer populations.

Survival and development of adult worms in fallow deer (Kistner et al., 1977; Nettles et al., 1977b; present study) suggest that if a deer survives the migration phases of the infection, *P. tenuis* could mature and produce larvae in this host. The small number of non-clinical but apparently naturally-infected deer ($n = 5$, Davidson et al., 1985) and low-dose experimentally-infected deer ($n = 3$, present study) examined may not reflect the full range of response in this host. In addition, feces of few fallow deer that survive meningeal worm infection have been examined for the presence of *P. tenuis* larvae. Until there is conclusive evidence that there is no possibility of translocating the parasite with infected fallow deer, we cannot recommend that fallow deer be translocated from areas enzootic for *P. tenuis*.

ACKNOWLEDGMENTS

We thank T. Ewaschuk and T. Terry for their technical assistance in rearing the fawns at Eilerslie. Similarly C. Wilke is acknowledged for his laboratory skills, particularly his expertise with the Baermann technique. Northern Lights Big Game Corporation provided financial support (subcontract to W. M. Samuel) and fallow deer fawns for the study. M. Lankester provided helpful suggestions throughout the study. Lo-

gistical support was provided by Alberta Agriculture, Edmonton, Alberta.

LITERATURE CITED

- ANDERSON, R. C. 1963. The incidence, development, and experimental transmission of *Pneumostrongylus tenuis* Dougherty (Metastrongyloidea: Protostrongylidae) of the meninges of white-tailed deer (*Odocoileus virginianus borealis*) in Ontario. *Canadian Journal of Zoology* 41: 775-792.
- . 1964. Neurologic disease in moose infected experimentally with *Pneumostrongylus tenuis* from white-tailed deer. *Veterinary Pathology* 1: 289-322.
- . 1965. The development of *Pneumostrongylus tenuis* in the central nervous system of white-tailed deer. *Pathologia Veterinaria* 2: 360-379.
- . 1971. Neurologic disease in reindeer (*Rangifer tarandus tarandus*) introduced into Ontario. *Canadian Journal of Zoology* 49: 159-166.
- , M. W. LANKESTER, AND U. R. STRELIVE. 1966. Further experimental studies of *Pneumostrongylus tenuis* in cervids. *Canadian Journal of Zoology* 44: 851-861.
- , AND A. K. PRESTWOOD. 1981. Lungworms. In *Diseases and parasites of white-tailed deer*, W. R. Davidson, F. A. Hayes, V. F. Nettles, and F. E. Kellogg (eds.). Miscellaneous Research Publication No. 7, Tall Timbers Research Station, Tallahassee, Florida, pp. 266-317.
- , AND U. R. STRELIVE. 1967. The penetration of *Pneumostrongylus tenuis* into the tissues of white-tailed deer. *Canadian Journal of Zoology* 45: 285-289.
- , AND ———. 1968. The experimental transmission of *Pneumostrongylus tenuis* to caribou (*Rangifer tarandus terraenovae*). *Canadian Journal of Zoology* 46: 503-510.
- , AND ———. 1969. The effect of *Pneumostrongylus tenuis* (Nematoda: Metastrongyloidea) on kids. *Canadian Journal of Comparative Medicine* 33: 280-286.
- , AND ———. 1972. Experimental cerebrospinal nematodiasis in kids. *The Journal of Parasitology* 58: 816.
- BERGERUD, A. T., AND W. E. MERCER. 1989. Caribou introductions in eastern North America. *Wildlife Society Bulletin* 17: 111-120.
- CANADIAN COUNCIL ON ANIMAL CARE. 1984. Guide to the care and use of experimental animals, Vol. 2. Canadian Council on Animal Care, Ottawa, Ontario, Canada, 208 pp.
- DAVIDSON, W. R., J. M. CRUM, J. L. BLUE, D. W. SHARP, AND J. H. PHILLIPS. 1985. Parasites, diseases, and health status of sympatric populations of fallow deer and white-tailed deer in Kentucky. *Journal of Wildlife Diseases* 21: 153-159.

- KISTNER, T. P., G. R. JOHNSON, AND G. A. RILLING. 1977. Naturally occurring neurologic disease in a fallow deer infected with meningeal worms. *Journal of Wildlife Diseases* 13: 55–58.
- LANKESTER, M. W., AND R. C. ANDERSON. 1968. Gastropods as intermediate hosts of *Parelaphostrongylus tenuis* Dougherty of white-tailed deer. *Canadian Journal of Zoology* 46: 373–383.
- , J. E. SMITS, M. J. PYBUS, D. FONG, AND J. C. HAIGH. 1990. Experimental infection of fallow deer (*Dama dama*) with elaphostrongylid nematodes (Nematoda: Protostrongylidae) from caribou (*Rangifer tarandus caribou*) in Newfoundland. *Alces* 26: 154–162.
- NETTLES, V. F., A. K. PRESTWOOD, R. G. NICHOLS, AND C. J. WHITEHEAD. 1977a. Meningeal worm-induced neurologic disease in black-tailed deer. *Journal of Wildlife Diseases* 13: 137–143.
- , ———, AND R. D. SMITH. 1977b. Cerebrospinal parelaphostrongylosis in fallow deer. *Journal of Wildlife Diseases* 13: 440–444.
- PLATT, T. R., AND W. M. SAMUEL. 1978. *Parelaphostrongylus odocoilei*: Life cycle in experimentally infected cervids including the mule deer, *Odocoileus h. hemionus*. *Experimental Parasitology* 46: 330–338.
- PRESTWOOD, A. K., AND V. F. NETTLES. 1977. Repeated low-level infection of white-tailed deer with *Parelaphostrongylus andersoni*. *The Journal of Parasitology* 63: 974–978.
- PYBUS, M. J. 1983. *Parelaphostrongylus andersoni* Prestwood 1972 and *P. odocoilei* (Hobmaier and Hobmaier 1934) (Nematoda: Metastrongyloidea) in two cervid definitive hosts. Ph.D. Thesis. University of Alberta, Edmonton, Alberta, Canada, 185 pp.
- , AND W. M. SAMUEL. 1981. Nematode muscleworm from white-tailed deer of southeastern British Columbia. *The Journal of Wildlife Management* 45: 537–542.
- , ———, D. A. WELCH, AND C. J. WILKE. 1990. *Parelaphostrongylus andersoni* (Nematoda: Protostrongylidae) in white-tailed deer from Michigan. *Journal of Wildlife Diseases* 26: 535–537.
- ROGERS, W. P. 1963. Physiology of infection with nematodes: Some effects of the host stimulus on infective stages. *Annals of the New York Academy of Sciences* 113: 208–216.
- . 1966. Exsheathment and hatching mechanisms in helminths. *In* *Biology of parasites*. Academic Press, New York, New York, pp. 33–40.
- SEVERINGHAUS, C. W., AND R. W. DARROW. 1976. Failure of elk to survive in the Adirondacks. *New York Fish and Game Journal* 23: 98–99.
- , AND L. W. JACKSON. 1970. Feasibility of stocking moose in the Adirondacks. *New York Fish and Game Journal* 17: 18–32.
- TRAINER, D. O. 1973. Caribou mortality due to the meningeal worm (*Parelaphostrongylus tenuis*). *Journal of Wildlife Diseases* 9: 376–378.
- TYLER, G. V., C. P. HIBLER, AND A. K. PRESTWOOD. 1980. Experimental infection of mule deer with *Parelaphostrongylus tenuis*. *Journal of Wildlife Diseases* 16: 533–540.
- WELCH, D. A., M. J. PYBUS, W. M. SAMUEL, AND C. J. WILKE. 1991. Reliability of fecal examination for detecting infections of meningeal worm (*Parelaphostrongylus tenuis*) in elk. *Wildlife Society Bulletin* 19: 326–331.
- WOOLF, A., C. A. MASON, AND D. KRADEL. 1977. Prevalence and effects of *Parelaphostrongylus tenuis* in a captive wapiti population. *Journal of Wildlife Diseases* 13: 149–154.

Received for publication 13 March 1991.