



## OPHTHALMOLOGIC EXAMINATION OF THE NORMAL EYE OF THE KOALA

Authors: Hirst, Lawrence W., Brown, Anthony Stephen, Kempster, Roxanne, and Winney, Nedda

Source: Journal of Wildlife Diseases, 28(3) : 419-423

Published By: Wildlife Disease Association

URL: <https://doi.org/10.7589/0090-3558-28.3.419>

---

BioOne Complete ([complete.BioOne.org](https://complete.BioOne.org)) is a full-text database of 200 subscribed and open-access titles in the biological, ecological, and environmental sciences published by nonprofit societies, associations, museums, institutions, and presses.

Your use of this PDF, the BioOne Complete website, and all posted and associated content indicates your acceptance of BioOne's Terms of Use, available at [www.bioone.org/terms-of-use](https://www.bioone.org/terms-of-use).

Usage of BioOne Complete content is strictly limited to personal, educational, and non - commercial use. Commercial inquiries or rights and permissions requests should be directed to the individual publisher as copyright holder.

---

BioOne sees sustainable scholarly publishing as an inherently collaborative enterprise connecting authors, nonprofit publishers, academic institutions, research libraries, and research funders in the common goal of maximizing access to critical research.

## OPHTHALMOLOGIC EXAMINATION OF THE NORMAL EYE OF THE KOALA

Lawrence W. Hirst,<sup>1</sup> Anthony Stephen Brown,<sup>2</sup> Roxanne Kempster,<sup>1</sup> and Nedda Winney<sup>3</sup>

<sup>1</sup> Division of Ophthalmology, 2nd Floor, Lions Research Building, Princess Alexandra Hospital, Ipswich Road, Woolloongabba, Brisbane, Queensland 4102, Australia

<sup>2</sup> C/- Department of Lands and Environment, Division of Environment and Conservation, Private Mail Bag, Apia, Western Samoa

<sup>3</sup> C/- Bold Acres, O'Leary Avenue, Burpengary, Queensland 4505, Australia

**ABSTRACT:** The ophthalmic examination of the koala (*Phascolarctos cinereus*) was undertaken to describe the normal in vivo structure. Twenty-two of 28 koalas examined were found to have normal eyes. Slit-lamp examination revealed unusual lamellae in the cornea, and mean keratometric readings were  $59.3 \pm 3$  diopters, corneal endothelial cell area of  $381.4 \mu\text{m}^2 \pm$  with a standard deviation of  $46.8 \mu\text{m}^2$ . No particular features were seen which would explain the susceptibility of this animal to ocular infection by *Chlamydia psittaci*.

**Key words:** *Phascolarctos cinereus*, slit-lamp examination, specular microscopy, intraocular pressure, keratometry, ophthalmic examination.

### INTRODUCTION

The koala (*Phascolarctos cinereus*) is a native Australian marsupial which is considered to be under considerable threat primarily from incursion on its natural habitat by urban and rural development, but also by trauma from dogs and vehicles, and infectious diseases.

Since the turn of this century, there have been isolated reports of severe eye infections (Pratt, 1937; Serventy and Serventy, 1975; Troughton, 1973; Stead, 1934), and for the last 15 yr, many of these have been diagnosed as chlamydial in origin (Cockram and Jackson, 1974; Brown and Grice, 1986). As chlamydial eye infection may be a significant component of overall chlamydial disease in the koala, and as blindness may ensue as a result of this infection, an understanding of the in vivo features of the koala eye is a prerequisite to investigating the chlamydial infection of the eye in this species. As there is no literature on the detailed microscopic features, the study was designed to investigate the in vivo characteristics of the koala eye using standard ophthalmological techniques and equipment.

### MATERIALS AND METHODS

Koalas which had been in captivity for varying periods of time, and which had not shown any signs of obvious ocular disease or infection (apart from history of trauma to one eye only) were used in this study (World Koala Research Corporation, Bunya Park Drive, Everton Hills, Queensland; Oasis Tourist Gardens, 141 Station Road, Sunnybank, Queensland; and the Australian Wool-Shed, 148 Samford Road, Ferny Hills, Queensland). Koalas were transported in hessian bags and anaesthetized with intravenous alfaxalone and alphadolone acetate (Saffan, Pitman Moore Australia Limited, 71 Eping Road, North Ryde, New South Wales 2113, Australia) with a loading dose of 0.1 ml/kg of body weight and incremental doses of 0.2 ml as required, as judged by the level of anaesthesia. This study was approved by The University of Queensland Animal Ethics Experimental Committee (The University of Queensland, St. Lucia, Brisbane 4072, Australia) and conformed to the NH & MRC/CSIRO/AAC Guide-lines for Animal Experimentation (Australian Code of Practice for the Care and Use of Animals for Scientific Purposes, National Health and Medical Research Council, Commonwealth Scientific and Industrial Research Organisation, Australian Agricultural Council, Published Canberra, Australia AGPS, 1990).

Each animal was identified with an ear tag, aged according to teeth-wear or, if known, approximate date of birth, sexed according to ex-

ternal genitalia, blood taken for chlamydial serology, and nasal, urogenital and ocular cultures were taken for isolation of *Chlamydia psittaci*.

Each animal was supported by a mobile animal stand for all of the studies requiring a horizontal orientation, or was otherwise held by staff. Using a Javal Schiötz keratometer (Haag-streit AG, Hess-strasse 27, CH-3097, Liebeseld-Sthweisch, Bern, Switzerland), the central corneal curvature was measured on each eye. If the curvature exceeded 60 diopters, then an additional +1.00, +2.00 or +2.5 lens was added to the front of the keratometer and new measurements taken. The keratometer was then calibrated against standard ball-bearings (Consolidated Bearing Co (Qld) Pty Ltd, 51 Sandgate Road, Albion, Queensland, Australia) to develop a graph of values above 60 diopters. A calibrated pneumotonometer (Bio-Rad Ophthalmic Division, 237 Putnam Avenue, Cambridge, Massachusetts 02139, USA) was used to measure intraocular pressure in both eyes.

External photographs, using a macro lens (Nikon Corporation, Fuji Building, 2-3 Marunouchi 3 chome, Chiyoda-ku, Tokyo 100, Japan) and bellows, giving a final one to one magnification, were taken of both eyes, and each animal was then examined with a Zeiss photo slit-lamp (Carl Zeiss Oberkochen, Postfach 1369, 7082 Oberkochen, Germany) for anterior segment details of conjunctiva, cornea, anterior chamber, iris, and crystalline lens. Representative photographs of the anterior segment structures were taken. Specular microscopy of the corneal endothelium was undertaken using a Keeler Konan wide-field specular microscope (Konan Camera Research Institute Inc, Head Office, 10-29 Miyanashi-cho, Nishinomiya, Hyogo, Japan 662). About 18 photographs of the central 4 mm of corneal endothelium were taken on each cornea, and, at the same time, central specular microscopic pachometry was performed, first focusing on the end of the specular microscopic cone, and then focusing on the endothelial layer. The resultant negatives were printed to 200 mm × 250 mm prints and digitized on a Microplan digitizing tablet (GTCO Corporation, 1055 First Street, Rockville, Maryland 20850, USA) and computer (Don Santo Corporation, 197 Oak Street, Natick, Massachusetts 01760, USA). Gonioscopy, using a Koepe infant lens (Ocular Instruments, Bellvue, Washington, USA), was performed on some animals. A Technar B-scan (Tekner Inc of St Louis, 267 Wolfner Drive, Fenton, Missouri 63026, USA) ultrasound examination was performed on each eye through closed lids in order to measure axial length. Using two, and sometimes three, drops of tropicamide 1% (Alcon Laboratories, Frenchs Forest, New South Wales 2086, Australia) the pupils

were dilated and indirect funduscopy performed. Some representative fundal photographs were taken using a Zeiss fundus camera (Carl Zeiss Oberkochen, Postfach 1369, 7082 Oberkochen, Germany). The entire examination usually took 30 to 45 min. None of the procedures resulted in ocular problems.

## RESULTS

Twenty-eight animals (totalling 53 eyes) were examined over a 12 mo period. Age range was 12 mo to >10 yr, and sex distribution was 68% female and 32% male. Unexpected slit-lamp pathology was noted in six of the animals despite external clinical examination suggesting that these were normal eyes. These koalas were not included in the cumulative database as various pathologies found included corneal stromal vascularization and corneal crystals, epithelial corneal haziness, conjunctival scarring, abnormal pupils, iris atrophy, posterior synechiae to the lens surface and dystrophic changes to the retina.

Table 1 lists the keratometry (mean ± 1 SD: 59.3 ± 3 diopters), pneumotometry (24.2 ± 6 mm Hg), pachometry (0.38 ± 0.05 mm), and B-scan axial length findings (12.6 ± 1 mm).

External examination of the koala eye reveals a narrow interpalpebral fissure exposing the cornea only, often with no visible sclera between muscular hairy lids. A prominent and thin nictitating membrane normally lies across the inferonasal portion of the cornea usually extending laterally 3 to 5 mm. The lids show little definition between the skin and mucosal membrane, and, externally, have one to two rows of darkly pigmented lashes. A row of Meibomian gland orifices (12 to 20) lie posterior to this lash line in an area of heavy pigmentation with less pigmentation around the orifices themselves. There is a vertically oval, tight pupil and a heavily pigmented brown iris with multiple crypts and occasional prominent radial vessels.

Slit-lamp examination revealed a well-vascularized conjunctiva with minimal surface morphology and a prominent smooth nictitating membrane. The forni-

TABLE 1. Ocular examination findings in 22 koalas (*Phascolarctos cinereus*) of south east Queensland, Australia.

Koala number	Sex	Age (yr)	Eye	Keratometry (diopters)	Average*	Astigmatism (diopters)	Intra-ocular pressure (mm Hg)	Pachometry (mm)	Axial length (mm)
26/87	F	Adult	L	55/57.5 × 135	(56.25)	2.5	27	0.41	11.0
30/87	F	2-3	R	62/61.5 × 115	(61.75)	0.5	12	0.33	11.0
			L	64/62.5 × 180	(63.25)	0.5	7	0.33	11.0
125/88	F	Adult	R	54/55 × 30	(54.5)	1.0	16	—	13.5
			L	55/56 × 140	(55.5)	1.0	16	—	13.0
148/88	M	3	R	57	(57.0)	0.0	25	0.35	11.0
			L	58/56 × 180	(57.0)	2.0	27	0.34	11.0
152/88	M	11-12	R	52/56 × 105	(54.0)	4.0	23	0.30	15.0
			L	53/56 × 90	(54.5)	3.0	23	0.30	13.5
153/88	M	5	R	57/58 × 65	(56.5)	1.0	25	0.42	11.0
			L	59/55 × 70	(57.0)	4.0	25	0.41	13.0
154/88	M	4	R	59/60 × 90	(59.5)	1.0	25	0.32	12.5
			L	55/57 × 90	(56.0)	2.0	27	0.31	12.5
155/88	F	1	R	64.5	(64.5)	0.0	27	0.30	11.0
			L	64.5	(64.5)	0.0	24	0.30	10.5
156/88	F	1	R	59.5/60 × 90	(59.75)	0.5	24	0.30	11.0
			L	60	(60.0)	0.0	26	0.30	11.0
159/88	F	9	R	62/59 × 90	(60.5)	3.0	23	—	12.0
			L	59/57 × 95	(58.0)	2.0	24	—	12.0
178/88	M	4	R	62	(62.0)	0.0	25	0.39	12.0
			L	62	(62.0)	0.0	25	0.39	14.0
179/88	F	1.6	R	57/59 × 60	(58.0)	2.0	23	0.40	12.0
			L	58/55 × 9	(56.5)	3.0	25	0.40	13.0
190/88	F	1.5	R	58/59 × 180	(58.5)	1.0	25	0.42	13.0
			L	58/60 × 180	(59.0)	2.0	25	0.40	13.0
191/88	F	1.5	R	62/60 × 90	(61.0)	2.0	25	0.42	12.0
			L	62/61 × 90	(61.5)	1.0	25	0.42	13.0
285/88	M	3	R	60	(60.0)	—	—	0.45	13.0
289/88	M	3	R	58.5/57 × 100	(57.75)	—	—	0.39	14.0
			L	59/58.5 × 70	(58.75)	0.5	30	0.39	14.0
290/88	M	4	R	54/53 × 90	(53.5)	—	—	0.49	14.0
314/88	F	3	R	59	(59.0)	0.0	25	0.41	11.5
			L	58	(58.0)	0.0	25	0.43	12.0
335/88	F	2	R	61	(61.0)	—	—	0.42	14.0
			L	58	(58.0)	—	—	0.41	13.0
357/88	F	2.5	R	65	(65.0)	0.0	22	0.39	11.0
			L	66.5/67.5 × 100	(67.0)	1.0	20	0.37	10.0
365/88	F	1.25	R	62	(62.0)	—	—	0.41	13.0
			L	61/62 × 90	(61.5)	1.0	24	0.41	12.5
386/88	F	1.5	R	61	(61.0)	0.0	25	0.36	11.0
			L	61	(61.0)	0.0	25	0.37	11.0
Mean			—	—	59.32	—	24.2	0.38	12.63
SD			—	—	3.114	—	6.45	0.049	1.203

\* Dioptic power in one axis/dioptic power in axis at 90 degrees (average dioptic power).

ces were short and the tarsal plates were quite flaccid. The cornea was circular with no peripheral vascularization and no prominent limbal changes (Fig. 1). The corneal epithelium was smooth and the

stroma clear, apart from two to three planes of opacity centrally parallel to the corneal surface which became less marked in the periphery of the cornea (Fig. 2). The endothelial surface was unremarkable by slit

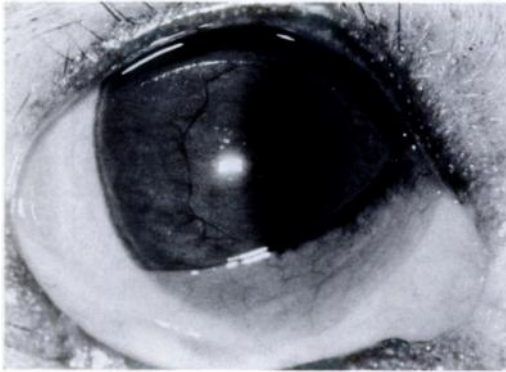


FIGURE 1. External photograph of a normal koala eye.

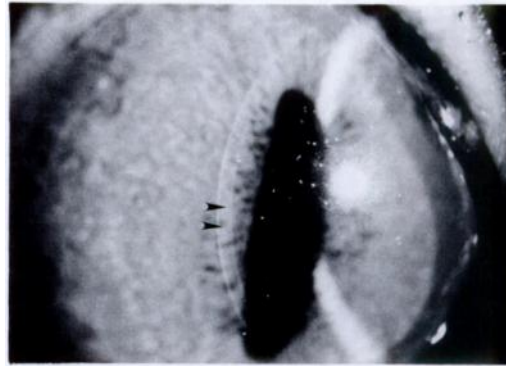


FIGURE 2. High magnification slit-lamp photograph of koala cornea showing two fine intrastromal opaque lamellae (arrows).

lamp examination. The anterior chamber was deep and the iris was heavily vascularized and pigmented. There was a vertically oriented pupil with variable amount of pigment ruff extending on to the anterior surface of the iris. On dilated examination, there was a very thick crystalline lens which was clear, and the vitreous cavity was unremarkable. Indirect ophthalmoscopy of the fundus revealed a highly refractile tapetal layer above, and a very pale optic disc with trifid vasculature. Specular microscopy of the endothelium showed a reasonably regular,

hexagonal array of cells with some pleomorphism in size and shape (Table 2) (average cell size  $381.6 \mu\text{m}^2$  with a standard deviation of  $46.8 \mu\text{m}^2$ ). The ultrasound examination demonstrated a somewhat shortened globe (average length 12.63 mm with a standard deviation of 1.20 mm) with a wide equator and no other remarkable features.

#### DISCUSSION

Little was known about the eye of the normal koala so that its response to a chlamydial infection remained an enigma

TABLE 2. Morphology of corneal endothelial cells by specular microscopy in sixteen koala corneas.

Koala no.	Sex	Age (yr)	Eye	Area ( $\mu\text{m}^2$ )	SD	Form factor	No. of cells	Hexagonality (%)
26/87	F	Adult	L	429.7	67.18	0.8819	216	83.3
153/88	M	5	R	457.0	91.44	0.8732	635	73.0
			L	468.5	106.20	0.8668	639	66.8
154/88	M	4	L	376.0	58.46	0.8727	140	76.4
156/88	F	1	R	405.4	90.96	0.8685	1,300	67.1
			L	396.5	97.84	0.8629	575	68.5
179/88	F	1.6	R	381.4	61.99	0.882	118	80.5
285/88	M	3	R	372.6	75.37	0.8751	906	69.9
289/88	M	3	R	411.1	76.25	0.8651	374	67.1
290/88	M	4	R	385.4	86.47	0.8722	446	64.8
335/88	F	2	R	319.4	51.74	0.8687	111	77.5
			L	304.6	57.59	0.8675	335	73.1
365/88	F	1.25	R	366.3	62.84	0.8693	373	75.3
			L	388.4	69.38	0.8726	527	73.6
386/89	F	1.5	R	310.1	63.49	0.869	429	71.6
			L	330.7	64.25	0.8714	507	62.7
Mean					381.4	0.8712		71.9
SD					46.8	0.0051		5.6

without the base-line data of the in vivo characteristics of the eye. This study was so designed as to provide such base-line data by regular, non-invasive ophthalmological examination of a koala population not infected by *Chlamydia psittaci*.

All 28 koalas were initially considered normal upon gross external examination, and yet six of these koalas showed minor pathological changes upon more subtle ophthalmological examination that suggested previous ocular disease. Although the clinical significance of these disease processes remains obscure, it does indicate that cursory external examination of the koala eye, without using slit-lamp examination and dilated examination, is likely to miss evidence of possible previous infection, trauma or other unknown disease.

The cornea/air interface in the koala eye is extremely curved compared to most animals, perhaps compensated for by a short anterior/posterior dimension. Also, there appears to be a modest amount of astigmatism with the increased curvature frequently being at, or close to, the horizontal meridian. The significance of this remains obscure. There is also a consistent finding in the koala cornea of planes of opacity: the structure and significance of this opacity also remains unknown at this time. Retinal examination shows an organization of disc, tapetal and non-tapetal retina similar to that found in other marsupials (Johnson, 1901).

We did not find any particular features that would explain a predisposition of these eyes to chlamydial infection. However, this type of detailed examination has already led to the description of a different corneal disease (Hirst et al., 1992) which might easily have been confused with chlamydial

keratitis if the baseline data on the eye of the normal koala had not been accumulated.

#### ACKNOWLEDGMENTS

We are grateful for the supply of koalas for examination from the World Koala Research Corporation, the Oasis Tourist Gardens and the Australian Wood-Shed. Supported in part by the Australian Foundation for the Prevention of Blindness (Queensland Division), the Centre for Wildlife Research Inc., and by the Australian Koala Foundation.

#### LITERATURE CITED

- BROWN, A. S., AND R. G. GRICE. 1986. Experimental transmission of *Chlamydia psittaci* in the koala. In Chlamydial infections, D. Oriol, G. Ridgway, J. Schachter, D. Taylor-Robinson, and M. Ward (eds.). Proceedings of the Sixth International Symposium of Human Chlamydial Infections, Cambridge University Press, Cambridge, England, pp. 349-352.
- COCKRAM, F. A., AND A. R. B. JACKSON. 1974. Isolation of a *Chlamydia* from cases of keratoconjunctivitis in koalas. Australian Veterinary Journal 50: 82-83.
- HIRST, L. W., A. S. BROWN, R. KEMPSTER, J. HALL, AND J. WOOLCOCK. 1992. Keratitis in free-ranging koalas (*Phascolarctos cinereus*) on Magnetic Island, Townsville. Journal of Wildlife Diseases 28: 424-427.
- JOHNSON, G. L. 1901. Contributions to the comparative anatomy of the mammalian eye chiefly based on ophthalmoscopic examination. Philosophical Transactions of the Royal Society of London (Series B) 194: 1-82.
- PRATT, A. 1937. The call of the koala. Robertson and Mullens, Melbourne, Australia, 120 pp.
- SERVENTY, V., AND C. SERVENTY. 1975. The koala. E. P. Dutton and Co, Inc., New York, New York, 80 pp.
- STEAD, D. G. 1934. The koala, or native bear. Australian Wildlife 1: 13-22.
- TROUGHTON, E. 1973. Furred animals of Australia, 9th ed. Angus and Robertson, Sydney, Australia, 384 pp.

Received for publication 18 September 1990.