

A Case of Cleft Palate in a Kuril Seal (*Phoca vitulina stejnegeri*), from Hokkaido, Japan

Authors: Suzuki, Masatsugu, Kishimoto, Mayumi, Hayama, Shin-ichi, Ohtaishi, Noriyuki, and Nakane, Fumio

Source: Journal of Wildlife Diseases, 28(3) : 490-493

Published By: Wildlife Disease Association

URL: <https://doi.org/10.7589/0090-3558-28.3.490>

BioOne Complete (complete.BioOne.org) is a full-text database of 200 subscribed and open-access titles in the biological, ecological, and environmental sciences published by nonprofit societies, associations, museums, institutions, and presses.

Your use of this PDF, the BioOne Complete website, and all posted and associated content indicates your acceptance of BioOne's Terms of Use, available at www.bioone.org/terms-of-use.

Usage of BioOne Complete content is strictly limited to personal, educational, and non-commercial use. Commercial inquiries or rights and permissions requests should be directed to the individual publisher as copyright holder.

BioOne sees sustainable scholarly publishing as an inherently collaborative enterprise connecting authors, nonprofit publishers, academic institutions, research libraries, and research funders in the common goal of maximizing access to critical research.

A Case of Cleft Palate in a Kuril Seal (*Phoca vitulina stejnegeri*), from Hokkaido, Japan

Masatsugu Suzuki,¹ Mayumi Kishimoto,² Shin-ichi Hayama,³ Noriyuki Ohtaishi,¹ and Fumio Nakane,¹ ¹Department of Oral Anatomy I, School of Dentistry, Hokkaido University, Kita 13 Nishi 7 Kita-ku, Sapporo, Hokkaido 060, Japan; ²Wildlife Management Office, 1-18-18 Teraodai, Tama-ku, Kawasaki, Kanagawa 214, Japan; ³Division of Wild Animal Medicine, Nippon Veterinary and Animal Science University, 1-7-1 Kyonan-cho, Musashino, Tokyo 180, Japan

ABSTRACT: A male pup Kuril seal (*Phoca vitulina stejnegeri*) from Hokkaido, Japan, was observed with a unilateral and total cleft of the primary palate. Complications included a supernumerary tooth, hypoplasia and asymmetry of the face, and deformation of the eyeball and external auditory meatus. An accompanying pneumonia may have resulted from water flowing into the respiratory system due to imperfect closure of the nostril by the cleft. No other abnormalities were found.

Key words: Kuril seal, *Phoca vitulina stejnegeri*, cleft palate, congenital malformation.

There have been few reports of congenital abnormalities in pinnipeds (Lauckner, 1985) due to their habitats and life histories. Among harbor seals (*Phoca vitulina*), there are reports of abnormalities of tooth number and position (Colyer, 1936; Suzuki et al., 1990) and of a hairless and toothless pup (King, 1964).

The Kuril seal (*Phoca vitulina stejnegeri*), a subspecies of harbor seals (Niizuma, 1986), occurs in eastern Hokkaido, the Kuril Islands, eastern Kamchatka and the Commander Islands (Shaughnessy and Fay, 1977; King, 1983; Niizuma, 1986). The population of the Kuril seals in Japan consists of only about 370 individuals, and their breeding range is extremely limited (Hayama, 1989). We report on a Kuril seal found in Hokkaido, Japan, with a cleft palate.

The Kuril seal was rescued at a fishing port in Shizunai (42°21'N, 142°22'E) on 15 May 1989. Since permanent teeth were beginning to erupt, this seal was judged to be a pup. After the rescue, the pup was immediately brought to the Aquarium at

Seaside Park Hiroo in the town of Hiroo, but died the next day. A necropsy was performed at the Division of Wild Animal Medicine at the Nippon Veterinary and Animal Science University, Tokyo, Japan, on 18 May. The skull was cleaned and examined in the Department of Oral Anatomy I, School of Dentistry, Hokkaido University.

The seal was a male pup with a straight length from the tip of the snout to the end of the tail of 930 mm. Girth at just behind the fore flippers was 501 mm. The total weight was 8.86 kg.

The typical length of the Kuril seal at birth is estimated to be 982 mm (Naito and Nishiwaki, 1972). A small amount of white lanugo hair, which had been shed in the latter part of the gestation period and possibly had been inhaled with the amniotic fluid at birth, was found in the nasal cavity. Thus, we believed that the pup had become separated from the mother and drifted ashore soon after birth.

The cleft running through on the right lip was so wide that the right nostril and mouth were connected (Fig. 1). The left nostril also was out of its natural position. The cleft of the palate was between the third incisor and the canine on the right side, limited in the region of alveolar process. A supernumerary tooth stood on the right side of the cleft on the dental arch.

The right half of the face had hypoplasia and the upper jaw was clearly bending to the left (Fig. 1). Also the lower jaw was twisted to the left. Because tissue was raised on the right palpebral fissure, the eyeball could not be seen externally. The right

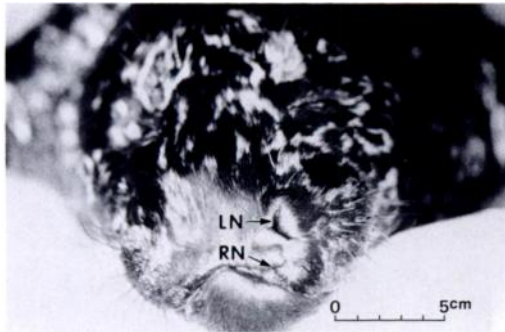


FIGURE 1. The face of the Kuril seal pup showing the unified right nostril and mouth, and twisted jaw. RN:right nostril, LN:left nostril.

opening of the external auditory meatus was smaller than the left.

Aside from the cleft, abnormalities were not detected in the oral and pharyngeal regions. The right eyeball was deformed into a hard and small globular mass about

one-sixth of the diameter of the normal left one. Although making an accurate diagnosis was difficult because of postmortem degeneration, abnormal findings in the internal organs were confined to the lungs. The pup had hepatization of many pulmonary lobules based on the macroscopic observation, and may have had pneumonia. There was no milk or food in the stomach.

The skull had deformations in addition to a cleft of the palate (Fig. 2A). Divergence of the palate was observed only between the right incisive bone and maxilla (Fig. 2B), as expected from external observation. Both of the incisive bones and the left maxilla were bent to the left. The divarication was wide, and the right palatine fissure unified with the cleft. All six incisors were displaced with the incisive bones. The supernumerary tooth stood in

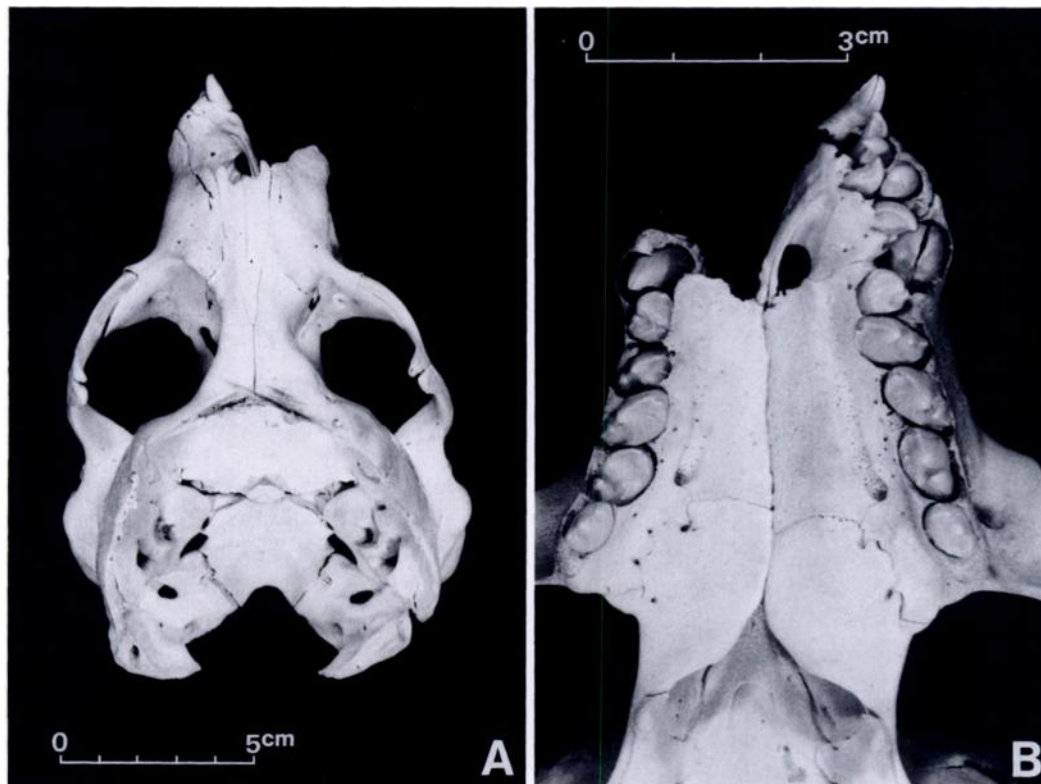


FIGURE 2. The whole skull (A) and the palate (B) of the Kuril seal pup. The calvaria was opened to remove the brain. Divergence of the palate was observed between the right incisive bone and maxilla. The incisive bones and the left maxilla were bent to the left. Incisors were displaced with the incisive bones.

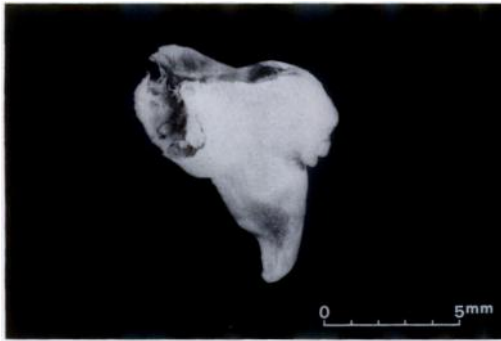


FIGURE 3. The supernumerary tooth of the Kuril seal pup; it stood on the side of the cleft of the palate. The crown (lower half) resembled that of an incisor, but the upper half of the root was deformed.

this divarication separate from the bones of the skull along with some small pieces of bone. The crown of this tooth resembled that of an incisor, but the root was deformed (Fig. 3).

Hypoplasia was evident in the bones on the right side of the skull, especially affecting the maxilla, zygomatic bone, and zygomatic process of the temporal bone. Consequently, the right orbit and nasal cavity were smaller than the left orbit and nasal cavity, respectively. Crowding of the right postcanine teeth was more evident than on the left. There were no other clear malformations of the skull.

There have been numerous reports of cleft lip or palate in humans because of their clinical importance, and several classifications of that symptom are presented. Although there is still no universally accepted classification, the Karnahan and Stark (1958) (K&S) classification and the American Cleft Palate Association (ACPA) classification probably represent the best available systems today for humans (Berlin, 1971). Both classifications are based on human embryology. However, the ACPA classification is very detailed and relies too heavily on human anatomy to apply to other mammals. So we used the K&S classification in this examination.

According to Karnahan and Stark (1958), the term "primary palate" is used to encompass the lip, alveolar process and an-

terior palate up to the incisive foramen, since it originates from the maxillary prominence and the medial nasal prominence. The cleft of the Kuril seal occurred only in the primary palate region, and ran through from the mouth to the right nostril. Therefore, this case is classified as a unilateral and total cleft of the primary palate, according to the K&S classification.

Moor (1983) used the term "cleft lip" as a synonym for a cleft of the primary palate in the K&S classification and ascribed a cleft lip to the failure of the maxillary prominence on the affected side to merge with the medial nasal prominences. The pathogenesis of the cleft in this seal may be similar to Moor's description since the pattern of organogenesis does not vary much in mammals (Kato, 1969). A detailed study of the embryology of the Kuril seal would be needed to determine when the cleft occurred because it is not known when the maxillary prominence and medial nasal prominence fuse.

Complications of the cleft palate found in this Kuril seal, such as the supernumerary tooth, hypoplasia of the face, bending of the jaws and deformation of the eyeball and ear, also have been reported in humans. A supernumerary tooth is found in 10% of human cleft palate patients (Ohshima, 1964). Some cases of asymmetry of the face or nasal cavity with cleft palate were described by Pruzansky (1955) and Latham (1969). Deformations of the eye and ear have been reported by Warburg (1960) and Hartung and Schweckendiek (1973) as complications of cleft palates. Thus, similar complications in a seal may be a reasonable expectation. The relationships between the cleft palate and other complications in this case are not clear.

Small (1967) pointed out that the clinical indication of cleft palate is reflux of milk or other fluids from the nostrils in nonhuman mammals. The pup may have had these symptoms, but it probably had an even more serious handicap as a pinniped. Pinnipeds close their nostrils while under water to prevent water from flowing

into their respiratory system (King, 1983). Since this pup's right nostril was abnormal and connected to the mouth, the nostril could not close effectively. The lung lesion might have been caused by the flow of water into the lung through the imperfect nostril.

ACKNOWLEDGMENTS

We are deeply grateful to the staff of the Aquarium at Seaside Park Hiroo for providing us with this precious specimen. And we also thank Mr. N. Hachiya and Miss J. Terazaki (Department of Oral Anatomy I, School of Dentistry, Hokkaido University) for assisting us throughout this study.

LITERATURE CITED

- BERLIN, A. J. 1971. Classification of cleft lip and palate. *In* Cleft lip and palate, W. C. Grabb, S. W. Rosenstein and K. R. Bzoch (eds.). Little, Brown and Company, Boston, Massachusetts, pp. 54-65.
- COLYER, F. 1936. Variations and disease of the teeth of animals. John Bale, Sons and Danielsson Limited, London, England, pp. 115-118.
- HARTUNG, B., AND W. SCHWECKENDIEK. 1973. Malformations of the ear in cleft palate patients. *Journal of Maxillofacial Surgery* 1: 253-258.
- HAYAMA, S. 1989. Kuril seal -the present status in Japan. *Ambio* 17: 75-78.
- KARNAHAN, D. A., AND R. B. STARK. 1958. A new classification for cleft lip and palate. *Plastic and Reconstructive Surgery* 22: 435-441.
- KATO, Y. 1969. Comparative embryology of domestic animals [In Japanese]. Yokendo, Tokyo, Japan, pp. 76-86.
- KING, J. E. 1964. Seals of the world. Trustees of the British Museum, London, England, pp. 51-56.
- . 1983. Seals of the world. 2nd ed. Oxford University Press, Oxford, England, pp. 174-177.
- LATHAM, R. A. 1969. The pathogenesis of the skeletal deformity associated with unilateral cleft lip and palate. *Cleft Palate Journal* 6: 404-414.
- LAUCKNER, G. 1985. Pinnipeds. *In* Disease of marine animals, Vol. IV, O. Kinne (ed.). Biologisch Anstalt Helgoland, Hamburg, Federal Republic of Germany, pp. 683-793.
- MOOR, K. L. 1983. Before we are born. W. B. Saunders Company, Philadelphia, Pennsylvania, pp. 142-146.
- NAITO, Y., AND M. NISHIWAKI. 1972. The growth of two species of the harbour seal in the adjacent waters of Hokkaido. *The Scientific Reports of the Whales Research Institute* 24: 127-144.
- NIIZUMA, A. 1986. A review of the taxonomy of the Kuril Seal and other members of the genus *Phoca* [In Japanese with English summary]. *In* Ecology and protection of the Kuril seal, K. Wada, T. Itoo, A. Niizuma, S. Hayama, and M. Suzuki (eds.). Tokai University Press, Tokyo, Japan, pp. 1-17.
- OHSHIMA, Y. 1964. Statistical study of the position of cleft and abnormality in number and position of tooth in cleft palate patients [In Japanese]. *Journal of the Japanese Stomatological Society* 13: 401-422.
- PRUZANSKY, S. 1955. Factors determining arch form in clefts of the lip and palate. *American Journal of Orthodontics* 41: 827-951.
- SHAUGHNESSY, P. D., AND F. H. FAY. 1977. A review of the taxonomy and nomenclature of North Pacific harbour seals. *Journal of Zoology, London* 182: 385-419.
- SMALL, E. 1967. Disease of the mouth and esophagus. *Journal of the American Veterinary Medical Association* 151: 1714-1718.
- SUZUKI, M., N. OHTAISHI, AND F. NAKANE. 1990. Supernumerary postcanine teeth in the Kuril seal (*Phoca vitulina stejnegeri*), the larga seal (*Phoca largha*) and the ribbon seal (*Phoca fasciata*). *Japanese Journal of Oral Biology* 32: 323-329.
- WARBURG, M. 1960. Anophthalmos complicated by mental retardation and cleft palate. *Acta Ophthalmologica* 38: 394-404.

Received for publication 10 June 1991.