

## **Morbilliviral Disease in Atlantic Bottlenose Dolphins (*Tursiops truncatus*) from the 1987-1988 Epizootic**

Authors: Lipscomb, Thomas P., Schulman, F. Yvonne, Moffett, Deborah, and Kennedy, Seamus

Source: Journal of Wildlife Diseases, 30(4) : 567-571

Published By: Wildlife Disease Association

URL: <https://doi.org/10.7589/0090-3558-30.4.567>

---

BioOne Complete ([complete.BioOne.org](https://complete.BioOne.org)) is a full-text database of 200 subscribed and open-access titles in the biological, ecological, and environmental sciences published by nonprofit societies, associations, museums, institutions, and presses.

Your use of this PDF, the BioOne Complete website, and all posted and associated content indicates your acceptance of BioOne's Terms of Use, available at [www.bioone.org/terms-of-use](https://www.bioone.org/terms-of-use).

Usage of BioOne Complete content is strictly limited to personal, educational, and non - commercial use. Commercial inquiries or rights and permissions requests should be directed to the individual publisher as copyright holder.

---

BioOne sees sustainable scholarly publishing as an inherently collaborative enterprise connecting authors, nonprofit publishers, academic institutions, research libraries, and research funders in the common goal of maximizing access to critical research.

## Morbilliviral Disease in Atlantic Bottlenose Dolphins (*Tursiops truncatus*) from the 1987–1988 Epizootic

Thomas P. Lipscomb,<sup>1</sup> F. Yvonne Schulman,<sup>1</sup> Deborah Moffett,<sup>2</sup> and Seamus Kennedy,<sup>2</sup> <sup>1</sup> Department of Veterinary Pathology, Armed Forces Institute of Pathology, Washington, DC 20306, USA; <sup>2</sup> Department of Agriculture for Northern Ireland, Veterinary Sciences Division, Stormont, Belfast, BT4 3SD, Northern Ireland

**ABSTRACT:** Lungs and lymph nodes of 79 Atlantic bottlenose dolphins (*Tursiops truncatus*) that died from 6 August 1987 to 16 April 1988 along the Atlantic coasts of New Jersey, Virginia, and Florida (USA) were examined histologically and were tested for the presence of morbillivirus antigen by an immunoperoxidase technique. Lung lesions included areas of interstitial pneumonia characterized by varying combinations of type II pneumocyte hyperplasia, interstitial fibroplasia and leukocytes, syncytia, and intranuclear and intracytoplasmic inclusion bodies. Fungal, bacterial, and mixed bacterial and fungal pneumonias were common. Lymphoid depletion, lymphocytolysis, syncytia, and intranuclear and intracytoplasmic inclusion bodies were present in lymph nodes. Morbillivirus antigen was detected in 42 (53%) of 79 dolphins examined. Based on histopathologic and immunocytochemical findings, we diagnosed morbillivirus-induced disease. This is the first report of disease caused by morbillivirus in bottlenose dolphins and in any cetacean species outside Europe.

**Key words:** Atlantic bottlenose dolphin, *Tursiops truncatus*, morbillivirus, survey, immunohistochemistry.

From June of 1987 through May of 1988, an approximately ten-fold increase in mortality of Atlantic bottlenose dolphins (*Tursiops truncatus*) occurred along the Atlantic coast of the United States (Federal Register, 1993). The increased incidence of dolphin stranding spread south from New Jersey (USA), eventually reaching Florida (USA). At the end of the epizootic, 742 dolphins were confirmed dead. Over 50% of the inshore population of bottlenose dolphins in the affected area was estimated to have died (Federal Register, 1993). After a scientific investigation, Geraci (1989) concluded that the most likely cause of the mortality was brevetoxin, a “red tide” toxin produced by the marine dinoflagellate *Ptychodiscus brevis*.

At the direction of the U.S. National Marine Fisheries Service, formalin-fixed paraffin-embedded tissues from 80 bottlenose dolphins collected during this investigation were transferred to the Armed Forces Institute of Pathology (AFIP), Washington, D.C. (USA) for independent studies and to be permanently stored. Similar specimens from 15 other bottlenose dolphins that died during the epizootic and that were not examined as part of the initial investigation also were submitted to the AFIP.

As part of a retrospective study of the 1987 to 1988 bottlenose dolphin epizootic, we performed histologic examinations of all lung and lymph nodes from the submitted cases. Lung or lymph node samples were available in 79 of the 95 cases. These dolphins stranded from 6 August 1987 to 16 April 1988 along the Atlantic coast of the United States between 39°50'N, 74°20'W and 28°24'N, 80°37'W. Of these, 12 washed ashore in New Jersey, 42 in Virginia (USA), and 23 in Florida; the sites of stranding of two dolphins were not documented. Paraffin-embedded tissues were sectioned at 5  $\mu$ m and stained with hematoxylin and eosin for examination by light microscopy. Selected sections were stained with Brown-Hopps Gram stain, Brown and Brenn Gram stain, or by Grocott's methenamine silver nitrate method (Arrington, 1992).

We also examined sections of these tissues stained for morbilliviral antigen by an immunoperoxidase technique (Kennedy et al., 1991). A monoclonal antibody to hemagglutinin protein of phocine distemper virus (Kennedy et al., 1988) was used as the primary antibody. This antibody also reacts with striped dolphin (*Stenella coe-*

*ruleoalba*) morbillivirus, harbor porpoise (*Phocoena phocoena*) morbillivirus, canine distemper virus, and measles virus (Domingo et al., 1990; Trudgett et al., 1991). Unless otherwise stated, the reagents used for immunostaining were part of a commercially available avidin-biotin-peroxidase technique kit (Vectastain Elite ABC Kit, Vector Laboratories Inc., Burlingame, California, USA). All steps, unless otherwise indicated, were performed at temperatures between 15 and 23 C in a dark humidified chamber. Fresh Tris-saline buffer at pH 7.6 (TBS) was used for each washing step. Briefly, sections were cut at 5  $\mu$ m and placed on glass slides coated with a solution of casein glue (Elmer's Glue-All, Borden, Inc., Columbus, Ohio, USA), deparaffinized and placed in alcohol. Sections were incubated in a freshly prepared solution of 0.5% hydrogen peroxide in methanol for 20 min. After rinsing in tap water, sections were washed in TBS for 10 min. They were then placed in a solution of 0.1% pronase (Protease XIV, Sigma Chemical Co., St. Louis, Missouri, USA) in TBS for 5 min at 20 C. Sections were washed twice in buffer for 10 min and then incubated in diluted (1:50) normal horse serum for 20 min to remove background staining. Diluted (1:10) primary antibody was applied overnight to sections. Sections were rinsed in tap water and washed twice in TBS for 20 min. Diluted (1:200) biotinylated horse anti-mouse immunoglobulin G solution was placed on the sections for 30 min at 20 C. Sections were washed for 20 min and incubated with avidin-biotin-peroxidase complex reagent for 30 min. After washing in TBS for 20 min, sections were incubated in diaminobenzidine tetrahydrochloride (Sigma Chemical Co.)-hydrogen peroxide staining solution for 10 min and counterstained lightly with Mayer's hematoxylin (Drury et al., 1967). Lung and lymph node sections from morbillivirus-infected striped dolphins were used as positive controls. Test sections incubated with a monoclonal antibody to chicken anemia virus prepared

by the methods of McNulty et al. (1990), or test sections from which first layer antibody was omitted served as negative controls.

Significant lung lesions often were present. Areas of interstitial pneumonia characterized by varying combinations of type II pneumocyte hyperplasia, interstitial fibroplasia and leukocyte infiltration, occasional syncytia, and rare eosinophilic intranuclear and intracytoplasmic inclusion bodies were seen. These lesions frequently were subtle. Acute or subacute suppurative and often hemorrhagic pneumonias that contained fungal hyphae or Gram-negative bacteria, or a combination of the two, were prevalent. Gram-negative bacillary emboli indicated septicemia in some cases. Generalized lymphoid depletion, selective depletion of lymphoid follicles, lymphocytolysis, syncytia, and infrequent eosinophilic intranuclear and intracytoplasmic inclusion bodies were found in lymph nodes. Suppurative lymphadenitis associated with bacterial colonies occasionally was encountered.

In lung tissue, there was specific intracytoplasmic and intranuclear staining of morbilliviral antigen in bronchiolar and alveolar epithelial cells, syncytia (Fig. 1), macrophages, and interstitial mononuclear cells. Similar staining was present in lymphocytes (Fig. 2) and syncytia in lymph nodes. Staining of morbilliviral antigen was frequently highly focal in distribution in these tissues.

Morbilliviral antigen was detected in 42 (53%) of 79 dolphins tested. Among antigen-positive dolphins, 40 (95%) had syncytia or inclusion bodies in lung or lymph node. Based on histopathology, 22 (52%) antigen-positive dolphins had evidence of fungal pneumonia, bacterial pneumonia, mixed fungal and bacterial pneumonia, septicemia, or bacterial lymphadenitis. Of antigen-negative dolphins, 12 (32%) had syncytia or inclusion bodies and 16 (43%) had fungal or bacterial pneumonia, or septicemia; none had bacterial lymphadenitis. It is likely that postmortem autolysis and

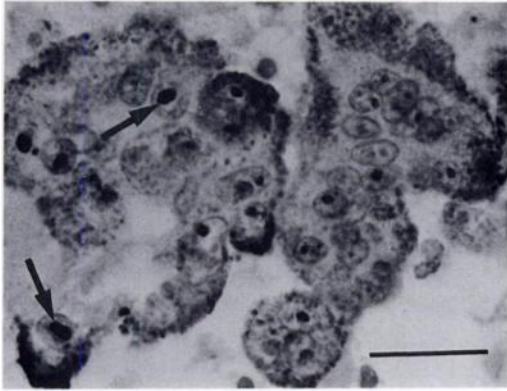


FIGURE 1. Immunoperoxidase staining of morbillivirus antigen in cytoplasm and nuclei (arrows) of syncytia in pulmonary alveolus of a bottlenose dolphin. Bar = 20  $\mu$ m.

focal distribution of antigen prevented detection of antigen in many of these dolphins. Morbilliviral antigen was demonstrated in three dolphins from New Jersey, 20 from Virginia, 17 from Florida, and two for which the stranding site was not recorded. Dates of stranding of antigen-positive dolphins ranged from 8 August 1987 to 17 February 1988.

Our histopathologic and immunoperoxidase findings were similar to those reported for morbillivirus-infected harbor porpoises (Kennedy et al., 1991, 1992), harbor seals (*Phoca vitulina*) (Kennedy et al., 1988, 1989), and striped dolphins (Domingo et al., 1990). Syncytial cells and eosinophilic intranuclear and intracytoplasmic inclusion bodies are highly characteristic of morbillivirus-induced disease in several species (Barker et al., 1993; Dungworth, 1993). Morbilliviral infections, such as canine distemper virus infection of dogs, cause immunosuppression that commonly results in opportunistic infections (Dungworth, 1993). The frequent occurrence of fungal and bacterial infections in dolphins that also were infected by morbillivirus was consistent with morbillivirus-induced immunosuppression resulting in secondary infections.

The hypothesis that brevetoxin was the

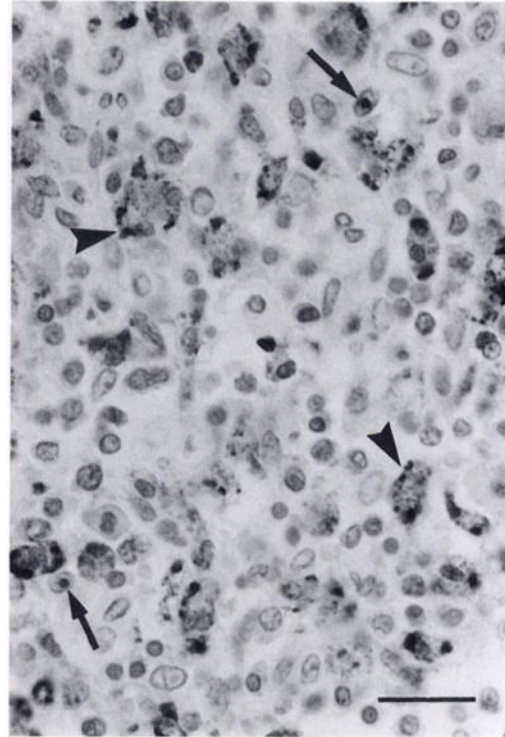


FIGURE 2. Immunoperoxidase staining of morbillivirus antigen in cytoplasm (arrowheads) and nuclei (arrows) of lymphocytes in lymph node of a bottlenose dolphin. Bar = 20  $\mu$ m.

cause of the epizootic has been criticized (U.S. Congress, 1989). Although a red tide was identified off Cape Hatteras, North Carolina (USA) in October 1987, none was apparent when the increased mortality in New Jersey began in June of that year (Geraci, 1989). Red tides often kill fish, shellfish, and birds (O'Shea et al., 1991), but, except for the immediate vicinity of Cape Hatteras, significant mortality of these species did not coincide temporally or geographically with dolphin mortality. Furthermore, brevetoxin is not known to produce the lesions found in the dolphins, which were predominantly those of opportunistic bacterial and fungal infections (Geraci, 1989); also, the assay used to identify brevetoxin in the dolphin tissues recently was reported to be unreliable (Hansen, 1991).

High levels of anthropogenic contami-

nants, including polychlorinated biphenyls which are known to be immunosuppressive in other species (Vos, 1972), were detected in some dolphins from the die-off (Geraci, 1989); however, these levels generally were similar to those found in captive bottlenose dolphins (Geraci, 1989). While contaminants may have played a contributory role in causing the epizootic, evidence supportive of a primary role has not been presented.

During the initial investigation, serum antibody titers to canine distemper virus were detected in six of 13 live-caught dolphins (Geraci, 1989), evidence of a previous exposure to a morbillivirus. However, no evidence of morbilliviral infection was recognized in stranded dolphins and attempts to culture morbilliviruses failed (Geraci, 1989). Details of the viral culture methods were not described. No viruses were detected with an ultrastructural examination of tissues (Geraci, 1989). Morbillivirus and other infectious agents were discounted as likely causes of the epizootic (Geraci, 1989).

This is the first report of disease caused by morbilliviral infection in bottlenose dolphins and in any cetacean species outside Europe. Morbilliviruses have caused major epizootics affecting striped dolphins (Domingo et al., 1990), harbor seals (Kennedy et al., 1988), and Baikal seals (*Phoca sibirica*) (Grachev et al., 1989) justifying their designation as the most potent agents of mass mortality in both pinnipeds and odontocete cetaceans worldwide (Duignan et al., 1994). We have demonstrated that morbillivirus-induced disease was prevalent in dolphins that died throughout much of the geographic and temporal span of the 1987 to 1988 epizootic. The frequent presence of morbilliviral antigen in tissues of dolphins with bacterial and fungal infections is consistent with morbillivirus-mediated immunosuppression as occurs in other species. Our findings provide strong evidence that morbilliviral infection was the primary cause of this epizootic and

establish it as the first of four morbilliviral epizootics among aquatic mammals in recent years.

We thank A. Trudgett and C. Lyons for provision of the monoclonal antibody to phocine distemper virus and the many individuals who assisted in the past and present investigations of this epizootic. This study was supported in part by the American Registry of Pathology, Washington, D.C. 20306-6000. T. P. Lipscomb is a major in the U.S. Army. The opinions or assertions contained herein are the private views of the authors and are not to be construed as official or as reflecting the views of the Department of the Army or of the Department of Defense.

#### LITERATURE CITED

- ARRINGTON, J. B. 1992. Bacteria, fungi, and other microorganisms. *In* Laboratory methods in histotechnology, E. D. Prophet, B. Mills, J. B. Arrington, and L. H. Sobin (eds.). American Registry of Pathology, Washington, D.C., pp. 221-226.
- BARKER, I. K., A. A. VAN DREUMEL, AND N. PALMER. 1993. The alimentary system. *In* Pathology of domestic animals, K. V. F. Jubb, P. C. Kennedy, and N. Palmer (eds.). Academic Press, San Diego, California, pp. 159-163.
- DOMINGO, M., L. FERRER, M. PUMAROLA, A. MARCO, J. PLANA, S. KENNEDY, M. MCALISKEY, AND B. K. RIMA. 1990. Morbillivirus in dolphins. *Nature* 336: 21.
- DRURY, R. A. B., E. A. WALLINGTON, AND R. CAMERON. 1967. Carleton's histological technique, 4th ed., Oxford University Press, New York, New York, 127 pp.
- DUIGNAN, P. J., J. T. SALIKI, D. J. ST. AUBIN, J. A. HOUSE, AND J. R. GERACI. 1994. Neutralizing antibodies to phocine distemper virus in Atlantic walrus (*Odobenus rosmarus rosmarus*) from arctic Canada. *Journal of Wildlife Diseases* 30: 90-94.
- DUNGWORTH, D. L. 1993. The respiratory system. *In* Pathology of domestic animals, K. V. F. Jubb, P. C. Kennedy, and N. Palmer (eds.). Academic Press, San Diego, California, pp. 617-624.
- FEDERAL REGISTER. 1993. Volume 58, number 64, U. S. Government Printing Office, Washington, D.C., pp. 17,789-17,791.
- GERACI, J. R. 1989. Clinical investigation of the 1987-88 mass mortality of bottlenose dolphins along the US central and south Atlantic coast. Final report to National Marine Fisheries Service

- and U.S. Navy, Office of Naval Research, and Marine Mammal Commission, Guelph, Ontario, Canada, pp. 1-63.
- GRACHEV, M. A., V. P. KUMAREV, L. V. MAMAEV, V. L. ZORIN, L. V. BARANOVA, N. N. DENIKINA, S. I. BELIKOV, E. A. PETROV, V. S. KOLESNIK, R. S. KOLESNIK, V. M. DOROFEEV, A. M. BEIM, V. N. KUDELIN, F. G. NAGIEVA, AND V. N. SIDOROV. 1989. Distemper virus in Baikal seals. *Nature* 338: 209.
- HANSEN, L. J. 1991. Report on the investigation of 1990 Gulf of Mexico bottlenose dolphin strandings, Southeast Fisheries Science Center, National Oceanic and Atmospheric Administration, Miami, Florida, pp. 53-55.
- KENNEDY, S., J. A. SMYTH, S. J. MCCULLOUGH, G. M. ALLAN, F. MCNEILLY, AND S. MCQUAID. 1988. Confirmation of cause of recent seal deaths. *Nature* 335: 21.
- , ———, P. F. CUSH, P. DUIGNAN, M. PLATTEN, S. J. MCCULLOUGH, AND G. M. ALLAN. 1989. Histopathologic and immunocytochemical studies of distemper in seals. *Veterinary Pathology* 26: 97-103.
- , ———, ———, M. MCALISKEY, S. J. MCCULLOUGH, AND B. K. RIMA. 1991. Histopathologic and immunocytochemical studies of distemper in porpoises. *Veterinary Pathology* 28: 1-7.
- , T. KUIKEN, H. M. ROSS, M. MCALISKEY, D. MOFFETT, C. M. MCNIVEN, AND M. CAROLE. 1992. Morbillivirus infection in two common porpoises (*Phocoena phocoena*) from the coasts of England and Scotland. *The Veterinary Record* 131: 286-290.
- MCNULTY, M. S., D. P. MACKIE, D. A. POLLOCK, J. MCNAIR, D. TODD, K. A. MAWHINNEY, T. J. CONNOR, AND F. MCNEILLY. 1990. Production and preliminary characterization of monoclonal antibodies to chicken anemia agent. *Avian Diseases* 34: 352-358.
- O'SHEA, T. J., G.B. RATHBUN, R. K. BONDE, C. D. BUERGELT, AND D. K. ODELL. 1991. An epizootic of Florida manatees associated with a dinoflagellate bloom. *Marine Mammal Science* 7: 165-179.
- TRUDGETT, A., C. LYONS, M. J. WELSH, N. DUFFY, S. J. MCCULLOUGH, S. MCNEILLY. 1991. Analysis of a seal and a porpoise morbillivirus using monoclonal antibodies. *The Veterinary Record* 128: 61.
- U.S. CONGRESS. 1989. First session on the conclusions of the clinical investigation of the 1987-88 mass mortality of the bottlenose dolphins along the United States central and south Atlantic coasts. Subcommittee on Oversight and Investigations, Committee on Merchant Marine and Fisheries, House of Representatives, 101st Congress, first session. Serial number 101-20, U. S. Government Printing Office, Washington, D.C., pp. 1-302.
- VOS, J. G. 1972. Toxicology of PCB's for mammals and birds. *Environmental Health Perspectives* 1: 105-117.

*Received for publication 25 October 1993.*