



A Trematode Metacercaria Causing Gill Cartilage Proliferation in Steelhead Trout from Oregon

Authors: Olson, Robert E., and Pierce, Jack R.

Source: Journal of Wildlife Diseases, 33(4) : 886-890

Published By: Wildlife Disease Association

URL: <https://doi.org/10.7589/0090-3558-33.4.886>

BioOne Complete (complete.BioOne.org) is a full-text database of 200 subscribed and open-access titles in the biological, ecological, and environmental sciences published by nonprofit societies, associations, museums, institutions, and presses.

Your use of this PDF, the BioOne Complete website, and all posted and associated content indicates your acceptance of BioOne's Terms of Use, available at www.bioone.org/terms-of-use.

Usage of BioOne Complete content is strictly limited to personal, educational, and non - commercial use. Commercial inquiries or rights and permissions requests should be directed to the individual publisher as copyright holder.

BioOne sees sustainable scholarly publishing as an inherently collaborative enterprise connecting authors, nonprofit publishers, academic institutions, research libraries, and research funders in the common goal of maximizing access to critical research.

A Trematode Metacercaria Causing Gill Cartilage Proliferation in Steelhead Trout from Oregon

Robert E. Olson¹ and Jack R. Pierce,² ¹Department of Fisheries and Wildlife, Coastal Oregon Marine Experiment Station, Oregon State University, Hatfield Marine Science Center, Newport, Oregon 97365, USA; ²Department of Biology, Austin College, Sherman, Texas 75090, USA

ABSTRACT: Gills of steelhead trout (*Oncorhynchus mykiss*) held in liveboxes to detect the presence of pathogens in the Willamette River (Oregon, USA) became heavily infected with trematode metacercariae. The metacercariae encysted adjacent to the cartilaginous rods of gill filaments and elicited a host response of cartilage proliferation from the perichondrium. Although some hyperplasia of gill epithelium and fusion of lamellae was apparent, the extent of damage to the respiratory surface was apparently insufficient to cause trout mortality. Morphological characteristics of the metacercariae did not allow precise identification, but they suggested affinities to either the Heterophyidae or Cryptogonimidae. Some heterophyids are known to cause proliferation of cartilage in fish gills, while cryptogonimids are not. This is the first report of trematode induced gill cartilage proliferation in steelhead trout.

Key words: Metacercaria, gill cartilage proliferation, *Oncorhynchus mykiss*, pathology, steelhead trout.

As part of an effort to determine the resistance of two hatchery stocks of winter steelhead trout (*Oncorhynchus mykiss*) to the myxosporidian pathogen, *Ceratomyxa shasta*, the Oregon Department of Fish and Wildlife (ODFW, Corvallis, Oregon, USA) held steelhead trout in live boxes at Riverview Marina on the Willamette River near Corvallis, Oregon (USA: 44°35'N, 123°16'W) during the summer of 1993. Fish were sampled periodically throughout the summer months and examined for pathogens. Although *C. shasta* was the dominant pathogen in these fish, a trematode metacercaria that located in the steelhead trout gills was present in substantial numbers in individual fish. We obtained a sample of seven steelhead trout that had been held in a Willamette River livebox from 2 June 1993 until 27 September 1993. This report describes the trematode

infection and the host tissue response to them.

The seven steelhead trout (200 to 247 mm. total length) from Marion Forks Hatchery (Idanha, Oregon, USA) stock were examined for the presence of gill metacercariae. Using a dissecting microscope, the number of trematode metacercariae per gill filament was determined for each trout by counting the larvae in a total of 50 gill filaments taken from 3 gill arches. Several metacercariae were dissected from their cysts, fixed in warm AFA (ethyl alcohol formalin-acetic acid fixative) and stained with Semichon's acetocarmine. Representative gill arches were fixed in Bouin's solution before routine histological preparation and staining with Wheatley's modified Gomari trichrome (Alger, 1966). In the following description means for examination and measurement data are followed by the standard deviation (SD) in parenthesis. Representative specimens of metacercariae are deposited in the H. W. Manter Parasitological collection (University of Nebraska, Lincoln, Nebraska, accession number HWML 39318).

All seven steelhead trout were infected with trematode metacercariae in gill tissue (Figs. 1,2). The mean number of metacercariae per gill filament for all fish was 12.9 (5.5) and ranged from 6.8 (2.9) in the most lightly infected fish to 18.6 (3.8) in the heaviest. To obtain an estimate of the total number of trematodes in each fish, the number of gill filaments on each of 10 gill arches was counted (mean = 95.8, SD = 4.05) and the result multiplied by the number of gill arches per fish (8) and then by the mean number of trematodes per gill filament. Based upon this, the mean number of metacercariae per fish was 9,847 (3,621; range = 5,181-14,286).

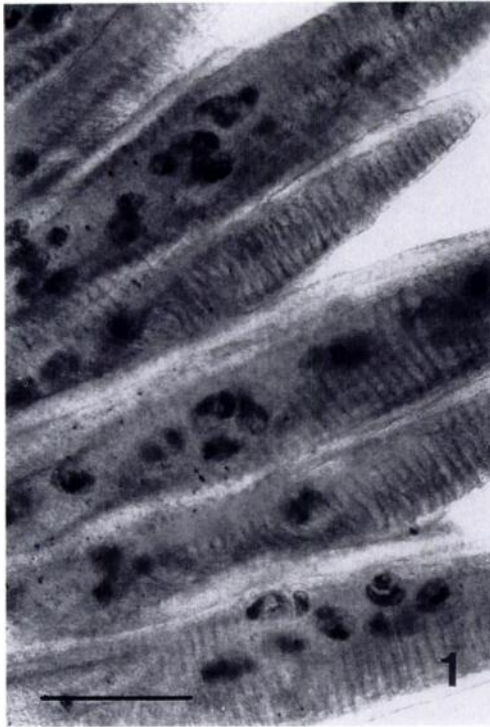

FIGURE 1. Wet mount of gill filaments of steelhead trout with metacercarial cysts. Bar = 500 μm .

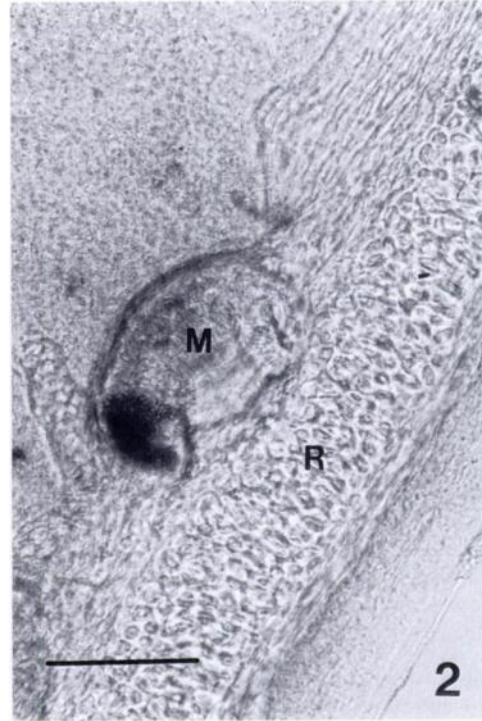


FIGURE 2. Wet mount of gill filaments of steelhead trout with a metacercaria (M) encysted adjacent to a cartilaginous gill rod (R). Bar = 100 μm .

Living trematode metacercariae were dissected from several cysts. They measured approximately 500 μm in length although they were capable of substantial contraction and extension of their bodies. Eight fixed and stained metacercariae had a mean length of 359 μm (40.5) and a mean width of 90.6 μm (21.7).

Metacercariae were elongate, minutely spinose, with a relatively large oral sucker surrounded by a single row of 29 to 32 circumoral spines (Fig. 3). The pharynx was separated from the mouth by a prepharynx, the ventral sucker was small and in the posterior third of the body, the digestive tract extended posterior to the ventral sucker. Reproductive organs were not developed and a ventrogenital sac was not observed.

Histological sections of steelhead trout gill tissue were examined to determine the specific location of metacercarial cysts and any host tissue response to them. In normal gill tissue a gill filament is supported

by a rod of specialized cartilage. The matrix in gill rod cartilage is acidophilic and there is less of it per cell than in most other types of cartilage, the chondrocytes are basophilic (Stoskopf, 1993). Each metacercaria was located adjacent to a cartilaginous rod and was enveloped by the perichondrium (Fig. 4). Thirty metacercarial cysts were measured, using the inside of cysts as reference points. The mean length was 160 μm (19) while the mean width was 77 μm (9). Each cyst was directly surrounded by one to several layers of flattened fibrous tissue and then usually embedded in an area of proliferating cartilage, five to eight cell layers thick. Compared to the mature cartilage of the gill rod, the proliferating cartilage surrounding the parasite was characterized by less pronounced lacunae and less matrix (Fig. 4). In most cases, cartilage proliferation was not sufficient to modify the structure of the gill lamellae; however, hyperplasia of

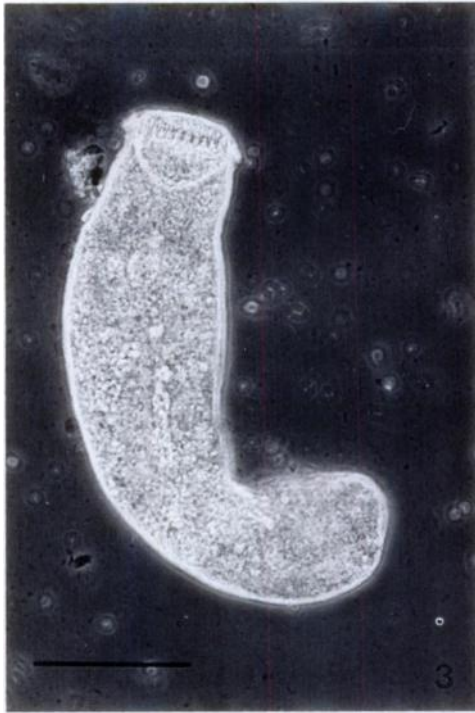

FIGURE 3. Wet mount of metacercaria dissected from cyst. Note the single row of circumoral spines. Bar = 100 μm .

filament epithelium in some areas did lead to fusion of gill lamellae and loss of respiratory surface (Fig. 5). Noga (1996) indicated that while metacercariae usually are innocuous and cause little harm, they can affect organ function if they displace sufficient host tissue. Additionally, the characteristic lack of substantial host response to metacercariae is probably due to cyst formation by the parasite.

Most cercariae which penetrate fish tissues are not highly host specific, although they are often organ-specific (Paperna, 1995). Metacercariae belonging to many different trematode families are known to encyst in the gill tissues of fishes and often elicit a fibroblastic response by the host (Blazer and Gratzek, 1985). In some cases, however, parasites may localize near the cartilaginous rod of the gill filament. Here they may elicit a host response of gill cartilage proliferation. Reports of trematode metacercariae causing proliferation of gill

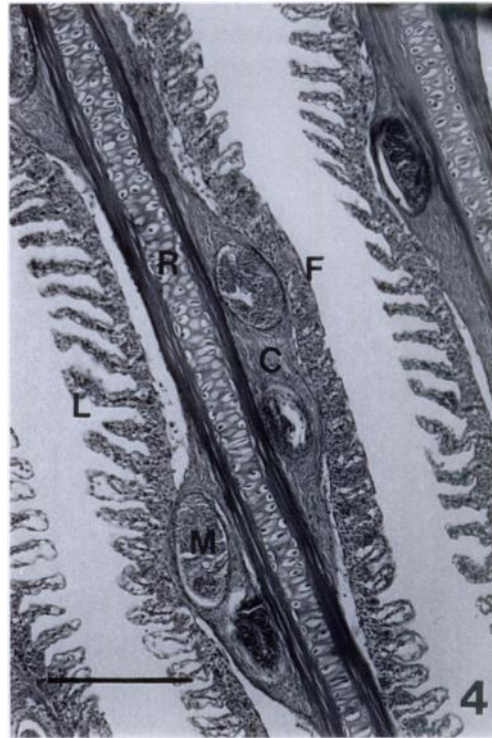


FIGURE 4. Histological section of gill filament of steelhead trout with cartilaginous gill rod (R) and lamellae (L). Metacercarial cysts (M) lie adjacent to gill rod and are enveloped by perichondrium and proliferating cartilage (C). Note fusion of lamellae (F). Wheatley's modified Gomori trichrome stain. Bar = 200 μm .

cartilage have all been putatively caused by members of the family Heterophyidae (Sogandares-Bernal and Lumsden, 1963; Martin, 1964; Blazer and Gratzek, 1985; Paperna, 1995). Sogandares-Bernal and Lumsden (1963) observed metacercariae of *Ascocotyle angrense* in the gill filament cartilage of cyprinodont and poeciliid fishes of the southern and eastern United States. Martin (1964) reported that *Pygidiosoides spindalis* cercariae penetrate the gills of *Fundulus parvipinnis*. There they encyst adjacent to the cartilaginous rod of the gill filament. The host then encloses the metacercaria in a thin layer of bone or cartilage. Blazer and Gratzek (1985) observed a reaction that often consisted of extensive cartilage proliferation around metacercariae in four species of

naturally infected pondraised aquarium fishes in Florida (USA) and in two experimentally infected species. They stated that the metacercariae that they observed resembled members of the family Heterophyidae, especially those in the genus *Pygidiopsoides* and in the *Ascocotyle* spp. complex. A similar host response was described by Farstey as cited in Paperna (1995) from the cichlid *Oreochromis aurea*, at Lake Kinneret (Israel). Metacercariae in this case belonged to the genus *Centrocestus* of the family Heterophyidae. In a detailed study of mineralized ossicles associated with metacercariae of the heterophyid *Apophallus brevis* in the musculature of *Perca flavescens*, Taylor et al. (1994) found that the ossicles were composed of ectopic bone; a single metacercaria had located in a gill arch rather than muscle and chondroblast-like cells had surrounded the parasite.

The unequivocal assignment of the steelhead trout metacercariae to trematode family was not possible based upon observable characteristics of the larval trematodes. It was not possible to distinguish between the families, Heterophyidae or Cryptogonimidae, based upon cumulative morphological evidence. These characteristics included small size, spinose epidermis, circumoral spines, presence of a pre-pharynx and a small ventral sucker. Characteristics that suggested an affinity of these metacercariae with the family Heterophyidae included the above characters, general size and shape, and especially that they located specifically in the cartilage of the gill filaments where they were associated with proliferation of cartilage cells. The steelhead metacercariae differed from the heterophyid genera noted above in the number of circumoral spines. The parasites in steelhead have a single row of 29 to 32 spines; *A. angrense* has an anterior row of 16 to 18 and a posterior accessory dorsal row of two to three spines (Sogandares-Bernal and Lumsden, 1963); *P. spindalis* has a single row of 14 (Martin, 1964); and *C. formosanus* has a double row of 30

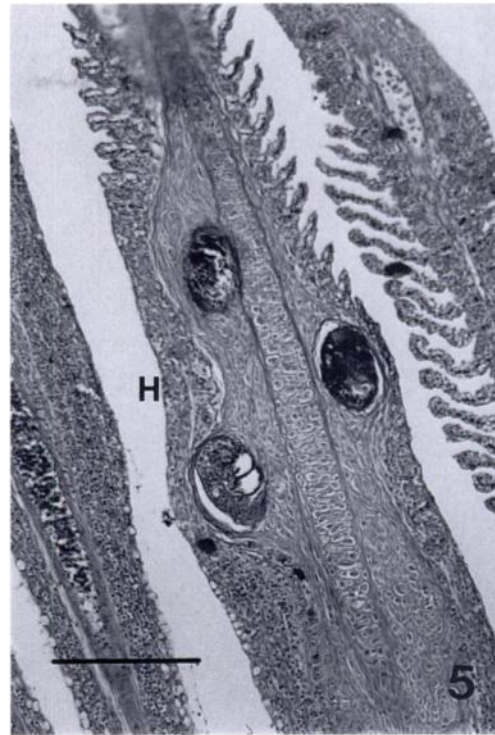

FIGURE 5. Histological section of gill filament of steelhead trout with cartilagenous gill rod and adjacent metacercarial cysts. Note extensive hyperplasia of filament epithelium (H) and fusion of lamellae. Wheatley's modified Gomari trichrome stain. Bar = 200 μ m.

to 36 circumoral spines (Chen, 1942). The number of circumoral spines did correspond with those of certain cryptogonimids, such as in *Allacanthochasmus* sp. In known species of the family Cryptogonimidae, the metacercariae located in tissues other than gill cartilage, often skin or body musculature (Schell, 1985). The only reported heterophyid metacercaria encysted in fishes in Oregon is *Apophallus donicus*. Metacercariae of *A. donicus* encyst in and beneath the skin of six species of northwestern Oregon fishes (Niemi and Macy, 1974). There have been no reports of cryptogonimid metacercariae in Oregon fishes.

Our observations of infected steelhead trout suggested that although the parasites did cause cartilage proliferation, damage to the respiratory surface of the gill was

probably not sufficient to be a direct cause of mortality. Blazer and Gratzek (1985) found that cartilage proliferation was extensive in some cases and was associated with fusion of gill filaments. In heavily infected fish, the resulting reduction in respiratory surface was postulated to be harmful to fish stressed by low oxygen conditions. Paperna (1991) reported similar respiratory stress in cichlids and carp and mortality in farmed Japanese eelers, all infected by metacercariae of *Centrocestus* sp. that located in gill cartilage. It is not known whether or not free-ranging steelhead trout serve as intermediate hosts for the trematode metacercaria discussed here or if confinement in live-boxes facilitated infection.

We thank R. Holt and T. Amandi of the Oregon Department of Fish and Wildlife for providing the infected steelhead trout. This is Oregon Agricultural Experiment Station Technical Paper No. 11011.

LITERATURE CITED

- ALGER, N. 1966. A simple, rapid, precise stain for intestinal protozoa. *American Journal of Clinical Pathology* 45: 361–362.
- BLAZER, V. S., AND J. B. GRATZEK. 1985. Cartilage proliferation in response to metacercarial infections of fish gills. *Journal of Comparative Pathology* 95: 273–280.
- CHEN, H. T. 1942. The metacercaria and adult of *Centrocestus formosanus* (Nishigari, 1924), with notes on the natural infection of rats and cats with *C. armatus* (Tanabe, 1922). *The Journal of Parasitology* 28: 285–298.
- MARTIN, W. E. 1964. Life cycle of *Pygidiopsisoides spindalis* Martin, 1951 (Heterophyidae: Trematoda). *Transactions of the American Microscopical Society* 83: 270–272.
- NIEMI, D. R., AND R. W. MACY. 1974. The life cycle and infectivity to man of *Apophallus donicus* (Skrjabin and Lindtrop, 1919) (Trematoda: Heterophyidae) in Oregon. *Proceedings of the Helminthological Society of Washington* 41: 223–229.
- NOGA, E. J. 1996. *Fish disease: Diagnosis and treatment*. Mosby-Year Book, Inc., St. Louis, Missouri, 367 pp.
- PAPERNA, I. 1991. Diseases caused by parasites in the aquaculture of warm water fish. *Annual Review of Fish Diseases* 1: 155–194.
- . 1995. Digenea (Phylum Platyhelminthes). *In Fish diseases and disorders, Volume 1, Protozoan and metazoan infections*, P. T. K. Woo (ed.), CAB International, Wallingford, United Kingdom, pp. 329–389.
- SCHELL, S. C. 1985. *Handbook of trematodes of North America north of Mexico*. University Press of Idaho, Moscow, Idaho, 263 pp.
- SOGANDARES-BERNAL, F., AND R. D. LUMSDEN. 1963. The generic status of the heterophyid trematodes of the *Ascocotyle* complex, including notes on the systematics and biology of *Ascocotyle angrense* Travassos, 1916. *The Journal of Parasitology* 49: 264–274.
- STOSKOPF, M. K. 1993. Fish histology. *In Fish medicine*, M. K. Stoskopf (ed.), W. B. Saunders Co., Philadelphia, Pennsylvania, pp. 31–47.
- TAYLOR, L. H., B. K. HALL, T. MIYAKE, AND D. K. CONE. 1994. Ectopic ossicles associated with metacercariae of *Apophallus brevis* (Trematoda) in yellow perch, *Perca flavescens* (Teleostei): development and identification of bone and chondroid bone. *Anatomy and Embryology* 190: 29–46.

Received for publication 10 August 1996.