

## **A Stingray Spine in the Scapula of a Bottlenose Dolphin**

Authors: McFee, Wayne, Root, Hillary, Friedman, Richard, and Zolman, Eric

Source: Journal of Wildlife Diseases, 33(4) : 921-924

Published By: Wildlife Disease Association

URL: <https://doi.org/10.7589/0090-3558-33.4.921>

---

BioOne Complete ([complete.BioOne.org](https://complete.BioOne.org)) is a full-text database of 200 subscribed and open-access titles in the biological, ecological, and environmental sciences published by nonprofit societies, associations, museums, institutions, and presses.

Your use of this PDF, the BioOne Complete website, and all posted and associated content indicates your acceptance of BioOne's Terms of Use, available at [www.bioone.org/terms-of-use](https://www.bioone.org/terms-of-use).

Usage of BioOne Complete content is strictly limited to personal, educational, and non - commercial use. Commercial inquiries or rights and permissions requests should be directed to the individual publisher as copyright holder.

---

BioOne sees sustainable scholarly publishing as an inherently collaborative enterprise connecting authors, nonprofit publishers, academic institutions, research libraries, and research funders in the common goal of maximizing access to critical research.

## A Stingray Spine in the Scapula of a Bottlenose Dolphin

Wayne McFee,<sup>1</sup> Hillary Root,<sup>2</sup> Richard Friedman,<sup>3</sup> and Eric Zolman,<sup>1</sup> <sup>1</sup>Department of Commerce, National Oceanic and Atmospheric Administration, National Marine Fisheries Service, Charleston Laboratory, 219 Ft. Johnson Rd., Charleston, South Carolina 29412, USA; <sup>2</sup>Medical University of South Carolina, Molecular and Cellular Biology and Pathobiology Graduate Program, 171 Ashley Avenue, Charleston, South Carolina 29425, USA; <sup>3</sup>Medical University of South Carolina, Department of Orthopaedic Surgery, 171 Ashley Avenue, Charleston, South Carolina 29425, USA

**ABSTRACT:** A stingray spine was found lodged in the scapula of a deceased 272 cm, male bottlenose dolphin (*Tursiops truncatus*) from South Carolina (USA) following skeletal preparation, nearly 6 mo after necropsy. No external puncture wound, internal bruising, or laceration of muscle tissue surrounding the scapula was evident during necropsy of the animal. Implantation of the spine did not appear to be related to the death of the dolphin, but probably occurred at an early age. Abnormal development of bone surrounding the spine resulted in the formation of a cavity at the wound site. Two mechanisms were considered as contributors for the cavity formation. These were the mechanical action of the spine stimulating the body's defense system for managing foreign objects, and the release of potent toxins from the spine sheath.

**Key words:** Bottlenose dolphin, case report, scapula, stingray spine, toxins, *Tursiops truncatus*.

Associations between stingrays and bottlenose dolphins (*Tursiops truncatus*) appear to be common (Walsh et al. 1988). Both inhabit shallow coastal waters of the western North Atlantic Ocean. Incidental physical encounters, whether accidental or intentional, can result in the infliction of a stingray spine into the dolphin. Most descriptions of stingray-spine inflictions have been limited to fleshy parts of dolphins (Castello, 1977; Walsh et al. 1988; Cowan, 1993; McClellan et al. 1996). Less frequently, the spines have been described to penetrate bone (Reynoso, 1989). This report documents a stingray spine embedded in the scapula of a bottlenose dolphin.

On 15 May 1994, a 272 cm, male bottlenose dolphin was reported in distress in the Stono River (32°46.7'N and 80°02.6'W; Charleston County, South Carolina, USA). The dolphin was captured alive by South Carolina Department of

Natural Resources (SCDNR, Charleston, South Carolina, USA) personnel and transported to their holding tank at the Ft. Johnson Marine Facility (James Island, South Carolina, USA) with the intent to rehabilitate the animal. The dolphin expired in the holding tank within 1.5 hr and was immediately transported to the National Marine Fisheries Service (NMFS, Charleston Laboratory, Charleston, South Carolina, USA) for necropsy. A standard necropsy was performed resulting in an inconclusive cause of death. All organs were examined both externally and internally for lesions, color, and texture. Seventy-two 1 cm<sup>2</sup> tissue samples were collected from all major organs, lymph nodes, glands, reproductive organs, and lesions. These were preserved in 10% buffered formalin (Stephens Scientific, Riverdale, New Jersey, USA). Formalin-fixed tissue samples were analyzed by the Armed Forces Institute of Pathology (AFIP, Washington, D.C., USA) for histopathology. The tissues were embedded in paraffin, sectioned (6 μm) with a rotary microtome, stained with hematoxylin-eosin, and examined under light microscopy (Sheehan and Hrapchak 1980). Organ tissues were archived in an -80 C ultracold freezer at the NMFS Charleston Laboratory for subsequent contaminant (trace metals and organics) and acetylcholinesterase activity analyses. Following necropsy, the carcass was flensed and the skull and skeleton frozen at -20 C for later skeletal preparation. The stingray spine fragments were found embedded in the right scapula of the dolphin following skeletal preparation nearly 6 mo after the necropsy.

The necropsy report was inconclusive,

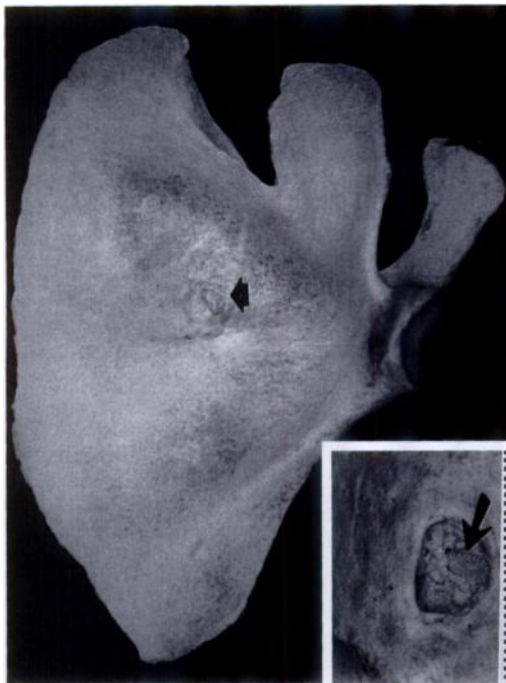


FIGURE 1. Right scapula of a bottlenose dolphin showing dorso-medial surface with cavity 8.1 cm from the glenoid fossa resulting from a stingray spine (arrow). Inset shows detail of primary cavity in scapula of a bottlenose dolphin with stingray spine fragments (arrow). Scale is in mm.

but results suggest that the animal was suffering from a chronic systemic infection based on gross observations of liver, kidney, spleen, lymph nodes, and adrenal glands. In addition, there was a substantial volume of peritoneal fluid that suggested a massive infection. Histologically, the liver exhibited extramedullary hematopoiesis and centrilobular necrosis, and the spleen and lymph nodes were hyperplastic and plasmacytotic with some lung-associated lymph nodes exhibiting multifocal anthracosis. Blood analysis supported the above histological findings of the liver with aspartate aminotransferase (AST[SGOT]) levels elevated (1,340 IU/L; normal = 48–250 IU/L) and alanine aminotransferase (ALT[SGPT]) elevated (398 IU/L; normal = 51–214 IU/L). AFIP results suggested bronchopneumonia as the primary cause of debilitation, possibly caused by a bacterial infection. AFIP results of polymer-

ase chain reaction (PCR) testing for the presence of morbilliviral RNA were negative. There was no evidence of an external puncture wound, internal bruising, or laceration of muscle tissue surrounding the scapula, allowing the stingray spine to remain undetected until further skeletal preparation.

The stingray spine penetrated the medial-dorso surface of the right scapula, 8.1 cm from the glenoid fossa (Fig. 1), and was broken into two fragments. The larger spine fragment (3.1 cm) was located just dorsal and to the left of the smaller spine tip (1.5 cm) fragment. The primary cavity formed around these fragments was 1.3 cm wide and 2.7 cm deep (Fig. 1). The thickness of the scapula at this point was 1.6 cm as compared to 0.6 cm to the left scapula. Each fragment was enclosed within a distinct cavity, both of which lay within the larger primary cavity. Tentative identification of the spine was made through comparisons of spines pictured in Halstead (1970, 1988) and through direct observations of spines provided by the Medical University of South Carolina (MUSC, Charleston, South Carolina, USA). Eight species from three genera (*Dasyatis* spp., *Gymnura* spp., and *Urolophus* spp.) of stingrays occur in the Atlantic Ocean of the United States and Canada (Anonymous, 1991). The spine most closely resembled that of the Atlantic stingray (*Dasyatis sabina*) a species which inhabits shallow waters, commonly in bays, in the western North Atlantic (Halstead, 1970). This is consistent with the habitat of coastal bottlenose dolphins.

The possibility that toxins located in the spine tissue were responsible for the abnormal bone development surrounding the spine fragments was considered. Stingray spines contain a venom produced in the integumentary sheath which covers the barb (Holloway et al. 1953). The cellular localization of putative venom secretory cells has been identified in tissue from the ventrolateral groove of the barb (Halstead and Modglin, 1953). Soft tissue wounds in-

flicted by stingray barbs are characterized by local edema, tissue ischemic necrosis, and extreme pain. Bone tissue inflictions have not been well described.

Russell (1954) identified fifteen fractions of stingray venom by electrophoretic analysis. He determined that the venom contained the enzymes phosphodiesterase and 5-nucleotidase, as well as the neurotransmitter serotonin. Phosphodiesterase activity hydrolytically degrades cyclic AMP, while nucleotidase activity hydrolyzes cellular nucleotides. Serotonin release activates the adenylate cyclase cascade resulting in cyclic AMP formation. The importance of these substances to the venom's mode of action remains uncharacterized. Halstead (1988) suggests that stingray venom is capable of increasing capillary permeability at the wound site, which may lead to the characteristic local edema.

Considering the juxtaposition of the larger spine fragment, the larger cavity formed in the scapula may have been caused by physiological responses to the released venom as a result of localized edema beneath the periosteum of the scapula. The mammalian scapula is formed by intramembranous ossification, that is forming directly from the membranous periosteum (Jackson, 1933). This is opposed to long bones, which are composed of cartilaginous analogs, or bone templates composed primarily of cartilage. In long bones, as the animal matures, successive layers of cartilage are deposited on top of this analog, and the deeper layers gradually ossify. It is assumed that ossification in marine mammals occurs similarly to that of other mammals.

In our case, we suggest that the spine was inflicted into the scapula while the dolphin was quite young when the scapula was surrounded by a thick and active periosteum. The spine evidently pierced the scapula from the medial side and proceeded to break into two sections including the tip which remained embedded and the longer section which came to rest deep

into the periosteum above the embedded spine tip.

Increases in blood flow and capillary permeability at the wound site may have increased the rate of ossification of the raised periosteum surrounding the spine, resulting in formation of the primary cavity. Following resorption of the venomous exudate by developing bone tissue, the spine fragments remained lodged within the primary cavity, but not completely embedded. The position of the spine tip fragment within the primary cavity indicates that the size and nature of cavity formation may be directly related to the extent of edema, and secondarily to the volume of venom released from the spine fragments. Alternatively, this spine tip fragment may have had tissue from the ray or dolphin sheathing it. As the animal grew the soft tissue was resorbed, leaving behind the cavity.

We believe that the primary cavity formed from the two spine fragments was due to the combined effects of the stingray venom and mechanical irritation due to a foreign object. Based on knowledge of the effects of venom on soft tissue, it is plausible that the stingray venom caused edema beneath the periosteum. An increase in blood flow to the penetrated area may have resulted in rapid intramembranous ossification surrounding the spine which formed the large cavity. As a result, only the distal ends of each fragment were embedded within their own cavities.

We also feel that the injury may have occurred at an early age while bone development was occurring. The total length of the dolphin and the worn and missing teeth indicated that this was an older animal. Therefore, the spine wound occurred many years earlier and was not a factor in the animal's death. Moreover, observations during the necropsy did not reveal an external puncture wound, internal bruising, or laceration of muscle tissue surrounding the scapula. This further supports the above assumption.

We thank C. Bain for his assistance in

species identification of the stingray spine and comments; J. McFadden for his expertise in bone development and injuries; B. Phillips for assistance with photography of the Figures; T. Lipscomb for histology results, P. Fair, G. Doucette, and D. Wolf for comments; C. Woodley, G. Scott, and L. Hansen for suggestions; J. P. Gallo Reynoso for providing information on stingray spine inflections in cetaceans; S. Rehrauer for help with skeletal preparation; and the SCDNR for allowing the opportunity to collect a valuable specimen.

#### LITERATURE CITED

- ANONYMOUS. 1991. Common and scientific names of fishes from the United States and Canada, 5th ed., American Fisheries Society, Bethesda, Maryland, 183 pp.
- CASTELLO, H. P. 1977. Food of a killer whale: Eagle stingray, *Mylobatis* found in the stomach of a stranded *Orcinus orca*. Scientific Report of the Whales Research Institute, Tokyo 29: 107-111.
- COWAN, D. F. 1993. Pathologist's Report. Texas Stranding Newsletter, 4: 1-23.
- HALSTEAD, B. W., AND F. R. MODGLIN. 1953. A preliminary report on the venom apparatus of the Batray, *Holorhinus californicus*. Copeia 3: 165-175.
- HALSTEAD, B. W. 1970. Poisonous and venomous marine animals of the world. Vol. 3 U.S. Government Printing Office, Washington, D.C., 1,006 pp.
- . 1988. Poisonous and venomous marine animals of the world. The Darwin Press, Inc., Princeton, New Jersey, 1,168 pp.
- HOLLOWAY, J. E., N. C. BUNKER, AND B. W. HALSTEAD. 1953. The venom of *Urobatis halleri* (Cooper), the round stingray. California Fish and Game 39: 77-82.
- JACKSON, C. M. 1933. Morris' human anatomy, 9th ed. P. Blakiston's Son and Co., Inc., Philadelphia, Pennsylvania, 1,435 pp.
- MCCLELLAN, W. A., V. G. THAYER, AND D. A. PABST. 1996. Stingray spine mortality in a bottlenose dolphin, *Tursiops truncatus*, from North Carolina waters. The Journal of the Elisha Mitchell Scientific Society 112: 98-101.
- REYNOSO, J. P. G. 1989. Traumatismo vertebral en delfin comun *Delphinus delphis* (cetacea: delphinidae) por inclusion de espina de mantarraya *Dasyatis* sp. (*Pisces: Dasyatidae*). Veterinaria Mexico 20: 277-279.
- RUSSELL, F. E. 1954. Cardiovascular effects of the venom of the round stingray, *Urobatis halleri*. In Venoms. American Association for the Advancement of Science, Washington, D.C., pp. 33-41.
- SHEEHAN, D. C., AND B. B. HRAPCHAK. 1980. Theory and practice of histotechnology, 2nd ed. C. V. Mosby Co., St. Louis, Missouri, 481 pp.
- WALSH, M. T., D. BEUSSE, G. D. BOSSART, W. G. YOUNG, D. K. O'DELL, AND G. W. PATTON. 1988. Ray encounters as a mortality factor in Atlantic bottlenose dolphins (*Tursiops truncatus*). Marine Mammal Science 4: 154-162.

Received for publication 20 May 1996.