



Epidermal Tumors of Rainbow Smelt with Associated Virus

Authors: Herman, Roger Lee, Burke, C. N., and Perry, S.

Source: Journal of Wildlife Diseases, 33(4) : 925-929

Published By: Wildlife Disease Association

URL: <https://doi.org/10.7589/0090-3558-33.4.925>

BioOne Complete (complete.BioOne.org) is a full-text database of 200 subscribed and open-access titles in the biological, ecological, and environmental sciences published by nonprofit societies, associations, museums, institutions, and presses.

Your use of this PDF, the BioOne Complete website, and all posted and associated content indicates your acceptance of BioOne's Terms of Use, available at www.bioone.org/terms-of-use.

Usage of BioOne Complete content is strictly limited to personal, educational, and non - commercial use. Commercial inquiries or rights and permissions requests should be directed to the individual publisher as copyright holder.

BioOne sees sustainable scholarly publishing as an inherently collaborative enterprise connecting authors, nonprofit publishers, academic institutions, research libraries, and research funders in the common goal of maximizing access to critical research.

Epidermal Tumors of Rainbow Smelt with Associated Virus

Roger Lee Herman,¹ C. N. Burke,² and S. Perry,³ ¹U.S. Geological Survey, Biological Resources Division, Leetown Science Center, National Fish Health Research Laboratory, 1700 Leetown Road, Kearneysville, West Virginia, 25430, USA; ²Department of Pathobiology, University of Connecticut, Storrs, Connecticut, 06269, USA; ³New Hampshire Fish and Game Department, 2 Hazen Drive, Concord, New Hampshire, 03301, USA.

ABSTRACT: Epithelial tumors of the skin occurred in landlocked populations of rainbow smelt (*Osmerus mordax*) in several lakes in New Hampshire (USA) during the spawning runs. Histologically, these were noninvasive epithelial cell lesions. Herpesvirus-like particles could be seen in the nucleus and cytoplasm. The lesions occurred in both males and females. Prevalence, which varied annually, was as high as 30%.

Key words: Herpesvirus, hyperplasia, neoplasia, *Osmerus mordax*, papilloma, spawning.

In the mid 1980's skin tumors in smelt (*Osmerus* sp.) became of interest when Anders and Möller (1985) found papillomatosis in spawning smelt (*Osmerus eperlanus*) from the estuary of the Elbe River (Germany). Subsequently, Herman (1988) described invasive squamous carcinomas in a population of landlocked rainbow smelt (*Osmerus mordax*) from Maine (USA).

Anders and Möller (1985) cited only the 1916 report by T. Breslauer of epithelial tumors in smelt from the Baltic Sea. However, our review of cases archived in the National Fish Health Research Laboratory (NFHRL, Kearneysville, West Virginia, USA) and the Registry of Tumors of Lower Animals (RTLA, Washington, D.C., USA) revealed several specimens with similar lesions collected from various locations in the northeastern United States as early as 1966. Further, we found that epithelial tumors are seen annually in spawning populations of landlocked rainbow smelt in several lakes in New Hampshire (USA). Herein, we describe the salient histological features of these tumors and provide preliminary observations on the possible infectious agent in their etiology.

Fish were collected from tributaries of Pleasant Lake (Whites Brook, 43°26'N,

71°58'W) and Sunapee Lake (Otter Brook, 43°26'N, 72°4'W), New Hampshire (USA) during spawning runs in April 1988. They were caught after dark using a lift net 1 m in diameter having a 0.6 cm mesh (bar measure) bag. Rainbow smelt with skin tumors were placed in a portable holding tank until morning, when the fish were thoroughly examined and tissue samples were taken.

Twenty-five smelt with multiple lesions were euthanized with tricaine methane-sulfonate (Argent Chemical Laboratories, Redmond, Washington, USA). Lesions and adjacent tissues were excised, cut in 3 to 5 mm portions and preserved in Bouin's solution or minced in 3% glutaraldehyde in pH 7.3 cacodylate buffer.

Paraffin sections were prepared (4 µm) from Bouin's fixed tissue and stained with hematoxylin and eosin, Feulgen reaction for DNA, or alcian blue-periodic acid Schiff for mucopolysaccharides (Coolidge and Howard, 1979). Glutaraldehyde-fixed blocks were post fixed in 2% osmium tetroxide and embedded in Epon 812, thin sectioned and stained with 2% uranyl acetate and Reynold's lead citrate (Hayat, 1986). Stained sections were examined with a Phillips 300 electron microscope operated at 75 to 100 Kv.

The skin tumors were raised, variable in size and shape, and distributed over the body and fins without a definite pattern (Fig. 1). They were translucent to grayish, and some appeared hyperemic or hemorrhagic; they had a jelly-like consistency and were easily dislodged.

The lesions were consistent in having rather abrupt edges (Fig. 2) and being composed of pleomorphic epithelial cells with intercellular bridges (Fig. 3) connected by desmosomes. Mitotic figures were

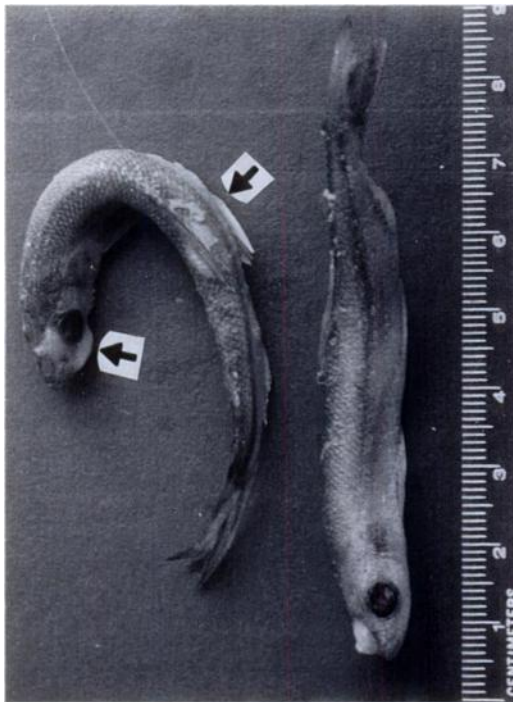

FIGURE 1. Preserved landlocked rainbow smelt with epithelial tumors on head, body and fins (arrows).

not seen. The squamous layer, when present, was only one or two cells thick and the cells appeared less flattened than in adjacent unaffected skin. Penetration through the basement membrane into the dermis was not found, dermal pegs were not present. Individual tumors showed varying amounts of lymphocytic infiltration, necrosis, cystic structures, and "pearl" formation (Fig. 4). Mucous cells, when present in the tumor, were scattered among the epithelial cells. The stratum germinativum could be distinguished in all lesions examined, although it was sometimes mildly disrupted. One tumor, from a male, had overgrown several breeding tubercles with no apparent effect on the tubercle structure.

Virus particles were abundant, but they were not uniformly distributed throughout the tumor. The nucleus contained clusters of virus capsids of 80 to 90 nm (Fig. 5). Enveloped forms of 160 to 200 nm were seen in the cytoplasm and intercellular

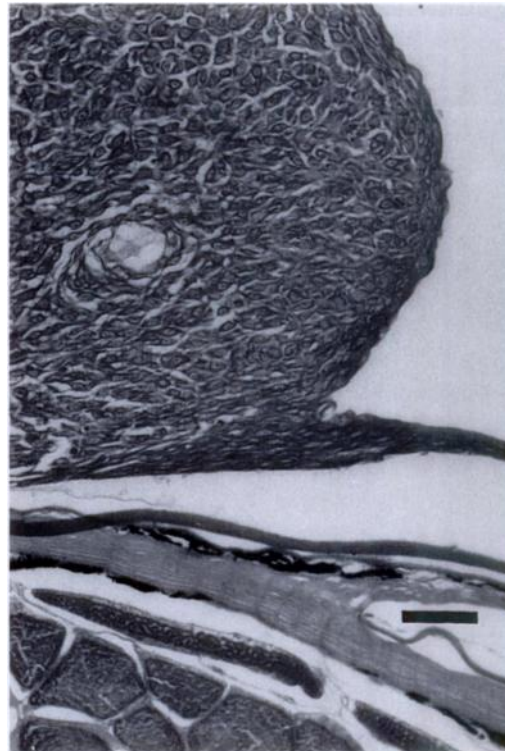


FIGURE 2. Section of skin tumor in rainbow smelt showing abrupt transition from normal epithelium to tumor, and confinement of the growth to the epithelial layer. H&E. Bar = 50 μ m.

spaces (Fig. 6). Crystal arrays of virus, potentially visible with the light microscope, were not seen; this was consistent with the lack of Feulgen positive inclusions in paraffin sections. Presence of the virus in the nucleus, size, and general morphology, suggested the probability of a herpesvirus infection.

Lesions observed in our study have similarities to those described by Anders and Möller (1985) as papillomatosis, but they lack the supporting dermal components. This suggests a diagnosis of epidermal hyperplasia although the presence of epithelial "pearls" suggests the possibility of carcinoma. The role of the apparent virus in these lesions is unknown.

Epidermal tumors with associated virus or viruslike particles have been reported in a variety of fish species from diverse geographical locations (Wolf, 1988). Some of

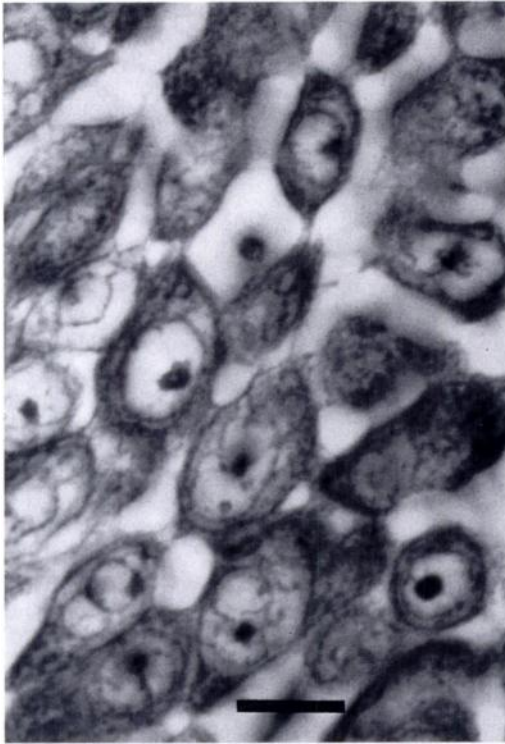


FIGURE 3. Section of skin tumor in rainbow smelt showing pleomorphic epithelioid cells with intercellular bridges. H&E. Bar = 10 μ m.

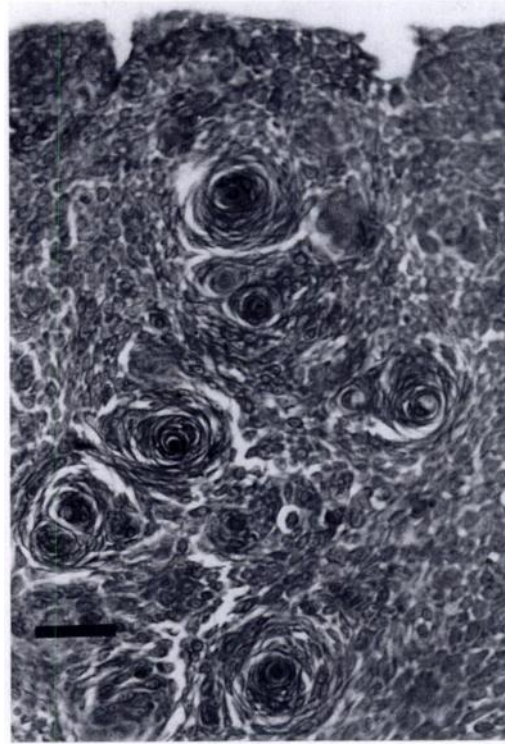


FIGURE 4. Section with numerous "pearl" structures in rainbow smelt with tumors. H&E. Bar = 50 μ m.

these have been transmitted with cell-free tumor extracts. However, a causal relationship between visualized or even isolated virus and epidermal tumors has been firmly established with only three viruses. Lymphocystis iridovirus causes cellular hypertrophy. *Oncorhynchus masou* herpesvirus and cyprinid herpesvirus are oncogenic. Rainbow smelt with grossly similar epithelial lesions have been caught not only in the tributaries of lakes sampled for this study, but also in at least three nearby lakes. Surveys by biologists of the New Hampshire Fish and Game Department (Concord, New Hampshire, USA) showed the prevalence in these lakes varied annually from <10% to >30%.

NFHRL archives contain photo transparencies of a landlocked rainbow smelt caught from Lake Winnepesaukee (New Hampshire, USA; 43°37'N, 71°21'W) in 1966 with lesions histologically similar to

those of specimens caught in 1988. Sections of three anadromous specimens collected from the Penabscot River (Maine, USA; 44°28'N, 68°48'W) in 1976 show folded epithelial proliferations with thin dermal connective tissue elements sup-

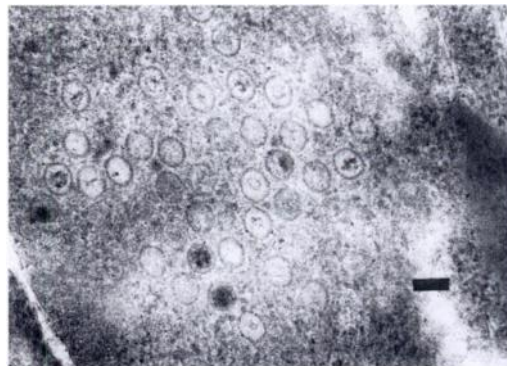


FIGURE 5. Electronmicrograph of putative virus in a cell nucleus of a tumor from rainbow smelt. Bar = 100 nm.

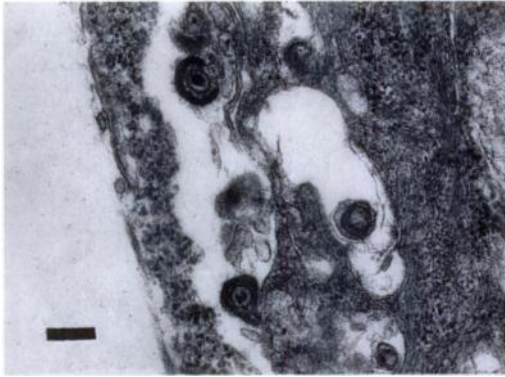


FIGURE 6. Electronmicrograph of enveloped putative virus in the intercellular space of an epithelial tumor in rainbow smelt. Bar = 200 nm.

porting the folds. The anadromous specimens had only one tumor each, whereas all the landlocked forms had multiple lesions.

The neoplasms from rainbow smelt in New Hampshire appeared to differ from those described by Anders and Möller (1985). The lesions of European smelt were described as papillomatous, and Anders (1988) illustrated several cases with folded, thickened epithelium with supporting connective tissue elements. The neoplasms from the fish in New Hampshire had no papillomatous configurations. Individual European smelt showed only one or two neoplasms, whereas the fish from New Hampshire had many. Neoplasms from the three anadromous specimens from Maine presented a gross and histological picture similar to that in the European smelt. There appears to be a difference in structure of lesions in marine versus freshwater specimens. This could be explained by a common etiology expressed differently in marine and freshwater environments. Measurements of the virus particles by Anders and Möller (1985) and Morrison et al. (1996) indicate a slightly larger capsid than found in the fish from New Hampshire. Conversely, the enveloped form in the fish from New Hampshire was larger. If the visualized viruses are the etiological agents in all three cases, they could be different but closely

related viruses. The report of epidermal tumors in rainbow smelt from rivers of Nova Scotia (Canada) may argue against these hypotheses (Morrison and MacDonald, 1995). The specimens from Nova Scotia had either thickened epidermal or papillomatous lesions. A few lesions were diagnosed as carcinomas. All lesions contained similar virus particles.

The ease with which the majority of these lesions appear to be dislodged and the presence of lymphocytic reactions suggests the neoplasms slough spontaneously and cause no significant problem for the individual fish unless a secondary fungal or bacterial infection develops. Fungal lesions are common on rainbow smelt in bait holding tanks, but to what extent such infections may be a problem in the noncaptive populations is unknown.

Affected fish are most commonly observed during the spawning runs, but have been caught through the ice prior to the spawning season. Lesions have not yet been reported from fish caught during summer. The association of lesions with sexually active fish suggests hormones may unmask the virus, suppress immune response or directly affect the epithelium, causing uncontrolled growth. Anders and Yoshimizu (1994) discuss some of these potential interactions. Alternately, the seasonality may be a result of temperature modulations of the immune response of the fish, as suggested by Bowser et al. (1988) for walleyes (*Stizostedion vitreum*) with dermal sarcoma. Positive identification and elucidation of the relationship of the virus to the lesions will require isolation and cultivation of the virus for transmission studies.

LITERATURE CITED

- ANDERS, K. 1988. Biologie von Tumor- und tumorähnlichen Krankheiten der Elbfische. Verlag H. Möller, Keil, Germany. 173 pp.
- , AND H. MÖLLER. 1985. Spawning papillomatosis of smelt, *Osmerus eperlanus* L., from the Elbe estuary. *Journal of Fish Diseases* 8: 233–235.
- , AND M. YOSHIMIZU. 1994. Role of viruses

- in the induction of skin tumors and tumor-like proliferations of fish. *Diseases of Aquatic Organisms* 19: 215–232.
- BOWSER, P. R., M. J. WOLFE, J. L. FORNEY, AND G. A. WOOSTER. 1988. Seasonal prevalence of skin tumors from walleye (*Stizostedion vitreum*) from Oneida Lake, New York. *Journal of Wildlife Diseases* 22: 292–298.
- COOLIDGE, B. J., AND R. M. HOWARD. 1979. Animal histology procedures, 2nd ed., U.S. Department of Health, Education, and Welfare, Public Health Service, National Institutes of Health, NIH Publication No. 80–275, Washington, D.C., 198 pp.
- HAYAT, M. A. 1986. Basic Techniques for Transmission Electron Microscopy. Academic Press, Inc., Orlando, Florida, 411 pp.
- HERMAN, R. L. 1988. Squamous cell carcinoma in rainbow smelt *Osmerus mordax*. *Diseases of Aquatic Organisms* 5: 71–73.
- MORRISON, C., AND C. MACDONALD. 1995. Epidermal tumors on rainbow smelt and Atlantic salmon from Nova Scotia. *Journal of Aquatic Animal Health* 7: 241–250.
- , C. T. LEGGIADRO, AND D. J. MARTELL. 1996. Visualization of viruses in tumors of rainbow smelt *Osmerus mordax*. *Diseases of Aquatic Organisms* 26: 19–23.
- WOLF, K. 1988. Fish viruses and fish viral diseases. Cornell University Press, Ithaca, New York, 476 pp.

Received for publication 10 December 1996.