

CHRONIC RHINITIS ASSOCIATED WITH HERPESVIRAL INFECTION IN CAPTIVE SPUR-THIGHED TORTOISES FROM SPAIN

Authors: Muro, J., Ramis, A., Pastor, J., Velarde, R., Tarres, J., et al.

Source: Journal of Wildlife Diseases, 34(3) : 487-495

Published By: Wildlife Disease Association

URL: <https://doi.org/10.7589/0090-3558-34.3.487>

BioOne Complete (complete.BioOne.org) is a full-text database of 200 subscribed and open-access titles in the biological, ecological, and environmental sciences published by nonprofit societies, associations, museums, institutions, and presses.

Your use of this PDF, the BioOne Complete website, and all posted and associated content indicates your acceptance of BioOne's Terms of Use, available at www.bioone.org/terms-of-use.

Usage of BioOne Complete content is strictly limited to personal, educational, and non - commercial use. Commercial inquiries or rights and permissions requests should be directed to the individual publisher as copyright holder.

BioOne sees sustainable scholarly publishing as an inherently collaborative enterprise connecting authors, nonprofit publishers, academic institutions, research libraries, and research funders in the common goal of maximizing access to critical research.

CHRONIC RHINITIS ASSOCIATED WITH HERPESVIRAL INFECTION IN CAPTIVE SPUR-THIGHED TORTOISES FROM SPAIN

J. Muro,¹ A. Ramis,² J. Pastor,² R. Velarde,² J. Tarres,² and S. Lavin^{2,3}

¹ Clínica Veterinaria Prat de la Creu, c/Prat de la Creu, 24, bloc H, Andorra la Vella, Principality of Andorra, Spain

² Department of Animal Pathology and Animal Science, School of Veterinary Medicine, Universitat Autònoma de Barcelona, 08193. Bellaterra, Barcelona, Spain.

³ Corresponding author (e-mail: IVPP4@cc.uab.es)

ABSTRACT: An epidemic of chronic rhinitis in a population of 50 captive spur-thighed tortoises (*Testudo graeca graeca*) from Palafrugell (Girona, Spain) is described, in which eight animals died and 12 were euthanatized to perform necropsies and post-mortem studies. The main clinical sign was a bilateral, seromucous rhinitis often accompanied by stomatitis and glossitis. Hematology and serum biochemistry were performed in 33 of the 50 ill animals and in 29 healthy tortoises from three disease-free populations. Lymphocyte count, aspartate aminotransferase (AST) activity, and α -globulin levels were significantly higher in the animals from the sick population. The heterophil count was significantly lower in the sick animals. Some of the diseased tortoises also showed a normocytic-normochromic anemia. Lesions were restricted to the respiratory system and oral cavity. Marked epithelial hyperplasia and presence of a severe mixed inflammatory infiltrate in the epithelium of the oral, nasal, and tracheal mucosae were observed. Electron microscopy demonstrated the presence of intracytoplasmic and intranuclear viral particles of the size, shape, and distribution pattern typical of a herpesvirus.

Key words: Chronic rhinitis, epidemic, herpesviral infection, spur-thighed tortoise, *Testudo graeca graeca*.

INTRODUCTION

Spur-thighed (*Testudo graeca graeca*) and Hermann's (*Testudo hermanni hermanni*) tortoises are the two species that live in the Iberian Peninsula. Their natural distribution was originally in Northern Africa (from Morocco to Libya) and Southern Spain (National Park of Doñana-Huelva, Southern Murcia and Northern Almeria, Spain) (Stubbs, 1989). Some colonies also were introduced in Sardinia, Sicily, Malta and continental Italy. Spur-thighed tortoises are endangered species in eastern Europe (Honegger, 1974; Highfield and Martin, 1990). The species is actually included in the International Union for Conservation of Nature and Natural Resources (IUCN) Appendix II (vulnerable) (Stubbs, 1989) and in the European Union regulation 3626/82 Attachment C.

Herpesviral infections in chelonians have been associated with several diseases in different species (Jacobson, 1994; Pettan-Brewer et al., 1996). Herpesviral infections has been associated with stomatitis and enteritis in Hermann's and four-toed (*Agrionemys horsfieldii*) tortoises

(Lange et al., 1989); stomatitis and encephalitis in Hermann's and spur-thighed tortoises (Müller et al., 1990); glossitis and meningoencephalitis in Hermann's tortoises (Heldstab and Bestetti, 1989); and stomatitis in Hermann's and spur-thighed tortoises (Cooper et al., 1988; Braune et al., 1989). Upper respiratory tract diseases, mainly rhinitis, are among the most common diseases affecting captive tortoises (Keymer, 1978; Lawrence and Needham, 1985; Jacobson et al., 1991). Running nose syndrome is a significant potentially transmissible disease of tortoises. Several outbreaks have been described in Europe during recent years, with the main clinical sign being a bilateral, persistent, seromucous rhinitis. Although a viral etiology has been advocated by some authors (Lawrence and Needham, 1985; Highfield, 1993; Jacobson, 1994), the exact causative agent has not been yet identified.

Simultaneously to the above, an epidemic of chronic rhinitis was detected in 1988 in the USA affecting desert tortoises (*Gopherus agassizii*). Electron microscopic studies demonstrated the presence of *My-*

coplasma spp. in the nasal epithelium of all the diseased animals and in one of the controls (Jacobson et al., 1991). However, viral particles were recently identified in lungs, oral and nasal cavity lesions in this species (Pettan-Brewer et al., 1996). Thus, it is postulated that a virus may be responsible for the first stages of this upper respiratory tract disease as it is for the European running nose syndrome, although they also may be different clinical processes. The present study describes the clinical signs, hematological and serum biochemistry changes and microscopic lesions found in a captive population of spur-thighed tortoises with chronic rhinitis due to a herpesviral infection.

MATERIAL AND METHODS

An epidemic of chronic rhinitis was detected in a private collection of tortoises from Palafrugell (Girona, Spain, 46°40'N, 5°20'E). The overall population consisted of 50 adult spur-thighed tortoises, three four-toed tortoises and 12 Hermann's tortoises, but the disease process affected only the spur-thighed tortoises. The spur-thighed tortoises had come from Southern Morocco and had been continuously introduced since 1984. The animals had been reproductively successful at the rate of 100 new tortoises per year until the chronic rhinitis epidemic appeared. All the adult tortoises lived in semi-wild conditions. The diet consisted of a mixture of wild plants from the area and commercial vegetables and fruits (Highfield, 1990; Boyer and Boyer, 1994). There were no extreme temperatures in their restrained habitat; hibernation pattern were similar to those seen in their natural habitat.

In 1990, rhinitis was noticed after the hibernation period in March. This was not coincident with any new importation or introduction. Thirty-three spur-thighed tortoises were affected of the overall population of 50 tortoises and only 12 individuals hatched that year during the hatching period from August to September. Eight tortoises died and 12 were euthanatized. The remaining animals were treated with enrofloxacin (5% Baytril, Bayer AG, Leverkusen, Germany), which controlled the disease (Highfield, 1993; Bonnie et al., 1994).

Two groups of animals were used for this study. The first group (Group I) consisted of 33 clinically ill animals (eight males and 25 females), weighing from 240 to 2,480 g. Twelve of them were euthanatized for the histopatho-

logical study. The second group (Group II) consisted of 29 healthy animals (10 males and 19 females) from three private collections located in the same geographic area and weighing from 360 to 2,420 g. All the tortoises (Groups I and II) were adult animals. Thorough physical examinations as described by Jacobson (1987) and Jackson and Lawton (1992) were performed to identify clinically healthy animals. To establish hematological reference values, animals from three disease-free zoological collections, which had not introduced new animals for 2 yr were studied. Thus, asymptomatic carriers were excluded.

Blood samples were obtained during March and April from Groups I and II by puncture of the dorsal coccygeal vein, using 0.45 × 13 mm needles and 1 to 2 ml syringes (Samour et al., 1984). From each sample, 0.6 ml were introduced in heparinized tubes (Jacobson, 1987; Jacobson et al., 1992) (Microtainer, Becton Dickinson & Co., Rutherford, New Jersey, USA) and 0.6 ml were placed in plastic tubes, allowing them to clot for 30 to 40 min and then centrifuging them at 3,000 (r.p.m.) for 10 min to obtain serum.

All samples were refrigerated (0–4 C) until they were processed for hematology and glucose determinations. Time between sample collection and processing was always <4 hr (Jacobson, 1992). Serum was frozen until biochemical analysis could be performed. Red blood cell and leukocyte counts were manually performed by the hemocytometric method, using modified Natt-Herrick solution (1:100 dilution) and a Neubauer chamber (Campbell, 1996).

Hemoglobin concentration was determined by the cyanomethemoglobin method, using a photometer (4010 Photometer, Boehringer Mannheim, Hamburg, Germany). To avoid false increased values due to the cloudiness produced by free erythrocyte nuclei (Campbell, 1996), readings of the samples were performed after centrifugation at 3,000 (r.p.m.) for 5 min. Hematocrit value was determined by the microhematocrit method, using a microhematocrit centrifuge (Hawksley, Lancing, W Sussex, England) and centrifuging at 16,000 (r.p.m.) for 5 min. Erythrocytic indices, MCV (mean corpuscular volume), MCH (mean corpuscular hemoglobin) and MCHC (mean corpuscular hemoglobin concentration) were calculated using standard formulas (Campbell, 1996). The differential leukocyte count was performed by microscopic identification of 100 cells on a May-Grünwald/Giemsa (Panreac, Barcelona, Spain) stained blood smear, following the identification criteria described by Hawkey and Dennett (1989) and Alleman et al. (1992).

The serum biochemical parameters determined were glucose, total bilirubin, urea, creatinine, uric acid, cholesterol, phosphorus, sodium, potassium, chloride, aspartate aminotransferase (AST), alanine aminotransferase (ALT), lactate dehydrogenase (LDH), gamma glutamyltransferase (GGT), alkaline phosphatase (AP), amylase, lipase, total protein concentration, and protein fractions. Most of these parameters were automatically determined at 37 C by a Merck Autoanalyzer (Vitalab Selectra model, Barcelona, Spain), using Merck reagents. Sodium and potassium were determined by a selective electrode photometer (Beckman, Electrolyte 2A model, Fullerton, California, USA).

Serum total proteins were determined by the Biuret method (Jacobson, 1992). Serum protein fractions were separated and quantified by electrophoresis using an ATOM-501 feeder (Sebla, Lyon, France) with an electrophoretic bucket and cellulose acetate bands. Migration was performed with 0.04 M sodium veronal buffer at 200 volts and 50 mA for 28 min. Staining was accomplished with amide black (Panreac, Barcelona, Spain). The obtained fractions were then quantified by photodensitometric read, using the DIGISCAN ATOM-430 photodensitometer (Photodensitometer D.V.S. Sebla, Mod. 1510, Lyon, France).

Due to the presence of an exoskeleton and the inability to explore them, radiology is essential in the diagnosis of clinical processes affecting tortoises (Jackson and Sainsbury, 1992). Two different views, antero-posterior and latero-lateral, were performed on each tortoise to better evaluate both lung fields and to detect pneumonic foci (Jacobson, 1987).

Necropsies of the 12 euthanatized animals from Group I were performed. Euthanasia was by an intracoelomic injection of sodium pentobarbital (Pentobarbital sodique, Sanofi, Libourne, France). The heads of five of these tortoises were bisected longitudinally with an electric saw, complete necropsies were performed following the technique of Cooper (1992). Tissues from all organs were fixed during 24 hours in 10% buffered formalin for their histopathological study. Three mm-thick blocks were then cut and fixed again in 10% buffered formalin for an additional 6 hr. The cut sections were then embedded in paraffin and processed following routine procedures (Bancroft and Stevens, 1992). Four μ m-thick sections were cut from each block and there were stained with hematoxylin and eosin. Tissue blocks for transmission electron microscopy (TEM) were fixed in 2% osmium tetroxide (OsO_4) in Sorensen buffer for 30 min at room temperature and then washed twice in Sorensen buffer for 10

min. One mm-thick semi-thin sections were cut and stained with toluidin blue for light microscopy. Ultra-thin sections were cut and stained with uranyl acetate and lead nitrate for transmission electron microscopy (Bancroft and Stevens, 1992).

A Student-Fisher *t*-test for independent data was used to statistically evaluate the hematological and biochemical parameters between Group I (ill tortoises) and Group II (healthy tortoises) with significant differences set at $P \leq 0.05$.

RESULTS

The main clinical sign of affected tortoises was sialorrhoea, which was bloody in some of the affected animals. The most frequent lesions were stomatitis and glossitis, with presence of bloody ulcers and diphtheric membranes that covered the dorsal surface of the tongue and the hard palate, and even reached the glottis and esophagus in some animals. All the diseased spur-thighed tortoises showed bilateral and persistent rhinitis with serous to mucopurulent nasal discharge, frequently associated with radiographically evident bronchopneumonia. Dyspnea was present in seven animals (23%), which presented increased respiratory sounds, open-mouth breathing and totally extended necks. Two of the animals had large cutaneous ulcers covered by caseous material on the caudal surface of one rear limb. Blepharitis and keratitis were seen in three of the affected animals. One of the tortoises showed a unilateral "arcus lipoides corneae" without hypercholesterolemia.

Hematologic and serum biochemical results of animals from Groups I and II are shown in Tables 1 and 2, respectively. Significant differences between Groups I and II were found in only two of 12 hematological parameters evaluated, lymphocytes and heterophils. Diseased tortoises displayed marked lymphocytosis (mean = 52%) and heteropenia (mean = 35%) with a high percentage of toxic heterophils. Eccentric, pale blue-stained, long intracytoplasmic inclusions were found in lymphocytes from three animals. Similar inclusions also were observed in the cytoplasm

TABLE 1. Hematologic parameters of the spur-thighed tortoises from Spain with (Group I) and without (Group II) rhinitis.

Parameters	Units	Group I ^a			Group II ^b		
		n ^c	Mean	SD ^d	n ^c	Mean	SD ^d
Red blood cell count	10 ¹² /L	21	0.46	0.1	29	0.45	0.1
Hematocrit value	%	16	23.7	7.4	20	21.7	7.7
Hemoglobin concentration	g/L	20	81.1	18.2	22	76.4	31.6
Mean corpuscular volume	fL	16	502.2	117.6	20	471.9	164.6
Mean corpuscular hemoglobin	pg	19	196.5	65.2	22	181.4	87.5
Mean corpuscular hemoglobin concentration	g/L	14	357.0	55.0	19	447.5	25.4
White blood cell count	10 ⁹ /L	22	7.4	4.1	29	8.3	3.9
Lymphocytes ^e	%	13	51.8	19.8	10	19.6	10.2
Monocytes	%	13	6.6	8.3	10	3.7	2.5
Heterophils ^e	%	13	35.3	17.8	10	58.1	14.4
Eosinophils	%	13	4.9	4.2	10	8	3.0
Basophils	%	13	1.5	1.5	10	2.5	2.1

^a Tortoises with rhinitis.^b Healthy tortoises.^c Sample size.^d Standard deviation.^e $P < 0.05$ between Groups I and II.

of erythrocytes from two of these tortoises. Three of the diseased tortoises also had a normocytic-normochromic anemia. Aspartate aminotransferase (AST) and α -globulin fraction values were significantly higher (mean = 213.34 U/l and 1.11 g/dl, respectively) in Group I than in the control group (Group II). Radiographically, four tortoises had unilateral pneumonia. Hepatomegaly was observed in three animals in which hepatic steatosis was later diagnosed.

At necropsy, a small amount of intracoelemic fat was found in the inguinal and axillary areas. All the necropsied females had ovarian follicles in different maturation stages. The examination of the longitudinally transected heads demonstrated the existence of abundant seromucous secretion in the nasal cavity and upper respiratory airways. Diphtheroid glossitis was found in six animals. The fibrinoid material extended caudally, surrounding the glottis and even reaching the tracheal bifurcation. Two animals showed emphysematous areas in both lungs and the presence of exudate within the airways. Splenomegaly was observed in one tortoise.

Microscopic lesions were found in the respiratory system and the oral cavity. Animals were classified into three groups depending on the degree and type of lesions found. Tortoises in Group A showed non-specific inflammatory lesions in nasal and oral mucosae, animals in Group B displayed similar lesions plus a catarrhal purulent bronchopneumonia, and animals in Group C were those with intranuclear eosinophilic inclusions in epithelial cells of the respiratory system and oral cavity in addition to the lesions previously described for Groups A and/or B.

Group A consisted of seven animals. All had glossitis and stomatitis with marked epithelial hyperplasia, a severe mixed inflammatory infiltrate (mononuclear cells and polymorphonuclear heterophils) in the epithelial lamina propria, and some degree of exocytosis. In the respiratory system, the variable inflammatory reaction was mainly located in the nasal cavity and trachea. Tracheitis was especially intense in two animals, which showed marked epithelial hyperplasia with areas of squamous metaplasia. A severe mixed inflammatory infiltrate in the lamina propria, exocytosis,

TABLE 2. Serum biochemical parameters of the spur-thighed tortoises from Spain with (Group I) and without (Group II) rhinitis.

Parameter	Units	Group I ^a			Group II ^b		
		n ^c	Mean	SD ^d	n ^c	Mean	SD ^d
Glucose	mEq/L	18	66.3	42.9	20	63.1	42.0
Total bilirubin	mg/dl	7	0.4	0.5	16	0.5	0.7
Urea	mg/dl	27	21.4	20.7	20	31.9	22.2
Creatinine	mg/dl	26	0.3	0.5	15	0.5	0.3
Uric acid	mg/dl	16	1.7	1.2	15	1.9	1.1
Cholesterol	mg/dl	17	171.2	68.4	5	124.8	90.1
Phosphorus	mg/dl	2	7.8	1.0	7	8.0	5.9
Sodium	mEq/L	1	122.0	—	8	135.0	15.6
Potassium	mEq/L	2	3.6	0.7	6	3.5	0.9
Chloride	mEq/L	2	219.5	173.2	9	117.0	15.2
AST ^e	UI/L	29	213.3	295.4	24	52.2	40.2
ALT	UI/L	24	9.6	14.5	12	18.9	18.3
LDH	UI/L	12	128.9	285.9	21	121.5	248.4
GGT	UI/L	8	4.5	4.6	9	2.3	2.9
Alkaline phosphatase	UI/L	12	229.2	317.0	17	196.1	219.9
Amilase	UI/L	4	0.5	0.4	19	1.5	1.7
Lipase	UI/L	3	14.3	17.9	17	63.5	80.7
Total proteins	g/dl	24	3.5	1.2	25	3.7	1.9
Albumin	g/dl	7	1.1	0.4	13	1.1	0.6
Globulins							
α ^e	g/dl	6	1.1	0.06	13	0.6	0.3
β	g/dl	6	0.6	0.03	13	0.5	0.2
γ	g/dl	6	0.8	0.03	13	0.7	0.3
Albumin/Globulin ratio		6	0.5	0.1	13	0.6	0.2

^a Tortoises with rhinitis.

^b Healthy tortoises.

^c Sample size.

^d Standard deviation.

^e $P < 0.05$ between Groups I and II.

and abundant cell debris in the tracheal lumen. In addition, a slight activation of lung lymphoid aggregates and presence of a mixed inflammatory infiltrate (mononuclear cells and polymorphonuclear heterophils) was observed in the alveolar septa.

The two animals included in Group B showed a catarrhal purulent bronchopneumonia in addition to the lesions described for Group A. Their alveolar spaces were filled with foamy macrophages, polymorphonuclear heterophils (PMNH), coccid bacteria, and abundant cell debris. In Group C, all three animals displayed severe glossitis, stomatitis and fibrino-necrotizing and/or purulent rhinotracheitis with numerous intranuclear eosinophilic inclusions within epithelial cells (Figs. 1, 2). Moreover, the nasal fossae and tracheal

lumen were partially obstructed by large amounts of purulent exudate (PMNH, macrophages, multinucleated giant cells, bacteria and cell debris). One animal showed only a slight activation of lymphoid aggregates and a scarce amount of mixed inflammatory infiltrate in the interstitial tissue of the alveolar septa. A catarrhal purulent bronchopneumonia was observed in the other two animals. Broad necrotic areas with loss of the epithelial layer and abundant fibrin deposits were observed in the trachea of the first animal. Intranuclear eosinophilic inclusions also were observed in the alveolar epithelium of this animal.

The ultrastructural study of nasal, lingual, and tracheal epithelium with intranuclear eosinophilic inclusions revealed

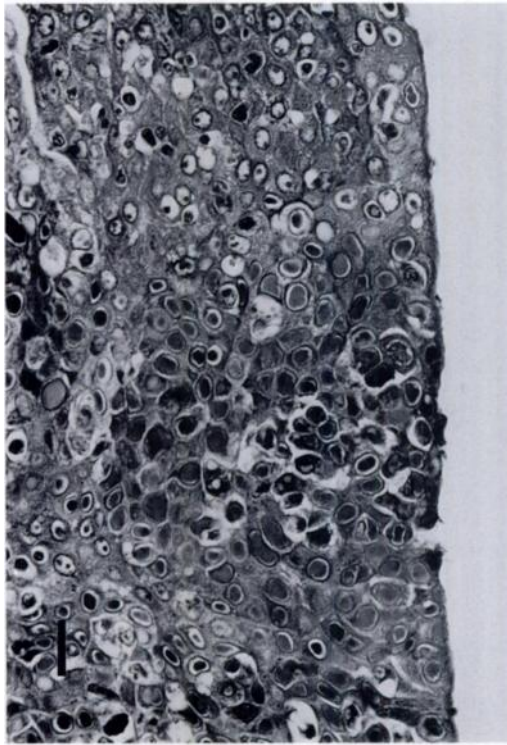


FIGURE 1. Lingual epithelium from a spur-thighed tortoise with herpesvirus infection. The microphotograph shows a marked epithelial hyperplasia, exocytosis of mononuclear cells and multiple intranuclear eosinophilic inclusions in the lingual epithelium. H & E. Bar = 30 μ m.

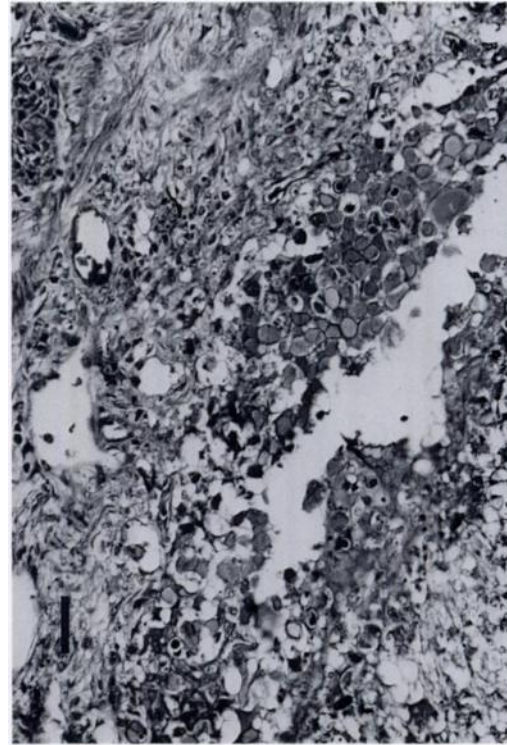


FIGURE 2. Nasal epithelium from a spur-thighed tortoise with herpesvirus infection. The microphotograph shows degenerated and necrotic epithelial cells with multiple intranuclear inclusions in some of them. H & E. Bar = 60 μ m.

intranuclear and intracytoplasmic viral particles (Fig. 3). Intranuclear virions were 130 nm diameter, hexagonal-shaped structures without lipidic envelopes and appeared to be randomly distributed throughout the nucleoplasm. Intracytoplasmic particles were morphologically similar, but showed lipidic envelopes and were bigger (300 nm diameter). They also were distributed randomly throughout the cytoplasm. Their size, morphology and distribution were consistent with those of herpesvirus particles.

DISCUSSION

Clinical signs of diseased tortoises were similar to those described in the running nose syndrome (Jackson, 1991; Highfield, 1993). The first clinical signs observed are nasal discharge, salivation and anorexia,

followed by the appearance of caseous necrosis of membranes on the tongue and oral mucosa; the clinical signs were similar to herpesvirus infection in a desert tortoise (Pettan-Brewer et al., 1996). However, upper respiratory tract signs prevail in the desert tortoise with the upper respiratory tract disease associated with *Mycoplasma* spp. (Jacobson et al., 1991).

Characteristic hematological changes in affected tortoises include heteropenia and lymphocytosis. Since animals that had epithelial viral inclusions in several tissues showed the highest lymphocyte counts, lymphocytosis in these ill tortoises could be associated with herpesvirus infection. Moreover, such animals showed more severe heteropenia and toxic changes in heterophils. Heteropenia and presence of toxic heterophils could be associated with a

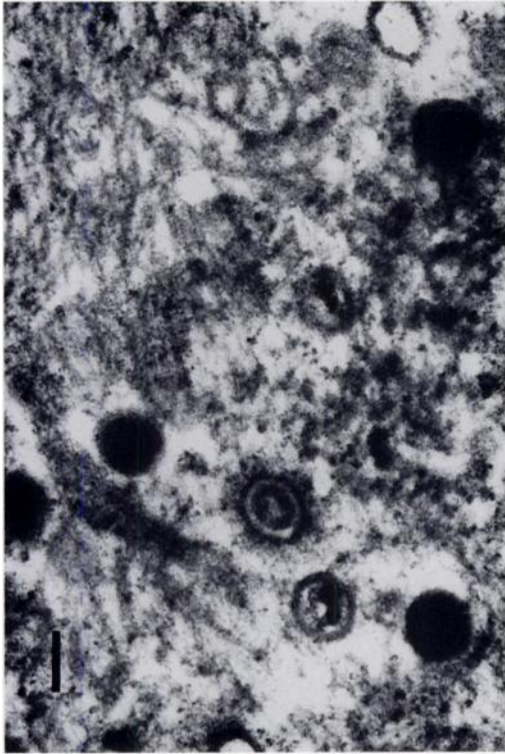


FIGURE 3. Transmission electron micrograph of the lingual epithelium from a spur-thighed tortoise with herpesvirus infection. Intranuclear viral particles have an electron dense core surrounded by an electron dense hexagonal capsid. Bar = 100 μ m.

secondary bacterial infection (Campbell, 1994).

Jacobson et al. (1991) found anemia in desert tortoises with upper respiratory tract disease associated with *Mycoplasma* spp. and related the anemia to chronic inflammation. We found no differences in erythrocyte counts, hematocrit values or hemoglobin concentrations between the diseased and healthy tortoises of our study. However, some of the diseased tortoises showed normocytic-normochromic anemia. The significance of intracytoplasmic inclusion bodies in lymphocytes and erythrocytes remains undetermined. Since they were found in animals with larger amounts of intranuclear inclusion bodies in several tissues, further ultrastructural studies are needed to better clarify their meaning. The significant increases in AST activity

and α -globulin levels in diseased tortoises could be due to the severe tissue necrosis present (Jacobson et al., 1991; Campbell, 1996).

The histopathological lesions found in tongue, oral cavity, trachea, and lungs are similar to those previously described in herpesvirus infections (Harper et al., 1982; Braune et al., 1989; Heldstab and Bestetti, 1989; Lange et al., 1989; Müller et al., 1990; Pettan-Brewer et al., 1996). In contrast, in desert tortoises infected with *Mycoplasma agassizii* the lesions are primarily confined to the nasal cavity (Jacobson et al., 1991; Jacobson et al., 1995). *Mycoplasma* spp. were not seen in our study, but cultures were not performed to rule out their presence.

As in mammalian herpesviruses, the herpesvirus found in our study shows a marked tropism for epithelial tissue. Viral replication takes place in the oral mucosa epithelium, which could mean that transmission from animal to animal is mainly oral. From there, the virus spreads to other organs and systems (Müller et al., 1990). Viral replication also occurs in the respiratory tract, which could be indicative of aerosol transmission. Müller et al. (1990) have suggested vertical transmission for this virus because they found intranuclear viral particles in the ductus deferent epithelium in male tortoises. In our study, ovarian follicles were found in different maturation stages, which could indicate that the process does not affect folliculogenesis. However, egg hatching seemed to be severely diminished.

Herpesviruses often induce persistent and latent infections with irregular periods of disease reactivation and viral shedding. Infected animals may remain asymptomatic for several years (Müller et al., 1990; Gerlach, 1994). Possibly this also occurs in tortoises. The high incidence of the disease during the spring and summer months may be due to activation of latent viruses due to the immunosuppression present after hibernation (Lawrence and Needhan, 1985; Braune et al., 1989).

Highfield (1993) reported mortality rates from 50 to 100% in tortoises affected of running nose syndrome. In our study, eight out of 50 tortoises died during a 5 mo period. Mortality decreased after treatment of secondary bacterial infections with enrofloxacin at 10 mg/kg/day, intramuscularly, for 10 days (Highfield, 1993; Prezant et al., 1994). If the more severely affected animals were not allowed to hibernate, mortality rates also were reduced. Most animals showed signs of rhinitis after hibernation, so they had to be treated again at that time. Using this treatment protocol, all the remaining animals but one were kept alive subsequently. Prognosis of affected tortoises is difficult to assess due to the lack of sustained studies.

The existence of asymptomatic or latently infected animals among recently imported or new introductions of tortoises in their natural habitat hinders disease control. Quarantine periods, serologic testing, PCR tests, lingual prints and cell cultures could be useful for clinical diagnosis and identify carriers (Müller et al., 1990).

LITERATURE CITED

- ALLEMAN, A., E. R. JACOBSON, AND R. E. RASKIN. 1992. Morphologic and cytochemical characteristics of blood cells from the desert tortoise (*Gopherus agassizii*). *American Journal Veterinary Research* 53: 1645-1651.
- BANCROFT, J. D., AND A. STEVENS. 1992. Theory and practice of histochemical techniques. Churchill Livingstone, Edinburgh, UK, 677 pp.
- BONNIE, L. R., M. PAPICH, AND R. A. COOK. 1994. Pharmacokinetics of enrofloxacin after a single intramuscular injection in indian star tortoises (*Geochelone elegans*). *Journal of Zoo and Wildlife Medicine* 25: 88-94.
- BOYER, D. M., AND T. H. BOYER. 1994. Tortoise care. *Bulletin of the Association of Reptilian and Amphibian Veterinarians* 4: 16-28.
- BRAUNE, S., W. GEIB, AND W. THIEL. 1989. Eine neue durch Herpesviren verursachte Erkrankung bei Landschilkröten. *Tierärztliche Praxis* 17: 416-419.
- CAMPBELL, T. W. 1994. Hematology. *In Avian medicine: Principles and application*. B. W. Ritchie, G. J. Harrison and L. R. Harrison (eds.). Wingers Publishing Inc., Lake Worth, Florida, pp. 176-198.
- . 1996. Clinical pathology. *In Reptile medicine and surgery*. D. R. Mader (ed.). W. B. Saunders Co., Philadelphia, Pennsylvania, pp. 248-257.
- COOPER, J. E., S. GSCHMEISSNER, AND R. D. BONE. 1988. Herpes-like virus particles in necrotic stomatitis of tortoises. *Veterinary Record* 21: 544.
- . 1992. Post-mortem examination. *In Manual of reptiles*. P. Beynon (ed.). British Small Animal Veterinary Association, Cheltenham, UK, pp. 40-45.
- GERLACH, H. 1994. Viruses. *In Avian medicine: Principles and application*. B. W. Ritchie, G. J. Harrison and L. R. Harrison (ed.). Wingers Publishing Inc., Lake Worth, Florida, pp. 874-885.
- HARPER, P. A. W., D. C. HAMMOND, AND W. HEUSCHELE. 1982. A herpesvirus-like agent associated with a pharyngeal abscess in a desert tortoise. *Journal of Wildlife Diseases* 18: 491-494.
- HAWKEY, C. M., AND T. B. DENNETT. 1989. Normal and abnormal red cells, granulocytes, lymphocytes, monocytes and azurophils. *In A colour atlas of comparative veterinary haematology*. C. M. Hawkey and T. B. Dennett (eds.). Wolfe Medical Publications, London, UK, 192 pp.
- HELDSTAB, A., AND G. BESTETTI. 1989. Herpesviridae causing glossitis and meningoencephalitis in land tortoises (*Testudo hermanni*). *Herpetopathologia* 1: 5-9.
- HIGHFIELD, A. C., AND J. MARTIN. 1990. Is there a tortoise AIDS in our midst. Special Report, Tortoise Trust Newsletter Autumn: 2-8.
- . 1990. Keeping and breeding tortoises in captivity. Longdunn Press Ltd., Bristol, UK, 149 pp.
- . 1993. Running nose syndrome. Tortoise Trust Newsletter 2: 1-2.
- HONEGGER, R. E. 1974. The reptile trade. *In International zoo year book*. The Zoological Society of London, London, UK, 14: 47-52.
- JACKSON, O. F. 1991. Reptiles. Part One. Chelonians. *In Manual of Exotic Pets*. P. H. Beynon and J. E. Cooper (eds.). British Small Animal Veterinary Association, Cheltenham, UK, pp. 221-243.
- , AND P. C. LAWTON. 1992. Examination and diagnostiques techniques. *In Manual of exotic pets*. P. H. Beynon and J. E. Cooper (eds.). British Small Animal Veterinary Association, Cheltenham, UK, pp. 32-35.
- , AND A. W. SAINSBURY. 1992. Radiological and Related Investigations. *In Manual of exotic pets*. P. H. Beynon and J. E. Cooper (eds.). British Small Animal Veterinary Association, Cheltenham, UK, pp. 63-66.
- JACOBSON, E. R. 1987. Reptiles. *Veterinary Clinics of North America: Small Animal Practice* 17: 1203-1225.
- , J. M. GASKIN, M. B. BROWN, R. K. HARRIS, C. H. GARDINER, J. L. LAPOINTE, H. P. ADAMS, AND C. REGGIARDO. 1991. Chronic upper respiratory tract disease of free-ranging desert tor-

- toises (*Xerobates agassizii*). *Journal of Wildlife Diseases* 27: 296–316.
- . 1992. Laboratory investigations. In *Manual of exotic pets*. P. H. Beynon and J. E. Cooper (eds.). British Small Animal Veterinary Association, Cheltenham, UK, pp. 50–53.
- , J. SCHUMACHER, AND M. GREEN. 1992. Field and clinical techniques for sampling and handling blood for hematological and selected biochemical determinations in the desert tortoise, *Xerobates agassizii*. *Copeia* 1: 237–241.
- . 1994. Causes of mortality and diseases in tortoises: A review. *Journal of Zoo and Wildlife Medicine* 25: 2–17.
- , M. B. BROWN, I. M. SCHUMACHER, B. R. COLLINS, R. K. HARRIS, AND P. A. KLEIN. 1995. Mycoplasmosis and the desert tortoise (*Gopherus agassizii*) in Las Vegas Valley, Nevada. *Chelonian Conservation and Biology* 1: 279–284.
- KEYMER, I. F. 1978. Diseases of Chelonians: (1) Necropsy survey of tortoises. *Veterinary Record* 16: 548–552.
- LANGE, H., W. HERBST, J. M. WIECHERT, AND T. SCHLIEBER. 1989. Elektronemikroskopischer Nachweis von Herpesviren bei einem Massensterben von griechischen Landschildkröten (*Testudo hermanni*) und Vierzehenschildkröten (*Agrionemys horsfieldii*). *Tierärztliche Praxis* 17: 319–321.
- LAWRENCE, K., AND J. R. NEEDHAM. 1985. Rhinitis in long term captive Mediterranean tortoises (*Testudo graeca* and *T. hermanni*). *Veterinary Record* 21: 662–664.
- MÜLLER, M., W. SACHSSE, AND N. ZANGGER. 1990. Herpesvirus-Epidemie bei griechischen (*Testudo hermanni*) und der maurischen landschildkröte (*Testudo graeca*) in der Schweiz. *Schweizer Archiv für Tierheilkunde* 132: 199–203.
- PETTAN-BREWER, K. C. B., M. L. DREW, E. RAMSAY, F. C. MOHR, AND L. J. LOWENSTINE. 1996. Herpesvirus particles associated with oral and respiratory lesions in a California desert tortoise (*Gopherus agassizii*). *Journal of Wildlife Diseases* 32: 521–526.
- PREZANT, R. M., R. I. ISAZA, AND E. R. JACOBSON. 1994. Plasma concentrations and disposition kinetics of enrofloxacin in gopher tortoises (*Gopherus polyphemus*). *Journal of Zoo and Wildlife Medicine* 25: 82–87.
- SAMOUR, H. J., D. RISLEY, T. MARCH, B. SAVAGE, O. NIEVA, AND D. M. JONES. 1984. Blood sampling techniques in reptiles. *Veterinary Record* 114: 472–476.
- STUBBS, D. 1989. *Testudo graeca*. In *The conservation biology of tortoises*. I. R. Swinglad and M. W. Klemens (eds.). Occasional Papers of the IUCN Species Survival Commission. Vol. 5, Gland, Switzerland, pp. 31–33.

Received for publication 9 July 1997.