

## **PATHOLOGY OF DISEASES IN WILD DESERT TORTOISES FROM CALIFORNIA**

Authors: Homer, Bruce L., Berry, Kristin H., Brown, Mary B., Ellis, Georgeann, and Jacobson, Elliott R.

Source: Journal of Wildlife Diseases, 34(3) : 508-523

Published By: Wildlife Disease Association

URL: <https://doi.org/10.7589/0090-3558-34.3.508>

---

BioOne Complete ([complete.BioOne.org](https://complete.BioOne.org)) is a full-text database of 200 subscribed and open-access titles in the biological, ecological, and environmental sciences published by nonprofit societies, associations, museums, institutions, and presses.

Your use of this PDF, the BioOne Complete website, and all posted and associated content indicates your acceptance of BioOne's Terms of Use, available at [www.bioone.org/terms-of-use](https://www.bioone.org/terms-of-use).

Usage of BioOne Complete content is strictly limited to personal, educational, and non - commercial use. Commercial inquiries or rights and permissions requests should be directed to the individual publisher as copyright holder.

---

BioOne sees sustainable scholarly publishing as an inherently collaborative enterprise connecting authors, nonprofit publishers, academic institutions, research libraries, and research funders in the common goal of maximizing access to critical research.

## PATHOLOGY OF DISEASES IN WILD DESERT TORTOISES FROM CALIFORNIA

Bruce L. Homer,<sup>1,3</sup> Kristin H. Berry,<sup>2</sup> Mary B. Brown,<sup>1</sup> Georgeann Ellis,<sup>1</sup> and Elliott R. Jacobson<sup>1</sup>

<sup>1</sup> College of Veterinary Medicine, University of Florida, Gainesville, Florida 32610, USA

<sup>2</sup> United States Geological Survey, Biological Resources Division, Riverside Field Station, Riverside, California 92507, USA

<sup>3</sup> Corresponding author (e-mail: homerb@mail.vetmed.ufl.edu)

**ABSTRACT:** Twenty-four ill or dead desert tortoises (*Gopherus agassizii*) were received between March 1992 and July 1995 for necropsies from the Mojave and Colorado deserts of California (USA). Diseases observed in these animals included cutaneous dyskeratosis ( $n = 7$ ); shell necrosis ( $n = 2$ ); respiratory diseases ( $n = 7$ ); urolithiasis ( $n = 3$ ); and trauma ( $n = 5$ ). In tortoises with cutaneous dyskeratosis the horn layer of shell was disrupted by multiple crevices and fissures and, in the most severe lesions, dermal bone showed osteoclastic resorption, remodeling, and osteopenia. In tortoises with shell necrosis, multiple foci of necrotic cell debris and heterophilic inflammation within the epidermal horn layer were subtended by necrotic dermal bone colonized by bacteria and fungi. Of the seven tortoises with respiratory disease, five were diagnosed with mycoplasmosis. The diagnosis of mycoplasmosis was based on the presence of chronic proliferative rhinitis and positive serologic tests and/or isolation of *Mycoplasma* sp. Chronic fungal pneumonia was diagnosed in one tortoise with respiratory disease. In the three tortoises with urolithiasis, two were discovered dead, and the live tortoise had renal and articular gout. Traumatic injuries consisted of one tortoise entombed within its burrow, one tortoise burned in a brush fire, two tortoises struck by moving vehicles, and one tortoise attacked by a predator. While the primary cause of illness could be attributed to one or two major disease processes, lesions were often found in multiple organ systems, and a variety of etiologies were responsible for morbidity and mortality.

**Key words:** Desert tortoise, diseases, *Gopherus agassizii*, pathology, survey.

### INTRODUCTION

Desert tortoises (*Gopherus agassizii*) inhabit the Mojave, Colorado, and Sonoran deserts of the southwestern United States. During the last 20 yr, it appears that some populations of desert tortoises have had significant declines (U.S. Fish and Wildlife Service, 1994). Depending on the location and region, the causes of population declines have been multifactorial and may be the result of an accumulation of factors over a long period of time. Since the free-ranging female desert tortoise requires 12 to 20 yr to reach reproductive age (Woodbury and Hardy, 1948) and produces small numbers of eggs (average = 4) in each clutch (Turner et al., 1986), recovery of severely affected populations could require centuries (U.S. Fish and Wildlife Service, 1994). On 2 April 1990, the U.S. Fish and Wildlife Service listed desert tortoise populations north and west of the Colorado River as threatened under the Endangered

Species Act of 1973, as amended (Department of the Interior, 1990).

Disease has been one factor associated with recent declining numbers of desert tortoises (Jacobson, 1994). Cutaneous dyskeratosis, a shell disease, has been associated with high mortality in a protected population of desert tortoises at the Chuckwalla Bench Area of Critical Environmental Concern (Riverside County, California, USA) (Jacobson et al., 1994) and has been observed in tortoise populations elsewhere within their geographic range (Berry, 1997). The percentage of tortoises in the Chuckwalla Bench with the shell lesion increased from 1979 to 1990: from 68 to 97% in adults, and from 41 to 78% in immature tortoises (Jacobson et al., 1994). The lesion has been characterized as a loss of normal integrity of the cornified layer of the affected scutes. The cause of mortality was not determined in past studies as only shell biopsy specimens were collected from affected animals.

In 1988 desert tortoises with upper respiratory tract disease (URTD) were seen in the Desert Tortoise Natural Area (Kern County, California, USA) (Jacobson et al., 1991). Jacobson et al. (1991) found consistent chronic inflammatory lesions in the nasal cavity of free-ranging desert tortoises with URTD and, using electron microscopy, identified *Mycoplasma* sp. on the surface of nasal mucosal epithelium. Subsequently, *Mycoplasma agassizii* was demonstrated to be the causative agent (Brown et al., 1994) and an enzyme-linked immunosorbent assay (ELISA) test was developed for the detection of *M. agassizii*-specific antibodies (Schumacher et al., 1993). Free-ranging desert tortoises with signs of URTD or serological evidence of mycoplasmal infection have been found in other areas of the southwestern United States (Jacobson et al., 1995; Berry, 1997). Other potentially pathogenic bacteria isolated from nasal cavities and choanae of tortoises with URTD and healthy tortoises have included *Pasteurella testudinis*, *Aeromonas hydrophila*, *Klebsiella oxytoca*, and *Pseudomonas* sp. (Jacobson et al., 1991; Snipes et al., 1995).

Very little is known about other diseases of wild desert tortoises. Necropsy of ill, dying, and recently dead desert tortoises is a key approach in determining the causes of disease and mortality in different populations of these animals. In this study, we determined causes of illness or death in wild desert tortoises from all parts of their geographic range in California (USA) by gross and microscopic examination of tissues and by serologic, microbiologic, hematologic and toxicologic evaluations (Homer et al., 1994, 1996). In this paper, we describe the types of pathologic changes associated with a variety of diseases resulting in illness or death.

#### MATERIALS AND METHODS

Twenty-four tortoises from or near study sites throughout the Mojave desert and portions of the eastern and northern Colorado desert of California were examined from March 1992 through July 1995 (Table 1). Five tortoises

were found moribund or dead and 19 ill tortoises were collected alive. Live tortoises were obtained when they showed signs of lethargy, weakness, inanition, weight loss, ocular and nasal discharges, swollen eyelids, or shell lesions. They were collected also following trauma by moving vehicles, fire, predation, or being entombed. Tortoises were shipped via air freight (live tortoises) or Federal Express (dead tortoises) to the University of Florida (Gainesville, Florida, USA). Dead tortoises were shipped on ice.

Blood was collected from a carotic artery, placed into tubes containing lithium heparin, centrifuged to collect plasma and stored at  $-20^{\circ}\text{C}$ . A portion of plasma was submitted for an ELISA test to detect the presence of *M. agassizii*-specific antibodies, as described previously (Schumacher et al., 1993). After collection of blood, tortoises were euthanized with intravenous pentobarbital and a necropsy was conducted. Organs were removed *in bloc*, and the head was sectioned longitudinally on the midline for examination of the nasal cavity. Tissue sections (approximately 0.5 cm wide) from all major organ systems were fixed in 10% neutral buffered formalin for 24 to 48 hr, embedded in paraffin, sectioned at 5 to 6  $\mu\text{m}$ , and stained with hematoxylin and eosin and as necessary, with a variety of stains for bacteria, fungi and mucin (Luna, 1968).

Swab specimens of the choanae and colon of each tortoise were collected for aerobic bacterial isolation. Specimens were inoculated onto a Columbia agar with 5% sheep blood, Columbia CNA agar with 5% sheep blood, and MacConkey agar (all from Remel, Lenexa, Kansas, USA) and incubated for 48 hr at 37 C with 5%  $\text{CO}_2$ . To aid in the recovery of *Salmonella* sp., each colon swab also was inoculated into a Selenite broth (Remel) which was incubated at 37 C for 24 hr. The broth was then subcultured to a Hektoen enteric agar (Remel) and the plate was incubated at 37 C for 24 hr. Isolates were identified utilizing standard biochemical tests and the API 20E and NFT systems (BioMerieux Vitek, Inc., Hazelwood, Missouri). Swabs of nasal and choanal cavities were obtained for isolation of *Mycoplasma* sp. as described previously (Brown et al., 1994). Choanal swabs were obtained prior to opening the head. For nasal swabs, after the head was cut longitudinally, the nasal septum was excised and the interior sinus cavity was swabbed.

Liver weights were divided by the whole body weight to determine the percent body weight of liver for each tortoise in the study except tortoises 24 and 30. The percentages were arcsine-transformed (Sokal and Rohlf, 1995), and the differences in the percentages

TABLE 1. Location, sex, midline carapace length (MCL), weight, condition when found, and major diseases and/or lesions of 24 desert tortoises collected or salvaged between March 1992 and July 1995 for necropsies from the Mojave and Colorado Deserts of California (USA).

ID	Location	Sex	MCL (mm)	Weight (kg)	Condition	Primary diseases/lesions
1	(34°51'N, 115°09'W), San Bernardino County	F	202	1.46	Moribund—attacked by a predator	Predation and acute bacterial pneumonia
3	(33°32'N, 115°28'W), Riverside County	M	208	1.77	Alive—shell lesions	Cutaneous dyskeratosis
4	(34°25'N, 114°40'W), San Bernardino County	F	188	1.52	Alive—shell lesions	Shell necrosis (mixed bacterial and fungal etiology)
5	(34°07'N, 116°16'W), San Bernardino County	F	255	2.23	Alive—nasal and ocular discharge	Fungal pneumonia; ulcerative enteritis
6	(34°57'N, 117°26'W), San Bernardino County	F	191	1.15	Alive—entombed and lethargic	Cutaneous fungal infection; multicentric visceral inflammation
8	(33°32'N, 115°30'W), Riverside County	M	126	0.47	Alive—shell lesions	Cutaneous dyskeratosis
9	(33°32'N, 115°29'W), Riverside County	M	284	4.03	Alive—shell lesions	Cutaneous dyskeratosis
10	(33°32'N, 115°30'W), Riverside County	F	227	1.90	Alive—shell lesions	Cutaneous dyskeratosis Fungal dermatitis
11	(33°32'N, 115°29'W), Riverside County	M	193	1.30	Alive—shell lesions	Cutaneous dyskeratosis
12	(35°02'N, 115°12'W), San Bernardino County	M	286	4.25	Alive—burn injury, weak and lethargic	Burn injury; intestinal necrosis; multicentric visceral inflammation
13	(34°06'N, 116°09'W), San Bernardino County	F	230	1.45	Alive—weak, lethargic and weight loss	Mycoplasmosis
15	(34°59'N, 117°30'W), San Bernardino County	F	176	0.74	Moribund—multiple shell fractures	Blunt trauma; acute pneumonia
17	(34°36'N, 116°41'W), San Bernardino County	F	230	2.5	Alive—shell lesions	Shell necrosis (mixed bacterial and fungal etiology)
18	(34°07'N, 116°16'W), San Bernardino County	F	240	1.89	Alive—emaciated	Mycoplasmosis
19	(34°50'N, 117°04'W), San Bernardino County	F	252	2.3	Alive—nasal discharge	Mycoplasmosis
20	(34°59'N, 116°59'W), San Bernardino County	M	222	1.78	Alive—nasal discharge, weak, and emaciated	Mycoplasmosis
23	(35°06'N, 116°29'W), San Bernardino County	M	265	1.68	Alive—weak, lethargic and weight loss	Urolithiasis; renal and articular gout

TABLE 1. Continued.

ID	Location	Sex	MCL (mm)	Weight (kg)	Condition	Primary diseases/lesions
24	(35°22'N, 115°21'W), San Bernardino County	M	285	2.70	Dead	Urolithiasis
27	(34°50'N, 114°59'W), San Bernardino County	M	178	0.90	Moribund—multiple shell fractures	Blunt trauma
28	(34°40'N, 114°54'W), San Bernardino County	F	215	1.65	Alive—shell lesions	Cutaneous dyskeratosis; septicemia
29	(33°48'N, 115°46'W), Riverside County	F	245	3.17	Alive—nasal discharge and swollen eyelids	Mycoplasmosis
30	(35°13'N, 117°50'W), Kern County	M	260	pa	Dead	Urolithiasis
31	(35°21'N, 117°40'W), Kern County	M	271	3.73	Alive—nasal discharge, swollen eyelids and chin glands	Inflammation of chin glands, nasal cavity, eyelids, and salivary glands
32	(35°21'N, 117°40'W), Kern County	F	210	1.75	Alive—shell lesions and flaking of skin	Cutaneous dyskeratosis; multifocal necrotizing epidermitis with intralesional fungi

<sup>a</sup> Autolysis precluded accurate weight measurement.




FIGURE 1. Cutaneous dyskeratosis of plastron from a desert tortoise in California (tortoise 10). Flaking and peeling extends from the seams into the scutes (arrows). Bar = 4.5 cm.

between tortoises with chronic respiratory diseases or urolithiasis and the remaining tortoises were compared using a *t*-test. Analyses were performed using SAS 6.12 (SAS Institute, Inc., 1988).

### RESULTS

Desert tortoises ranged in size from 0.47 to 4.03 kg with a midline carapace length of 126 to 285 mm. Twenty-three tortoises were adults and one was a juvenile; 13 were females and 11 were males. Major diseases and/or lesions are listed in Table 1.

Seven tortoises (3, 8–11, 28 and 32) exhibited lesions consistent with cutaneous dyskeratosis. Gross shell lesions included white discoloration, flaking and peeling of the scutes, with irregular foci of pitting and chipping in the plastron and carapace.




FIGURE 2. Photomicrograph of normal shell from a desert tortoise. The epidermis is comprised of uniform multilayered horn material (H), subtended by stratified cuboidal epithelium (arrows). The dermis is comprised of a collagenous layer (C) subtended by dermal bone (B). H&E. Bar = 55  $\mu$ m.

Lesions were found most consistently in the plastron, usually on the midline, extending from the seams into the scutes (Fig. 1). Shell adjacent to these seams often had markedly accentuated ridges. In some areas, the white discolored scute could be peeled off in layers and was subtended by a thin layer of more normal appearing scute. Lesions in the carapace often encircled the scute just at the edges of the seams. The deepest scute defects exposed underlying bone, which was thin on cross-sectioning. Compared to normal shell (Fig. 2), areas with dyskeratosis were characterized microscopically by crevices, clefts and thinning of the epidermal horn layer (Fig. 3). In affected areas, the horn material changed abruptly from very compact pale staining substance to more eosinophilic fibrillar or fragmented substance (Fig. 3). Soil, plant debris, necrotic cellular debris and rare gram positive cocci were present in some lesions, and the epidermal epithelium was occasionally atrophic or hyperplastic. The external layer of the dermal bone was often irregular and com-

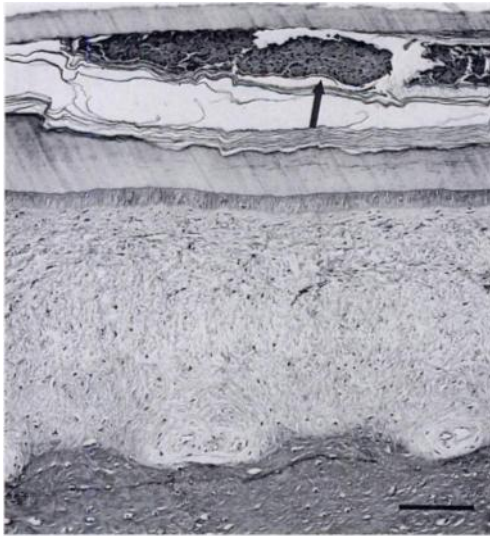


FIGURE 3. Photomicrograph of shell from tortoise with cutaneous dyskeratosis (tortoise 28). The horn material contains a cleft with fibrillar keratin and necrotic cellular debris (arrow). H&E. Bar = 115  $\mu$ m.

prised of woven bone with prominent cement lines. The most severely affected dermal bones exhibited osteoclastic resorption, osteopenia, widened osteoid seams, and an apparent increase in the number of osteoblasts lining the trabeculae. In one tortoise with osteopenia (28), mild to moderate dermal perivascular infiltrates of lymphocytes, macrophages and heterophils extended into the interosseous seams. In tortoise 10, the shell dermis was focally infiltrated by lymphocytes and the overlying horn layer was colonized by fungal hyphae. In tortoise 32, sections of skin contained intracorneal aggregates of necrotic heterophils with fungal hyphae and multifocal mild perivascular dermal infiltrates of lymphocytes.

In the two tortoises (4 and 17) with shell necrosis, several scutes had detached, revealing discolored dermal bone. In tortoise 4, the anterior scutes on the carapace and plastron had detached along the seams and the underlying bone was discolored white. On cut surface, the white dermal bone was subtended by more normal appearing light grey to cream/tan bone. In tortoise 17,

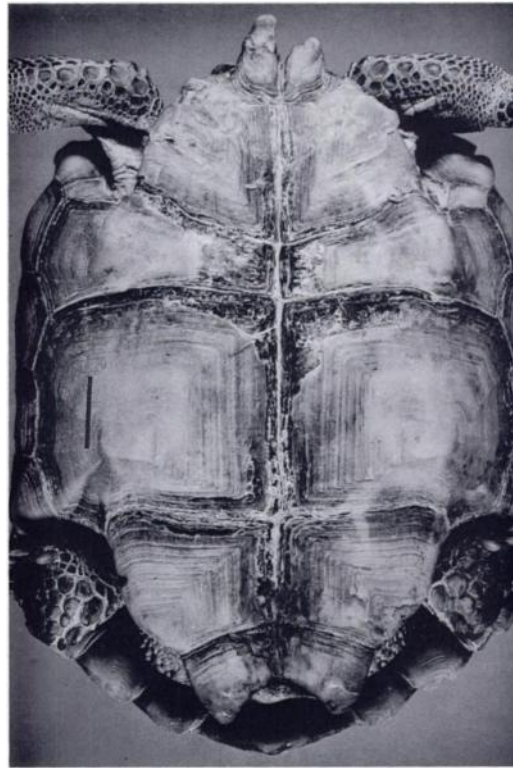


FIGURE 4. Shell necrosis of plastron (tortoise 17). Scute material has sloughed off the midline, exposing necrotic scute and dermal bone. The gular processes are irregular. Bar = 3 cm.

scute material along the midline of the plastron was fragmented and peeling off (Fig. 4). The underlying scute material and exposed dermal bone were white to black, lusterless and had a powdery surface. Microscopically, the affected shell was characterized by discrete areas of epidermal, dermal and osseous necrosis (Fig. 5), often subtended by regenerative layers of epidermis and dermal bone that were continuous with epidermis and bone adjacent to the affected segment. Abundant necrotic cells were present within the horn material, on the surface of exposed necrotic bone and between foci of sloughing scute and underlying regenerative scute. Necrotic dermis and bone were colonized by a mixed population of gram positive and negative bacteria (Fig. 5) and aseptate, occasionally branching, 6 to 10  $\mu$ m wide fungal hyphae. In areas of shell regeneration,

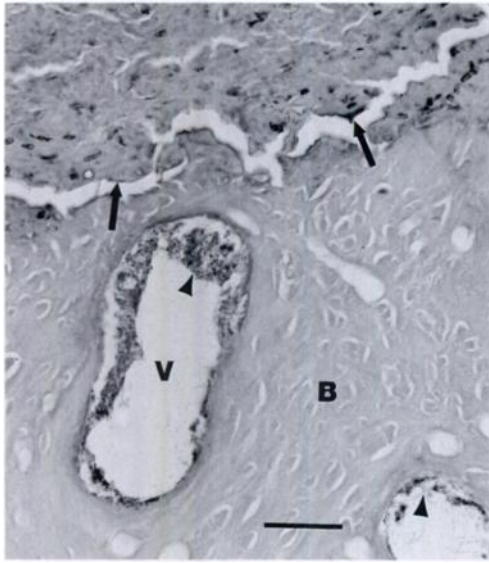


FIGURE 5. Photomicrograph of necrotic dermal bone (B) covered by necrotic cellular debris (arrows) in tortoise 4. Vascular channels (V) are colonized by bacteria (arrowhead). H&E. Bar = 28  $\mu$ m.

the epidermal epithelium was multifocally hyperplastic, and the dermis was thickened by fibrous tissue and moderate mixed infiltrates of heterophils, lymphocytes, and macrophages.

Tortoises with mycoplasmosis (13, 18, 19, 20 and 29) had a clear watery, frothy or mucoid nasal discharge, the conjunctivae and eyelids were wet and swollen, and the globes were sunken in the orbit. Microscopically, the nasal cavity was characterized by proliferation, metaplasia and disorganization of respiratory and olfactory mucosal epithelium, associated with replacement of columnar mucous and ciliated epithelium by nonciliated polygonal cells, and compact cellular infiltrates of lymphocytes, plasma cells, macrophages and heterophils. Leukocytes extended into and encompassed mucous glands, resulting in disruption of the architecture (Fig. 6). The epithelium of some glands had undergone squamous metaplasia and hyperkeratosis, and debris accumulated in the glandular lumina. Low numbers of heterophils and focal accumulations of lymphocytes infiltrated edematous dermis and

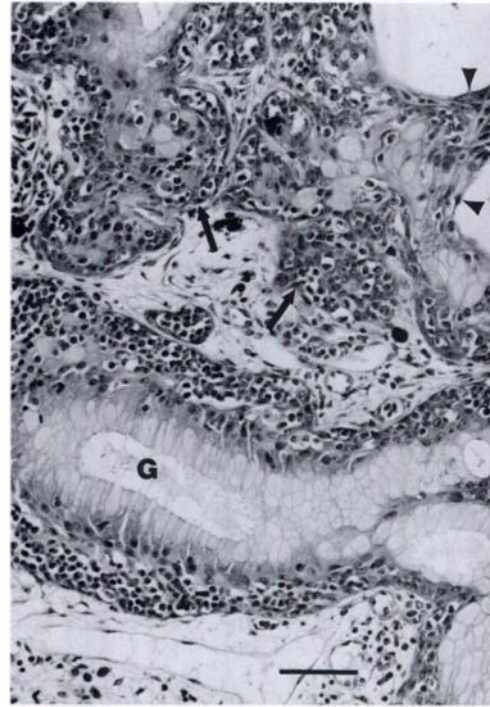


FIGURE 6. Photomicrograph of nasal glands (G) of tortoise 18 with mycoplasmosis. Glands are disrupted by mixed leukocytic infiltrates (arrows). In two dilated glands, mucous epithelium is replaced by squamous cells (arrowheads). H&E. Bar = 55  $\mu$ m.

conjunctivae of the eyelids of some tortoises.

Two tortoises with clinical signs of respiratory disease as described above did not have mycoplasmosis. The lungs of tortoise 5 were slightly reddened and multifocally firmer than normal. Areas of pulmonary inflammation were characterized by proliferation and hypertrophy of epithelium (Fig. 7); interstitial infiltrates of heterophils, lymphocytes, and macrophages; septal smooth muscle hypertrophy; and scattered 3 to 6  $\mu$ m wide, elongate, occasionally septate and branching fungal hyphae. A 1.0 cm irregular cavity in the mid left lung was filled with light tan caseous material composed of fibrin, cellular debris, necrotic leukocytes, numerous fungal hyphae and a population of 3 to 6  $\mu$ m wide ovoid yeasts. Tortoise 31 had a green inspissated mucoid nasal discharge and swollen eyelids. The left chin gland



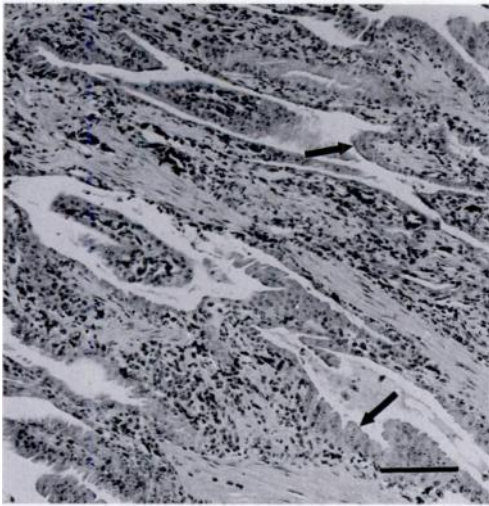


FIGURE 7. Photomicrograph of lung with proliferative pneumonia (tortoise 5). Epithelium lining air spaces is hyperplastic and hypertrophied (arrows). The hypercellular interstitium is infiltrated by a mixed population of leukocytes. H&E. Bar = 115  $\mu$ m.

was enlarged and exuded a small amount of grey fluid. The nasal cavity mucosa was infiltrated by heterophils. Both eyelids were edematous, with a mild infiltrate of heterophils. The chin gland contained perivascular infiltrates of lymphocytes and heterophils.

The urinary bladder of two tortoises (23 and 24) and the coelomic cavity of a severely autolyzed tortoise (30) for which only the shell remained, contained irregularly oval to round hard grey laminated uroliths (Fig. 8), measuring  $3.3 \times 3.3 \times 3.0$  to  $5.6 \times 4.4 \times 3.8$  cm and weighing 25 to 84 g. The bladder propria-submucosa was infiltrated focally by heterophils, and mucosal epithelium was hyperplastic and hypertrophied, with expansion of the apical cytoplasm by pale basophilic material that stained for mucin. In the live tortoise (23), the scapulohumeral joints and coxofemoral joints contained white thick chalky fluid (urate crystals). Multiple foci of renal tubular epithelial degeneration and necrosis were associated with tubular dilatation and intratubular and interstitial accumulation of urate crystals (Fig. 9). Nu-

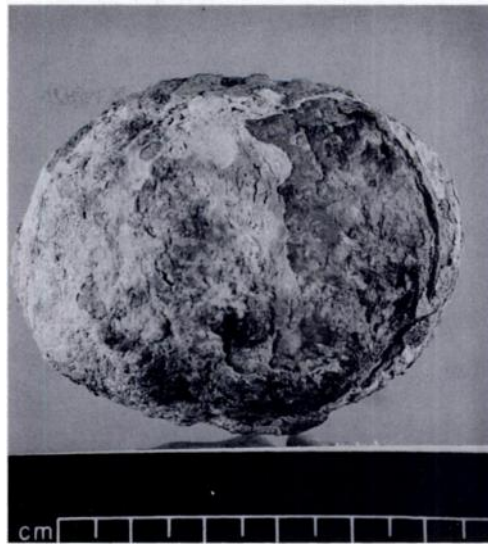


FIGURE 8. Urolith recovered from the coelomic cavity of tortoise 30.

clei of intact tubular epithelium were variably sized (anisokaryosis). Biochemical analysis of blood collected at four 3-mo intervals prior to death of tortoises 24 and 30 revealed a progressive elevation of blood urea nitrogen (25 to 306 mg/dl) in

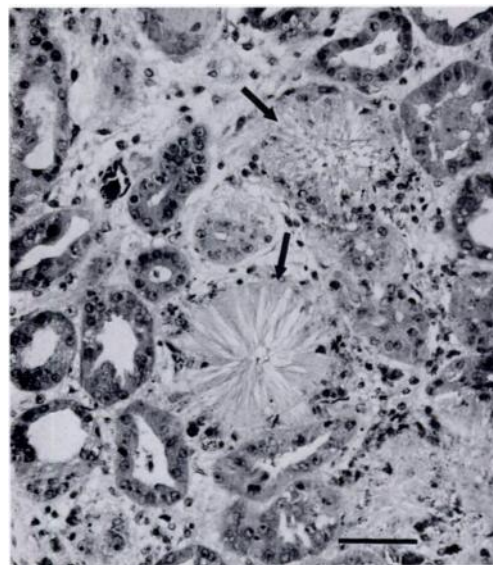


FIGURE 9. Photomicrograph of renal gout (tortoise 23). Several renal tubules are disrupted by radially arranged urate deposits (arrows). Epithelium of affected tubules is necrotic or sloughed. H&E. Bar = 56  $\mu$ m.

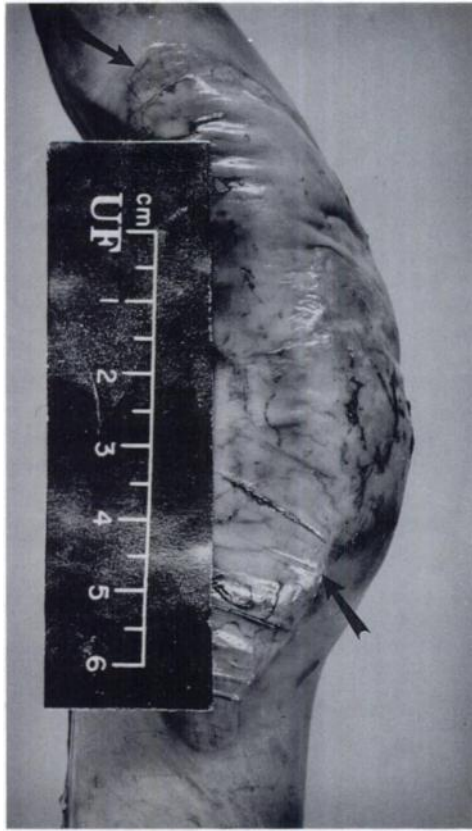

FIGURE 10. Large intestine of tortoise with burn injury (tortoise 12). Discrete area of necrosis is well demarcated from adjacent unaffected intestine (arrows).

both tortoises, and elevations of uric acid (5.6 to 12.9 mg/dl) in tortoise 24.

The interior of the burrow of tortoise 6 had collapsed, and the tortoise was tightly packed in dirt. The shell and skin were multifocally discolored brown/orange and were flaky. The stratum corneum of the skin contained aggregates of necrotic heterophils, the epidermis was focally necrotic and vacuolated, and the dermis was infiltrated by heterophils and scattered aggregates of lymphocytes. The horn layer of both skin and shell was colonized variably by 7 to 10  $\mu\text{m}$  wide, occasionally branching fragmented fungal hyphae.

Tortoise 12 was collected following a brush fire. Black burn marks and foci of melted shell were present around the edges of the shell and the skin over the head,

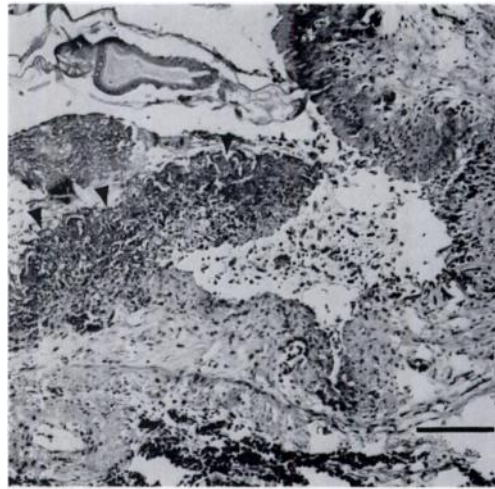


FIGURE 11. Photomicrograph of intestine from Figure 10. The mucosa is extensively ulcerated and there is a focal fibrinonecrotic exudate (arrowheads). The oxyurid-like nematode in the lumen facing the intact mucosa is considered an incidental finding. H&E. Bar = 115  $\mu\text{m}$ .

left foreleg and hind legs. Burned skin peeled easily, revealing thick creamy gray malodorous material covering blackened subcutis. The small and large intestines contained several  $3 \times 3$  to  $9 \times 4$  cm discrete transmural green/tan to dark purple, dull, friable foci encompassed by a red rim (Fig. 10). Microscopically, the small and large intestine contained multiple foci of acute mucosal to transmural necrotizing inflammation (Fig. 11).

Tortoises 15 and 27 were found moribund at the edge of a highway. The carapace and plastron were fractured through the scutes and bone along oblique lines or through the seams. The shell fractures extended into the coelomic cavity, and the intestine and liver were covered with blood and protruded through the fracture sites. The liver was multifocally lacerated and the spleen of tortoise 27 was ruptured, leaving only the stroma intact.

Tortoise 1 had chew marks associated with partial amputation of the cranium, maxilla and the dorsal neck region, ulceration of the tongue, and perforation of the trachea. A similar population of gram positive cocci, often present in pairs or small

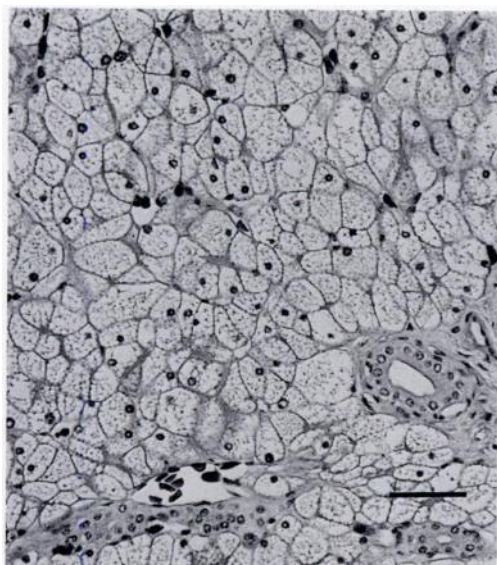


FIGURE 12. Photomicrograph of liver with vacuolar change (tortoise 8). Hepatocytes are swollen, compressing the sinusoids. Hepatocellular cytoplasm is compartmentalized by variably discrete vacuoles. H&E. Bar = 57  $\mu$ m.

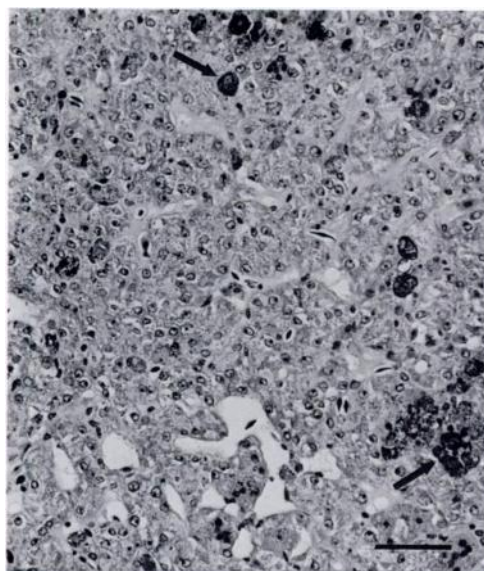


FIGURE 13. Photomicrograph of atrophic liver (tortoise 23). Variably sized (anisokaryotic) vesicular nuclei with prominent nucleoli are crowded due to loss of cytoplasm associated with atrophy. Cytoplasm is granular due to deposition of hemosiderin. There is increased deposition of melanin (arrows). H&E. Bar = 60  $\mu$ m.

chains, colonized the lung, the ulcerated area of the tongue and the lumen of the esophagus.

Liver degeneration was found in 15 tortoises. Some livers varied from small and dark brown to swollen with rounded edges, pale tan coloration and friable consistency. A few pale livers floated in formalin. However, many livers with histopathologic changes were unremarkable on gross examination. Liver lesions included hepatocellular vacuolar change (Fig. 12), atrophy (Fig. 13), increased deposition and aggregation of melanin (Fig. 13), hemosiderosis, and anisokaryosis. Liver lesions were most severe in tortoises with chronic respiratory diseases and urolithiasis (5, 13, 18, 19, 20, 23, and 29). The ratio of liver mass to body weight for these tortoises was less than that of other tortoises in the study ( $P < 0.001$ ), ranging from 0.95 to 2.2% of body weight compared to 2.1 to 6.0% for the other tortoises.

Degenerative skeletal muscle changes, found in 16 tortoises, were characterized by loss of striation, hyalinization, internal-

ized nuclei and atrophy. The most severe changes of acute degeneration and necrosis occurred in traumatized tortoises. Tissue cysts of *Sarcocystis*-like protozoa were present in skeletal muscles of six tortoises (1, 3, 4, 17, 20, 29), sometimes associated with mild infiltrates of lymphocytes and heterophils, and fibrosis.

Pancreatic acinar cells in tortoises 5, 13, 19, 20, 23, and 29 were shrunken and devoid of zymogen granules, consistent with atrophy. Lymphoid depletion of the spleen and hypertrophy and intracytoplasmic mucus accumulation of urinary bladder epithelium were other changes seen in some tortoises with chronic respiratory disease and urolithiasis; the latter lesion was associated often with evidence of dehydration (sunken globes, dry tacky subcutaneous and coelomic tissues, and weight loss). One or more tortoises with cutaneous dyskeratosis (28 and 32), shell necrosis (4), respiratory disease (5, 18 and 19), and a history of trauma (1, 6 and 12) had multicentric inflammation of multiple coelom-

ic organs including heart, lung, intestine, ovaries, kidney, adrenal, and spleen. The most common change in the bone marrow of tortoises with multicentric inflammation was hyperplasia of heterophils. However, in two tortoises with severe visceral inflammation (1 and 12), the number of heterophils was markedly reduced. Three tortoises had cactus spines embedded in the intestine and stomach (24) or tongue (3 and 27) and pharynx (27), associated with granuloma formation or acute inflammation and bacterial colonization.

Serologic examinations were conducted only for tortoises that arrived alive. Tortoises 12 and 23 had a suspect ELISA result at the 1:10 dilution. Tortoises 13, 18, 19, and 20 had seropositive results at 1:5 and 1:10 dilutions.

Potential bacterial pathogens isolated from the choanae and colon included *Citrobacter* sp., *Klebsiella oxytoca*, *Pasteurella testudinis*, *Pseudomonas* sp., and *Xanthomonas maltophilia*. *Pasteurella testudinis* was the most frequently isolated bacterium (9 of 23 tortoises), and the only organism isolated from both the choanae and colon of individual animals (5 of 9 tortoises). *Mycoplasma* sp. was isolated from the choanae and nasal cavity of two tortoises (13 and 29).

#### DISCUSSION

Pathologic changes associated with cutaneous dyskeratosis appear to have two components; one is loss of integrity in the hard keratin of the scute and the other is resorption of the underlying dermal bone. The disease appears to be associated with a defect in keratinization based on the propensity of the lesion to center over the seams. The keratinization process occurs at the seams (Jacobson et al., 1994). The role of the epithelium in the pathogenesis of cutaneous dyskeratosis is unclear; the epithelial layer was sometimes atrophied or hyperplastic, but necrosis or ulceration of epithelium was not detected. Jacobson et al. (1994) suggested that cutaneous dyskeratosis could be caused by an infectious

etiology, a toxic cause, or a nutritional deficiency. The absence of consistent shell inflammation and consistent bacterial or fungal colonization of the lesion tends to rule out an acute infectious etiology. The occasional bacteria and fungi that colonized the lesion were considered to be secondary invaders. Livers of several tortoises with cutaneous dyskeratosis had markedly swollen and vacuolated hepatocytes, and three from the Chuckwalla Bench (8, 9, and 10), where cutaneous dyskeratosis has been seen most commonly (Jacobson et al., 1994; Berry, 1997), had moderate hepatocellular anisokaryosis, suggestive of possible toxic liver disease (Kelly, 1993). There was gross and histologic evidence of dermal bone loss, although the relationship between the bone loss and the changes in the scute are not yet clear. It appears that bony changes occurred in the later stages of the disease when scute changes were most severe. The cause of decline in populations with high percentages of affected tortoises has not been determined. The anticipated end-stage of excessive scute disease and dermal bone loss would be perforation into the coelomic cavity. Although shell perforation was not detected in any of the tortoises of this study, areas of scute loss and osteopenia could have provided a portal of entry for the bacteria and fungi that colonized the scute. Most of the internal lesions were not immediately life threatening. However, the multicentric inflammation of one tortoise (28), pneumonia and fungal epidermitis of another tortoise (32), and fungal dermatitis of a third tortoise (10) would have likely resulted in the death of these three tortoises.

Features of shell necrosis not found in cutaneous dyskeratosis included sloughing of entire scutes, epidermal and bone necrosis, colonization of necrotic bone by bacterial and fungal organisms, extensive dermal inflammation, and shell repair. Bacterial and fungal cultures were not obtained from shell or skin, but *Klebsiella* sp. (tortoise 4), *Pseudomonas* sp. (tortoises 4

and 17), and *Xanthomonas maltophilia* (tortoise 17), all opportunistic pathogens associated with dermatitis (Rossi, 1996; Spencer, 1995), were isolated from the choanae. Shell repair occurred by infolding of hyperplastic epithelium from the margins of the lesion with undermining and extrusion of the necrotic portion similar to that described in other turtles with shell necrosis (Garner et al., 1997).

Most tortoises with mycoplasmosis were in moderately poor condition, as evidenced by dehydration and low body weight. All tortoises diagnosed with mycoplasmosis had nasal lesions similar to those reported by Jacobson et al. (1991, 1995). Tortoises also had inflammatory lesions in other tissues, and in some tortoises, visceral inflammation was multicentric, consistent with systemic disease. The livers of all tortoises and the pancreas of all but tortoise 18 were atrophied, consistent with chronic disease and/or malnutrition (Kelly, 1993). The species of *Mycoplasma* isolated from tortoises 13 and 29 has not yet been identified by serological or polymerase chain reaction analysis (Brown et al., 1995); it was not *M. agassizii* (Brown et al., 1994). However, the lesions in the affected tortoises were virtually identical to those described by Brown et al. (1994) in their transmission study using *M. agassizii*. Both tortoises were salvaged from Joshua Tree National Park, which is a highly frequented recreational area. Serologic testing helped to confirm the diagnosis for all affected tortoises except tortoise 29. The reason the ELISA test was positive for tortoise 13 but not 29 is not certain. Although antigens from the unnamed species of *Mycoplasma* were used to test the blood of tortoise 29, the ELISA test employed was developed for diagnosis of *M. agassizii* (Schumacher et al., 1993) and has not been standardized for detection of the other *Mycoplasma* sp. It also is possible that tortoise 29 was immunocompromised and did not have adequate antibody concentration. Suspect results in two tortoises (12 and 23) could represent

early infection, immunosuppression, an ablated response or a nonspecific reaction.

Fungi were not cultured from the lung of tortoise 5 with histologic findings of fungal pneumonia, but based on the morphology of the fungal hyphae and ovoid yeasts, there appeared to be a dual infection with *Aspergillus* sp. and *Candida* sp. (Chandler et al., 1980). Both organisms have been isolated from pulmonary lesions in chelonians (Frye, 1991a). In a review of causes of mortality and diseases in tortoises, no reports on mycotic diseases in wild tortoises were found (Jacobson, 1994). Fungi often cause infection secondary to compromise of immune function (Jacobson, 1980). In tortoise 5, there was a marked reduction in numbers of splenic lymphocytes, possibly resulting in immunosuppression. *Citrobacter* sp., isolated from the colon, has been associated with septicemic cutaneous ulcerative disease of aquatic turtles (Rossi, 1996) and could have been responsible for ulcerative enteritis found in this tortoise. In turn, the intestinal lesion may have served as a portal of entry for the fungi.

Clinical signs and lesions in tortoise 31 resembled those of mycoplasmosis; however, serologic testing and culture for *Mycoplasma* were negative. This may not rule out mycoplasmosis, since rhinitis and blepharitis were acute. Lesions of mycoplasmosis in tortoises of this and other studies (Jacobson et al., 1991, 1995) were more chronic. Failure to isolate other pathogenic bacteria from the choanae tends to rule out a bacterial etiology. Another cause of upper respiratory and ocular disease in tortoises is vitamin A deficiency (Jacobson, 1994). However, squamous epithelial metaplasia, a hallmark of hypovitaminosis A, was not detected.

Three tortoises (23, 24 and 30) had urolithiasis. Factors that predispose animals to urolithiasis include excretion of calculogenic material in the urine, urinary pH, dehydration, vitamin A deficiency and supersaturation of urine by stone-forming salts (Maxie, 1993). While uroliths may be

tolerated to some extent, they may incite an inflammatory response in the urinary bladder and they occupy space in the urinary bladder that would normally hold fluid. In addition to heterophilic inflammation of the bladder wall, mucosal epithelial cells were hyperplastic and the apical cytoplasm was expanded with mucus. We believe the epithelial changes were either a reaction to the uroliths or an indication of dehydration. The latter is supported by the presence of similar changes in other dehydrated tortoises that did not have uroliths. The renal and articular lesions in tortoise 23 were consistent with gout (Frye, 1991b). Predisposing factors for gout include dehydration, pre-existing renal disease, exposure to a nephrotoxin, or excess animal protein in the diet (Maxie, 1993). However, the exact cause in desert tortoises is unknown. Based on the severity of the renal lesion and the lack of inflammation, a preexisting renal lesion was the likely cause of gout in this tortoise. The exact cause of death of tortoises 24 and 30 could not be determined. Dehydration and enteritis, associated with cactus spine penetration, were likely contributing factors in tortoise 24. Prior to death, both tortoises had biochemical evidence (elevated BUN and uric acid) of dehydration and/or renal insufficiency (Campbell, 1996); hyperuricemia also can be associated with gout. Renal damage could not be assessed due to advanced autolysis.

Two tortoises that sustained trauma (6 and 12) had multicentric visceral inflammation. Fungal dermatitis accounted for the flakiness of the skin of tortoise 6. Although fungi can be primary cutaneous pathogens, superficial cutaneous mycotic infections in reptiles usually occur secondary to some predisposing factor such as poor sanitation, high humidity, malnutrition or overcrowding (Jacobson, 1980). Heterophilic hyperplasia in the bone marrow was a response to the multicentric inflammation (Garner et al., 1996). Visceral inflammation in tortoise 12 was most severe in the intestine. The transmural in-

testinal necrosis was considered to be a post-burn complication, probably associated with impaired humoral and cell-mediated immunity (Griswold, 1993). Burn wound infection is usually caused by endogenous bacteria from the skin or gastrointestinal tract (Saxon and Kirby, 1992). *Citrobacter* sp. and *P. testudinis* were isolated from the colon, and the subcutis of the burned foreleg was colonized by bacteria. Unlike tortoise 6, bone marrow was depleted of heterophils, which was most likely the result of an overwhelming demand for heterophils in the intestine (Garner et al., 1996). Two tortoises (15 and 27) had evidence of acute blunt trauma as would occur subsequent to being struck by a moving vehicle. There was no other evidence of underlying disease in the tortoises. The cause of death of tortoise 1 was acute bacterial-induced bronchopneumonia, consistent with *Streptococcus* sp. etiology, likely occurring secondary to the head and neck lacerations.

Hepatic lesions seen in 15 tortoises were degenerative, but were otherwise nonspecific. Causes of lipidosis and hydropic degeneration overlap and include bacterial or environmental toxins, hepatocellular hypoxia, anorexia or dietary and metabolic imbalances (Kelly, 1993). Anisokaryosis represents a regenerative or toxic change, while hemosiderosis may have occurred due to inability to mobilize iron stores, as occurs in anemia of chronic disease (Smith, 1989). Iron-laden macrophages were reported to increase in livers of tortoises with URTD (Jacobson et al., 1991). The liver may undergo catabolism during starvation, resulting in atrophy (Kelly, 1993). Livers of chronically ill tortoises commonly contained increased amounts of melanin, suggesting that melanosis is a marker of chronic disease, as described in fish (Kennedy-Stoskopf, 1993). Melanin is not harmful. Conversely, melanin can neutralize free radicals and may have a bactericidal effect (Kennedy-Stoskopf, 1993).

The high frequency (16 tortoises) of

acute skeletal muscle lesions suggests that tortoises might be prone to exertional rhabdomyolysis (Bartsch et al., 1977). This lesion may have occurred when tortoises were restrained for blood collection. Muscle lesions seen in traumatized tortoises were also consistent with exertional rhabdomyolysis. Six tortoises had organisms resembling *Sarcocystis* sp. within muscle fibers, occasionally associated with mild chronic myositis. *Sarcocystis* spp. are generally not considered to be pathogens of reptiles (Barnard and Upton, 1994).

A number of chronically ill tortoises had a history of weight loss and were emaciated at the time of collection. In these tortoises, weight loss was an excellent indication of chronic disease and was often associated with muscle, pancreatic and/or hepatic atrophy. However, body weight versus carapace length cannot be used by itself to assess the health of tortoises because body weight is influenced by oviposition, time since hibernation, imbibition of water, defecation and micturition, and thickness of dermal bone (Jacobson et al., 1993). Liver as a percent of body weight may be a better indicator of chronic disease, since there was a significant difference between the percentage in tortoises with chronic respiratory diseases or systemic illness associated with urolithiasis and that of the other tortoises in this study.

This study was designed to address the types of diseases and associated pathologic changes occurring in wild desert tortoises, rather than the prevalence of disease. It was part of a larger investigation on density of desert tortoise populations. Only dead tortoises or those with obvious signs of illness were collected. Diseases may have a direct and obvious impact on mortality in populations of free-ranging desert tortoises. However, the effects of many diseases may be more subtle. Diseases may contribute to reduced growth, reduced reproductive vigor, and reduced survivorship of individuals and populations. Cutaneous dyskeratosis, for example, appears to contribute to or cause thinning

of the scutes and dermal bone, thereby rendering the tortoise more vulnerable to other diseases such as fungal infections and multicentric visceral inflammation. Diseases also may inhibit or slow growth rates of individuals by reducing appetite, resulting in malnutrition. For females, reduction in growth rates limit carapace length and size, thereby limiting numbers of eggs produced annually. For juveniles, reduction in growth rates prolong the period of vulnerability to predators and environmental stresses.

#### ACKNOWLEDGEMENTS

We thank the following agencies and individuals for providing tortoises, information and scientific support for various aspects of this study: Bureau of Land Management (BLM), Riverside, California, USA; National Biological Service (NBS), Riverside, California, USA; the National Training Center, Fort Irwin, California, USA; Joshua Tree National Park, Riverside and San Bernardino Counties, California, USA; and H. Avery, W. Boarman, R. Fortun, J. Freilich, A. Garry, C. Kameen, C. Klug, J. Howland, C. Sharpe, M. Walker, T. Esque, G. Goodlett, A. P. Woodman, S. Hart, P. Gould, E. LaRue, T. Egan, E. K. Spangenberg, D. J. Morafka, K. Nagy, M. Vaughn, S. Boland and T. Rado. Special thanks to I. Schumacher for conducting *Mycoplasma* sp. serology; D. Brown for *Mycoplasma* sp. culture analyses; E. Williams and B. Hall for necropsy and histology technical assistance; and C. Buergelt, D. Forrester and E. Greiner for review of this manuscript. The tortoises were collected under the appropriate permits and authorities of the BLM, NBS, California Department of Fish and Game, and U.S. Fish and Wildlife Service. This study was supported by the BLM and NBS through contract Nos. B950-C1-0062 and 14-16-009-1544, respectively, and the National Training Center at Fort Irwin, California. This paper is published as University of Florida, College of Veterinary Medicine Journal Series No. 513.

#### LITERATURE CITED

- BARNARD, S. M., AND S. J. UPTON (editors). 1994. A veterinary guide to the parasites of reptiles. Krieger Publishing Company, Malabar, Florida, 154 pp.
- BARTSCH, R. C., E. E. MCCONNELL, G. D. IMES, AND J. M. SCHMIDT. 1977. A review of exertional rhabdomyolysis in wild and domestic animals. *Veterinary Pathology* 14: 314-324.

- BERRY, K. H. 1997. Demographic consequences of disease in two desert tortoise populations in California, USA. *In* Proceedings: Conservation, restoration, and management of tortoises and turtles—An international conference. J. Van Abbeema (ed.). Wildlife Conservation Society Turtle Recovery Program and the New York Turtle and Tortoise Society, New York, New York, pp. 91–99.
- BROWN, D. R., B. C. CRENSHAW, G. S. MC-LAUGHLIN, I. M. SCHUMACHER, C. E. MCKENNA, P. A. KLEIN, E. R. JACOBSON, AND M. B. BROWN. 1995. Taxonomic analysis of the tortoise mycoplasmas *Mycoplasma agassizii* and *Mycoplasma testudinis* by 16S rRNA gene sequence comparison. *International Journal of Systematic Bacteriology* 45: 348–350.
- BROWN, M. B., I. M. SCHUMACHER, P. A. KLEIN, K. HARRIS, T. CORRELL, AND E. R. JACOBSON. 1994. *Mycoplasma agassizii* causes upper respiratory tract disease in the desert tortoise. *Infection and Immunity* 62: 4580–4586.
- CAMPBELL, T. W. 1996. Clinical pathology. *In* Reptile medicine and surgery, D. R. Mader (ed.). W. B. Saunders Company, Philadelphia, Pennsylvania, pp. 248–257.
- CHANDLER, F. W., W. KAPLAN, AND L. AJELLO. 1980. Color atlas and text of the histopathology of mycotic diseases. Year Book Medical Publishers, Inc., Chicago, Illinois, 333 pp.
- DEPARTMENT OF INTERIOR (U.S. FISH AND WILDLIFE SERVICE). 1990. Endangered and threatened wildlife and plants; determination of threatened status for the Mojave population of the desert tortoise. *Federal Register* 55: 12178–12191.
- FRYE, F. L. 1991a. Infectious diseases. *In* Reptile care. An atlas of diseases and treatments. F. L. Frye (ed.). T.F.H. Publications, Inc., Neptune City, New Jersey, pp. 101–160.
- . 1991b. A practical guide for feeding captive reptiles. *In* Reptile care. An atlas of diseases and treatments. F. L. Frye (ed.). T.F.H. Publications, Inc., Neptune City, New Jersey, pp. 41–100.
- GARNER, M. M., B. L. HOMER, E. R. JACOBSON, R. RASKIN, B. HALL, W. A. WEIS, AND K. H. BERRY. 1996. Staining and morphologic features of bone marrow hematopoietic cells in desert tortoises (*Gopherus agassizii*). *American Journal of Veterinary Research* 57: 1608–1615.
- , R. HERRINGTON, E. W. HOWERTH, B. L. HOMER, V. F. NETTLES, R. ISAZA, E. B. SHOTTS, AND E. R. JACOBSON. 1997. Shell disease in river cooters (*Pseudemys concinna*) and yellow-bellied turtles (*Trachemys scripta*) in a Georgia (USA) lake. *Journal of Wildlife Diseases* 33: 78–86.
- GRISWOLD, J. A. 1993. White cell response to burn injury. *Seminars in Nephrology* 13: 409–415.
- HOMER, B. L., K. H. BERRY, M. M. CHRISTOPHER, M. B. BROWN, AND E. R. JACOBSON. 1994. Necropsies of desert tortoises from the California deserts and elsewhere in the Southwest. Final report to the United States Department of the Interior, Bureau of Land Management Contract No. B950-C1-0062, Riverside, California, 85 pp.
- , ———, AND E. R. JACOBSON. 1996. Necropsies of eighteen desert tortoises from the Mojave and Colorado deserts of California. Final Report to the United States Department of the Interior, National Biological Service, Research Work Order No. 131, Riverside, California, 120 pp.
- JACOBSON, E. R. 1980. Mycotic diseases in reptiles. *In* The comparative pathology of zoo animals, R. J. Montali and G. Migaki (eds.). Smithsonian Institution Press, Washington, D.C., pp. 283–290.
- . 1994. Causes of mortality and disease in tortoises: a review. *Journal of Zoo and Wildlife Medicine* 25: 2–17.
- , M. B. BROWN, I. M. SCHUMACHER, B. R. COLLINS, R. K. HARRIS, AND P. A. KLEIN. 1995. Mycoplasmosis and the desert tortoise (*Gopherus agassizii*) in Las Vegas Valley, Nevada. *Chelonian Conservation Biology* 1: 279–284.
- , J. M. GASKIN, M. B. BROWN, R. K. HARRIS, C. H. GARDINER, J. L. LAPOINTE, H. P. ADAMS, AND C. REGGIARDO. 1991. Chronic upper respiratory tract disease of free-ranging desert tortoises (*Xerobates agassizii*). *Journal of Wildlife Diseases* 27: 296–316.
- , M. WEINSTEIN, K. BERRY, B. HARDENBROOK, C. TOMLINSON, AND D. FREITAS. 1993. Problems with using weight versus carapace length relationships to assess tortoise health. *Veterinary Record* 132: 222–223.
- , T. J. WRONSKI, J. SCHUMACHER, C. REGGIARDO, AND KRISTIN BERRY. 1994. Cutaneous dyskeratosis in free-ranging desert tortoises, *Gopherus agassizii*, in the Colorado Desert of Southern California. *Journal of Zoo and Wildlife Medicine* 25: 68–81.
- KELLY, W. R. 1993. The liver and biliary system. *In* Pathology of domestic animals, Vol. II, 4th ed. K.V.F. Jubb, P. C. Kennedy, and N. Palmer (eds.). Academic Press, New York, New York, pp. 319–406.
- KENNEDY-STOSKOPF, S. 1993. Immunology. *In* Fish medicine, M. K. Stoskopf (ed.). W. B. Saunders Company, Philadelphia, Pennsylvania, pp. 149–159.
- LUNA, L. G. 1968. Manual of histologic staining methods of the Armed Forces Institute of Pathology. McGraw-Hill Book Company, New York, New York, 251 pp.
- MAXIE, M. G. 1993. The urinary system. *In* Pathology of domestic animals, Vol. II, 4th ed., K.V.F. Jubb, P. C. Kennedy, and N. Palmer (eds.). Academic Press, New York, New York, pp. 447–538.
- ROSSI, J. V. 1996. Dermatology. *In* Reptile medicine



- and surgery, D. R. Mader (ed.). W. B. Saunders Co., Philadelphia, Pennsylvania, pp. 104–117.
- SAS INSTITUTE INC. 1988. SAS/STAT User's Guide. SAS Institute, Inc., Cary, North Carolina, 1028 pp.
- SAXON, W. D., AND R. KIRBY. 1992. Treatment of acute burn injury and smoke inhalation. In Current Veterinary Therapy XI. Small Animal Practice, R. W. Kirk and J. D. Bonagura (eds.). W. B. Saunders Company, Philadelphia, Pennsylvania, pp. 146–153.
- SCHUMACHER, I. M., M. B. BROWN, E. R. JACOBSON, B. R. COLLINS, AND P. A. KLEIN. 1993. Detection of antibodies to a pathogenic *Mycoplasma* in desert tortoises (*Gopherus agassizii*) with upper respiratory tract disease. *Journal of Clinical Microbiology* 31: 1454–1460.
- SMITH, J. E. 1989. Iron Metabolism and its diseases. In *Clinical biochemistry of domestic animals*, Kaneko (ed.). Academic Press, San Diego, California, pp. 256–273.
- SNIPES, K. P., R. W. KASTON, J. M. CALAGOAN, AND J. T. BOOTHBY. 1995. Molecular characterization of *Pasteurella testudinis* isolated from desert tortoises (*Gopherus agassizii*) with and without upper respiratory tract disease. *Journal of Wildlife Diseases* 31: 22–29.
- SOKAL R., AND F. J. ROHLF. 1995. Biometry. The principles and practice of statistics in biological research. 3rd ed. W. H. Freeman and Company, New York, New York, 887 pp.
- SPENCER, R. C. 1995. The emergence of multiple-antibiotic-resistant *Stenotrophomonas* (*Xanthomonas maltophilia*) and *Burkholderia* (*Pseudomonas cepacia*). *Journal of Hospital Infection* 30(suppl.): 453–464.
- TURNER, F. B., P. HAYDEN, B. L. BURGE, AND J. B. ROBERSON. 1986. Egg production by the desert tortoise (*Gopherus agassizii*) in California. *Herpetologica* 42: 93–104.
- U.S. FISH AND WILDLIFE SERVICE. 1994. Desert Tortoise (Mojave Population) Recovery Plan. U.S. Fish and Wildlife Service, Portland, Oregon, 73 pp.
- WOODBURY, A. M., AND R. HARDY. 1948. Studies of the desert tortoise, *Gopherus agassizii*. *Ecological Monographs* 18: 145–200.

*Received for publication 3 June 1997.*