

SARCOCYSTIS MUCOSA IN BENNETTS WALLABIES AND PADEMELONS FROM TASMANIA

Author: Jakes, Kathryn A.

Source: Journal of Wildlife Diseases, 34(3) : 594-599

Published By: Wildlife Disease Association

URL: <https://doi.org/10.7589/0090-3558-34.3.594>

BioOne Complete (complete.BioOne.org) is a full-text database of 200 subscribed and open-access titles in the biological, ecological, and environmental sciences published by nonprofit societies, associations, museums, institutions, and presses.

Your use of this PDF, the BioOne Complete website, and all posted and associated content indicates your acceptance of BioOne's Terms of Use, available at www.bioone.org/terms-of-use.

Usage of BioOne Complete content is strictly limited to personal, educational, and non - commercial use. Commercial inquiries or rights and permissions requests should be directed to the individual publisher as copyright holder.

BioOne sees sustainable scholarly publishing as an inherently collaborative enterprise connecting authors, nonprofit publishers, academic institutions, research libraries, and research funders in the common goal of maximizing access to critical research.

SARCOCYSTIS MUCOSA IN BENNETTS WALLABIES AND PADEMELONS FROM TASMANIA

Kathryn A. Jakes^{1,2}

¹ Department of Biomedical Science, University of Tasmania, Launceston, Australia

² Present address: Department of Parasitology, University of Queensland, St. Lucia, Queensland 4067, Australia

ABSTRACT: Macroscopic gastrointestinal sarcocysts were detected in 36 of 270 (13%) Tasmanian pademelons (*Thylogale billardierii*) and 47 of 292 (16%) Bennetts wallabies (*Macropus rufogriseus*) from January 1995 to March 1996 at onshore and offshore study sites in Tasmania (Australia). The sarcocysts were characterized using light and electron microscopy. The ultrastructure of the primary cyst wall was consistent with that of *Sarcocystis mucosa*, an apicomplexan parasite commonly found in macropodid marsupials. Although conventional statistical tests were not applied to data, there were apparent differences in the prevalence of infection in macropodid marsupials inhabiting onshore (19%) versus offshore (0%) sites. These differences were attributed to the presence or absence of medium-sized dasyurid marsupials. The results of this study provide strong circumstantial evidence that these dasyurid marsupials are the probable definitive hosts for *S. mucosa* in free-ranging Tasmanian macropodids.

Key words: Bennetts wallaby, *Dasyurus* spp., macropodid marsupial, *Macropus rufogriseus*, Tasmanian pademelon, sarcocyst, *Sarcocystis mucosa*, *Thylogale billardierii*.

INTRODUCTION

Although sarcocystosis is a significant disease of domestic animals in Australia (Cawthorn and Speer, 1989), there are few published reports relating to prevalence or geographic distribution of *Sarcocystis* spp. within free-ranging wild animal populations. Sarcocysts have been reported in a wide range of bird, reptile, and mammal species in Australia (Munday et al., 1978, 1979). Macroscopic sarcocysts detected in the gastrointestinal tract of macropodid marsupials were classified on the basis of their morphology and ultrastructural characteristics as *S. mucosa* (O'Donoghue et al., 1987).

The objectives of the study reported here were to isolate and identify *S. mucosa* from two species of indigenous Tasmanian macropodid marsupials (*Macropus rufogriseus* and *Thylogale billardierii*) by conventional morphological methods, to evaluate the prevalence of infection, and to propose the most likely definitive hosts for *S. mucosa* in Tasmania.

MATERIALS AND METHODS

Tasmania is an island state located approximately 240 km off the southeast corner of mainland Australia. Six locations around the state were selected for the study. Three of

these were located on the main island of Tasmania: Launceston (147°05'E, 41°28'S), Westbury (146°50'E, 41°33'S), and Fingal (147°58'E, 41°39'S). The remaining three were offshore sites: Flinders Island (148°00'E, 40°05'S), Clarke Island (148°10'E, 40°30'S), and Maria Island (148°05'E, 42°35'S).

Two hundred and seventy Tasmanian pademelons (*Thylogale billardierii*) and 292 Bennetts wallabies (*Macropus rufogriseus*) were collected from study sites from January 1995 to March 1996 (Tasmanian Parks and Wildlife permit no. FA 95143, Hobart, Tasmania). These animals were culled ($n = 125$), or used for meat production ($n = 437$). An additional 61 Bennetts wallabies and 56 pademelons were collected as road-killed specimens from onshore sites.

Study sites were selected on the basis of species composition at each location. Feral and domestic dogs and cats were abundant at five of the study sites, although both of these were less abundant at Maria Island due to sporadic control programs conducted by National Parks. Macropodid marsupials taken from Clarke Island comprised only pademelons; Bennetts wallabies do not occur at this location. Birds of prey (eagles, falcons, hawks and harriers), and forest ravens (*Corvus tasmanicus*) were common at all six sites. Native carnivorous marsupials, namely Tasmanian devils (*Sarcophilus harrisii*) and eastern or tiger quolls (*Dasyurus viverrinus* and *D. maculatus*, respectively) were restricted to the Tasmanian mainland.

Tissue samples (masseter, tongue, hind- and forelimb, esophagus, heart, diaphragm and co-

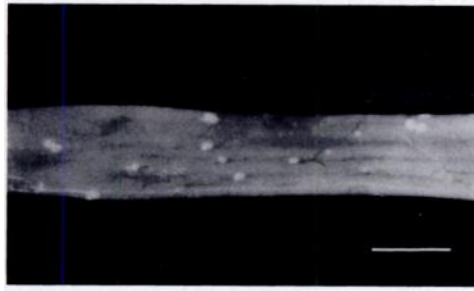


FIGURE 1. Macroscopic sarcocysts in gastrointestinal wall of Bennett's wallaby. Bar = 10 mm.

lon) were collected at necropsy and processed for light microscopy (LM). Tissues were fixed in 10% phosphate-buffered formalin (pH 7.2) for a minimum of 48 hr, dehydrated through a series of graded ethanol solutions, embedded in paraffin, and 5 to 6 μm sections were stained with Gill's haematoxylin and eosin (Stevens, 1982). Sarcocyst dimensions were measured using a stereo microscope (Kyowa SD, HD Scientific, Melbourne, Australia).

For transmission electron microscopy (TEM), five cysts (three from Bennett's wallabies and two from pademelons) were fixed in 3% glutaraldehyde (prepared in cacodylate buffer, pH 7.4, 24 hr at 4 C), post-fixed in 2% w/v osmium tetroxide, pre-stained en bloc in 2% uranyl acetate and embedded in Epon 812[®] resin (Probing and Structure, Thuringowa, Central Queensland, Australia). Semi-thin (0.5 μm) sections were cut on an LKB 0M4 Ultramicrotome (Linbrook International, Sydney, Australia) and mounted directly onto 200 mesh copper grids. The sections were stained with aqueous uranyl acetate and lead citrate (Reynolds, 1963) and examined with a Hitachi H-300 electron microscope at 75kV (Meeco, Sydney, Australia).

Twenty nine dasyurid marsupials (18 Tasmanian devils, six eastern and five tiger quolls) were collected as road-kills from onshore sites. Gastrointestinal tracts were removed to allow for gross inspection of contents, and wet-mount preparations from tissue scrapings of duodenum, ileum and colon were examined for sporocysts of *Sarcocystis* spp. using phase contrast microscopy (Olympus CH2, Selby Scientific, Melbourne, Australia). Gastrointestinal tissues also were prepared for light microscopy as described for samples collected at necropsy.

RESULTS

Macroscopically, the spherical to ovoid, nodular sarcocysts of ≤ 1.5 mm in diameter were recognizable by their white ap-

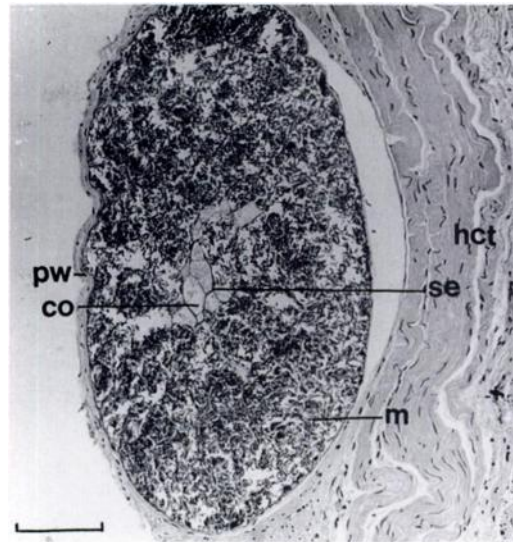


FIGURE 2. Photomicrograph of sarcocyst of *Sarcocystis mucosa* in gastrointestinal tissue of a macropod. The cyst, separated from host connective tissues (hct) by a thick primary wall (pw), was divided into compartments (co) by septa (se). Peripheral compartments contained large numbers of merozoites (m). H&E. Bar = 0.3 mm.

pearance in contrast to normal gastrointestinal tissue (Fig. 1). Sarcocysts, arranged in clusters or individually were, without exception, located in the large intestine and rectum of infected animals.

Conventional microscopy (LM and TEM) confirmed that sarcocysts removed from wallabies were morphologically and ultrastructurally identical to those taken from pademelons. Cysts were partitioned from host tissues by a thick wall, with no evidence to suggest the presence of a secondary cyst wall. Septa separated the sarcocysts into compartments containing closely packed zoites which measured 2 μm in width by 8.5 μm in length ($n = 25$). The most centrally located cyst compartments appeared to be empty or fluid-filled (Fig. 2), although the presence of fluid was not substantiated due to the nature of the histological processing. The primary cyst wall was interspersed with numerous invaginations and short protrusions containing fibril bundles aligned at right angles to the wall (Fig. 3). According to the classi-

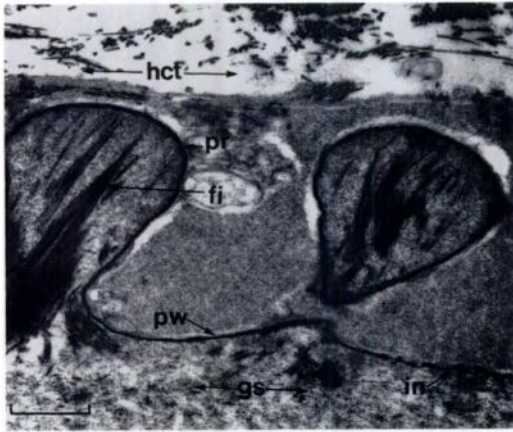


FIGURE 3. Transmission electron micrograph of cyst primary wall (pw) of *Sarcocystis mucosa*. The wall was regularly interspersed with invaginations (in) and short protrusions (pr). The protrusions contained bundles of fibrils (fi) aligned at right angles to the primary wall. Host connective tissues (hct) and ground substance (gs) also were visible. Bar = 0.5 μ m.

fication system of Dubey et al. (1989), the ultrastructure of the primary cyst wall corresponded to a type 13, commonly found in wallabies, and described by O'Donoghue et al. (1987) as *S. mucosa*. Host connective tissue consisted predominantly of fibroblasts. Ground substance was present on both sides of the primary wall. No sporocysts were seen in either the freshly prepared slides, or in serial paraffin sections of tissue prepared from any of the 29 dasyurid marsupials.

Macroscopic sarcocysts were detected in 47 of 232 (20%) Bennetts wallabies, and 36 of 205 (18%) pademelons taken from onshore sites, an average prevalence of 19%. No infections were detected in 125 macropodids (60 Bennetts, 65 pademelons) obtained from offshore island sites. Amongst the road-killed macropodid group, 9 of 61 (15%) Bennetts wallabies and 6 of 56 (11%) pademelons were infected with *S. mucosa*, an average prevalence of 13%.

DISCUSSION

The difference in prevalence of *S. mucosa* was not analysed statistically because

the methods of animal collection used during the study were opportunistic rather than systematic. However, the general trends for the prevalence of *S. mucosa* in macropodids from Tasmania were assessed. Overall, there was a prevalence of 19% in animals from onshore sites, and 0% in those from offshore sites. This indicates that definitive hosts for *S. mucosa* are confined to onshore sites. The prevalence of infection in the road-kill group was slightly lower than that of other onshore macropodids (13% compared to 19%) but the data from this group should be interpreted with caution. The difference in prevalence could be attributed to a variety of factors, including the drought conditions in Tasmania during 1995 and 1996 (Zillman, 1997). Drought conditions increase not only the incidence of macropodid road-kills, but also the number of male animals killed compared to females (Coulson, 1997). A large proportion of those killed on the road are juveniles (Coulson, 1989). Considering these circumstances, it is unlikely that data from road-killed animals are truly representative of a macropodid population in the wild.

Sporocysts of *S. mucosa* were not seen in any of the wet-mount or histological slides prepared from dasyurid marsupials, but infection of these animals with sexual stages of the parasite should not be discounted solely on this basis. It is possible that insufficient numbers of dasyurid marsupials were examined, as Munday et al. (1978) detected only one infected Tasmanian devil and one tiger quoll from 50 and 11 animals examined, respectively.

Macroscopic sarcocysts from Bennetts wallabies and Tasmanian pademelons in this study were shown to be morphologically and ultrastructurally identical, suggesting that *S. mucosa* is able to utilize either or both species of macropodid as an intermediate host. If this is the case, then the fact that no Bennetts wallabies were collected from Clarke Island becomes irrelevant. Theoretically, infection should have been maintained in the single species

macropodid, the pademelon, if suitable definitive hosts were also present at that location. The inter-species similarities between sarcocysts from the two macropodid species allowed the data to be pooled when assessing the overall prevalence of *S. mucosa*. The morphological characteristics of sarcocysts found in the present study were consistent with those described by O'Donoghue et al. (1987) from red-necked wallabies and unadorned rock wallabies (*Petrogale assimilis*) in Queensland, and from Bennetts wallabies in Tasmania.

To determine the most likely definitive host groups for *S. mucosa* in Tasmania, one must assume that the parasite has the heteroxenous life cycle common to most other members of the genus. Many of the larger carnivores, such as foxes (*Vulpes vulpes*) and dingoes (*Canis familiaris dingo*) which are widespread on mainland Australia, are absent from Tasmania (Newsome, 1983). However, domestic dogs and cats have become well-established in feral populations across Tasmania (Jones, 1983). It has been suggested that corvids (crows and ravens) and raptors are definitive host candidates for *S. mucosa* in Australia (O'Donoghue et al., 1987). Although crows are absent from Tasmania, forest ravens are widespread (Olsen et al., 1993). These birds are omnivorous, with a diet composed of approximately equal parts of carrion, insects and plant material (Blakers et al., 1984). Raptors, which feed primarily on reptiles, small mammals and carrion, are found in a range of habitats across Tasmania including the offshore islands (Thomas, 1979). There have been several documented cases of sarcocystosis and sporocyst shedding in birds, suggesting that avian species are able to act simultaneously as intermediate and definitive hosts for some species of *Sarcocystis* (Munday et al., 1979; Dubey et al., 1991).

The Tasmanian tiger (*Thylacinus cynocephalus*) is considered to be extinct (Smith, 1980). The only other large indigenous carnivore is the Tasmanian devil (*Sarcophilus harrisii*). These are common

around sclerophyll forest, open bushland and agricultural land and have a wide food spectrum including insects, small mammals and carrion (Pellis and Nelson, 1984). Intraspecific fighting among devils can lead to severe injury and death, often culminating in cannibalism (Guiler, 1970), and horizontal transmission of *S. mucosa* may be occurring within the single species host, as has been suggested for *Trichinella pseudospiralis* (Obendorf et al., 1990). Coprophagia also may present a recurrent source of infection within some populations of Tasmanian devils (Obendorf et al., 1990). A monoxenous life cycle of sarcosporidia has been documented in the tail-shedding Canarian lizard, *Gallotia galloti* (Matuschka and Bannert, 1987). However, this type of developmental adaptation does not detract from the possibility that *S. harrisii* are suitable definitive hosts for *S. mucosa*.

Other possible definitive hosts for the parasites in Tasmania include eastern and tiger quolls. Research has shown that tiger quolls are primarily carnivorous on live prey and carrion, with vegetable matter a relatively minor, although significant, dietary component (Belcher, 1995). Eastern quolls, although smaller, prey on bandicoots, rabbits and rats (Godsell, 1983), and also feed on large carrion including wallabies, possums and sheep (Pellis and Nelson, 1984). Eastern quolls are not indigenous to Queensland but their counterparts, the aggressive and carnivorous northern quolls (*D. hallucatus*), are widely distributed across the Townsville hinterland (Begg, 1983), where the capture of macropodids took place in the earlier study by O'Donoghue et al. (1987). Tiger quolls are also commonly found at that same location (Begg, 1983).

In summary, the only suitable definitive hosts for *S. mucosa* in Tasmania are cats and dogs, ravens, raptors, and dasyurid marsupials. Only the latter group were absent from the three island sites, and no infections were detected in wallabies or pademelons from these locations. It is

therefore appropriate to suggest that one of the dasyurid marsupials is the definitive host for *S. mucosa* in Tasmania and possibly also in Queensland. Isoenzyme electrophoresis has demonstrated that Tasmanian devils and quolls, and in particular the northern quoll, are genetically closely related (Baverstock et al., 1982). As one species of *Sarcocystis* can utilize one or more species of definitive or intermediate host (Cawthorn and Speer, 1989), it is feasible that in Queensland, quolls are the definitive hosts while in Tasmania, the sexual stages of the cycle occur in both quolls and Tasmanian devils.

ACKNOWLEDGMENTS

Thanks are extended to B. Munday for his supervision during the course of this study. Much appreciation is extended to S. Cairns, D. Geraghty, and D. Wright for critically reviewing the manuscript. The author also wishes to thank the following people for invaluable assistance and advice: B. Day, the staff of Lenah Game Meats, and S. Smith. The study was partially funded by the University of Tasmania, Launceston, Tasmania.

LITERATURE CITED

- BAVERSTOCK, P. R., M. ARCHER, M. ADAMS, AND B. J. RICHARDSON. 1982. Genetic relationships among 32 species of Australian dasyurid marsupials. In *Carnivorous marsupials*, M. Archer (ed.). Royal Zoological Society of New South Wales, Sydney, Australia, pp. 641–650.
- BEGG, R. J. 1983. The northern quoll. In *The Australian Museum complete book of Australian mammals*, R. Strahan (ed.). Angus and Robertson, Sydney, Australia, p. 23.
- BELCHER, C. A. 1995. Diet of the tiger quoll (*Dasyurus maculatus*) in East Gippsland, Victoria. *Australian Wildlife Research* 22: 341–359.
- BLAKERS, M., S. J. F. DAVIES, AND P. N. REILLY. 1984. The atlas of Australian birds. Royal Australasian Ornithologists Union, Melbourne University Press, Melbourne, Australia, 738 pp.
- CAWTHORN, R. J., AND C. A. SPEER. 1989. *Sarcocystis*: Infections and disease of humans, livestock and other hosts. In *Coccidiosis of man and domestic animals*, P. Long (ed.). C.R.C. Press Inc., Boca Raton, Florida, pp. 91–120.
- COULSON, G. 1989. The effect of drought on road mortality of macropods. *Australian Wildlife Research* 16: 79–83.
- . 1997. Male bias in road-kills of macropods. *Australian Wildlife Research* 24: 21–25.
- DUBEY, J. P., C. A. SPEER, AND R. FAYER. 1989. *Sarcocystosis of animals and man*. C.R.C. Press Inc., Boca Raton, Florida, 215 pp.
- , S. L. PORTER, A. L. HATTEL, D. C. KRADEL, M. J. TOPPER, AND L. JOHNSON. 1991. *Sarcocystis* associated clinical encephalitis in a golden eagle (*Aquila chryaetos*). *Journal of Zoo and Wildlife Medicine* 22: 233–236.
- GODSELL, J. 1983. The eastern quoll. In *The Australian Museum complete book of Australian mammals*, R. Strahan (ed.). Angus and Robertson, Sydney, Australia, pp. 20–21.
- GUILER, E. R. 1970. Observations on the Tasmanian devil, *Sarcophilus harrisii* (Marsupialia: Dasyuridae). I. Numbers, home range, movements and food in two populations. *Australian Journal of Zoology* 18: 49–62.
- JONES, E. 1983. The feral cat. In *The Australian Museum complete book of Australian mammals*, R. Strahan (ed.). Angus and Robertson, Sydney, Australia, pp. 488–489.
- MATUSCHKA, F. R., AND B. BANNERT. 1987. Cannibalism and autonomy as predator-prey relationship for monoxenous Sarcosporidia. *Parasitology Research* 74: 88–93.
- MUNDAY, B. L., R. W. MASON, W. J. HARTLEY, P. J. A. PRESIDENTE, AND D. OBENDORF. 1978. *Sarcocystis* and related organisms in Australian wildlife I: Survey findings in mammals. *Journal of Wildlife Diseases* 14: 417–433.
- , W. J. HARTLEY, AND K. E. HARRIGAN. 1979. *Sarcocystis* and related organisms in Australian wildlife II. Survey findings in birds, reptiles, amphibians and fish. *Journal of Wildlife Diseases* 15: 57–73.
- NEWSOME, A. E. 1983. Dingo and fox. In *The Australian Museum complete book of Australian mammals*, R. Strahan (ed.). Angus and Robertson, Sydney, Australia, pp. 482–486.
- OBENDORF, D., J. H. HANDLINGER, R. W. MASON, K. P. CLARKE, A. J. FORMAN, P. T. HOOPER, S. J. SMITH, AND M. HOLDSWORTH. 1990. *Trichinella pseudospiralis* infection in Tasmanian wildlife. *Australian Veterinary Journal* 67: 108–110.
- O'DONOGHUE, P. J., D. L. OBENDORF, M. G. O'CALLAGHAN, E. MOORE, AND B. R. DIXON. 1987. *Sarcocystis mucosa* (Blanchard 1885) Labbe 1889 in unadorned rock wallabies (*Petrogale assimilis*) and Bennett's wallabies (*Macropus rufogriseus*). *Parasitology Research* 73: 113–120.
- OLSEN, P., F. CROME, AND J. OLSEN. 1993. Birds of prey and ground birds of Australia. The national photographic index of Australian wildlife, Angus and Robertson, Sydney, Australia, 200 pp.
- PELLIS, S. M., AND J. E. NELSON. 1984. Some aspects of predatory behavior of the quoll, *Dasyurus viverrinus* (Marsupialia: Dasyuridae). *Australian Mammalogy* 7: 5–15.
- REYNOLDS, E. S. 1963. The use of lead citrate at

- high pH as electron opaque stain in electron microscopy. *Journal of Cell Biology* 17: 208.
- SMITH, S. J. 1980. The Tasmanian tiger: A report on an investigation of the current status of thylacine, *Thylacinus cynocephalus*, funded by the World Wildlife Fund. Wildlife Division Technical Report (Tasmania: National Parks and Wildlife Service), Hobart, Tasmania, Australia, 133 pp.
- STEVENS, A. 1982. The haematoxylin. In *Theory and practice of histological techniques*, 2nd ed. J. D. Bancroft and A. Stevens (eds.). Churchill Livingstone, New York, New York, pp. 109–121.
- THOMAS, D. 1979. Tasmanian bird atlas. Fauna of Tasmania handbook, No. 2, Fauna of Tasmania Committee, University of Tasmania, Hobart, Tasmania, Australia, 171 pp.
- ZILLMAN, J. 1997. The Drought Report. Australian Bureau of Meteorology, Melbourne, Australia, 2 pp.

Received for publication 20 August, 1997.