

## **Platynosomum fastosum in Ex-captive Orangutans from Indonesia**

Authors: Warren, Kristin S., Swan, Ralph A., and Hobbs, Russell P.

Source: Journal of Wildlife Diseases, 34(3) : 644-646

Published By: Wildlife Disease Association

URL: <https://doi.org/10.7589/0090-3558-34.3.644>

---

BioOne Complete ([complete.BioOne.org](https://complete.BioOne.org)) is a full-text database of 200 subscribed and open-access titles in the biological, ecological, and environmental sciences published by nonprofit societies, associations, museums, institutions, and presses.

Your use of this PDF, the BioOne Complete website, and all posted and associated content indicates your acceptance of BioOne's Terms of Use, available at [www.bioone.org/terms-of-use](https://www.bioone.org/terms-of-use).

Usage of BioOne Complete content is strictly limited to personal, educational, and non - commercial use. Commercial inquiries or rights and permissions requests should be directed to the individual publisher as copyright holder.

---

BioOne sees sustainable scholarly publishing as an inherently collaborative enterprise connecting authors, nonprofit publishers, academic institutions, research libraries, and research funders in the common goal of maximizing access to critical research.

## ***Platynosomum fastosum* in Ex-captive Orangutans from Indonesia**

Kristin S. Warren,<sup>1,2</sup> Ralph A. Swan,<sup>2,5</sup> Russell P. Hobbs,<sup>3</sup> Heriyanto,<sup>1</sup> Eva M. Kuhn,<sup>4</sup> and Jonathan L. Heeney,<sup>4</sup> <sup>1</sup> Wanariset Orangutan Reintroduction Centre, East Kalimantan, Indonesia; <sup>2</sup> Department of Applied Veterinary Medicine, Division of Veterinary and Biomedical Sciences, Murdoch University, South Street, Murdoch, Perth, Western Australia 6150; <sup>3</sup> Division of Veterinary and Biomedical Sciences, Murdoch University, South Street, Murdoch, Perth, Western Australia 6150; <sup>4</sup> Biomedical Primate Research Centre, Lange Kleiweg 151, P.O. Box 3306, 2280 G. H. Rijswijk, The Netherlands; and <sup>5</sup> Author to whom reprint requests should be addressed (e-mail: swan@numbat.murdoch.edu.au)

**ABSTRACT:** The liver fluke *Platynosomum fastosum* was identified upon necropsy of three ex-captive orangutans (*Pongo pygmaeus*) which had been part of a rehabilitation program for reintroduction to the wild. This trematode has not been reported in orangutans previously and is commonly found in cats in Southeast Asia. Cross infection from cats via intermediate hosts, to orangutans kept in captivity as pets, could explain their presence in the latter. Although *P. fastosum* caused intrahepatic and bile duct damage, death of the hosts could not be attributed solely to the presence of the liver fluke infection.

**Key words:** Liver fluke, orangutan, *Platynosomum fastosum*, *Pongo pygmaeus*, reintroduction.

The liver fluke *Platynosomum fastosum* was detected in three ex-captive orangutans (*Pongo pygmaeus*) of 13 animals that died during a confirmed outbreak of strongyloidosis at the Wanariset Orangutan Reintroduction Centre (East Kalimantan, Indonesia; 116°59'E, 1°0'S) during the period from December 1995 to March 1996.

The three orangutans in which liver flukes were detected were a female aged 2.5 yr, a male aged 3.0 yr and a female aged 7.5 yr at the time of death. The two youngest animals originated from East Kalimantan (Samarinda, Indonesia; 117°9'E, 0°30'S) and the oldest animal from South Kalimantan (Banjarmasin, Indonesia; 114°33'E, 3°22'S). All three had clinical signs of inappetence and chronic diarrhea prior to death. Adult trematodes were detected during necropsy and collected for identification from the 7.5-yr-old female. In the other two cases, trematodes were identified on histopathological examination of liver sections.

The intact trematodes were identified as *P. fastosum*, a member of the family Di-

crocoeliidae. Two stained adult specimens were compared to *P. fastosum* collected from a cat in peninsular Malaysia and were judged to belong to the same species based on the description in Shanta (1970) by the size of the suckers, extent of the vitellaria, size of the eggs and body shape (Fig. 1). Toft (1982) reviewed the trematodes of primates and Cribb and Spratt (1992) discussed the genus *Platynosomum* in mammals. The only other dicrocoeliid recorded from orangutans is *Leipertrema rewelli* which has been found in the pancreas of orangutans from Borneo (Indonesia). Specimens of *P. fastosum* from the orangutan are deposited in the Museum of Western Australia (Perth, Western Australia; accession number WAM 5/97).

*Platynosomum fastosum* has been reported previously from a macaque in peninsular Malaysia (Shanta, 1970). Two species of the genus *Platynosomum* are described from primates in Brazil (Kingston and Cosgrove, 1967). Both were smaller than *P. fastosum* but the larger of the two (*P. amazonensis*) had a narrow tapering tail compared to the bluntly rounded posterior extremity of *P. fastosum*. Also, the testes of *P. amazonensis* are only slightly larger than the ovary, whereas the testes of *P. fastosum* are considerably larger.

Although *P. fastosum* has not been reported in orangutans previously, it has been detected in the liver and bile ducts of domestic cats in Malaysia, as well as in Central and South America, the Caribbean, and southern USA (Soulsby, 1982). Maldonado (1945) studied the life cycle of this trematode in Puerto Rico. The first intermediate host, a snail *Subulina octona*,

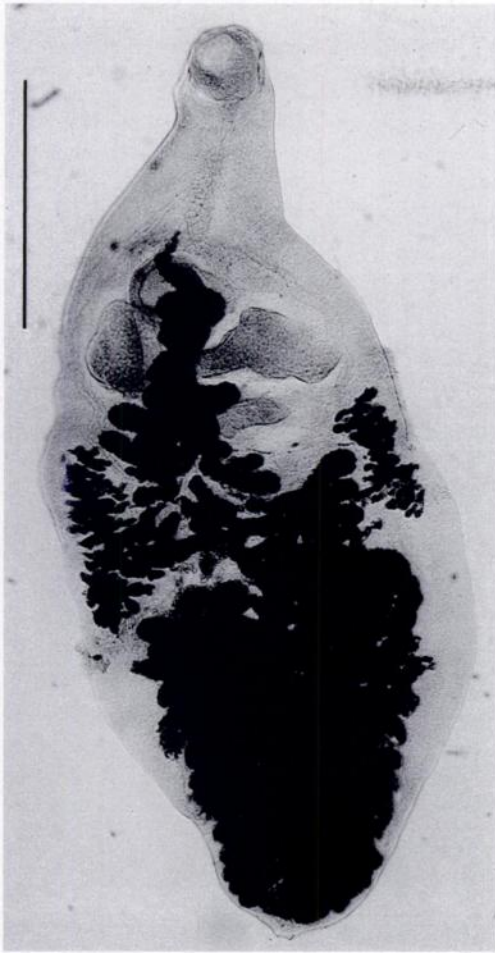


FIGURE 1. Photomicrograph of a stained adult *Platynosomum fastosum* from an orangutan. Bar = 1 mm.

was confirmed by experimental infection. Cats were experimentally infected by being fed metacercariae from naturally infected lizards (*Anolis cristatellus*) but could not be infected by eating cercariae from snails. However, the natural means by which lizards became infected was not investigated, so although Maldonado (1945) concluded that lizards were the second intermediate host, it is possible that they were only paratenic hosts. The life cycle in Southeast Asia is unknown, but Retnasabapathy and Prathap (1971) speculated that in peninsular Malaysia, the second intermediate host may be either a lizard or a cockroach. Cats become infected by eat-

ing the second intermediate host, after which the metacercaria migrates to the liver.

*Platynosomum fastosum* does not usually result in severe disease in cats, although in some cases it may result in vomiting, diarrhea, jaundice and death, with enlarged livers and marked dilation of the bile ducts (Soulsby, 1982). Histopathological examinations of two of the infected orangutans revealed hepatic lesions. In both cases the intrahepatic bile ducts were found in the bile ducts and liver tissue. Mild diffuse infiltration of mononuclear cells in the hepatic sinuses was also evident. Fifteen flukes were collected from within a small dissected area of the bile duct of one orangutan. While the presence of the trematodes can not alone be sufficient explanation of the cause of death in these individuals, they may have contributed to the hosts' demise in combination with other diseases such as strongyloidosis, their poor physiological state, and possibly lowered immune resistance.

It is not known how the orangutans became infected with *P. fastosum*. Orangutans arriving at the Reintroduction Centre had been confiscated from captivity, where they are often kept by families as pets in small villages. Cats also are kept as pets in villages and there is a significant feral cat population. In such a setting, it is possible for orangutans to become infected through ingestion of the second intermediate hosts. The anthelmintics used at the Reintroduction Centre to control gastrointestinal parasites were pyrantel pamoate (Combantrin, PT Pfizer Indonesia, Jakarta, Indonesia) and mebendazole (Vermox, Janssen Pharmaceutical, Pandaan, Jawa Timur, Indonesia) which are ineffective against liver fluke. Albendazole (Valbazen, Smith Kline Animal Health Products, French's Forest, New South Wales, Australia) also was used sporadically. Lack of treatment with a specific trematocidal drug may have allowed unimpeded development of these parasites. Certainly control measures for this parasite, including fecal screening of all

orangutans to detect the presence of eggs, controlling the feral cat population and incorporating a trematocidal drug into a parasite control program, should be included in a health management strategy for these animals.

The authors acknowledge W.T.M. Smits and staff of the Wanariset Orangutan Re-introduction Centre. The sponsorship of the Merck Foundation also is gratefully appreciated.

#### LITERATURE CITED

- CRIBB, T. H., AND D. M. SPRATT. 1992. Dicrocoeliidae (Trematoda: Digenea) of Australian mammals with description of *Dicrocoelium antechini* n.sp., *Athesmioides aiolos* n.g., n.sp. and *Platynosomum burrman* n.sp. *Systematic Parasitology* 21: 211-222.
- KINGSTON, N., AND G. E. COSGROVE. 1967. Two new species of *Platynosomum* (Trematoda: Dicrocoeliidae) from South American monkeys. *Proceedings of the Helminthological Society of Washington* 34: 147-151.
- MALDONADO, J. F. 1945. The life history and biology of *Platynosomum fastosum* Kossak, 1910 (Trematoda: Dicrocoeliidae). *Puerto Rico Journal of Public Health and Tropical Medicine* 21: 17-39.
- RETNASABAPATHY, A., AND K. PRATHAP. 1971. The liver-fluke *Platynosomum fastosum* in domestic cats. *The Veterinary Record* 88: 62-65.
- SHANTA, C. S. 1970. A species of *Platynosomum* from a monkey. *Malaysian Veterinary Journal* 5: 17-18.
- SOULSBY, E. 1982. Helminths, arthropods and protozoa of domesticated animals. Balliere Tindall, London, England, 809 pp.
- TOFT, J. D., II. 1982. The pathoparasitology of the alimentary tract and pancreas of nonhuman primates: A review. *Veterinary Pathology* 19: 44-92.

*Received for publication 8 August 1997.*