



THE EFFECT OF DIETARY AFLATOXIN ON WILD TURKEY POULTS

Authors: Quist, C. F., Bounous, D. I., Kilburn, J. V., Nettles, V. F., and Wyatt, R. D.

Source: Journal of Wildlife Diseases, 36(3) : 436-444

Published By: Wildlife Disease Association

URL: <https://doi.org/10.7589/0090-3558-36.3.436>

BioOne Complete (complete.BioOne.org) is a full-text database of 200 subscribed and open-access titles in the biological, ecological, and environmental sciences published by nonprofit societies, associations, museums, institutions, and presses.

Your use of this PDF, the BioOne Complete website, and all posted and associated content indicates your acceptance of BioOne's Terms of Use, available at www.bioone.org/terms-of-use.

Usage of BioOne Complete content is strictly limited to personal, educational, and non - commercial use. Commercial inquiries or rights and permissions requests should be directed to the individual publisher as copyright holder.

BioOne sees sustainable scholarly publishing as an inherently collaborative enterprise connecting authors, nonprofit publishers, academic institutions, research libraries, and research funders in the common goal of maximizing access to critical research.

THE EFFECT OF DIETARY AFLATOXIN ON WILD TURKEY POULTS

C. F. Quist,^{1,4} D. I. Bounous,² J. V. Kilburn,³ V. F. Nettles,¹ and R. D. Wyatt³

¹ Southeastern Cooperative Wildlife Disease Study, College of Veterinary Medicine

² Department of Pathology, College of Veterinary Medicine

³ Department of Poultry Science University of Georgia, Athens, Georgia 30602, USA

⁴ Corresponding author (e-mail: cquist@cvm.vet.uga.edu)

ABSTRACT: Aflatoxins, toxic metabolites of *Aspergillus flavus* or *Aspergillus parasiticus*, cause poor feed utilization, decreased weight gains, depressed immune function, liver dysfunction, coagulation abnormalities, and death in a wide variety of species including humans. Conservationists have become concerned that increasingly popular wildlife feeding or baiting practices could expose wildlife to toxic amounts of aflatoxin-contaminated grains. In particular, the effects of aflatoxins on the wild turkey (*Meleagris gallopova silvestris*) are of concern because the conspecific domestic turkey is highly susceptible to aflatoxins. To evaluate the effect of dietary aflatoxin on wild turkeys, four groups of 4-mo-old wild turkeys were fed diets containing either 0, 100, 200, or 400 µg aflatoxin/kg feed for 2 wk in September and October 1996. Aflatoxin-fed poults had decreased feed consumption and weight gains as compared with control poults. Decreased liver-to-body weight ratios, liver enzyme alterations, slightly altered blood coagulation patterns, and mild histologic changes indicated low-level liver damage. Compromise of cell-mediated immunity was indicated by decreased lymphoblast transformation. The effects were apparent in all treatment groups to variable levels, but significant differences most often were found at 400 µg aflatoxin/kg feed. This study shows that short-term aflatoxin ingestion by wild turkeys can induce undesirable physiologic changes; therefore, exposure of wild turkeys to feeds containing aflatoxin levels of 100 µg aflatoxin/kg feed or more should be avoided.

Key words: Aflatoxicosis, aflatoxin, *Aspergillus*, immune suppression, liver damage, *Meleagris gallopova silvestris*, wild turkey.

INTRODUCTION

Aflatoxin, produced by *Aspergillus flavus* or *Aspergillus parasiticus*, causes altered protein synthesis by inhibiting nucleic acid transcription and interfering with RNA translation. Aflatoxins interact with the basic metabolic pathways of the cell disrupting key enzyme processes including carbohydrate and lipid metabolism and protein synthesis (Cheeke and Shull, 1985). The Krebs cycle and phosphorylation of substrates also are inhibited via alterations in mitochondrial function (Cheeke and Shull, 1985). By virtue of the multiplicity of actions aflatoxins have on the liver and other cells containing mixed function oxidase systems, the effects of these toxins on animals are profound and far-reaching.

Since 1960, when approximately 100,000 domestic turkey poults (*Meleagris gallopova gallopova*) died from what was termed "Turkey X disease" (Blount, 1961), extensive research has been conducted to

determine the effects of aflatoxin on domestic animals. Although most animals have been shown to be susceptible, young animals are more susceptible than older animals presumably due to the lack of well-developed hepatic enzymatic systems that are required to degrade the toxins (Cheeke and Shull, 1985). Moreover, there is tremendous variability in the degree of susceptibility, even among closely related species. For example, chickens are quite resistant to the effects of aflatoxin compared with turkeys (Arafa et al., 1981), but there is breed variability even among chickens (Gumbmann et al., 1970). Similarly, bobwhite quail (*Colinus virginianus*) are more susceptible to the effects of aflatoxin than are Japanese quail (*Coturnic japonica*) (Stewart, 1985).

In the southern United States, artificial feeding of white-tailed deer (*Odocoileus virginianus*), wild turkeys (*Meleagris gallopova silvestris*), and other wildlife species has created an opportunity for wildlife to be exposed to aflatoxins, particularly via

contaminated corn. Aflatoxin levels in 51% of 39 submitted samples of shelled corn picked up at deer bait piles in North and South Carolina (USA) (Fischer et al., 1995) ranged from <10 to 750 μg aflatoxin/kg feed (parts per billion). More recently, analysis of corn offered by retailers in Georgia for use as wildlife feed revealed aflatoxin in three of 31 bags; one bag had 385 μg aflatoxin/kg feed (C. Quist, unpubl. data). Corn that is deliberately left unharvested for a wildlife food source is another source of aflatoxin. Aflatoxin levels found in standing corn during a 3 yr study on a bobwhite quail plantation ranged from 42 to 1,210 μg aflatoxin/kg feed (Stewart, 1985). Among wildlife species, the effects of aflatoxins have only been studied in white-tailed deer and bob-white quail. Subclinical liver damage was detected in both species (Quist et al., 1997; Stewart, 1985). These findings indicate that the threat of aflatoxicosis to wildlife is real albeit not well studied.

The effects of aflatoxin on domestic turkeys has been documented. Extensive mortality was produced in young domestic turkeys that were given 400 μg aflatoxin/kg feed or more of dietary aflatoxin (Giambrone et al., 1985b). Lower levels of aflatoxin cause blood-clotting abnormalities, immune dysfunction, and decreased feed conversion (Witlock and Wyatt, 1981; Giambrone et al., 1985a). Given this extreme susceptibility of the conspecific domestic turkey to aflatoxins, there is particular concern regarding the susceptibility of wild turkeys to aflatoxin exposure, yet the effects of aflatoxins on wild turkeys have not been studied.

The objective of this study was to determine the susceptibility of wild turkey poults to aflatoxin through evaluation of feed consumption, weight gains, gross and histologic lesions, blood chemistry profiles, blood clotting times, carotenoid levels, and immune function of wild turkey poults fed a diet contaminated with aflatoxin.

MATERIALS AND METHODS

Feeding trials were conducted in September and October 1996 at The University of Georgia

Poultry Diagnostic and Research Center (Clarke County, Georgia, USA; 33°55'N, 83°22'W). Because of the difficulties in obtaining sufficient numbers of age-equivalent wild-caught birds, 48 1-day-old wild turkeys were obtained from a certified commercial game bird breeder (Toubl Game Bird Farms, Beloit, Wisconsin, USA). The game bird breeder was carefully screened to insure that the source birds of his flocks were "true" wild turkeys. The poults were placed in battery brooders, then moved to floor pens bedded with cedar shavings when they were 14-days-old. Feed and water were provided *ad libitum*.

This study was designed to incorporate as many of the controlled variables as possible that are characteristic of the "real world" situation within the environment of the wild turkey. Corn is most likely to be introduced into the wild turkey's environment in the autumn. Because wild turkey poults hatched in the summer would be approximately 3-to-4 mo old by late summer, this age group is deemed to be most at risk. Therefore, we began this study when the poults were 3.5 mo of age. The wild turkey poults were fed aflatoxin-contaminated feed *ad libitum* for 14 days. It is well-known that aflatoxin contamination of grain is sporadic, non-uniform and occurs only in certain batches of corn (Fischer et al., 1995). Thus, in the "real world", it is most likely that the birds will forage on a bait pile of corn opportunistically, and if the corn were contaminated with aflatoxin it also is reasonable to assume that not every meal would be from the bait pile and perhaps not even one meal on every day. Consequently the probable duration of exposure of the wild turkeys to the aflatoxin contaminated material would be of short duration rather than long duration; hence, a relatively short feeding period was chosen.

When the birds were 3.5-mo-old, they were weighed and leg-banded for identification. The poults were divided into four groups of 12, each poult group had approximately equal total body weights. Each pen was assigned one of four dietary treatments of 0 (control), 100, 200, and 400 μg total aflatoxin/kg feed.

The aflatoxin used in this study was prepared by growing *A. parasiticus* NRRL 2999 on moistened polished rice according to the method of West et al. (1973). The resulting moldy rice was dried and ground to a fine powder and analyzed for aflatoxins by spectrophotometric methods described by Nabney and Nesbitt (1965). A weighed amount of the rice powder was added to the basal feed ration to attain the desired concentration of the dietary aflatoxin. The basal diet for the turkeys was turkey grower ration prepared by the University of Georgia

Department of Poultry Science. The concentration of aflatoxin in the final ration was confirmed to be close to the desired concentration on each batch of ration prepared. This analysis was performed with the Aflatest P affinity column procedure (Vicam, Watertown, Massachusetts, USA).

Baseline blood samples were collected on day 0 via jugular venipuncture for complete blood counts and serum chemistry profiles. At 7 and 14 days into the study, the turkeys were weighed and the amount of feed consumed was calculated. At day 14, blood was drawn from the turkeys for the following assays: complete blood counts and serum chemistry profiles, clotting times, carotenoid levels, and immune function studies. The poulters were humanely euthanized in a carbon-dioxide gas chamber, then necropsied. Body and organ weights (liver, heart, bursa, pancreas, and kidney) were obtained, and samples were taken for immunologic assays and histopathology. Tissue samples collected for histologic examination included bursa of Fabricius, cecum, duodenum, gonad, heart, jejunum, kidney, liver, lung, pancreas, pectoral muscle, proventriculus, spleen, thymus, and ventriculus. Specimens of liver and kidney were taken from the same location in the right and left liver lobe and proximal kidney pole, respectively. Tissue samples were fixed in 10% neutral buffered formalin, processed, embedded in paraffin, sectioned at 4 μm , and stained with hematoxylin and eosin (H&E) prior to light microscopy.

Serum chemistry analyses were performed on an Abbott Spectrum Series II analyzer (Abbott Laboratories, Dallas, Texas, USA). Complete blood counts were done manually using the Unopette method as recommended by the manufacturer (Becton Dickson, Rutherford, New Jersey, USA). Hematocrit values were determined through the use of microhematocrit tubes. Prothrombin times were measured using the techniques described by Doerr et al. (1976). Blood was collected in sodium citrate for measurement of carotenoids as described by Stone et al. (1971).

After the turkeys were euthanized, spleens from six of the poulters were removed aseptically, and mononuclear splenocytes were isolated for lymphoblast transformation assays (LBT) and immunophenotyping assays as previously described (Bounous et al., 1995). Blastogenic responses were expressed as a mean stimulation index (SI) obtained by dividing the mean counts per minute (CPM) of stimulated cells (CPM_S) minus CPM of unstimulated cells (CPM_U) by CPM_U ($\text{SI}_{\text{Thymidine}} = (\text{CPM}_S) - (\text{CPM}_U) / (\text{CPM}_U)$).

Body weight data was statistically analyzed

by a one-way analysis of variance (Tukey-Kramer test) with a comparison made between the body weight at the beginning of the feed study and the body weight after 7 and 14 days of aflatoxin feeding. All other data was statistically analyzed by an parametric analysis of variance with Bartlett's test to test for homogeneity of variances. If the Bartlett's test indicated a significant difference among the standard deviations, then a Kruskal-Wallis nonparametric analysis of variance was conducted (Motulsky, 1995). All statements of significance are based upon $P \leq 0.05$. All data are expressed as mean \pm standard deviation (SD).

RESULTS

Mortality occurred in each of the four treatment groups during the 2 wk feeding trial. One turkey each was lost from the 0, 100, and 200 μg aflatoxin/kg feed groups, and three turkeys in the 400 μg aflatoxin/kg feed group died. The deaths of three poulters (one each from the 0, 100, and 400 μg aflatoxin/kg feed groups) occurred within the first few days of the study and were attributed to capture myopathy based on gross and histologic lesions. The poult from the 400 μg aflatoxin/kg feed group also had ingested a large metallic foreign body. A poult from the 200 μg aflatoxin/kg feed group was diagnosed with severe chronic septic tibiotarsal synovitis. Retrospectively, it was found that the initial white blood cells counts from this bird were elevated, necessitating its removal from the study. Ten days into the study, a second poult in the 400 μg aflatoxin/kg feed group died from chronic staphylococcal peritonitis. The third poult from the 400 μg aflatoxin/kg feed group died on day 14; no gross or microscopic lesions indicative of infectious disease or trauma were present. We were unable to obtain a blood sample from this bird that may have confirmed aflatoxicosis prior to its untimely death.

Over the course of the study, total feed consumption by the 400 μg aflatoxin/kg feed poulters was approximately half the amount consumed by control poulters. Unfortunately, the precise amount of feed consumed per bird per day could not be

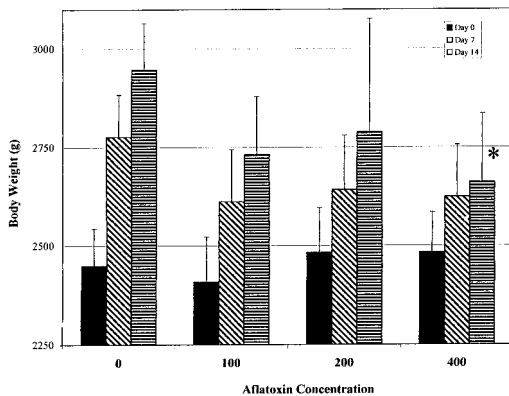


FIGURE 1. Average body weights (\pm SD) of groups of 4-mo-old wild turkey poult fed 0, 100, 200, or 400 μ g aflatoxin/kg feed at 0, 7, and 14 days. Poults receiving 400 μ g aflatoxin/kg feed gained significantly less weight ($P \leq 0.05$) over the 14 day trial than did the other poults. Significant values are marked with an asterisk (*).

quantified because of daily variation in poult numbers due to the mortality during the study.

Body weights of individual poults in the four treatment groups were not significantly different at the beginning of the study ($\bar{x} = 2455.35 \pm 36$ g; range = 2406 to 2483 g) (Fig. 1). Over the course of the study, all poults gained weight, but a linear pattern of gain was seen in all groups with the control poults gaining the most weight and the 400 μ g aflatoxin/kg feed poults gaining the least (Fig. 1). By day 14, the weight gain obtained by these 400 μ g aflatoxin/kg feed poults was significantly less than that obtained by the other groups ($P \leq 0.05$).

At necropsy, the nine poults from the 400 μ g aflatoxin/kg feed group had a slight orange discoloration of livers, and microscopically, mild biliary hyperplasia was present. Mild hepatocellular lipidosis also was noted in this group, but this lesion occurred only slightly more frequently than in the other groups. No microscopic lesions were present in remaining tissues.

Control poults had significantly higher ($P \leq 0.05$) relative liver weights (organ-to-body weight ratio: g organ/100 g body weight) than did aflatoxin-fed poults (Ta-

ble 1). Relative spleen weights from all aflatoxin-fed groups were less than those of control poults and the relative pancreatic weights were higher than control poults, but not statistically so.

By the end of the study, trends, but no statistically significant differences, were found in blood cell count parameters (Table 2). Control poults had the lowest PCV and total white blood cell (WBC) count of the four treatment groups. The total WBC counts of poults from the 400 μ g aflatoxin/kg feed group were higher than those of the control group due to an increase in both lymphocytes and heterophils. Absolute basophil counts of the 400 μ g aflatoxin/kg feed group were much lower than the other groups.

Blood chemistry results from samples collected at the end of the study are shown (Table 3). Total protein and albumin concentrations of poults in the 200 and 400 μ g aflatoxin/kg feed groups were significantly lower ($P \leq 0.05$) than those of poults in the 0 or 100 μ g aflatoxin/kg feed groups. Concentrations of aspartate transaminase (AST) activity among 200 and 400 μ g aflatoxin/kg feed treatment poults were significantly higher than those of control poults ($P \leq 0.05$). Cholesterol concentrations among aflatoxin-fed poults were lower than those of the controls, but the results were only significant at the 200 μ g aflatoxin/kg level ($P \leq 0.05$). Poults from the 100 μ g aflatoxin/kg feed group had a significant higher ($P \leq 0.05$) uric acid concentration when compared with the control group. Triglyceride levels decreased linearly with increasing levels of aflatoxin in the diet, but not to the level of statistical significance. No significant alterations were found in serum concentrations of glucose, calcium, or lactate dehydrogenase (LDH) among the poults.

Prothrombin times after 14 days indicated that control poults had a more rapid mean coagulation time (10.24 ± 0.97 sec) than did the 100 (10.30 ± 0.80 sec), 200 (10.55 ± 0.50 sec), or 400 (10.76 ± 0.64 sec) μ g aflatoxin/kg feed treatment groups.

TABLE 1. Comparative relative organ weights (g organ per 100 g body weight) of 4-mo-old wild turkeys fed aflatoxin for 14 days.

Dietary aflatoxin ($\mu\text{g}/\text{kg}$ feed)	Liver	Pancreas	Spleen (g of organ/100 g body weight)	Heart (g of organ/100 g body weight)	Kidney	Bursa
0	1.50 \pm 0.13 ^a	0.196 \pm 0.026 ^a	0.092 \pm 0.014 ^a	0.601 \pm 0.036 ^a	0.280 \pm 0.033 ^a	0.052 \pm 0.009 ^a
100	1.34 \pm 0.10 ^b	0.212 \pm 0.043 ^a	0.069 \pm 0.006 ^a	0.625 \pm 0.057 ^a	0.278 \pm 0.050 ^a	0.054 \pm 0.012 ^a
200	1.29 \pm 0.16 ^b	0.224 \pm 0.030 ^a	0.067 \pm 0.016 ^a	0.628 \pm 0.077 ^a	0.283 \pm 0.048 ^a	0.060 \pm 0.016 ^a
400	1.31 \pm 0.16 ^b	0.232 \pm 0.048 ^a	0.079 \pm 0.047 ^a	0.625 \pm 0.076 ^a	0.298 \pm 0.027 ^a	0.045 \pm 0.014 ^a

^{a,b} Values (mean \pm SD) within a column with different superscripts are significantly different ($P \leq 0.05$).

However, these differences were not significant.

Total plasma carotenoids determined at the end of the study were as follows: control poult, 0.028 \pm 0.011 $\mu\text{g}/\text{ml}$; 100 μg aflatoxin/kg feed poult, 0.036 \pm .006 $\mu\text{g}/\text{ml}$; 200 μg aflatoxin/kg feed poult, 0.026 \pm .007 $\mu\text{g}/\text{ml}$; and 400 μg aflatoxin/kg feed poult, 0.028 \pm .007 $\mu\text{g}/\text{ml}$. The carotenoid concentration among 100 μg aflatoxin/kg feed poult was significantly greater ($P \leq 0.05$) remaining poult groups.

Of the immune function tests performed, the poult that were fed 400 μg aflatoxin/kg feed had markedly decreased lymphoblast transformation ($\text{SI} = 8 \pm 5$) as compared with control ($\text{SI} = 48 \pm 28$), 100 ($\text{SI} = 32 \pm 27$), or 200 ($\text{SI} = 38 \pm 41$) poult, but the results were not significantly different. Similarly, no significant differences were detected using immunophenotyping, but all aflatoxin-fed poult had an increased percentage of CD8+ staining cells, and the groups fed 100 and 200 μg aflatoxin/kg feed had a decreased percentage of CD4+ staining cells (Fig. 2). The CD4/CD8 ratio was decreased in all poult fed aflatoxin, as a result of the increase in CD8+ cells.

DISCUSSION

Based on this study, the effect of aflatoxins on the feed consumption, weight gains, liver and immune function, and blood parameters of wild turkeys has many similarities to the effects of aflatoxin on domestic poult even though the birds used here were older than the 1- to 14-day-old birds often used in studies of domestic turkeys.

The decreased feed consumption and decreased weight gain that we observed in these wild turkeys is commonly seen in aflatoxin-fed domestic poult (Arafa et al., 1981). Although it may be argued that taste aversion causes the decreased feed consumption and resultant diminished weight gains, decreased weight gain is also seen in poult administered aflatoxin via oral dosing (Giambone et al., 1985a), thus

TABLE 2. Packed cell volumes and differential leukocyte counts of 4-mo-old wild turkeys fed aflatoxin for 14 days.

Parameter	Dietary aflatoxin (μg of aflatoxin/kg of diet)			
	0.0	100	200	400
Packed cell vol. (%)	36.0 \pm 4.2 ^a	41.0 \pm 3.0 ^a	39.5 \pm 3.7 ^a	39.4 \pm 3.4 ^a
Total WBC (cells/dl)	22,664 \pm 6,501 ^a	30,562 \pm 17,385 ^a	23,958 \pm 5,976 ^a	33,908 \pm 14,680 ^a
Heterophils (cell/dl)	8,854 \pm 4,374 ^a	14,307 \pm 12,808 ^a	8,628 \pm 3,362 ^a	15,014 \pm 8,820 ^a
Lymphocytes (cells/dl)	10,660 \pm 4,812 ^a	12,792 \pm 7,062 ^a	11,591 \pm 4,075 ^a	16,441 \pm 12,634 ^a
Monocytes (cells/dl)	1,498 \pm 747 ^a	1,537 \pm 1,011 ^a	1,959 \pm 1,243 ^a	1,580 \pm 1,234 ^a
Basophils (cells/dl)	1,446 \pm 950 ^a	1,369 \pm 808 ^a	1,700 \pm 1,015 ^a	895 \pm 536 ^a

^{a,b} Values (mean \pm SD) within a row with different superscripts are significantly different ($P \leq 0.05$).

minimizing taste aversion to the aflatoxins as the sole cause of decreased food consumption and resultant failure to gain weight. The decreased weight gain seen in these wild turkey poults, though less pronounced, is similar to reports of 1-day-old (Giambone et al., 1985a; Arafa et al., 1981) and 2-wk-old (Giambone et al., 1985b) domestic turkey poults fed aflatoxin. Control wild turkey poults weighed 10.7% more than the 400 μg aflatoxin/kg feed group compared with a 13% weight differential in domestic poults fed 200 μg aflatoxin/kg feed (Weibking et al., 1994) or 250 μg aflatoxin/kg feed (Pier and Heddleston, 1970) aflatoxin.

The decreased relative liver weights of our aflatoxin-fed poults (Table 1) is consistent with previous studies of domestic poults (Gumbmann et al., 1970; Weibking et al., 1994). Studies in chickens indicate that the liver is the organ most sensitive to

the effects of aflatoxin (Huff et al., 1986). Reported alterations in weights of other organs vary, which previously has been speculated to be due to the different forms of aflatoxin and different concentrations of aflatoxin metabolites used in each study (Weibking et al., 1994). No significant alterations in the average weights of pancreas and bursa were found in our wild turkey poults, which again is consistent with studies of domestic poults (Weibking et al., 1994).

Although pale orange-tinted livers are a common gross finding in aflatoxin-intoxicated domestic animals (Cheeke and Shull, 1985), the mild histologic lesions seen in this study may be due to the relatively short 14 day feeding period used here. Significant histologic lesions are most common after 17 to 31 days exposure to aflatoxins (Gumbmann et al., 1970).

In domestic turkeys, biochemical chang-

TABLE 3. Serum chemistry values of 4-mo-old wild turkeys fed aflatoxin for 14 days.

Serum component	Dietary aflatoxin (μg aflatoxin/kg feed)			
	0.0	100	200	400
Total Protein (g/dl)	4.2 \pm 0.4 ^a	4.2 \pm 0.5 ^a	3.7 \pm 0.4 ^b	3.4 \pm 0.7 ^b
Albumin (g/dl)	1.5 \pm 0.2 ^a	1.3 \pm 0.3 ^a	1.2 \pm 0.2 ^b	1.1 \pm 0.4 ^b
AST (U/L)	304 \pm 39 ^a	320 \pm 19 ^a	340 \pm 41 ^{a,b}	407 \pm 80 ^b
Cholesterol (mg/dl)	114 \pm 11 ^a	99 \pm 16 ^a	85 \pm 21 ^b	96 \pm 12 ^a
Uric Acid (mg/dl)	4.5 \pm 1.4 ^a	6.3 \pm 1.3 ^b	4.7 \pm 1.1 ^a	5.8 \pm 1.8 ^a
Triglycerides (mg/dl)	189 \pm 36 ^a	186 \pm 34 ^a	178 \pm 23 ^a	171 \pm 39 ^a
LDH (U/L)	667 \pm 163 ^a	588 \pm 108 ^a	595 \pm 86 ^a	683 \pm 274 ^a
Glucose (mg/dl)	312 \pm 27 ^a	328 \pm 44 ^a	309 \pm 19 ^a	276 \pm 58 ^a
Calcium (mg/dl)	11.5 \pm 0.7 ^a	11.8 \pm 0.9 ^a	11.4 \pm 0.9 ^a	11.4 \pm 1.0 ^a

^{a,b} Values (mean \pm SD) within a row with different superscripts are significantly different ($P \leq 0.05$).

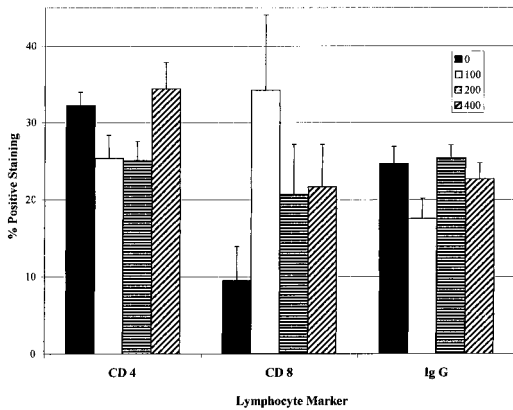


FIGURE 2. Immunophenotyping at Day 14 of groups of 4-mo-old wild turkey poults fed 0, 100, 200, or 400 μg aflatoxin/kg feed. Splenocytes were labeled with monoclonal antibodies to CD4 + and CD8 + cell markers and with anti-IgG. Cells were analyzed by flow cytometry. Results are expressed a percentage of labelled cells \pm SD.

es seen with aflatoxin exposure are maximal during the first 3 wk of exposure with hypoalbuminemia and the resultant hypoproteinemia considered the most sensitive indicators of aflatoxin intoxication (Gumbmann et al., 1970). Reductions in serum triglycerides also have been reported in chickens with high levels of aflatoxin exposure (Huff et al., 1986). This is compatible with the compromised hepatic function and hepatocellular damage indicated in these wild turkey poults by hypoalbuminemia, hypoproteinemia, and increased aspartate aminotransferase activity. Interference with lipid metabolism by aflatoxins is thought to cause impaired release of triglycerides by the liver (Cheeke and Shull, 1985), which would explain the progressively decreasing serum triglycerides seen here with increasing levels of aflatoxin in aflatoxin-fed wild turkey poults.

Aflatoxins cause a complex of alterations of carotenoid distribution in the tissues by a combination of interference with intestinal absorption, sequestration of carotenoids in the liver, and interference with integumentary deposition of mobilized carotenoids (Tyczkowski and Hamilton, 1987). Thus, in domestic poultry (Ty-

czkowski and Hamilton, 1987), carotenoid levels provide an additional assessment of altered fat metabolism from aflatoxicosis. Here, the 100 μg aflatoxin/kg feed wild turkeys had increased plasma carotenoids, possibly reflecting such increased fat mobilization. However, the lack of significant changes in carotenoid levels of the 200- and 400 μg aflatoxin/kg feed groups may be because wild turkeys lack the genetic propensity of domestic turkeys to deposit carotenoids in skin, muscle, and fat. Nonetheless, livers from the 400 μg aflatoxin/kg feed group were grossly orange, suggesting carotenoid deposition at that site. Liver carotenoid levels might have detected carotenoid deposition in hepatocytes, but this assay was not performed.

The mean packed cell volumes of all treatment groups of wild turkey poults were increased compared with controls, which contrasts with previous reports of decreased packed cell volumes (Weibking et al., 1994) and hemolytic anemia (Tung et al., 1975) in aflatoxin-exposed domestic poults. It is unknown whether the increased hematocrits seen in our wild turkeys were a direct effect of aflatoxin exposure, or whether they were secondary to other conditions. Because the anemia induced by aflatoxins in chickens begins after 17 to 21 days of aflatoxin ingestion (Huff et al., 1986), it may be that a more prolonged feeding trial in wild turkeys would be necessary for such an anemia to develop. Bone marrow granulocytic hyperplasia has been speculated to be the cause of heterophilia in chickens fed aflatoxin (Tung et al., 1975), but alternate explanations for the heterophilia seen in our poults includes an inflammatory response or a response to stress such as is observed in chickens (Siegel, 1971).

Cell-mediated immunity is inhibited by aflatoxin in domestic poults (Giambrone et al., 1985a; Giambrone et al., 1985b) and other species (Cheeke and Shull, 1985), probably through suppression of T-helper or cytotoxic T-cell activity (Sharma, 1993). The suppression of lymphoblastogenesis

indicates such impaired cell-mediated immunity in these wild turkeys. In mice, the challenge dose of the mycotoxin can alter whether T-helper or cytotoxic T-cells are most severely impacted (Hatori et al., 1991), which may explain the variation in CD4+ and CD8+ staining cells seen between our treatment groups. Pier and Heddleston (1970) demonstrated a reduction in acquired resistance to *Pasteurella multocida* in domestic turkey poults fed aflatoxins. As mycotoxin poisoning in livestock is often manifest by increased losses due to infectious organisms (Sharma, 1991), immune compromise to pathogens may be one of the most important effects aflatoxins have on wild turkeys.

The effects of aflatoxin on wild turkeys under field conditions will vary with the duration and consistency of ingestion of aflatoxin-contaminated feed and other environmental stressors. In contrast, these experimentally affected poults were maintained under optimal conditions with regard to feed quality and availability, and no additional stressors (other than once weekly handling during the feeding trial). Nonetheless, this study shows that short-term exposure of 4-mo-old wild turkey poults to aflatoxins produced a multitude of effects including decreased feed consumption and weight gains, decreased liver-to-body weight ratios, serum chemistry alterations, leukocyte alterations, and diminished cell-mediated immune function similar to those effects seen in intoxicated domestic turkey poults.

ACKNOWLEDGMENTS

This study was funded by a grant from National Wild Turkey Federation. We are grateful to R. L. Brooks Jr., M. Teglas, T. Cornish, J. Wlodkowski, C. Sewell, and B. Marchinton for their assistance. Financial assistance also was provided via sponsorship from the fish and wildlife agencies of Alabama, Arkansas, Florida, Georgia, Kansas, Kentucky, Louisiana, Maryland, Mississippi, Missouri, North Carolina, Puerto Rico, South Carolina, Tennessee, Virginia, West Virginia and through the Federal Aid to Wildlife Restoration Act (50 Stat. 917) and Grant Agreement 1445-GT09-96-0002,

U.S. Geological Survey, U.S. Department of the Interior.

LITERATURE CITED

- ARAFI, A. S., R. J. BLOOMER, H. R. WILSON, C. F. SIMPSON, AND R. H. HARMS. 1981. Susceptibility of various poultry species to dietary aflatoxins. *British Poultry Science* 22: 431-436.
- BLOUNT, W. P. 1961. Turkey "X" disease. *Journal of the British Turkey Federation* 1: 52,55,61.
- BOUNOUS, D. I., M. A. GOODWIN, R. L. BROOKS, C. M. LAMICHANE, R. P. CAMPAGNOLI, J. BROWN, AND D. B. SNYDER. 1995. Immunosuppression and intracellular calcium signaling in splenocytes from chicks infected with chicken anemia virus, CL-1 isolate. *Avian Diseases* 39: 135-140.
- CHEEKE, P. R., AND L. R. SHULL. 1985. Natural toxicants in feeds and poisonous plants. AVI Publishing Company, Inc., Westport, Connecticut, 492 pp.
- DOERR, J. A., R. D. WYATT, AND P. B. HAMILTON. 1976. Impairment of coagulation function during aflatoxicosis in young chickens. *Toxicology and Applied Pharmacology* 35: 437-446.
- FISCHER, J. R., A. V. JAIN, D. A. SHIPES, AND J. S. OSBORNE. 1995. Aflatoxin contamination of corn used as bait for deer in the southeastern United States. *Journal of Wildlife Diseases* 31: 570-572.
- GIAMBRONE, J. J., U. L. DEINER, N. D. DAVIS, A. S. PANAGALA, AND F. J. HOERR. 1985a. Effect of purified aflatoxin on turkeys. *Poultry Science* 64: 859-865.
- _____, _____, _____, _____, AND _____. 1985b. Effect of purified aflatoxin on turkeys and broiler chickens. *Poultry Science* 64: 1678-1684.
- GUMBMAN, M. R., S. N. WILLIAMS, A. N. BOOTH, P. VOHRA, R. A. ERNST, AND M. BETHARD. 1970. Aflatoxin susceptibility in various breeds of poultry. *Proceedings of the Society of Experimental Biological Medicine* 134: 683-688.
- HATORI, Y., R. P. SHARMA, AND R. P. WARREN. 1991. Resistance of C57BL/6 mice to immunosuppressive effects of aflatoxin B1 and the relationship with neuroendocrine mechanisms. *Immunopharmacology* 22: 127-136.
- HUFF, W. E., L. F. KUBENA, R. B. HARVEY, D. E. CORRIER, AND H. H. MOLLENHAUER. 1986. Progression of aflatoxicosis in broiler chickens. *Poultry Science* 65: 1891-1899.
- MOTULSKY, H. 1995. *Intuitive biostatistics*. Oxford University Press, Inc., New York, New York, 348 pp.
- NABNEY, J., AND B. F. NESBITT. 1965. A spectrophotometric method of determining the aflatoxins. *Analyst* 90: 155-160.
- PIER, A. C., AND K. L. HEDDLESTON. 1970. The effect of aflatoxin on immunity in turkeys. I. Impairment of actively acquired resistance to bacterial challenge. *Avian Diseases* 14: 797-809.

- QUIST, C. F., E. W. HOWERTH, J. R. FISCHER, R. D. WYATT, D. M. MILLER, AND V. F. NETTLES. 1997. Evaluation of low-level aflatoxin in the diet of white-tailed deer. *Journal of Wildlife Diseases* 33: 112–121.
- SIEGEL, H. S. 1971. Adrenals, stress, and the environment. *World's Poultry Science Journal* 27: 327–349.
- SHARMA, R. P. 1993. Immunotoxicity of aflatoxins. *Journal of Dairy Science* 76: 892–897.
- STEWART, R. G. 1985. Natural exposure of bobwhite quail to aflatoxin. Ph.D. Dissertation, University of Georgia, Athens, Georgia, 65 pp.
- STONE, H. A., W. M. COLLINS, AND W. E. URBAN. 1971. Evaluation of carotenoid concentration in chicken tissues. *Poultry Science* 50: 675–681.
- TUNG, H-T., F. W. COOK, R. D. WYATT, AND P. B. HAMILTON. 1975. The anemia caused by aflatoxin. *Poultry Science* 54: 1962–1969.
- TYCZKOWSKI, J. A., AND P. B. HAMILTON. 1987. Altered metabolism of carotenoids during aflatoxicosis in young chickens. *Poultry Science* 66: 1184–1188.
- WEIBKING, T. S., D. R. LEDOUX, A. J. BERMUDEZ, AND G. E. ROTTINGHAUS. 1994. Individual and combined effects of feeding *Fusarium moniliforme* culture material, containing known levels of fumonisin B1, and aflatoxin B1 in the young turkey poult. *Poultry Science* 73: 1517–1525.
- WEST, S., R. D. WYATT, AND P. B. HAMILTON. 1973. Improved yield of aflatoxin by incremental increases of temperature. *Applied Microbiology* 25: 1018–1019.
- WITLOCK, D. R., AND R. D. WYATT. 1981. Effect of dietary aflatoxin on hemostasis of young turkey poults. *Poultry Science* 60: 528–531.

Received for publication 19 February 1999.