

EPIDERMOPTID MANGE IN LAYSAN ALBATROSS FLEDGLINGS IN HAWAII

Authors: Gilardi, Kirsten V. K., Gilardi, James D., Frank, Anthony, Goff, M. Lee, and Boyce, Walter M.

Source: Journal of Wildlife Diseases, 37(1) : 185-188

Published By: Wildlife Disease Association

URL: <https://doi.org/10.7589/0090-3558-37.1.185>

BioOne Complete (complete.BioOne.org) is a full-text database of 200 subscribed and open-access titles in the biological, ecological, and environmental sciences published by nonprofit societies, associations, museums, institutions, and presses.

Your use of this PDF, the BioOne Complete website, and all posted and associated content indicates your acceptance of BioOne's Terms of Use, available at www.bioone.org/terms-of-use.

Usage of BioOne Complete content is strictly limited to personal, educational, and non - commercial use. Commercial inquiries or rights and permissions requests should be directed to the individual publisher as copyright holder.

BioOne sees sustainable scholarly publishing as an inherently collaborative enterprise connecting authors, nonprofit publishers, academic institutions, research libraries, and research funders in the common goal of maximizing access to critical research.

EPIDERMOPTID MANGE IN LAYSAN ALBATROSS FLEDGLINGS IN HAWAII

Kirsten V. K. Gilardi,^{1,2} James D. Gilardi,³ Anthony Frank,⁴ M. Lee Goff⁵ and Walter M. Boyce⁶ ¹ Wildlife Health Center, School of Veterinary Medicine, University of California, Davis, California 95616, USA; ² Corresponding author (e-mail: kvgilardi@ucdavis.edu); ³ The Oceanic Society, Fort Mason Bldg. E, San Francisco, California 94123, USA; ⁴ Department of Pathology, College of Veterinary Medicine and Biomedical Sciences, Colorado State University, Fort Collins, Colorado 80523-1671, USA; ⁵ Department of Entomology, University of Hawaii, Manoa, Honolulu, Hawaii 96822, USA; ⁶ Department of Pathology, Microbiology and Immunology, School of Veterinary Medicine, University of California, Davis, California 95616, USA.

ABSTRACT: Mange caused by the epidermoptid mite *Myialges nudus* (Acari: Epidermoptidae) is described in 31 dead fledgling Laysan albatrosses (*Phoebastria immutabilis*) from Midway Atoll (Hawaii, USA) sampled from 18 June to 10 July 1990 and from 21 June to 22 July 1991. This is the first record for this parasite from this host. Mites were collected from the skin; were located primarily in the stratum corneum; and were associated with mild to severe granulomatous inflammation, hyperkeratosis, dermal edema, ballooning degeneration of keratinocytes, neovascularization, and subdermal fibrosis. The severity of inflammation in some birds suggested that dermatitis due to *M. nudus* could be a significant cause of morbidity, or even mortality, in these birds.

Key words: Epidermoptidae, Laysan albatross, mange, mite, *Myialges*, seabird.

Midway Atoll (Hawaii, USA) is the site of one of the world's largest breeding colonies of Laysan albatross (*Phoebastria immutabilis*). Possible causes of morbidity and mortality in Laysan albatross chicks on Midway Atoll have included lead toxicity, plastics ingestion, dehydration, necrotizing enteritis, and trombiculid mite ("chigger") infestation (Sileo et al., 1990; Work et al., 1998). In this report, we describe the infestation of Laysan albatross fledglings on Midway Atoll with an ectoparasite not previously reported for this host, and the inflammatory lesions associated with this infestation.

From 18 June to 10 July 1990 and 21 June to 22 July 1991, we opportunistically collected skin samples from 31 dead Laysan albatross fledglings on Sand Island (Midway Atoll; 28°11'N, 177°2'W) in an exploratory study aimed at further investigating trombiculid mite infestation in Laysan albatross chicks on Midway (Goff

et al., 1989). The exact age of each chick was unknown, but likely ranged from 5 to 6 mo, based on the breeding phenology of Laysan albatross in the Hawaiian Islands (Harrison et al., 1983). We collected skin samples from fresh carcasses only (i.e., carcasses exhibited no grossly visible decomposition due to autolysis or sarcophagid fly infestation). We assumed the habitat type in which each carcass was found was the habitat in which the chick was raised, and described it as either ironwood (*Casuarina equisetifolia*) grove, maintained lawn, or aircraft runway (a significant portion of Sand Island was developed for military purposes during World War II). Full necropsies with histopathology on each bird were outside the scope of this exploratory project. Consequently, cause of mortality was unknown for all carcasses from which skin samples were obtained.

From each carcass we excised a 4 × 4 cm (16 cm²) section of skin and subcutaneous tissue from the ventral midline, approximately 4 cm cranial to the cloaca. Grossly, the skin was adequately feathered and appeared normal, with no visible rash or exudate. Overall body condition varied from emaciated to well-fleshed. Skin samples were preserved in 10% formalin.

To extract ectoparasites, three 1 cm² sections were removed from each of the larger 16 cm² samples. Each 1 cm² sample was digested by immersion in 10 ml of 10% potassium hydroxide (KOH) heated to 85 C ± 2 C in an ethylene glycol bath for 1.5 hr. Each sample was then centrifuged for 15 min at 3,600 rpm. The supernatant was decanted, the pellet resus-

pended in 10 ml of 70% ethanol and 5% glycerin to remove residual KOH, and the sample centrifuged again for 15 min at 3,600 rpm. Pellets were mounted on glass slides and fixed in Hoyer's medium (Ash and Orihel, 1987).

Extracted parasites were of uniform morphology, and were identified as the epidermoptid mite *Myialges (Metamicrolichus) nudus* (Fain, 1965). Voucher specimens of this mite have been deposited with the USDA National Parasite Collection (Beltsville, Maryland, U.S.A.; Accession No. 089336.00). To our knowledge, *Myialges nudus* has not previously been reported in Laysan albatross, nor has it been reported in any seabird species. *Myialges nudus* has been reported in Bohemian waxwings (*Bombycilla garrulus*), long-eared owls (*Asio otus*) (Fain, 1965), and a gray-cheeked parakeet (*Brotogeris pyrrhopterus*) (Greve, 1984). No trombiculid mites were extracted from these skin samples.

In order to assess the degree of infestation in skin samples collected in 1990 ($n = 16$), we counted total numbers of mites extracted from each of the three 1 cm² subsamples via light microscopy at 40 \times magnification. A whole body or gnathosoma (head-like structure) was counted as one mite: loose appendages were not quantified. Total counts for each of the subsamples were averaged to determine the mean mites/cm² in the ventral midline area of each carcass. Counts revealed an average of 134 mites/cm² (SD = 126.4; range = 1.3–393). Skin samples collected from seven carcasses found in ironwood groves contained significantly higher numbers of mites on average (210/cm²; SD = 153.2) compared to skin samples collected from six carcasses found on maintained lawns (66/cm², SD = 60.3; two-tailed t -test, $P = 0.05$). Concentration of mites was not quantified for 1991 samples.

Histologically, of the 31 skin samples examined, 14/16 (88%) of the 1990 samples and 10/15 (67%) of the 1991 skin samples exhibited mild to marked parasitic der-

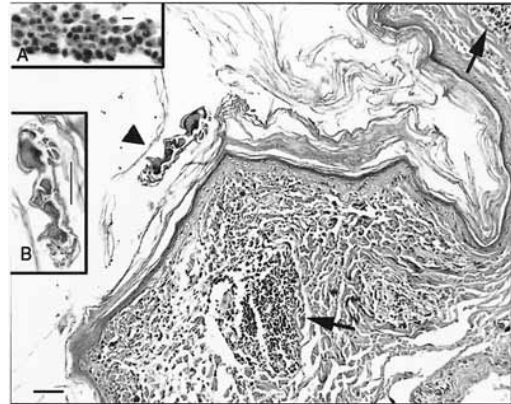


FIGURE 1. Photomicrograph of a section of Laysan albatross (*Phoebastria immutabilis*) skin. Hyperkeratosis and dense aggregates of epithelioid macrophages and lymphocytes comprising granulomatous inflammation are subjacent within the dermis (arrows), with higher magnification showing epithelioid macrophages (Inset A; bar = 10 μ). A cross-sectioned mite, *Myialges nudus*, is visible within the stratum corneum (large arrowhead), with higher magnification showing a cross-section of the parasite (Inset B; bar = 100 μ). Bar = 100 μ ; hematoxylin and eosin.

matitis (Fig. 1). The granulomatous inflammation, defined by epithelioid histiocytes as the dominant cell type, also was accompanied by diffuse hyperkeratosis, multifocal dermal edema, and infiltrates of heterophils with scattered eosinophils and lymphocytes in the superficial layers of the dermis. Whether the heterophil infiltrates represented a secondary acute inflammatory process or some variant of pyogranulomatous inflammation was unclear from the sections examined. Skin samples also exhibited congestion of superficial dermal vessels and multifocal cross-sectioned parasites in the stratum corneum, in some cases associated with foci of neovascularization. Several samples showed a moderately attenuated epidermis with ballooning degeneration of keratinocytes. Several samples exhibited severe granulomatous dermatitis with Langerhans-type multinucleate giant replacing large portions of the superficial dermis and obscuring the dermal-epidermal junction. In one 1990 sample, mites were observed within dilated feather follicles which were severely hy-

perkeratotic and exhibited a severe granulomatous reaction and subjacent dermal fibrosis.

Of 31 samples examined, two exhibited normal histology for avian skin with no mites observed, one exhibited no inflammation with a single mite present in the histosection, and four exhibited mild inflammation with no mites observed in the histosection.

Epidermoptid mites primarily infest birds; morphologically and pathophysiologically they are very similar to the psoroptid mites infesting mammals (Fain, 1965). Epidermoptid mites of the genus *Myialges*, subgenus *Metamicrolichus*, are parasitic in all their life stages. The mites are usually found embedded in the cornified layers of the skin where they cause mange-like lesions (Fain, 1965), as we observed in Laysan albatross fledglings from Midway in 1990 and 1991. The severity of the inflammation in skin samples from dead Laysan albatross fledglings suggests that mange due to *Myialges nudus* may have been a significant cause of morbidity, or even mortality, in these birds in 1990 and 1991.

The fact that *M. nudus* infestation has previously only been reported for terrestrial bird species raises the question as to how Laysan albatross fledglings on Midway Atoll became infested by this ectoparasite. It is possible that mites were introduced to the atoll on hippoboscids. A different *Myialges* sp., *M. caulotoon*, was recovered from hippoboscids collected from brown pelicans (*Pelecanus occidentalis*) and flightless cormorants (*Nannopterum harrisi*) on the Galapagos Islands (Madden and Harmon, 1998). Another possibility is that the mite was introduced to Midway Atoll on canaries (*Serinus canaria*) or common mynahs (*Acridotherus tristis*), both of which are terrestrial species first brought to Midway as pets at the turn of the century. They have since established large feral populations on the atoll. To our knowledge, the ectoparasites of

these two species on Midway Atoll have not been investigated.

The difference in average mite abundance between fledglings raised in ironwood groves and those raised on lawns suggests that Laysan albatrosses raised in ironwood groves experienced comparatively heavier mite infestations. A cause for this difference is unknown. The biological and physical characteristics of these two habitats differ dramatically in terms of ambient temperature, wind, solar exposure, bird/mammal/insect/plant assemblages, and human impacts. However, it is difficult to speculate on which, if any, of these habitat characteristics is related to the observed difference in degree of infestation in birds from the two different habitat types, as very little is known about the ecology of *Myialges nudus*.

This research was conducted on Midway Atoll under US Fish and Wildlife Service (USFWS) Special Use Permit No. MID-04-91. Samples were collected from Laysan albatross under USFWS Scientific Collections Permit No. PRT-749652. Tissue and arthropod samples were imported under U.S. Department of Agriculture (USDA) Animal Plant Health Inspection Service Importation Permit no. 23807. This research was supported in part by funds from the University of California at Davis Student Chapter of the American Veterinary Medical Association, and the Northwestern Hawaiian Islands National Wildlife Refuge. G. Lee and R. Houston provided invaluable assistance in the laboratory. We thank A. Fain for identifying the parasite. Special thanks are extended to W. B. Tyler for introducing some of us (K. and J. Gilardi) to Midway Atoll.

LITERATURE CITED

- ASH, L. R., AND T. C. ORIHEL. 1987. Parasites: A Guide to Laboratory Procedures and Identification. ASCP Press, American Society of Clinical Pathologists, Chicago, Illinois, 328 pp.
- FAIN, A. 1965. A review of the family Epidermoptidae Trouessart parasitic on the skin of birds (Acarina: Sarcoptiformes). Verhandelingen Van De Koninklijke Vlaamse Academie Voor Weten-

- schappen, *Letteren en Schone Kunsten Van Belgie, Klasse Wetens.* 27 Pt. I: 1–176, Pt. II: 1–144.
- GOFF, M. L., P. R. SIEVERT, AND L. SILEO. 1989. New species of Apoloniinae (Acari: Trombiculidae) from the Laysan Albatross taken in the Midway Islands and a key to the species of Apoloniinae of the world. *Journal of Medical Entomology* 26: 484–486.
- GREVE, J. H. 1984. Mange caused by *Myialges (Metamicrolichus) nudus* in a gray-cheeked parakeet. *Journal of the American Veterinary Medical Association* 185(1): 101–102.
- HARRISON, C. S., T. S. HIDA, AND M. P. SEKI. 1983. Hawaiian seabird feeding ecology. *Wildlife Monographs* 85: 71 pp.
- MADDEN, D. AND W. M. HARMON. 1998. First record and morphology of *Myialges caulotoon* (Acari: Epidermoptidae) from Galapagos hosts. *The Journal of Parasitology* 84: 186–189.
- SILEO, L., P. R. SIEVERT, AND M. D. SAMUEL. 1990. Causes of mortality of albatross chicks at Midway Atoll. *Journal of Wildlife Diseases* 26: 329–338.
- WORK, T. M., M. R. SMITH, AND R. DUNCAN. 1998. Necrotizing enteritis as a cause of mortality in Laysan albatross, *Diomedea immutabilis*, chicks on Midway Atoll, Hawaii. *Avian Diseases* 42: 1–5.

Received for publication 11 January 2000.