



## **Cerebral Cysticercosis in a Woodchuck (*Marmota monax*)**

Authors: Bröjer, C. M., Peregrine, A. S., Barker, I. K., Carreno, R. A., and Post, C.

Source: Journal of Wildlife Diseases, 38(3) : 621-624

Published By: Wildlife Disease Association

URL: <https://doi.org/10.7589/0090-3558-38.3.621>

---

BioOne Complete ([complete.BioOne.org](https://complete.BioOne.org)) is a full-text database of 200 subscribed and open-access titles in the biological, ecological, and environmental sciences published by nonprofit societies, associations, museums, institutions, and presses.

Your use of this PDF, the BioOne Complete website, and all posted and associated content indicates your acceptance of BioOne's Terms of Use, available at [www.bioone.org/terms-of-use](https://www.bioone.org/terms-of-use).

Usage of BioOne Complete content is strictly limited to personal, educational, and non - commercial use. Commercial inquiries or rights and permissions requests should be directed to the individual publisher as copyright holder.

---

BioOne sees sustainable scholarly publishing as an inherently collaborative enterprise connecting authors, nonprofit publishers, academic institutions, research libraries, and research funders in the common goal of maximizing access to critical research.

## Cerebral Cysticercosis in a Woodchuck (*Marmota monax*)

C. M. Bröjer,<sup>1</sup> A. S. Peregrine,<sup>1</sup> I. K. Barker,<sup>1</sup> R. A. Carreno,<sup>1</sup> and C. Post<sup>2</sup> <sup>1</sup>Department of Pathobiology, Ontario Veterinary College, University of Guelph, Guelph, Ontario N1G 2W1, Canada; <sup>2</sup>Wildcare Wildlife Rehabilitation Centre, 9788 Pine Valley Drive, Woodbridge, Ontario L4L 1A6, Canada; Corresponding author (email: Caroline.Brojer@sva.se)

**ABSTRACT:** A juvenile woodchuck (*Marmota monax*) with vestibular signs was found in Woodbridge, Ontario (Canada) and later euthanized. At necropsy there was marked distortion of the right side of the skull, where a large, fluctuant, subcutaneous mass extended under the zygomatic arch and caudally from the right eye towards the right ear. The mass was multiloculated and contained a large number of tapeworm cysticerci, each about 1 to 2 mm in diameter. The third and lateral ventricles of the brain were dilated and contained large numbers of similar cysticerci. Based on the exogenous budding of cysts and the morphology of the scolex in each cyst, they were identified as cysticerci of *Taenia crassiceps*. This is the first report of cerebral cysticercosis in a woodchuck.

**Key words:** Case report, cerebral cysticercosis, cysticercus, *Marmota monax*, metacestodes, *Taenia crassiceps*, woodchuck.

On 19 September 1997, a young female woodchuck (*Marmota monax*) was found lying by the side of a road near Woodbridge (Ontario, Canada; 43°47'N, 79°36'W), and taken to the Wildcare Wildlife Rehabilitation Centre in Woodbridge. On presentation, the animal was depressed and ataxic. It also had nystagmus and a head tilt toward the right. When placed in sternal recumbency the woodchuck became distressed and preferred to roll onto its back. A large mass was noted on the right side of the head. Symptomatic treatment with dexamethasone (Dexamethasone 5 injection, Vétoquinol N.-A. Inc., Lavaltrie, Quebec, Canada) and enrofloxacin (Baytril injectable solution, Bayer Inc., Agriculture Division-Animal Health, Toronto, Ontario, Canada) was initiated. The mass was lanced and drained, and microscopic analysis of the contents revealed the presence of multiple metacestodes. Therapy was continued for 3 days until it could be submitted to the Canadian Co-operative Wildlife Health Centre (Guelph,

Ontario) for euthanasia and postmortem evaluation.

At necropsy there was marked distortion of the skull in the vicinity of the right zygomatic arch. Radiographs revealed lateral displacement of the zygomatic arch and marked thinning of the frontal process of the zygomatic bone and the zygomatic process of the temporal bone, without any periosteal reaction (Fig. 1). On gross examination the right palatine bone was also markedly thinned. In association with these changes, a large, subcutaneous, fluctuant mass extended under the zygomatic arch and caudally from the right eye towards the right ear. The mass was multilocular and contained a large number of clear spherical cysts, approximately 1–2 mm in diameter, which microscopically were identified as tapeworm cysticerci. No other subcutaneous or intrafascial cysts were observed. However, the third and lateral ventricles of the brain were dilated and contained many cysticerci (Fig. 2). Finally, multiple yellow-tan slightly raised nodules from 1–3 mm in diameter, which contained individual cysticerci, were present in both lungs; nodules were slightly more abundant in peripheral areas of the diaphragmatic lobes.

On microscopic examination, the cysticerci were observed to undergo exogenous budding. Each cysticercus contained a differentiated anterior scolex with four suckers and an apical rostellum with hooks of two sizes arranged in two rows, which appeared interdigitated. The number of large and small hooks per rostellum varied between 15 and 20 for each size. Five large and five small hooks from each of three cysticerci were measured. The large hooks were 180–213  $\mu\text{m}$  (average 197  $\mu\text{m}$ ) and the smaller hooks were 129–141  $\mu\text{m}$  (av-

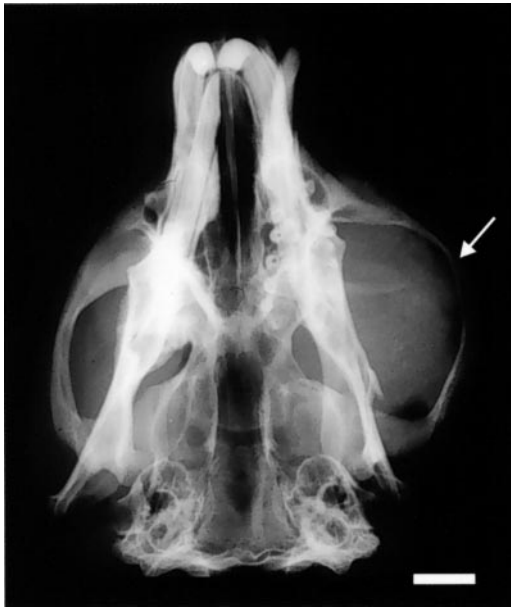

FIGURE 1. Dorso-ventral radiograph of a woodchuck skull showing lateral displacement of right zygomatic arch and thinning of frontal process of zygomatic bone and zygomatic process of temporal bone (arrow). Bar = 1 cm.

erage 136  $\mu\text{m}$ ). Based on these measurements as well as their morphology the cysticerci were identified as metacestodes of *Taenia crassiceps*, a tapeworm of foxes and other wild canids (Freeman, 1962). The size range reported for large hooks of *T. crassiceps* in various host species ranges from 129–210  $\mu\text{m}$ , while small hooks range from 95–157  $\mu\text{m}$  (Rausch, 1952; Freeman, 1962; Verster, 1969; Miyagi et al., 1990; Loos-Frank, 2000).

Selected tissues were fixed in 10% buffered formalin, embedded in paraffin, sectioned at 5  $\mu\text{m}$ , and stained with hematoxylin and eosin. Histologically, the markedly dilated ventricles of the brain contained sections of cysticerci. There also were numerous focal areas of malacia in the brain with mild hemorrhage, infiltrated by many macrophages, as well as occasional neutrophils, eosinophils, and lymphocytes. In several of the malacic areas there was axonal swelling and mild astroglyosis. These lesions were most prominent in periventricular and periaqueductal

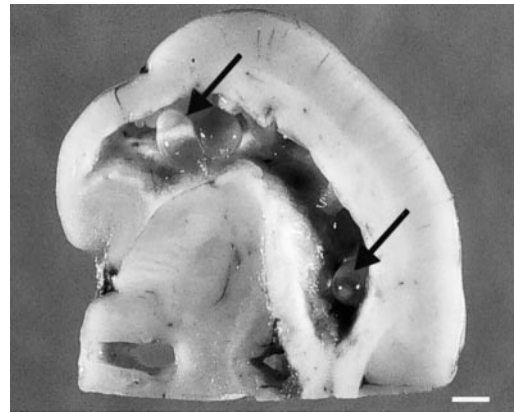


FIGURE 2. Transverse section of right half of a woodchuck brain showing dilated lateral ventricle containing several cysticerci of *Taenia crassiceps* (arrows). Bar = 1.5 mm.

areas. There also was a mixed inflammatory cell infiltrate in the meninges.

In cross sections of the palatine bone and its overlying muscles, there were large cystic spaces delineated by fibrous septa of varying thickness that contained intact, degenerate or mineralized cysticerci. The septa were infiltrated by a mixed inflammatory cell population that was more severe around degenerate larvae.

Despite the proximity of the large mass to the right eye, no cysticerci were found in the orbit or the globe. The lungs contained individual and multilocular parasite cysts, with a mixed inflammatory cell reaction, dominated by macrophages, in the fibrous septa surrounding the parasites. The inflammatory reaction in the lungs and subcutaneous tissues was consistent with that found by Albert et al. (1972) and Anderson et al. (1990) in woodchucks infected with the same parasite.

In North America, the adult form of *T. crassiceps* has been reported in arctic fox (*Alopex lagopus*) (Rausch, 1952), red fox (*Vulpes vulpes*) (Freeman, 1954), and wolves (*Canis lupus*) (Freeman, 1961). Natural infections with *T. crassiceps* larvae have also been reported in lemmings (*Dicrostonyx groenlandicus* and *Lemmus trimurcronatus*) (Rausch, 1952), eastern chipmunks (*Tamias striatus*) (Freeman,

1954), muskrats (*Ondatra zibethicus*) (Freeman, 1954), meadow voles (*Microtus pennsylvanicus*) (Freeman, 1954), woodchucks (Freeman, 1962; Beaudoin et al., 1969; Albert et al., 1972; Shiga et al., 1987; Anderson et al., 1990), and in a black lemur (*Eulemur macaco*) (Dyer and Greve, 1998).

*Taenia crassiceps* cysticerci in woodchucks are generally found in subcutaneous tissues in the cervical and axillary regions. Other locations include the inguinal area, peritoneal cavity, liver, between the trapezius and rhomboideus muscles, free in the thoracic cavity, and within the lung parenchyma (Albert et al., 1972; Anderson et al., 1990). In the present case, cysticerci were confined to brain, lung parenchyma, and subcutaneous tissue on the right side of the head. A similar case was reported by Shiga et al. (1987) in which a woodchuck developed a subcutaneous mass in the right cervical region extending to the submandibular area. Additional cysts in the maxillary sinus lifted the base of the right orbit, resulting in exophthalmos and nystagmus of the right eye. That animal also had numerous cysticerci in the lungs, but cysticerci were not reported in the brain.

Although reproduction of *T. crassiceps* metacestodes can continue in a host until it dies, the host can tolerate a large number of cysticerci (Freeman, 1962). Thus, none of the 18 cases observed by Albert et al. (1972) and Anderson et al. (1990) exhibited any signs of systemic illness. In contrast, in the present case the presence of cysticerci in the brain, and the associated extensive malacia, clearly interfered with neurological function. The ventricular dilation observed in the brain was probably due to interference with cerebrospinal fluid flow as a result of the inflammatory reaction and the presence of cysticerci in the ventricles and neuropil.

To the authors' knowledge this is the first report of cerebral cysticercosis in a naturally infected woodchuck. Cerebral cysticercosis should therefore be included

with rabies and *Baylisascaris* spp. visceral larva migrans as a cause of neurological disease in woodchucks.

In Europe, the common vole (*Microtus arvalis*) is the predominant intermediate host of *T. crassiceps*. Furthermore, cysticerci of *T. crassiceps* have been reported in the brain of experimentally infected voles (Rietschel, 1981), some of which developed signs of central nervous system disease. In abnormal intermediate hosts such as people, *T. crassiceps* has occasionally been found in intermuscular (Francois et al., 1998) and subcutaneous tissues (Chermette et al., 1995) as well as in the eye (Chuck et al., 1997). However, there are no reports of cysticerci in the brain.

It is unclear why the woodchuck in the present case developed lesions in atypical locations (i.e., brain and head) but not in more common sites (i.e., axillae and neck). The age and immune status of the animal may have played a role in the pathogenesis of the infection. The woodchuck was a juvenile and both Freeman (1962) and Rietschel (1981) have observed that young animals (white mice and common voles) are more susceptible to infection with *T. crassiceps* metacestodes than adults; inhibition of the rate of larval growth related to age (Freeman, 1962) appears to be antibody mediated (Beaudoin et al., 1969). Thus it is possible that the woodchuck was incapable of containing the infection to a subcutaneous location. On the other hand, cerebral cysticercosis in woodchucks may be more common than has been reported, but due to the location of cysticerci such animals become easy prey and are removed from the population before identification.

#### LITERATURE CITED

- ALBERT, T. F., R. L. SCHUELER, J. A. PANUSKA, AND A. L. INGLING. 1972. Tapeworm larvae (*Taenia crassiceps*) in woodchucks. *Journal of the American Veterinary Medical Association* 161: 648-651.
- ANDERSON, W. I., D. W. SCOTT, W. E. HORNBuckle, J. M. KING, AND B. C. TENNANT. 1990. *Taenia crassiceps* infection in the woodchuck: A retro-

- spective study of 13 cases. *Veterinary Dermatology* 1: 85–92.
- BEAUDOIN, R. L., D. E. DAVIS, AND K. D. MURRELL. 1969. Antibodies to larval *Taenia crassiceps* in hibernating woodchucks, *Marmota monax*. *Experimental Parasitology* 24: 42–46.
- CHERMETTE, R., J. BUSSIERAS, J. MARIONNEAU, E. BOYER, C. ROUBIN, B. PROPHETTE, H. MAILLARD, AND B. FABIANI. 1995. *Taenia crassiceps* invasive cysticercosis in an AIDS patient. *Bulletin de l'Académie Nationale de Médecine* 179: 777–783.
- CHUCK, R. S., R. J. OLK, G. J. WEIL, L. AKDUMAN, I. L. BENENSON, M. E. SMITH, AND H. J. KAPLAN. 1997. Surgical removal of a subretinal proliferating cysticercus of *Taenia crassiceps*. *Archives of Ophthalmology* 115: 562–563.
- DYER, N. W., AND J. H. GREVE. 1998. Severe *Cysticercus longicollis* cysticercosis in a black lemur (*Eulemur macaco macaco*). *Journal of Veterinary Diagnostic Investigation* 10: 362–364.
- FRANCOIS, A., L. FAVENNEC, C. CAMBON-MICHOT, I. GUEIT, N. BIGA, F. TRON, P. BRASSEUR, AND J. HEMET. 1998. *Taenia crassiceps* invasive cysticercosis. *American Journal of Surgical Pathology* 22: 488–492.
- FREEMAN, R. S. 1954. Studies on the biology of *Taenia crassiceps* (Zeder, 1800) Rudolphi 1810. *The Journal of Parasitology* 40 (Supplement. No. 5 section 2): 41.
- . 1961. Cestodes of wolves, coyotes, and coyote-dog hybrids in Ontario. *Canadian Journal of Zoology* 39: 527–532.
- . 1962. Studies on the biology of *Taenia crassiceps* (Zeder, 1800) Rudolphi, 1810 (Cestoda). *Canadian Journal of Zoology* 40: 969–990.
- LOOS-FRANK, B. 2000. An update of Verster's (1969) 'Taxonomic revision of the genus *Taenia* Linnaeus' (Cestoda) in table format. *Systematic Parasitology* 45: 155–183.
- MIYAGI, S., Y. OKU, M. OKAMOTO, M. OHBAYASHI, A. UCHIDA, AND R. L. RAUSCH. 1990. Growth of a Japanese isolate of *Taenia crassiceps* in intermediate and definitive hosts. *Parasitology Research* 76: 351–354.
- RAUSCH, R. 1952. Studies on the helminth fauna of Alaska. XI. Helminth parasites of microtine rodents—taxonomic considerations. *The Journal of Parasitology* 38: 415–444.
- RIETSCHER, G. 1981. Beitrag zur Kenntnis von *Taenia crassiceps* (Zeder 1800) Rudolphi, 1810 (Cestoda, Taeniidae). *Parasitology Research* 65: 309–315.
- SHIGA, J., H. AOYAMA, K. YAMAMOTO, S. IMAI, H. SAEKI, N. SASAKI, AND K. KOSHIMIZU. 1987. A case report of cysticercosis caused by *Cysticercus longicollis*, a larval form of *Taenia crassiceps* in a woodchuck (*Marmota monax*). *Experimental Animal* 36: 213–217.
- VERSTER, A. 1969. A taxonomic revision of the genus *Taenia* Linnaeus, 1758 s. str. *Onderstepoort Journal of Veterinary Research* 36: 3–58.

Received for publication 13 January 1999.